VETERINARSKI ARHIV 95 (3), 351-363, 2025 DOI: 10.24099/vet.arhiv.2690

Investigation of changes in goblet cells in the digestive tract of Van fish during reproductive migration

Burcu Ergöz Azizoğlu[1], Zehra Alkan[2], Ayşe Nur Erdemir[2], Elif Örgi[2], Elif Kaval Oğuz[3] and Ahmet Regaib Oğuz[2*]

[1]Yüksekova Vocational School Crop and Animal Production Dairy and Livestock Breeding Program, Hakkari University, Türkiye
[2]Department of Biology, Faculty of Science, Van Yüzüncü Yıl University, Türkiye
[3]Faculty of Education, Science Education, Van Yüzüncü Yıl University, Türkiye

AZIZOĞLU, B. E., Z. ALKAN, A. N. ERDEMIR, E. ÖRGI, E. K. OĞUZ, A. R. OĞUZ: Investigation of changes in goblet cells in the digestive tract of Van fish during reproductive migration. Vet. arhiv 95, 351-363, 2025.

ABSTRACT

Lake Van is among the largest soda lakes in the world. The Van fish is an endemic species of the carp family living in Lake Van. In order to breed, they migrate in flocks to the streams flowing into the lake between April and July, depending on the water temperature. After the fish lay their eggs in the fresh water, they return to Lake Van. In this study, goblet cells in the digestive tract of Van fish during reproductive migration were labeled with periodic acid–Schiff, Alcian Blue pH 2.5, Alcian Blue pH 1.0, Alcian Blue pH 0.5, and aldehyde fuchsin dyes. Changes in cell localization, density, and area were determined in different parts of the digestive tract in goblet cells containing neutral, acidic, O-sulfate ester, strongly sulfated, and sulfated acidic glycoconjugate. In the esophagus, goblet cells were only observed in the fish from Lake Van. Although goblet cell size and density varied in other parts of the digestive tract, all glycoconjugates were labeled. In the digestive tract of fish from the lake, the goblet cell areas were large, but the cell density was low, whereas the situation in the digestive tract of fish sampled from the streams was the opposite. It was concluded that the main reason for the goblet cell change in the digestive tract of Van fish is related to its feeding behavior and habitat.

Key words: goblet cells; digestive tract; Van fish, Lake Van

Introduction

The Van fish (*Alburnus tarichi*, Güldenstädt, 1814) is an endemic carp species living in Lake Van. It is the only vertebrate species adapted to the extreme conditions of the lake (pH 9.8, high alkalinity 153 mEq/L, and brackish water with 22‰ salinity). Fish caught from the lake are consumed by the local people as a high protein food source, and contribute positively to the local economy (DANULAT and KEMPE, 1992; DANULAT and SELÇUK, 1992).

* Corresponding author:
Ahmet Regaib Oğuz, Department of Biology, Faculty of Science, Van Yüzüncü Yıl University, 65080, Van/Türkiye, e-mail: ahmetoguz@yyu.edu.tr, ORCID: 0000-0001-6431-0508

ISSN 0372-5480
Printed in Croatia

While the Van fish fulfills its functions, such as growth and nutrition, in the lake, it moves to the fresh waters flowing into the lake to reproduce. When the fish reach reproductive maturity (+3 years old), they move en masse into fresh waters that flow into the lake to lay their eggs. This transition takes place in April-July, depending on the water temperature. The fish adapt by waiting downstream due to the different physicochemical conditions between the lake and river environments. During this process, histological and cytological changes are observed in organs and tissues responsible for osmoregulation, such as the kidneys, gills, skin, and digestive tract (OĞUZ, 2013; ÇELEBI and OĞUZ, 2020; ALKAN and OĞUZ, 2021). It is known that the fish do not feed during breeding migration, and are exposed to stress due to the pressure of hunting. They use most of their energy by moving against the current during the breeding migration (OĞUZ, 2015).

As in all vertebrates, the alimentary canal in fish consists of the oral cavity, pharynx, esophagus, stomach, anterior and posterior intestine, as well as the rectum that opens to the outside (GENTEN et al., 2009). The digestive tract of fish differs morphologically and histologically from species to species (MORRISON and WRIGHT, 1999). These differences are caused by lifestyle and dietary habits (such as omnivores, herbivores, and carnivores) (OLSSON and HOLMGREN, 2011). In addition, the morphology of the digestive system in fish is related to body size, ontogeny, and phylogeny (BANAN KHOJASTEH, 2012). Nutritional habits affect stomach size and intestinal length morphologically (SANTOS et al., 2015).

Depending on the parts of the digestive tract and the differences between species, the thickness of the layers and the lengths of the folds forming the tunica mucosa vary. When the digestive tract is examined histologically, it consists of a serous layer of epithelial cells, a muscularis layer of muscle cells, the submucosa of connective tissue cells, and tunica mucosa surrounding the lumen in the epithelial lamina (TAKASHIMA and HIBIYA, 1995; GENTEN et al., 2009; OSTASZEWSKA and MACIEJ, 2019).

Mucus is a slimy protective fluid secreted by mucous cells (e.g. goblet cells) found in the tunica mucosa (LAI et al., 2009). The task of mucus cells is to allow nutrients to slide easily along the channel and protect the cells against the harmful effects of chemicals. The density of mucus secreted from cells varies according to stress, pollutants, nutrition, and physical and chemical damage (SHEPHARD, 1994). Mucins secreted from the digestive system undertake many tasks. These include lubrication, digestion, absorption, controlling infectious diseases, and inhibiting the proliferation of harmful microorganisms (LORETZ, 1995; DOMENEGHINI et al., 2005). The mucus is a highly hydrated gel composed of 95% water and minor components, such as 5% mucin and electrolytes (DÍAZ et al., 2008). Mucins are high molecular weight glycoproteins. It has been stated that mucin glycoproteins constitute the main component of secretory mucins, transmembrane mucins in the apical membrane, and the glycocalyx (JOHANSSON et al., 2011).

It is known that the histochemical structures of mucins in the digestive tract of fish vary according to species, age, and habitat (GRAU et al., 1992; SARASQUETE et al., 2001; CAO and WANG, 2009). The presence and number of goblet cells along the channel in fish varies (DOMENIGHINI et al., 1998; SANDEN et. al., 2005). While it was stated that the mucus content was not affected by nutrition (ORTIZ-DELGADO et al., 2012), it was found in some studies that goblet cell contents changed due to the nutritional content (TIBBETTS, 2005; LUZZANA et al., 2005).

Goblet cells containing neutral glycoconjugate have a buffering effect on enzymatic digestion and absorption, and transport of molecules in the plasma membrane, as well as on the high acid content of the stomach (PETRINEC et al., 2005). It has been found that goblet cells containing acidic glycoconjugate in the posterior intestine help to remove food residues (SHI et al., 2007).

Studies have shown that the histochemical structures of mucins vary depending on the fish species, age, environment, and diet (ELIA et al., 2018). In the present study, the aim was to examine the changes in cell location, density, and areas of goblet cells in the digestive tract during the reproductive migration of Van fish.

Materials and methods

Fish. During the breeding migration, a total of 20 fish were caught from Lake Van (n:10) and streams (n:10) flowing into the lake. The fish were anesthetized by administering phenoxyethanol (320 µL/L). After the total length and weight of these fish were measured, they were dissected and the digestive tract was removed. The operculum of the fish was removed for age determination (KAVAL OĞUZ et al., 2021).

All of the animal experimental procedures were performed in accordance with the animal study protocols approved by the Animal Researchers Local Ethic Committee of Van Yüzüncü Yıl University (protocol no: 2021/04-05).

Histology. The digestive tract, esophagus, intestinal bulb, and anterior and posterior intestines were identified and removed (1 cm long piece) and kept in Bouin's fixative for 24 hours. Tissues were placed in 70% alcohol after fixation. They were passed through a graded alcohol series and embedded in paraffin. Sections of 5 µm were taken from the tissues and stained with hematoxylin and eosin (H&E), periodic acid–Schiff (PAS), Alcian blue pH 0.5, Alcian blue pH 1, Alcian blue pH 2.5, and aldehyde fuchsin dyes (BANCROFT and GAMBLE, 2002). The stained tissues were covered with Entellan and examined under a light microscope (Leica DMI 6000B, Germany) and photographed with a Leica DFC 490 camera (Leica Microsystems, Germany).

For quantitative histochemical analysis, cell densities and areas were measured in fish digestive tracts sampled from river and lake environments. For cell density, counts were performed in 20 areas, each with an area of 1 mm^2 of the epithelial section area, randomly chosen from microphotographs of the esophagus, intestinal bulb, and anterior and posterior intestines. For cell areas, measurements were made in 40 cells in different sections. Measurements were performed in the LAS program (Leica Application Suite, version 2.6.R1, Germany).

Statistics. The data were expressed as the mean ± standard error of the mean (SEM). Raw data were analyzed using SPSS (V 11.5, SPSS Company, Chicago, IL, USA). The data were analyzed by Student's t-test to determine differences between the groups. Significance was accepted at $P<0.05$.

Results

The total weight and fork length of the caught fish were 90-130 g and 18-22 cm, respectively. The fish examined in the study were determined to be 3+ years old. The digestive tract content of the fish caught in the river was empty, while the digestive tract content was intense in the fish caught in the lake.

The digestive tract of the Van fish consisted of an oral cavity, pharynx, esophagus, a intestinal bulb, and anterior and posterior intestines (Fig. 1). When the digestive tract was examined histologically, as in other vertebrates, from the outermost to the lumen, it consisted of a serous layer surrounding the canal, a muscularis layer consisting of muscle tissue, a submucosa layer consisting of loose connective tissue, and a tunica mucosa consisting of folds and containing goblet cells in the epithelial lamina. The mucous layer containing goblet cells consists of cells and loose connective tissue (Fig. 2).

The esophagus, which was the first part of the digestive tract examined, was quite short compared to the other parts. The muscularis layer consisted of striated muscle. The folds of the tunica mucosa were shorter and less numerous compared to the other parts, and there were goblet cells in it.

No true stomach structure was found after the esophagus in the Van fish. However, there was a intestinal bulb that served as a structurally and histologically differentiated stomach. These histological differences are clearly seen in the tunica mucosa and muscle tissue. The difference is that the folds of tunica mucosa of the part that acts as the stomach were longer compared to the tunica mucosa of the esophagus and intestines. The muscularis layer consists of a thin smooth muscle. The intestinal bulb was followed by the anterior intestine. The tunica mucosa of this structure was thinner than that of the intestinal bulb. The posterior intestine was the last part of the digestive tract and opened to the anus (Fig. 1). The tunica mucosa with goblet cells was thinner than the anterior one.



Fig. 1. Photograph of the Van fish and digestive tract

OS: esophagus, IB: intestinal bulb, AI: anterior intestine, PI: posterior intestine, RT: rectum

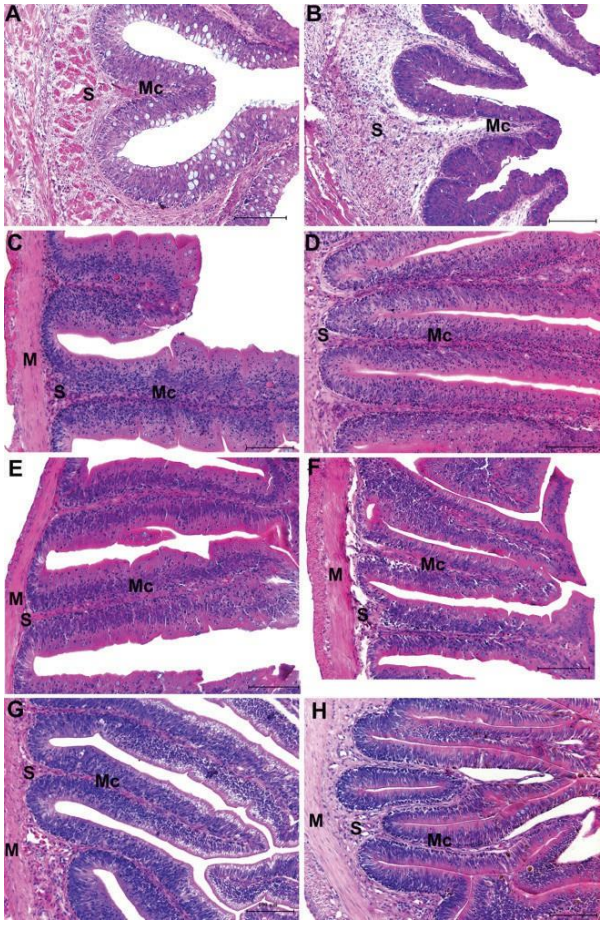

Fig. 2. Transverse section of the digestive tract stained with H&E

The esophagus (A, B), intestinal bulb (C, D), anterior gut (E, F), and posterior gut (G, H) (A, C, E, G: lake; B, D, F, H: from fresh water) (M: muscularis layer, S: submucosa layer, Mc: mucosa layer). Scale bar = 100 µm.

Goblet cell glycoconjugate content changed during the reproductive migration of Van fish (Fig. 3). Neutral mucins were stained with PAS. While the goblet cells containing neutral glycoconjugate in the esophagus were quite dense in the lake environment, they were not seen in the stream environment. The intestinal bulb, and the neutral glucoconjugate-containing mucus cells in the foregut and hindgut were more dense in fish in the stream environment, but the area was larger in fish in the lake environment. (Fig. 4).

Alcian blue pH 2.5 dye was used to identify goblet cells containing acidic glycoconjugate. While goblet cells throughout the digestive tract of fish sampled from the lake and stream showed positive results with Alcian blue pH 2.5, a difference was observed in their density (Fig. 5). The area of goblet cells containing acid glycoconjugate was largest in the fish esophagus in the lake environment. There was an increase in the area of these cells from the intestinal bulb towards the posterior intestine (Fig. 6A). The densities of the goblet cells containing acid glycoconjugate were higher in the esophageal part in the lake environment, while in the other parts it was higher in the fluvial environment. (Fig. 6B).

Mucous cells containing O-sulfate ester glycoconjugate were determined in some parts of the gastrointestinal tract of the Van fish. Digestive system sections were stained with Alcian blue pH 1.0 dye. While goblet cells containing O-sulfate ester glycoconjugate were stained in the esophagus in the lake environment, they were less visible in the stream environment. (Fig. 7). The intestinal bulb was stained in the river environment, with more intense staining in the anterior and posterior intestines. The number and area of goblet cells containing O-sulfate ester glycoconjugate in the esophagus were greater in fish in the lake environment compared to fish in the stream environment (Fig. 8). However, in other parts of the channel, the areas of these goblet cells were larger in the lake environment, while the number of cells was higher in the river environment.

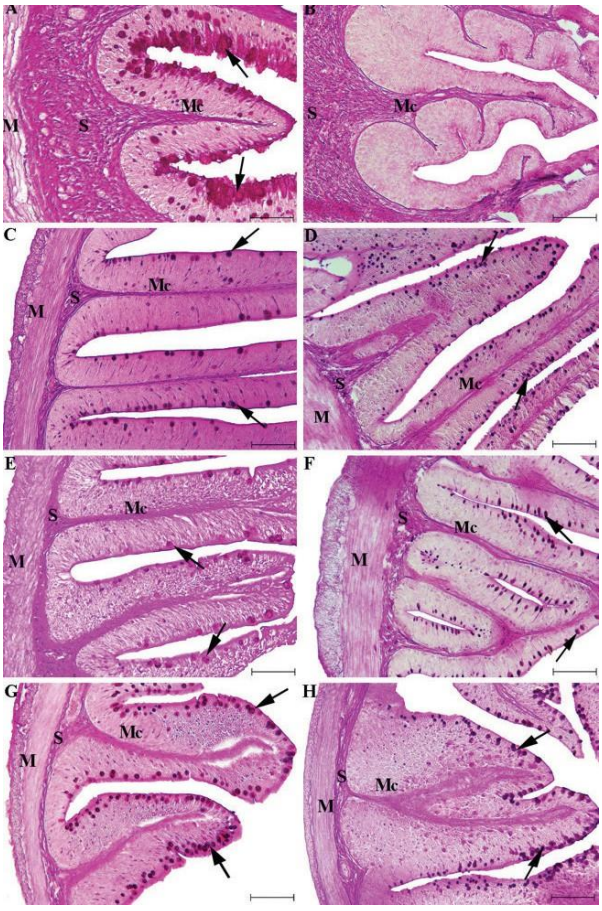

Fig. 3. Sections of the Van fish stained with PAS responding to neutral glycoproteins in goblet cells in the digestive tract (arrow) from the esophagus (A, B), intestinal bulb (C, D), anterior gut (E, F), and posterior gut (G, H) (A, C, E, G: lake; B, D, F, H: from fresh water)

(M: muscularis layer, S: submucosa layer, Mc: mucosa layer). Scale bar = 100 µm

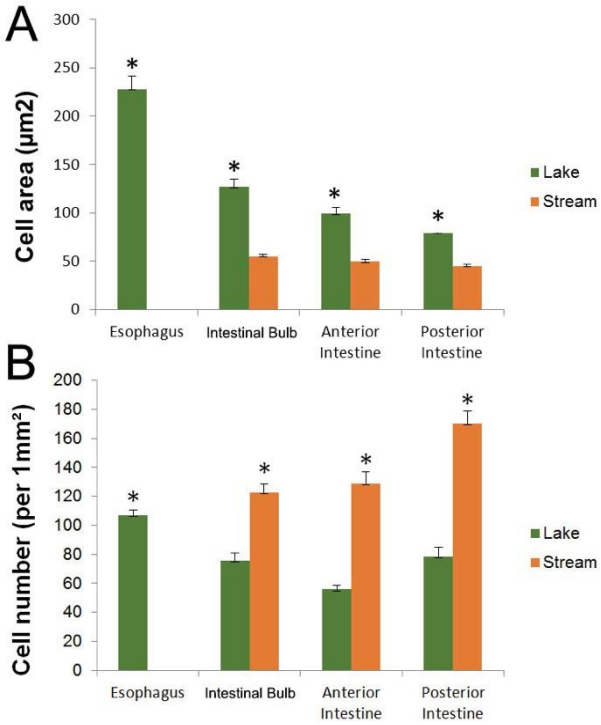

Fig. 4. Goblet cell area (A) and cell number (B) containing neutral glycoconjugate in the digestive tract of the Van fish during reproductive migration

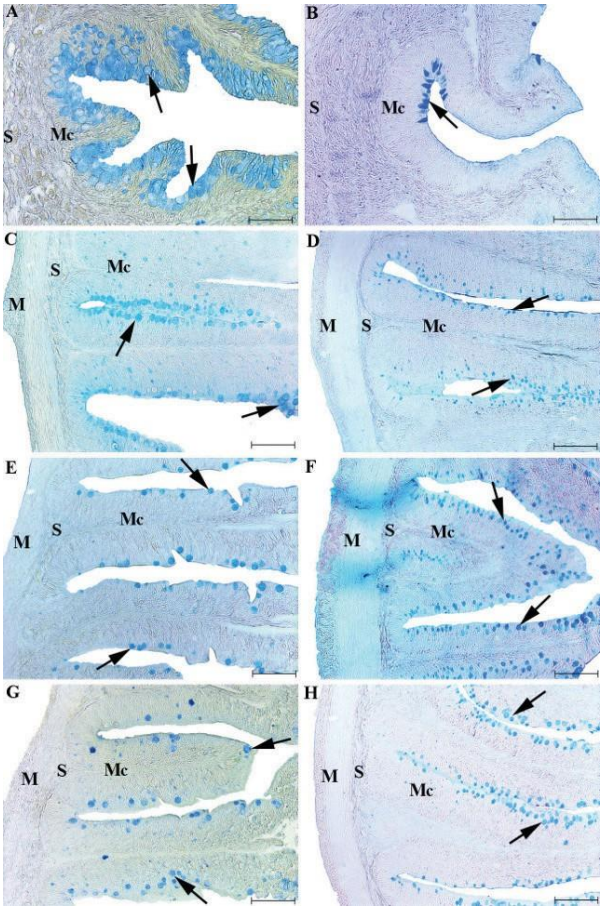

Fig. 5. Sections of Van fish stained with Alcian blue pH 2.5 responding to acidic glycoproteins in goblet cells in the digestive tract (arrow) from the esophagus (A, B), intestinal bulb (C, D), anterior gut (E, F), and posterior gut (G, H) (A, C, E, G: lake; B, D, F, H: from fresh water)
(M: muscularis layer, S: submucosa layer, Mc: mucosa layer). Scale bar = 100 µm

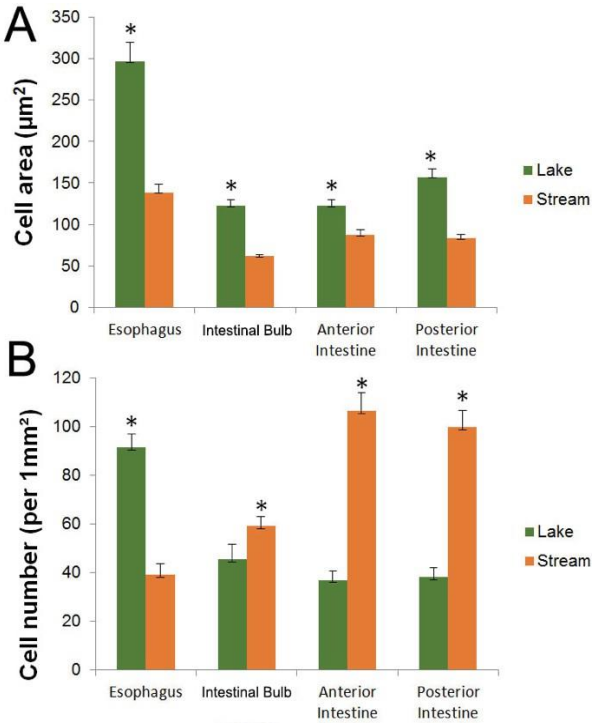

Fig. 6. Goblet cell area (A) and cell number (B) containing acid glycoconjugate in the digestive tract of the Van fish during reproductive migration

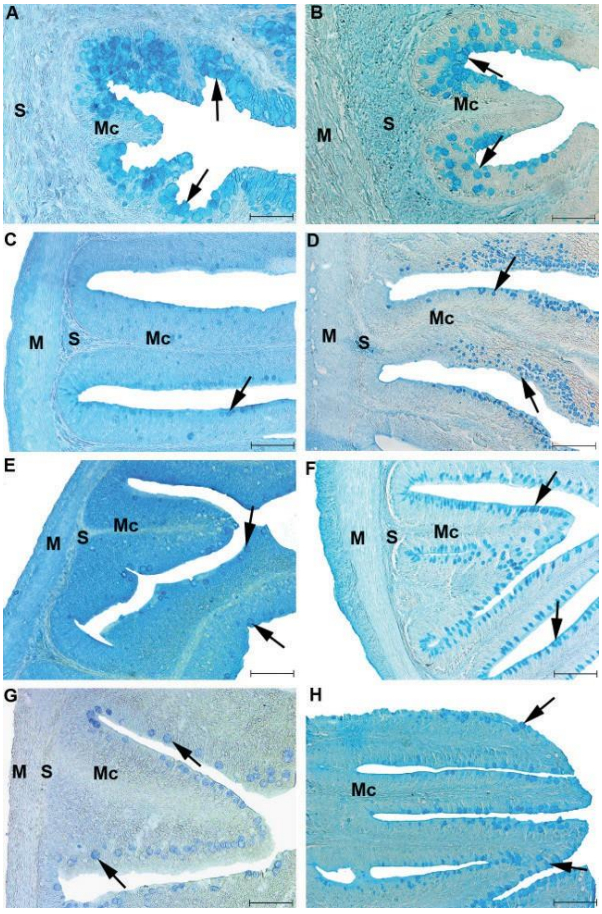

Fig. 7. Sections of Van fish stained with Alcian blue pH 1.0 responding to O-sulfate ester glycoproteins in goblet cells in the digestive tract (arrow) from the esophagus (A, B), intestinal bulb (C, D), anterior gut (E, F), and posterior gut (G, H) (A, C, E, G: lake; B, D, F, H: from fresh water)
(M: muscularis layer, S: submucosa layer, Mc: mucosa layer). Scale bar = 100 µm

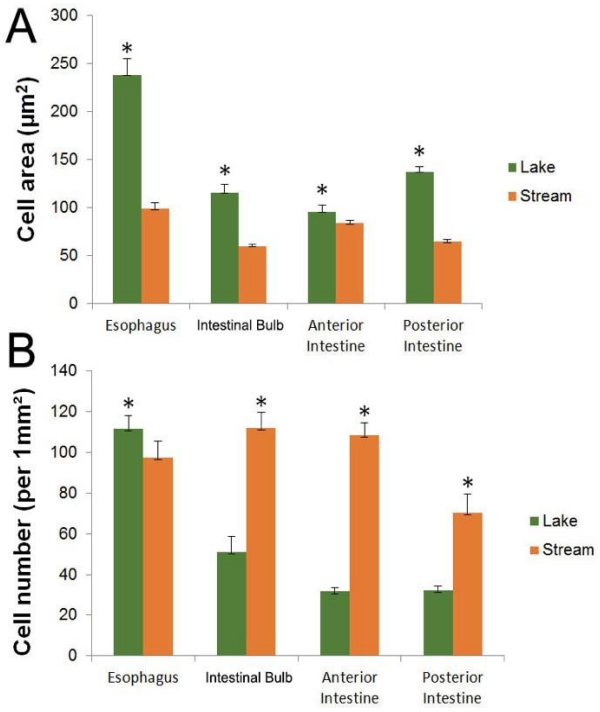

Fig. 8. Goblet cell area (A) and cell number (B) containing O-sulfate ester glycoconjugate in the digestive tract of the Van fish during breeding migration

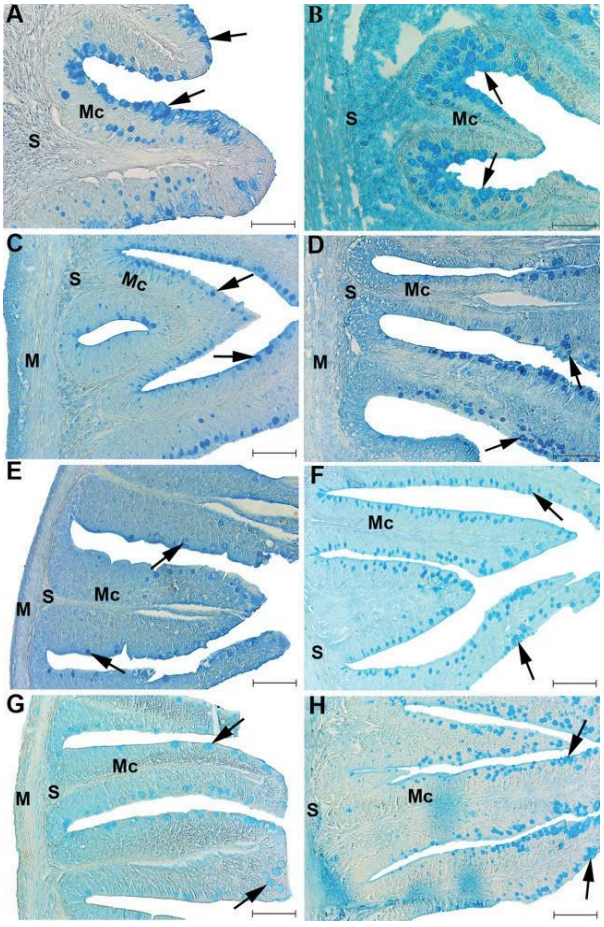

Fig. 9. Sections of Van fish stained with Alcian blue pH 0.5 responding to strong sulfated glycoproteins in goblet cells in the digestive tract (arrow) from the esophagus (A, B), intestinal bulb (C, D), anterior gut (E, F), and posterior gut (G, H) (A, C, E, G: lake; B, D, F, H: from fresh water)

(M: muscularis layer, S: submucosa layer, Mc: mucosa layer). Scale bar = 100 µm

Alcian blue pH 0.5 dye was used to identify goblet cells containing strong sulfated glycoconjugate. There were differences between the two environments along the channel (Fig. 9). While there was intense staining in the esophagus in the lake environment, goblet cells containing strong sulfate glycoconjugate were not seen in the stream environment. Goblet cells were denser in the intestinal bulb, anterior intestine and posterior intestines of fish sampled from the river environment (Fig. 10).

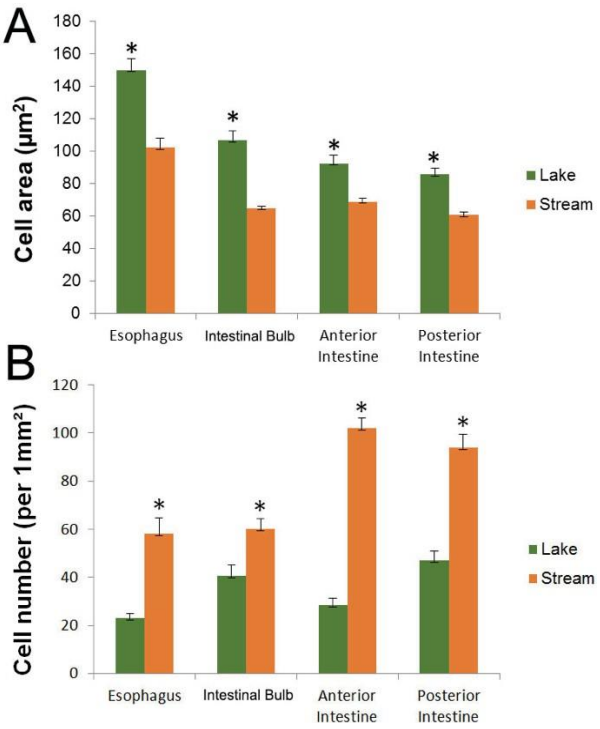

Fig 10. Goblet cell area (A) and cell number (B) containing strong sulfate glycoconjugate in the digestive tract of the Van fish during breeding migration

The number and size of goblet cells containing strong sulfated glycoconjugate differed between parts of the digestive tract, and the lake and stream environments. The area of goblet cells along the channel was larger in the lake environment. The number of goblet cells was greater in fish in the river environment.

Goblet cells containing sulfated acidic glycoconjugate were identified with aldehyde fuchsin. In the esophagus, they were stained intensely in the lake environment, while rarely seen in the river environment (Fig. 11). Mucus cells containing sulphate acidic glucoconjugate were found densely in the intestinal bulb, anterior intestine and posterior intestine of the river samples. (Fig. 12).

The goblet cell area was greater in fish that were in the lake environment along the digestive tract, while the number of goblet cells was higher in the esophagus part in the lake environment, it was higher in the other parts in the river environment.

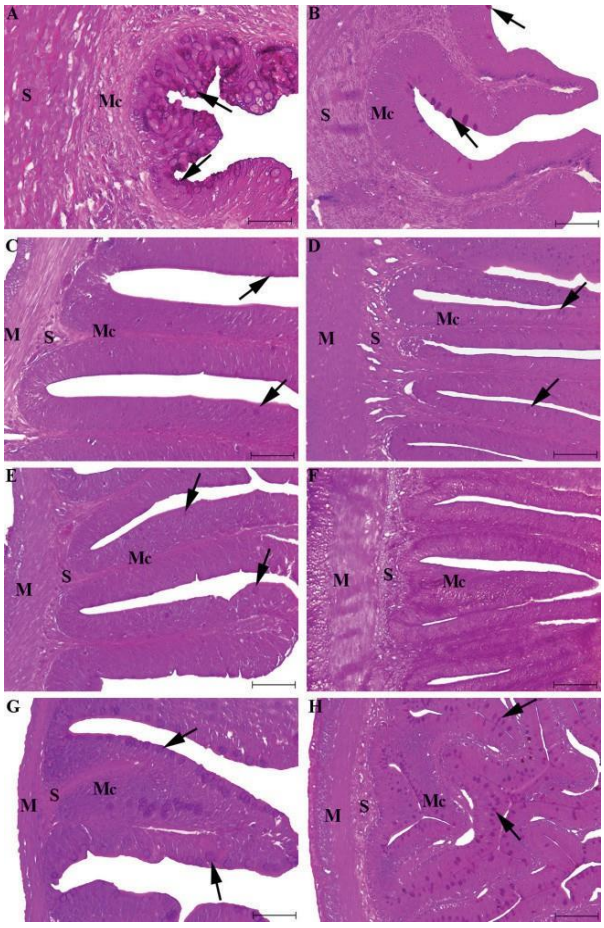

Fig 11. Sections of Van fish stained with Aldehyde fucsin responding to sulfated acidic ester glycoproteins in goblet cells in the digestive tract (arrow) from the esophagus (A, B), intestinal bulb (C, D), anterior gut (E, F), and posterior gut (G, H) (A, C, E, G: lake; B, D, F, H: from freshwater)

(M: muscularis layer, S: submucosa layer, Mc: mucosa layer). Scale bar = 100 µm

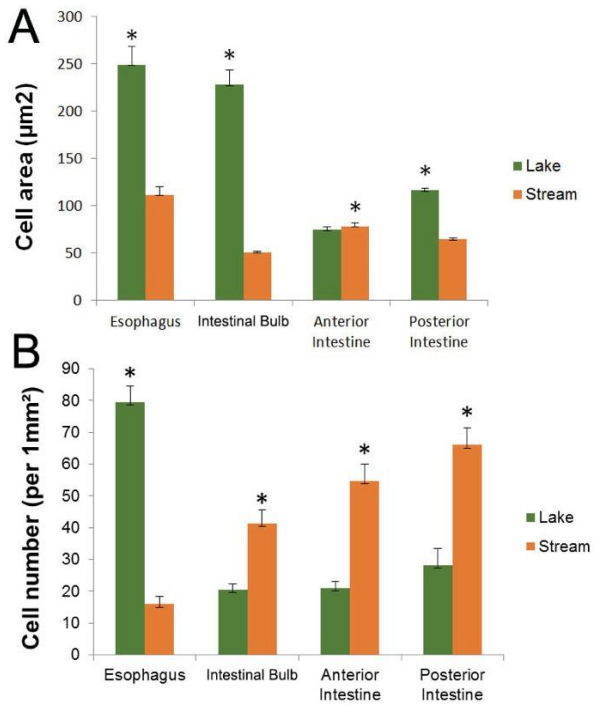

Fig. 12. Goblet cell area (A) and cell number (B) containing sulfated acidic ester glycoconjugate in the digestive tract of the Van fish during reproductive migration

Discussion

The digestive tract in the Van fish is histologically composed of serous, muscularis, submucosa, and tunica mucosa parts. It has been reported that the thickness and width of these layers vary according to the fish species and diet (DOMENEGHINI et al., 1998; MORRISON and WRIGHT, 1999). Close to the lumen, the tunica mucosa, consisting of folds, is the layer containing goblet cells (TAKASHIMA and HIBIYA, 1995; PARK and KIM, 2001). There are differences in the number and length of folds of the tunica mucosa that contain mucous cells along the Van fish digestive tract (ERGOZ and OĞUZ, 2023). Van fish reduce feeding in the stream environment due to stressful conditions during breeding migration. At the same time, the nutritional contents of fish in lakes and streams also differ. The reason for this is the realization of different functions, such as digestion and absorption in the regions of the digestive tract.

In the present study, as a result of morphometric measurements and histochemical staining, it

was observed that the goblet cells in the esophagus region affected by the lake water were greater in number and area than in the other regions. Along with the food intake in fish, some water from outside enters the food channel. Therefore, the alkaline and brackish water of Lake Van may have increased goblet cell secretion in the lake environment, where nutrient uptake takes place (KIM et al., 2008).

It is thought that physicochemical differences in water affect fish homeostasis (SADAUSKAS-HENRIQUE et al., 2019; YEŞILBAŞ and OĞUZ, 2022). It has been stated that goblet cells may have a role in ion regulation due to the glycoconjugate contents secreted from the cells in different pH ranges (POWELL et al., 1994). Van fish undergo a number of cytological and molecular changes to ensure osmoregulation during reproductive migration (OĞUZ, 2015). These changes are clearly observed in organs that play a role in osmoregulation, such as the digestive tract, gills, kidneys, and skin, which play a role in food intake. The results of our study indicate that changes in goblet cell contents, areas, and densities in the digestive tract of Van fish during reproductive migration may be caused by ionoregulation.

Goblet cell secretions surround the mucous layer like a barrier and protect it from microbial and parasitic infection, and physical and chemical abrasions from ingested nutrients. The number, density, and localization of goblet cells in fish exposed to different effects have been studied (TIBBETTS, 2005; CAO and WANG, 2009). It has been found that temperature, salinity, and pH affect the number, density, and localization of goblet cells (POWELL et al., 2001; ROBERTS and POWELL, 2003). Van fish show different feeding behaviors while migrating from Lake Van, which has high alkalinity and pH, to fresh waters to reproduce. The fish that feed in the lake do not feed in fresh waters, or feed very little. The larger goblet cell areas in lake-caught fish than in freshwater-caught fish may be related to nutrient digestion. High mucus secretion prevents the destruction of the mucous layer by digestive enzymes. In particular, neutral mucins are helpful in providing important cofactors for digestion, nutrient absorption, and breakdown of nutrients (VIDAL et al., 2020). It has been found that sulfated acid mucins are involved in the transfer of ions, liquids, and proteins (PETRINEC et al., 2005). For this reason, it is expected that goblet cell secretion is high in Van fish from the lake.

It is also known that goblet cells protect against microbial and parasitic infections. In a study on mullets it was reported that goblet cell density was higher in the intestines of fish infected with parasites compared to uninfected fish (BOSI and DEZFULI, 2015). Parasitic infections in Van fish are encountered in fresh waters (OĞUZ 2013; OĞUZ and OĞUZ, 2020). In addition, due to the high alkalinity of Lake Van, the diversity of microbial organisms and parasites is limited there (OĞUZ and OĞUZ, 2020). The number of goblet cells is higher in the fish of Lake Van in the river environment than in the fish in the lake environment. This suggests that the microbial and parasite density in the river environment causes an increase in the smaller volume goblet cells that perform the protective task. The histochemical results of this study confirm that each region of the gastrointestinal tract, on the basis of its function, requires a specific type of secretion. Different goblet cells may undertake various tasks in Van fish.

Conclusions

In conclusion, in our study, we found that the goblet cells and glycoconjugate contents in the digestive tract of the anadromous Van fish, which is endemic to Lake Van and very important for the local people, changed during reproductive migration. This study provides for the first time data on the number of goblet cells and their distribution in each region of the gastrointestinal tract of Van fish. These changes may be due to the physicochemical content of the water, the state of hunger and satiety, and factors such as parasites and stress. Although the morphological and histochemical adaptations observed in the digestive tract are related to the phylogeny of the fish, the main reason for these changes observed in the Van fish is thought to be related to their feeding behavior and habitat.

Ethics approval

All of the animal experimental procedures were performed in accordance with the animal study protocols approved by the Animal Researchers Local Ethic Committee of Van Yüzüncü Yıl University (protocol no: 2021/04-05).

Declaration of competing interest

No potential conflict of interest was reported by the authors.

References

ALKAN, Z., A. R. OĞUZ (2021): Investigation of gill goblet cells of Lake Van fish (*Alburnus tarichi*) during reproductive migration. Fish. Physiol. Biochem. 47, 409-419. https://doi.org/10.1007/s10695-020-00921-6

BANAN KHOJASTEH, S. M (2012): The morphology of the post-gastric alimentary canal in teleost fishes: a brief review. Int. J. Aquat. Sci. 3, 71-88.

BANCROFT, J. D., M. GAMBLE (2002): Theory and practice of histological techniques. 5th ed., Churchill Livingstone Publication, Edinburgh, pp. 593-620.

BOSI, G., B. S. DEZFULI (2015): Responses of Squalius cephalus intestinal mucous cells to *Pomphorhynchus laevis*. Parasitol. Int. 64, 167-172. https://doi.org/10.1016/j.parint.2014.11.018

CAO, X. J., W. M. WANG (2009): Histology and mucin histochemistry of the digestive tract of yellow catfish, *Pelteobagrus fulvidraco*. Anat. Histol. Embryol. 38, 254-261. https://doi.org/10.1111/j.1439-0264.2009.00932.x

ÇELEBI, F, A. R. OĞUZ (2020): The Changes of mucous cells in the skin of Van Fish [*Alburnus tarichi* (Güldenstädt, 1814)] during freshwater adaptation. Commagene. J. Biol. 4, 86-90. https://doi.org/10.31594/commagene.751122

DANULAT, E., S. KEMPE (1992): Nitrogeneus waste excretion and accumulation of urea and ammonia in *Chalcalburnus tarichi* (Cyprinidae) endemic to Lake Van (eastern Turkey). Fish. Physiol. Biochem. 9, 377-386. https://doi.org/10.1007/BF02274218

DANULAT, E., B. SELÇUK (1992): Life history and environmental conditions of the anadromous *Chalcalburnus tarichi* (*Cyprinidae*) in the highly alkaline Lake Van, eastern Anatolia, Turkey. Arch. Hydrobiol. 126, 105-125. https://doi.org/10.1127/archiv-hydrobiol/126/1992/105

DIAZ, A. O., A. M. GARCIA, A. L. GOLDEMBERG (2008): Glycoconjugates in the mucosa of the digestive tract of *Cynoscion guatucupa*: a histochemical study. Acta. Histochem. 110, 76-85. https://doi.org/10.1016/j.acthis.2007.08.002

DOMENEGHINI, C., S. ARRIGHI, G. RADAELLI, G. BOSI, A. VEGGETTI (2005): Histochemical analysis of glycoconjugate secretion in the alimentary canal of *Anguilla anguilla* L. Acta. Histochem. 106, 477-487. https://doi.org/10.1016/j.acthis.2004.07.007

DOMENEGHINI, C., R. PONNELLI STRAINI, A. VEGGETTI (1998): Gut glycoconjugates in *Sparus aurata* L. (Pisces, Teleostei). A Comparative histochemical study in laval and adult ages. Histol. Histopathol. 13, 359-372. https://doi.org/10.14670/HH-13.359

DOS SANTOS, M. L., F. P. ARANTES, T. C. PESSALL, J. E. DOS SANTOS (2015): Morphological, histological and histochemical analysis of the digestive tract of *Trachelyopterus striatulus* (Siluriformes: Auchenipteridae). Zoologia (Curitiba) 32, 296-305. https://doi.org/10.1590/S1984-46702015000400005

ELIA, A. C., M. T. CAPUCCHIO, I. B. CALDARON, G. MAGARA, A. J. M. DORR, I. BIASATO, L. GASCO (2018): Influence of *Hermetia illucens* meal dietary inclusion on the histological traits, gut mucin composition and the oxidative stress biomarkers in rainbow trout (*Oncorhynchus mykiss*). Aquaculture 496, 50-57. https://doi.org/10.1016/j.aquaculture.2018.07.009

ERGOZ, B., A. R. OĞUZ (2023): Histomorphological Study on Digestive Tract of Van Fish (*Alburnus tarichi* (Güldenstädt, 1814). JIST 13, 2403-2414. (in Turkish) https://doi.org/10.21597/jist.1297242

GENTEN, F., E. TERWINGHE, A DANGUY (2009): Atlas of Fish Histology. 1st ed., Science Publishers, Endfild, NH, USA, pp. 75-92.

GRAU, A., S. CRESPO, M. C. SARASQUETE, M. L. GONZALES (1992): The digestive tract of the amberjack *Seriola dumerii*, Risso: a light and scanning electron microscope study. J. Fish. Biol. 41, 287-303. https://doi.org/10.1111/j.1095-8649.1992.tb02658.x

JOHANSSON, M. E. V., D. AMBORT, T. PELASEYED, A. SCHUTTE, J. K. GUSTAFSSON, A. ERMUND, G. C. HANSSON (2011): Composition and functional role of the mucus layers in the intestine. Cell. Mol. Life. Sci. 68, 3635-3641. https://doi.org/10.1007/s00018-011-0822-3

KAVAL OĞUZ, E., B. ERGOZ, A. R. OĞUZ (2021): Histopathological alterations in Van fish (*Alburnus tarichi* Güldenstädt, 1814) exposed to tebuconazole. Chem. Ecol. 38, 17-26. https://doi:10.1080/02757540.2021.2017902

KIM, Y. K., H. IDEUCHI, S. WATANABE, S. I. PARK, M. HUH, T. KANEKO (2008): Rectal water absorption in seawater-adapted Japanese eel *Anguilla japonica*. Comp.

Biochem. Physiol. A. Mol. Integr. Physiol. 151, 533-541. https://doi.org/10.1016/j.cbpa.2008.07.016

LAI, S. K., Y. Y. WANG, D. WIRTZ, J. HANES (2009): Micro- and macrorheology of mucus. Adv. Drug. Deliv. Rev. 61, 86-100. https://doi.org/10.1016/j.addr.2008.09.012

LORETZ, C. A (1995): Electrophysiology of ion transport in teleost intestinal cells. Fish. Physiol. 14, 25-56. https://doi.org/10.1016/S1546-5098(08)60241-1

LUZZANA, U., F. VALFRÈ, M. MANGIAROTTI, C. DOMENEGHINI, G. RADAELLI, V. M. MORETTI, M. SCOLARI (2005): Evaluation of different protein sources in fingerling grey mullet *Mugil cephalus* practical diets. Aquac. Int. 13, 291-303. https://doi.org/10.1007/s10499-004-3099-9

MORRISON, C. M., J. R. WRIGHT (1999): A study of the histology of the digestive tract of the Nile tilapia. J. Fish. Biol. 54, 597-606. https://doi.org/10.1111/j.1095-8649.1999.tb00638.x

OĞUZ, A. R., E. K. OĞUZ (2020): Histopathology and immunohistochemistry of gills of Van fish (*Alburnus tarichi* Güldenstädt, 1814) infected with myxosporean parasites. J. Histotechnol. 43, 76-82.

OĞUZ, A. R (2015): Histological changes in the gill epithelium of endemic Lake Van Fish (*Chalcalburnus tarichi*) during migration from alkaline water to freshwater. North. West. J. Zool. 11, 51-57.

OĞUZ, A. R (2013): Environmental regulation of mitochondria-rich cells in *Chalcalburnus tarichi* (Pallas, 1811) during reproductive migration. J. Membr. Biol. 246, 183-188. https://doi.org/10.1007/s00232-012-9518-3

OLSSON, C., S. HOLMGREN (2011): The gut. In: Encyclopedia of fish physiology: from genome to environment. (Farrel, A. P. Ed.) Academic Press, San Diego, pp. 1229-1348.

ORTIZ-DELGADO, J. B., J. IGLESIAS, F. J. SÁNCHEZ, R. CAL, M. J. LAGO, J. J. OTERO, C SARASQUETE (2012): A morphohistological and histochemical study of hatchery-reared European hake, *Merluccius merluccius* (Linnaeus, 1758), during the lecitho-exotrophic larval phase. Sci. Mar. 76, 259-271. https://doi.org/10.3989/scimar.03424.03C

OSTASZEWSKA, T., K. MACIEJ (2019): Digestive System. In: The Histology of Fishes. (Formicki, K., F. Kirschbaum, Eds.) 1st ed., CRC Press, Boca Raton, FL, pp. 88-107. https://doi.org/10.1201/9780429113581

PARK, J. Y., I. S. KIM (2001): Histology and mucin histochemistry of the gastrointestinal tract of the mud loach, in relation to respiation. J. Fish. Biol. 58, 861-872. https://doi.org/10.1111/j.1095-8649.2001.tb00536.x

PETRINEC, Z., S. NEJEDLI, S. KUZIR, A. OPACAK (2005): Mucosubstances of the digestive tract mucosa in northern pike (*Esox lucius* L.) and european catfish (*Silurus glanis* L.). Vet. arhiv 75, 317-327.

POWELL, M. D., H. J. PARSONS, B. F. NOWAK (2001): Physiological effects of freshwater bathing of Atlantic salmon (*Salmo salar*) as a treatment for amoebic gill disease. Aquac. 199, 259-266. https://doi.org/10.1016/S0044-8486(01)00573-7

POWELL, M. D., D. J. SPEARE, G. M. WRIGHT (1994): Comparative ultrastructural morphology of lamellar epithelial, chloride and mucous cell glycocalyx of the rainbow trout (*Oncorhynchus mykiss*) gill. J. Fish. Biol. 44, 725-730. https://doi.org/10.1111/j.1095-8649.1994.tb01248.x

ROBERTS, S. D., M. D. POWELL (2003): Comparative ionic flux and gill mucous cell histochemistry: effects of salinity and disease status in Atlantic salmon (*Salmo salar* L.). Comp. Biochem. Physiol. A. Mol. Integr. Physiol. 134, 525-537. https://doi.org/ 10.1016/s1095-6433(02)00327-6

SADAUSKAS-HENRIQUE, H., C. M. WOOD, L. R. SOUZA-BASTOS, R. M. DUARTE, D. S. SMITH, A. L. VAL (2019): Does dissolved organic carbon from Amazon black water (Brazil) help a native species, the tambaqui *Colossoma macropomum* to maintain ionic homeostasis in acidic water? J. Fish. Biol. 94, 595-605. https://doi.org/ 10.1111/jfb.13943

SANDEN, M., M. H. G. BERNTSSEN, Å. KROGDAHL, G. I. HEMRE, A. M. BAKKE-MCKELLEP (2005): An examination of the intestinal tract of Atlantic salmon, *Salmo salar* L., parr fed different varieties of soy and maize. J. Fish. Dis. 28, 317-330. https://doi.org/ 10.1111/j.1365-2761.2005.00618.x

SARASQUETE, C., E. GISBERT, L. RIBEIRO, L. VIEIRA, M. T. DINIS (2001): Glyconjugates in epidermal, branchial and digestive mucous cells and gastric glands of gilthead sea bream, *Sparus aurata*, Senegal sole, *Solea senegalensis* and Siberian sturgeon, *Acipenser baeri* development. Eur. J. Histochem. 45, 267-78. https://doi.org/10.4081/1637

SHEPHARD, K. L (1994): Function for fish mucus. Rev. Fish Biol. Fish. 4, 401-429. https://doi.org/10.1007/BF00042888

SHI, G., J. X. WANG, X. Z. LIU, R. X. WANG (2007): Study on the histology and histochemistry of the digestive tract of *Sebastiscus marmoratus*. J. Fish. China 31, 293-302.

TAKASHIMA, F., T. HIBIYA (1995): An atlas of fish histology normal and pathological features. 2nd ed., Lubrecht and Cramer Ltd., Tokyo, Stuttgart, New York, pp. 88-106.

TIBBETTS, I. R (2005): The distribution and function of mucous cells and their secretions in the alimentary tract of *Arrhamphus sclerolepis krefftii*. J. Fish. Biol. 50, 809-820. https://doi.org/10.1111/j.1095-8649.1997.tb01974.x

VIDAL, M. R., T. F. R. RUIZ, D. D. DOS SANTOS, M. V. B. GARDINAL, F. L. DE JESUS, C. K. FACCIOLI, I. B. F. VICENTINI, C. A. VICENTINI (2020): Morphological and histochemical characterisation of the mucosa of the digestive tract in matrinxã *Brycon amazonicus* (Teleostei: Characiformes). J. Fish. Biol. 96, 251-260. https://doi.org/ 10.1111/jfb.14217

YEŞILBAŞ, A., A. R. OĞUZ (2022): Investigation of some hormones affecting osmoregulation of Lake Van fish (*Alburnus tarichi*) during reproductive migration. Aquac. Res. 53, 1011-1018. https://doi.org/10.1111/are.15642

Received: 16 May 2024
Accepted: 22 August 2024
Online publication: 28 February 2025

AZIZOĞLU, B. E., Z. ALKAN, A. N. ERDEMIR, E. ÖRGI, E. K. OĞUZ, A. R. OĞUZ: Istraživanje promjena vrčastih stanica probavnog sustava ribe Van tijekom migracije u vrijeme mriještenja. Vet. arhiv 95, 351-363, 2025.

SAŽETAK

Jezero Van među najvećim je slanim alkalnim jezerima na svijetu. U jezeru obitava i riba Van, endemska vrsta iz porodice šarana. Kako bi se razmnožavale, jedinke ove vrste migriraju u jatima u potoke koji se ulijevaju u jezero između travnja i srpnja, ovisno o temperaturi vode. Nakon što polože svoja jajašca u vodu, vraćaju se u jezero Van. U istraživanju su vrčaste stanice iz probavnog sustava ribe Van za vrijeme migracije periodično označivane bojilima Schiff, Alcian Blue (pH 2,5), Alcian Blue (pH 1,0), Alcian Blue (pH 0,5), i bojilom aldehid-fuksin. U različitim dijelovima probavnog sustava utvrđene su promjene u lokalizaciji i gustoći vrčastih stanica, koje su sadržavale neutralni, kiseli, O-sulfatni ester, izrazito sulfatni i kiseli sulfatni glikokonjugat. U jednjaku su vrčaste stanice uočene samo u ribi iz jezera Van. Iako su veličina i gustoća vrčastih stanica varirale u drugim dijelovima probavnog sustava, označeni su svi glikokonjugati. U probavnom sustavu ribe iz jezera, područja vrčastih stanica bila su velika, ali je njihova gustoća bila mala, dok je situacija s probavnim sustavom ribe iz potoka bila obrnuta. Zaključeno je da su glavni razlog promjena kod vrčastih stanica u probavnom sustavu ribe Van hranidbene navike i uvjeti staništa.

Ključne riječi: vrčaste stanice; probavni sustav; riba Van; jezero Van