

Incidence of listeriosis in farm chinchillas (*Chinchilla laniger*) in Croatia

Ruža Sabočanec^{1*}, Križan Čuljak¹, Kristijan Ramadan¹,
Tomo Naglič², Branka Šeol² and Dražen Matičić³

¹Department of General Pathology and Pathological Morphology, Faculty of Veterinary Medicine, University of Zagreb, Zagreb, Croatia

²Department of Microbiology and Infectious Diseases, Faculty of Veterinary Medicine, University of Zagreb, Zagreb, Croatia

³Clinic for Surgery, Orthopaedics and Ophthalmology, Faculty of Veterinary Medicine, University of Zagreb, Zagreb, Croatia

SABOČANEC R., K. ČULJAK, K. RAMADAN, T. NAGLIĆ, B. ŠEOL, D. MATIČIĆ:
Incidence of listeriosis in farm chinchillas (*Chinchilla laniger*) in Croatia. Vet.
arhiv 70, 159-167, 2000.

ABSTRACT

Listeriosis is an infectious disease of domestic and wild animals caused by *Listeria monocytogenes*, and is transferable to humans. There are two clinical forms of listeriosis: septicemic and encephalitic. This paper deals with two cases of listeriosis in chinchillas (*Chinchilla laniger*), originating from a farm in the County of Međimurje in Croatia, and were pathomorphologically and bacteriologically examined. This particular breed consisted of 64 chinchillas, 34 of which have died due to same symptoms. History reveals that animals had suffered loss of appetite, and abortion occurred about 5 days before death. Gross lesions included general anaemia and cachexia. Whitish-grey nodules the size of millet grain or a little larger were noticed along the capsule of liver, serosa of colon and in mesenteric lymph nodes. Numerous variably-sized granulomas in liver, intestines, lymph nodes and kidneys, with no special pattern, were observed histopathologically. They consisted of necrotic cells with somewhat more granulocytes in the centre and scattered individual giantocytes. Bacteriological examination of liver specimens revealed *Listeria monocytogenes* in a pure culture in both cases. This is the first description of listeriosis in chinchillas in Croatia.

Key words: listeriosis, *Chinchilla laniger*, encephalitic form, septicemic form, Croatia

* Contact address:

Prof. Dr. Ruža Sabočanec, Department of General Pathology and Pathological Morphology, Faculty of Veterinary Medicine, University of Zagreb, Heinzelova 55, 10000 Zagreb, Croatia; Phone: 385 1 23 90 311; Fax: 385 1 244 13 90

Introduction

Listeriosis in chinchillas was described for the first time in the late 1940s (MAC KAY et al., 1949).

Listeriosis is among the most frequent diseases of chinchillas, since this species of animals is more susceptible to *Listeria monocytogenes*, when compared to other species (FINLEY and LONG, 1977). The same authors discovered that the disease occurred after feeding chinchillas with a new delivery of feed. The animals manifested depression and loss of appetite. Several suffered from diarrhoea and the remainder constipation. In some, prolapsus of the rectum was observed.

About 14 cases of listeriosis in chinchillas have been reported in Washington and 14 cases in Virginia (SHALKOP, 1950). Clinically, diarrhoea and torticollis were observed, although some animals manifested no clinical symptoms prior to death. Pathoanatomically grey-whitish, pinhead-like foci were found in the liver in two cases. In all cases a slight enlargement of liver was observed, and in two cases haemorrhagic enteritis was also present. Three cases of listeriosis in chinchillas were described on farms in the region of Washington (LEADER and HOLTE, 1955). The diagnosis was established by examination of 30 chinchilla carcasses delivered for the analysis. Encephalitic and septicemic forms of listeriosis in chinchillas were also described (BOWDEN, 1959).

The epizooty of listeriosis in individual breeding with no clinical signs until death has been reported, although macroscopic findings showed multiple signs of necrosis all over the liver (PRIDHAM, 1966).

Isolation of *Listeria monocytogenes* at the National Veterinary Institute in Stockholm indicated the prevalence of the disease in some animals over a period of 14 years (NILSSON and SODERLING, 1974). The largest number (49 cases) was isolated in poultry, 47 cases in chinchillas, 34 cases in sheep and 31 cases in rabbits.

Histological and immunological investigations in sheep, cattle, goats, horses, pigs and one chinchilla were carried out on a total of 119 animals (PEIXOTO, 1986). 111 of them manifested signs of cerebral listeriosis, 3 abortive and 5 septicemic listeriosis. *Listeria monocytogenes* was directly isolated in 28 cases out of 112 isolates by bacteriological analysis, and after cold enrichment in 40 cases. In 68 bacteriologically positive cases, antigen of *Listeria monocytogenes* was demonstrated in 58 cases.

The favourable effect of some antibiotics to *Listeria monocytogenes*, serotype 4 was also described (FUROWITZ, 1989).

The incidence of listeriosis in northern and eastern Hungary was evaluated, as well as a description of the serotypes (HAJTOS and RALOVICH, 1994).

Data on *Salmonella enteritidis* and *Listeria* infections as being the main causes of mortality of chinchillas in Slovakia was reported (NOVAK, 1994).

Listeriosis in different species of domestic animals and chinchillas in Spain was reported (VAZQUEZ-BOLAND et al., 1996). The authors mostly described cases of encephalitic syndromes in *Listeria monocytogenes* infections.

In the breeding of 130 chinchillas, a mortality rate of 23% due to listeriosis was established (WILKERSON et al., 1997). The causative agent was isolated from different tissues, including the brain. Carcasses were cachectic, with whitish-grey foci on liver and necrotic foci in intestines, lymph nodes and lungs. The authors estimated that the infection had occurred through rodent-contaminated feed. The problem was solved after six months by thorough cleaning and disinfection of cages, a special method of watering and washing sand, removal of sick animals, change of feed and elimination of the carriers.

Materials and methods

At the end of 1999 a breeder in the County of Medimurje (northern Croatia) delivered two deceased chinchillas (*Chinchilla laniger*), which had aborted before death. The holder had 64 females, of which 34 died. As a rule, the female aborted and then, after three to five days, died. Except for loss of appetite, the owner noticed no other clinical sign of the disease. The animals were fed with pelletised feed and raisins and kept in accordance with the recommendations of the organizer of the production in the town of Čakovec, Croatia. Dissection of both animals was carried out at our Institute and the material was taken for pathohistological and bacteriological analysis. The material for pathohistological analysis was prepared by standard methods and stained by haematoxylin and eosin (H&E) stain. The material from lesions in liver of dissected chinchillas was inoculated on Columbia agar enriched with ovine blood and incubated aerobically at 37 °C for 48 hours. The isolated strain was identified by using conventional methods (BISPING and AMTSBERG, 1988; QUIN et al., 1994; HOLT et al., 1994).

Results

Gross lesions

Pathoanatomically cachexia and general anaemia was noticed. In the abdomen, whitish-grey nodules the size of millet grain or a little larger were noticed along the capsule of liver, serosa of colon and in mesenterial lymph nodes. Spleen was within its normal limits, or a just a little enlarged. The mucous membrane of stomach and intestines was inflamed and covered with a lot of mucus. In the mucous membrane of stomach, disseminated surface damage-erosions were observed.

The lungs were congested, while the heart was of normal size but with markedly degenerated myocardium.

Histopathological lesions

By histopathological analysis in liver, mostly centrolobularly hydropic vacuolar degeneration of hepatic cells was noticed (Fig. 1), together with centrolobular fatty degeneration (Fig. 2). Intralobularly, numerous smaller or larger granulomas with no special pattern were observed. These appeared to be built from transparent cells with somewhat more granulocytes in the centre and with scattered individual gigantocytes (Fig.

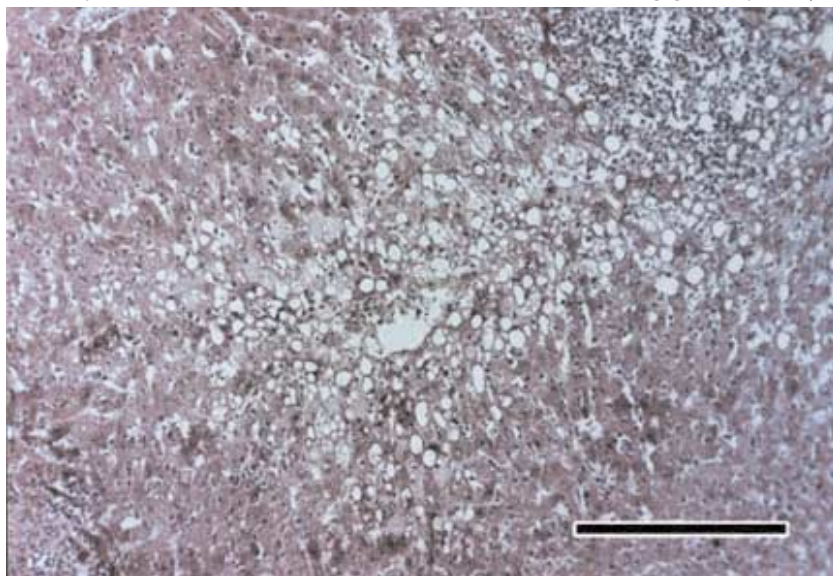


Fig. 1. Centrolobular hydropic vacuolar degeneration in the liver of chinchilla. HE; 20×2.5; scale bar=140 μ m

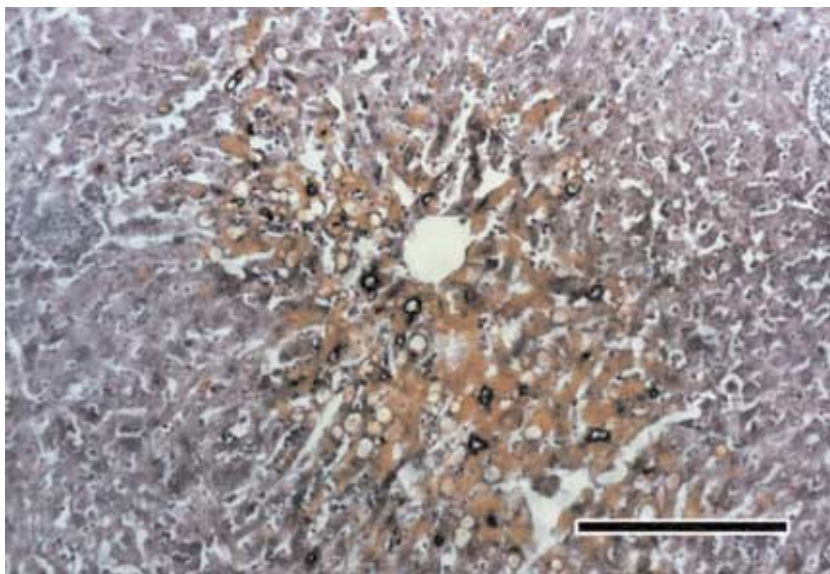


Fig. 2. Fatty degeneration in the liver of chinchilla.
Sudan III; 20×2.5; scale bar=140 μ m

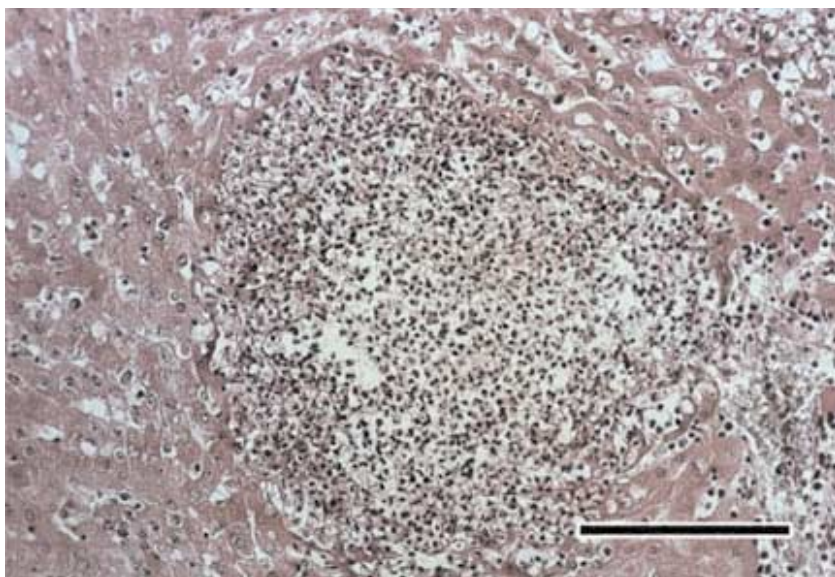


Fig. 3. Intralobular large granuloma with granulocytes in the liver
of chinchilla. HE; 20×2.5; scale bar=140 μ m

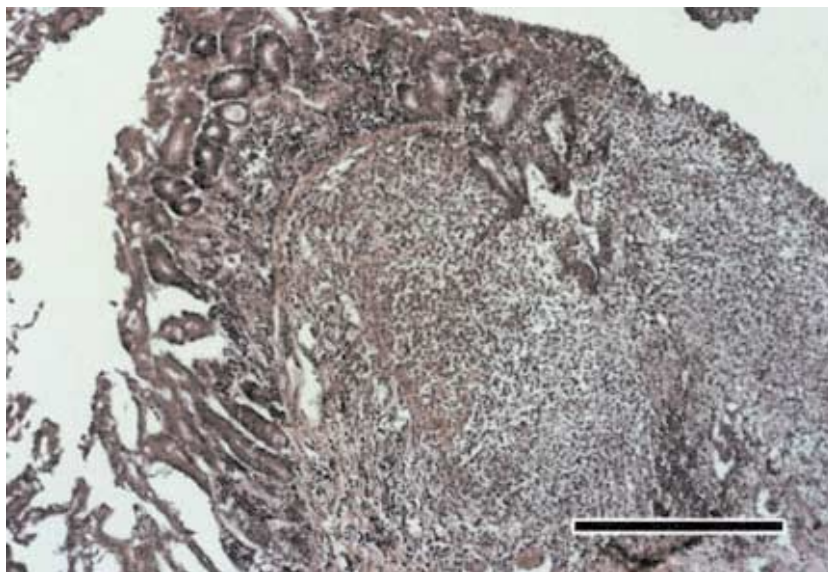


Fig. 4. Lymphoid proliferation with necrotic granuloma in the intestine of chinchilla. HE; 20×2.5; scale bar=140 μ m

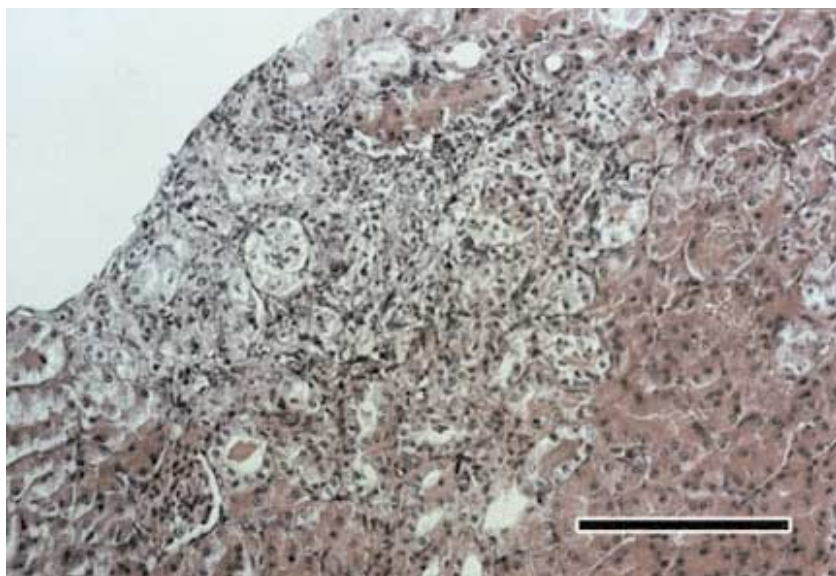


Fig. 5. Cortical part of kidneys, with initial formation of granuloma and tubular nephrosis. HE; 20×2.5; scale bar=140 μ m

3). In a small number of granulomas, signs of typical coagulative necrosis were noticed. Hepatic cells were rather spaced (dissociation) and with hyperaemia focally well pronounced. In the intestines, especially in the colon, a marked lymphoid proliferation with necrotic granulomas was observed submucously (Fig. 4). Lymphoid proliferation was noticed subserosely, as well as at the insertion of mesenterium, sometimes in smaller accumulations. In the cortical part of kidneys, circumscribed necrotic areas with sparse granulocytes could be observed, together with tubular nephrosis, giving the impression of initial formation of granulomas (Fig. 5).

Microbiological isolation

After an incubation period of 48 hrs on aerobically incubated media, small transparent colonies were grown abundantly and in pure culture. The colonies had smooth borders, were greyish-white, about 1.3 mm in diameter and surrounded by a narrow zone of beta-haemolysis. Gram-positive coccobacilli and short rods, occasionally in palisades, were found microscopically in stained culture smears. Bacterial cells of similar morphology were also seen in the stained tissue smears. In hanging-drop preparations made from subcultures incubated at room temperature, characteristic tumbling and rotary movements were observed. The isolated strain was catalase-positive, oxidase-negative, hydrolysed aesculin, and did not grow on MacConkey agar. It produced acid but not gas from glucose and L-rhamnose, although not from mannitol and d-xylose. CAMP-test with *Staphylococcus aureus* was positive. According to determined properties the isolated strain was identified as *Listeria monocytogenes*.

Discussion

From the examinations carried out, it was established that the delivered chinchillas were infected and died from a septicemic form of listeriosis. This was, however, the first case of listeriosis of chinchillas in Croatia. Gross lesions established in the intestines and liver were in accordance with the findings established elsewhere (PRIDHAM et al., 1966). Those findings corresponded also with the fact that the mentioned authors established epizooty in individual cases of breeding and deaths with no clinical signs of the disease, in just the same way as we did in our case. That is to say, according to historical data, the animals were losing weight due to complete loss of appetite; they aborted and died within 3-5 days. Gravidity obviously led to a lowering in general resistance of the organism, i.e. gravidity was the predisposing factor that led to the lowering of resistance of the organism and played a significant role in the

occurrence of infection. In our case the animals were also losing weight and in liver, intestines and mesenterial lymph nodes whitish-grey nodules were observed. Hence, the same symptoms as in the studies conducted elsewhere, when 23% of animals died of listeriosis (WILKERSON et al., 1997). Similarly to the mentioned authors, we also think that the infection occurred due to contaminated feed, most probably having been contaminated by rats or other rodents. Namely, the feed was pelletised by a known manufacturer and controlled by the organizer of the production from Čakovec, Croatia, so it could be assumed that the problem resulted from contamination while feed was in storage. According to some authors (SHALKOP, 1950; PRIDHAM et al., 1996), and also in our case, the disease occurred because no clear clinical symptoms were made known to all breeders, and also because the wider professional public was unaware that that special attention should be paid to bacterial infections, since listeriosis is an insidious disease and a dangerous zoonosis.

References

- BISPING, W., G. AMTSBERG (1988): Colour atlas for the diagnosis of bacterial pathogens in animal. Paul Parey Scientific Publisher. Berlin and Hamburg.
- BOWDEN, R. S. T. (1959): Disease of chinchillas. Vet. Rec. 71, 1033-1039.
- FINLEY, G. G., J. R. LONG (1977): An epizootic of listeriosis in chinchillas. Can. Vet. J. 6, 164-167.
- FUROWICZ, A. J., D. BRODA, P. LOCZEWSKI, D. CZERNOMYSY-FUROWICZ (1989): Therapeutic value of immunostimulation with *Propionibacterium acnes* in treatment of listeriosis in chinchilla. Medycyna-Wet. 5, 289-291.
- HAJTOS, I., B. RALOVICH (1994): New data on the occurrence and epidemiology of the listeriosis in Hungary. Magyar Allatorvosok Lapja 7, 443.
- HOLT, J. G., N. R. KRIEG, P. H. A. SNEATH, J. T. STALEY, S. T. WILLIAMS (1994): Bergey's Manual of Determinative Bacteriology. Williams and Wilkins. Baltimore.
- LEADER, R. W., R. J. A. HOLTE (1955): Studies on three outbreaks of listeriosis in chinchillas. Cornell. Vet. 45:78-84.
- MAC KAY, K. A., A. H. KENNEDY, D. L. T. SMITH, A. F. BAIN (1949): *Listeria monocytogenes* infection in chinchillas. Annual Report Ontario Veterinary College. pp. 137-145.
- NILSSON, O., O. SODERLIND (1974): *Listeria monocytogenes* isolated from animals in Sweden from 1958 to 1972. Nordisk-Vet. 3-4, 248-255.
- NOVAK, S., D. RUTTKAY, I. SOLAR (1994): Results of screening for bacterial diseases on large scale chinchilla (*Chinchilla laniger*) farms. Slovensky Vet. časopis 1, 19-21.
- PEIXOTO, P. F. (1986): Comparative histopathological and immunohistological studies for diagnosis of spontaneous listeriosis in animals. Retrospective study with peroxidase-antiperoxidase (PAP) technique on formalin preserved paraffin sections. Thesis. 109 pp.; 26 pp. Fachbereich Veterinärmedizin Justus-Libig-Universität Giessen, Germany.
- PRIDHAM, T. J., J. BUDD, L. H. A. KARSTAD (1966): Common diseases of fur bearing animals: II. Diseases of chinchillas, nutria and rabbits. Can. Vet. J. 4, 84-87.
- QUINN, P. J., M. E. CARTER, B. MARKEY, G. R. CARTER (1994): Clinical Veterinary Microbiology. Wolfe Publishing. London.
- SHALKOP, W. T. (1950): *Listeria monocytogenes* in chinchillas. J. A. V. M. A. 116, 447-448.

- VAZQUEZ-BOLAND, J. A., J. A. GAMALLO, M. T. RIPIO, G. DOMINGUEZ BERNAL, M. LARA, Y. VEGA, R. C. MAINAR, M. SUAREZ (1996): Listeriosis in domestic animals: a short review of epidemiology, diagnosis and public health implications and description of prevalence in Spain. *Med. Vet.* 6, 333-344.
- WILKERSON, M. J., A. MELENDY, E. STAUBER (1997): An outbreak of listeriosis in a breeding colony of chinchillas. *J. Vet. Diag. Invest.* 3, 320-323.

Received: 20 April 2000

Accepted: 10 May 2000

SABOČANEC, R., K. ČULJAK, K. RAMADAN, T. NAGLIĆ, B. ŠEOL, D. MATIČIĆ: Pojava listerioze u uzgoju činčila (*Chinchilla laniger*) u Hrvatskoj. *Vet. arhiv* 70, 159-167, 2000.

SAŽETAK

Listerioza je zarazna bolest domaćih i divljih životinja uzrokovana bakterijom *Listeria monocytogenes*, a može se prenijeti i na čovjeka. Klinički se manifestira u dva oblika: kao septikemija ili kao encefalitis. Rad opisuje dva slučaja listerioze u činčila (*Chinchilla laniger*), s jedne farme iz Međimurja u Hrvatskoj, koji su patomorfološki i bakteriološki obrađeni. U uzgoju su uginule 34 od 64 životinje s istim simptomima. Prema anamnestičkim podacima životinje su izgubile apetit i pobacile oko 5 dana prije uginuća. Makroskopski je bila vidljiva opća anemija i izrazita mršavost životinja. Sivo bijeli čvorići veličine zrna prosa ili nešto veći rasprostirali su se po jetri, serozi kolona i mezenterijalnim limfnim čvorovima. Histopatološkom pretragom jetre, crijeva, limfnih čvorova i bubrega nađeni su brojni granulomi, različite veličine i rasporeda. Sastojali su se od nekrotičnih stanica s nešto više granulocita u centru i razbacanim pojedinačnim gigantocitima. Bakteriološkom pretragom jetre obje činčile izolirana je *Listeria monocytogenes* u čistoj kulturi. Ovo je prvi opisani slučaj pojave listerioze u činčila u Hrvatskoj.

Cljučne riječi: listerioza, činčila, *Chinchilla laniger*, encefalitični oblik, septikemijski oblik, Hrvatska
