

Staphyloma caused by untreated cat scratch in Pekingese dog - a case report

**Boris Pirkić*, Marko Stejskal, Hrvoje Borošak, Dražen Matičić,
and Tomislav Babić**

*Clinic for Surgery, Orthopaedics and Ophthalmology, Faculty of Veterinary Medicine, University of Zagreb,
Croatia*

**PIRKIĆ, B., M. STEJSKAL, H. BOROŠAK, D. MATIČIĆ, T. BABIĆ: Staphyloma
caused by untreated cat scratch in Pekingese dog. Vet. arhiv 77, 469-474, 2007.**

ABSTRACT

The subject of this report is an interesting case of a state, developed from a seemingly innocuous injury. A number of unfavourable factors, combined and what seemed a mere scratch, developed over a short time into an eye threatening condition, i.e. staphyloma. The dog underwent operating procedure suitable for such a diagnosis: resection of part of outer ocular layer, which is described in detail further in the text.

Key words: staphyloma, cat scratch, eye surgery

Introduction

Scleral trauma may result in staphyloma, a localized ectatic area of sclera, or cornea, to which a portion of uveal tract adheres (SLATTER, 2001). However, there are no reports that show a connection between an untreated scleral surface injury, and the development of staphyloma.

The subject of this report is a Pekingese dog injured by a cat which scratched the sclera near the corneal limbal margin. The owner went to a local veterinarian who put the dog on a standard procedure for corneal and scleral superficial wounds (Chloramphenicol ointment three times daily, locally; Tropicamide drops once daily, locally), and concluded that the wound should heal within a week. After one week, the veterinarian found the wound satisfyingly healed, and ended the therapy with no need for further control visits. Two weeks later, the owner began to observe changes on the site of supposedly healed injury.

*Contact address:

Dr. sc. Boris Pirkić, Clinic for Surgery, Orthopaedics and Ophthalmology, Faculty of Veterinary Medicine, University of Zagreb, Heinzelova 55, 10000 Zagreb, Croatia, Phone: +385 1 2390 111, Fax: +385 1 2390 280, E-mail: bpirkic@vef.hr

Materials and methods

A three-year-old Pekingese dog was referred to the Surgery Clinic of the Faculty of Veterinary Medicine, University of Zagreb, with signs of a large scleral swelling near the limbal margin (Fig. 1).

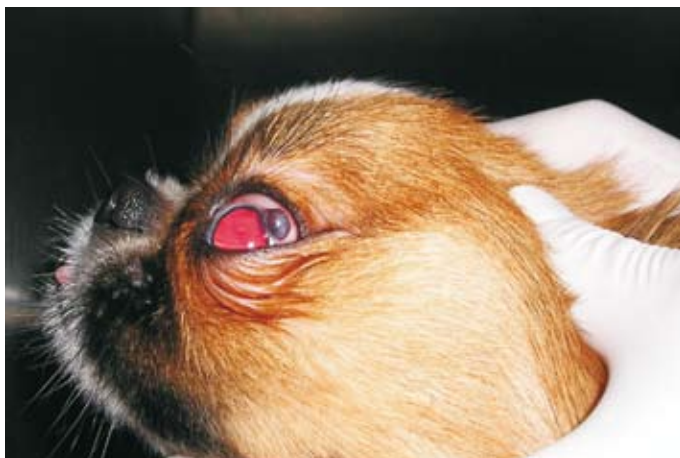

Fig. 1. The dog prior to operation, as it was at the time of reception

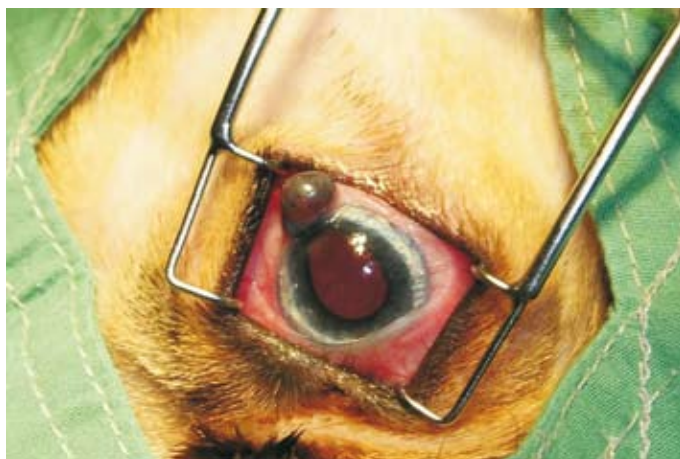


Fig. 2. Operating field prepared for resection of fibrous tunic

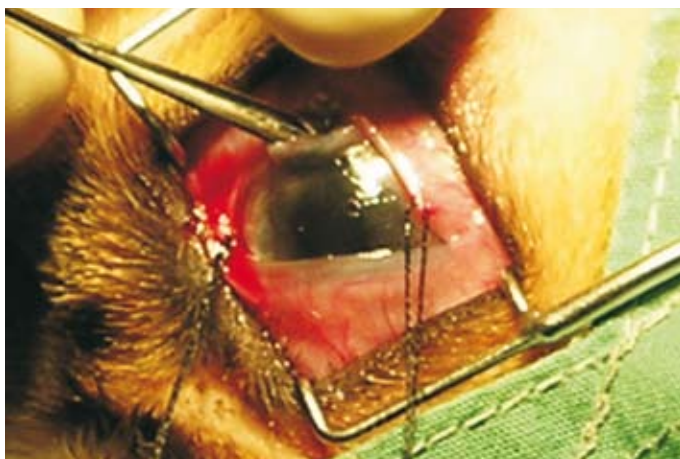


Fig. 3. Preplaced positional sutures for better manipulation with the eye. Also, a successful attempt to reposition the staphyloma contents below the outer layer surface is seen.

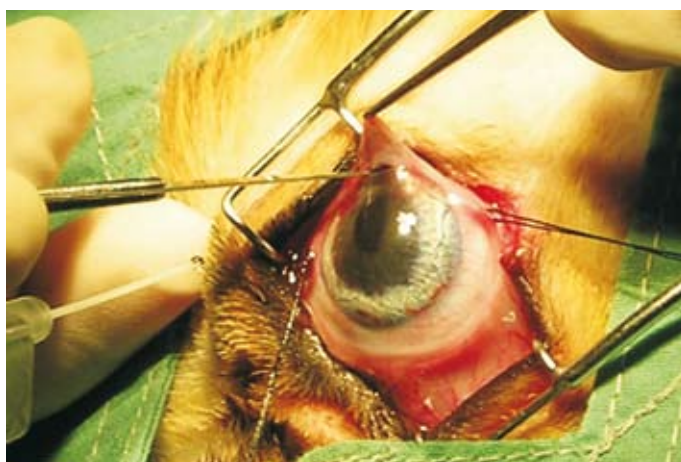


Fig. 4. Resection of fibrous tunic with blade number 11

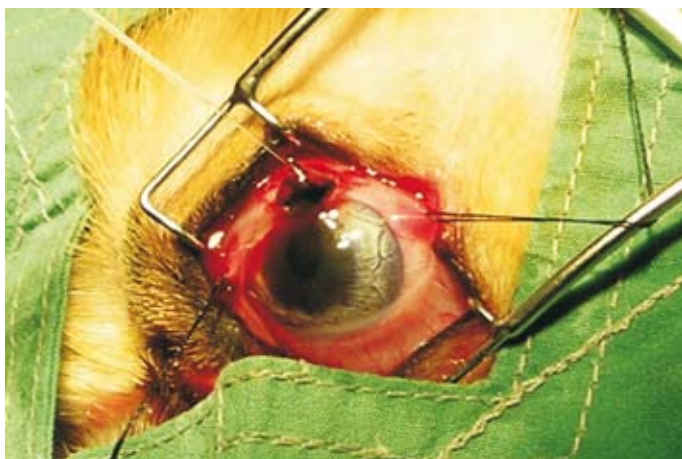

Fig. 5. Irrigation of operating field with saline

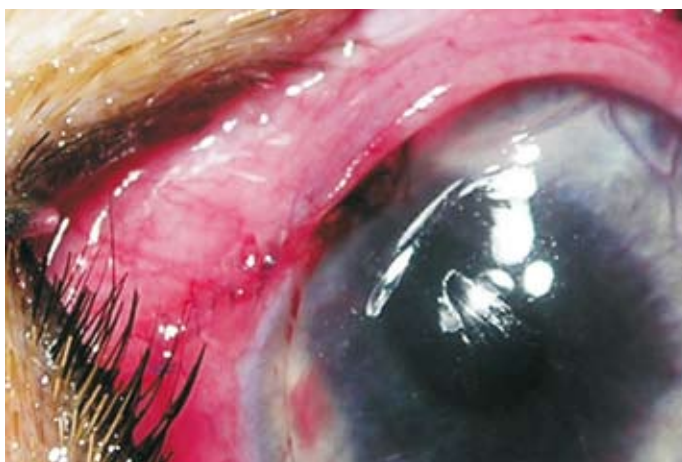

Fig. 6. The fibrous tunic defect was reconstructed and conjunctival flap was placed over it to prevent the irritation of lids with suture endings. This represents the final stage of the procedure.

The swelling had continuously grown during the preceding four weeks up to the existing size of approx. 5 mm wide with an irregular circular shape. During the ambulatory examination, using transillumination, a part of the iris was seen adhered within a swelling. Staphyloma was therefore an obvious diagnosis, and surgical therapy recommended for such a condition (GELLAT, 1999) was performed.

After routine preoperative tests were carried out (haematology, EKG), everything was found to be within normal limits. The dog was anesthetized using isoflurane (1.5%) in an oxygen flow of 1 L/min. intrapulmonary. The operation field was prepared (Fig. 2), and the swelling was tested for repositioning, which was possible (Fig. 3).

Tissue was dissected to the level of surrounding sclera and cornea (Fig. 4) and checked for possible iridal adhesions. The site of procedure was then irrigated with saline

Closure was done using continuous suture with 8-0 polyglactin 910, and spatulated needle, as recommended for lamellar tissues (BURATTO and IORI, 1996). After closing the scleral wound, a conjunctival flap was performed over the sutures to additionally secure the reconstructed tissue (Fig. 6).

Results and discussion

Initial clinical signs were noticed by the owner one month before referring to our clinic. Mild swelling at the site of the cat scratch continuously grew to a size of 5 mm in diameter within four weeks. It is important to bear in mind that the wound was completely healed on the scleral surface at first, before any signs of scleral tissue weakness was noticed. Therefore, the veterinarian who treated the dog prior to my clinic, had no obvious reasons for continuing the control visits. Prognosis was favourable, because the scratch was on the scleral surface, so no visual deficits were expected, and the literature widely mentions no further problems with regard to such cases.

However, this case proves that one can never be too sure regarding the outcome of such patients, where the tissues involved are as sensitive as ocular. Furthermore, we must not forget the continuous tension applied on ocular structures originating from intraocular pressure. Thinning of the scleral wall caused by the scratch was sufficient to produce a swelling that grew continuously, and the bigger the swelling became, the thinner and weaker was the scleral wall. Finally, we observed that a sort of circulus vitiosus had developed, which would eventually culminate in scleral rupture and consequent eye loss.

It can be summarized that the follow-up therapy regarding patients with ocular trauma must not cease at the first sign of healing, whether or not it is completed. The possibility of further complications is great, especially when bearing in mind the long healing processes and low vascularization of tunica fibrosa, which extends up to one year

after surgery (BURATTO and IORI, 1996). Owners must be informed about these facts, and contact maintained in case such complications should occur.

References

- BURATTO, L., M. IORI (1996): Incisions and sutures in cataract surgery, Fogliazza Editore.
- GELATT, K. N. (1999): Diseases of canine cornea and sclera. In: Veterinary Ophthalmology, 2nd ed., (Gellat K. N., Ed.). Philadelphia. Lea & Febiger, pp. 635-674.
- SLATTER, D. (2001): Cornea and Sclera. In: Fundamentals of Veterinary Ophthalmology, (Slatter D., Ed.), W. B. Saunders, Philadelphia.

Received: 27 November 2006

Accepted: 28 September 2007

PIRKIĆ, B., M. STEJSKAL, H. BOROŠAK, D. MATIČIĆ, T. BABIĆ: Stafilom uzrokovan neliječenim mačjim ogrebom u pekinškoga psa. Vet. arhiv 77, 469-474, 2007.

SAŽETAK

Predmet ovog prikaza zanimljiv je slučaj, naoko bezazlene, ozljede oka mačjim ogrebom. U kratkom roku, zbog niza nepovoljnih okolnosti razvilo se, od isprva uobičajene ozljede, za oko opasno stanje, stafilom. Pas je podvrgnut operacijskom zahvatu resekcije dijela vanjske očne ovojnice indiciranom za takvu dijagnozu, što je iscrpno opisano u tekstu.

Ključne riječi: stafilom, mačji ogreb, kirurgija oka
