

Gastroprotective effect of the crude methanol extract of *Terminalia avicennioides* in rats

Mohammed Musa Suleiman^{1,2*}, Isife Ogonna Romanus¹, and Sadiq Yusuf³

¹Department of Veterinary Physiology and Pharmacology, Faculty of Veterinary Medicine, Ahmadu Bello University, Zaria, Nigeria

²Present address: Phytomedicine Programme, Department of Paraclinical Sciences, Private Bag X04 Onderstepoort, University of Pretoria, South Africa

³Department of Human Physiology, Faculty of Medicine, Ahmadu Bello University, Zaria, Nigeria

SULEIMAN, M. M., I. O. ROMANUS, S. YUSUF: Gastroprotective effect of the crude methanol extract of *Terminalia avicennioides* in rats. Vet. arhiv 77, 345-354, 2007.

ABSTRACT

The effect of different doses of methanol extract of *Terminalia avicennioides* (Combretaceae) on acute mucosal damage induced by 0.6 M HCl and on mucus production in the stomach of rats was studied. Animals treated with *T. avicennioides* at a dose of 350 mg/kg showed a significant ($P<0.05$) reduction of gastric lesions produced by HCl, while the reduction in gastric damage was highly significant ($P<0.01$) at doses of 500 and 900 mg/kg when all the experiments were compared with rats treated with normal saline (untreated control). Similarly, the extract of *T. avicennioides* at 350, 500 and 900 mg/kg produced a significant ($P<0.05$) increase in mucus production when compared with normal saline (untreated) and cimetidine (treated) control rats. The effect of the extract on both gastric damage and mucus production were shown to dose-dependent. This study has therefore validated the claim that the plant possesses an ulcer healing effect.

Key words: *Terminalia avicennioides*, ulcer, gastroprotection, medicinal plant

Introduction

Peptic ulcer disease is a chronic inflammatory disease characterised by ulceration in the regions of upper gastrointestinal tract where parietal cells are found and where they secrete hydrochloric acid (HCl) and pepsin. The anatomic sites where ulcer occurs commonly are stomach and duodenum, causing gastric and duodenal ulcer, respectively (RANG et al., 2003). Pathophysiology of ulcer is due to an imbalance between aggressive

*Contact address:

Dr. Mohammed Musa Suleiman, Department of Physiology and Pharmacology, Faculty of Veterinary Medicine, Ahmadu Bello University, Zaria, Kaduna State, Nigeria, Phone: +234 803 6078 363; E-mail: mohsulai@yahoo.com

factors (acid, pepsin, *H. pylori* and non-steroidal anti-inflammatory agents) and local mucosal defensive factors (mucus bicarbonate, blood flow and prostaglandins). Integrity of gastro-duodenal mucosa is maintained through a homeostatic balance between these aggressive and defensive factors (HOOGERWERF and PASRICHA, 2001). One major cause of peptic ulceration in human and in small animals (dogs and cats) is the chronic use of non-steroidal anti-inflammatory drugs (NSAIDs) in the treatment of mild to moderate pain, and also inflammatory conditions (BRUNTON, 1996). The therapeutic and adverse effects of NSAIDs have been attributed to the ability of these drugs to inhibit the action of cyclooxygenase (COX) (DAVIES and WALLACE, 1997). COX is responsible for the synthesis of prostaglandins that normally inhibit acid secretion, as well as having a protective effect on the gastric mucosa (RANG et al., 2003). Infection of the stomach mucosa with *Helicobacter pylori* - a Gram-negative spiral-shaped bacterium - is now generally considered to be a major cause of gastro-duodenal ulcer (RANG et al., 2003). Several drugs are widely used to prevent or treat gastro-duodenal ulcers; these include H₂-receptor antagonists (cimetidine), proton pump inhibitors (omeprazole) and cytoprotectives (misoprostol) (RASKIN et al., 1995). Antacids, e.g. aluminium hydroxide and magnesium hydroxide, are used often to neutralize excess gastric acidity in the stomach. Due to problems associated with recurrence after treatment, there is therefore the need to seek alternative drug sources against GI ulcers (RANG et al., 2003).

Terminalia avicennioides belongs to the family Combretaceae (KEAY et al., 1960). The powdered leaves of *T. avicennioides* are used to treat ringworm infection and other skin diseases. The dried powdered root mixed with wasted bulbs of *Crinum* spp. and made into ointment with fresh cow butter is used for the treatment of rheumatic pain and other swollen joint conditions (DALZIEL, 1955). Traditionally, the Fulanis (the major cattle rearing people in Nigeria) use a decoction from the root of *T. avicennioides* for the treatment of helminthiasis (DALZIEL, 1955; IBRAHIM et al., 1983). The bark of *T. avicennioides* was shown to be active against *Vibrio cholera*; an aqueous extract administered to cholera patients reduced the incidence of diarrhoea by 85-90% (AKINSIDE and OLUKOYO, 1995). Similarly, the leaf extract of *T. avicennioides* demonstrated significant activity against *Salmonella typhi* and *Salmonella paratyphi* infection (AKINYEMI et al., 2003). Decoction of the bark of *T. avicennioides* is used to treat gastric and peptic ulcers (S. Garba, Personal Communication). The aim of this study is to determine the protection afforded by the methanol extract of the root of *T. avicennioides* in HCl-induced gastric mucosal damage in rats.

Materials and methods

Animals. Albino rats (Wistar strains) weighing between 85-187 g were used for all experiment in this study. They were purchased from Animal House, Department of Public

Health and Preventive Medicine, Ahmadu Bello University, Zaria, Nigeria. Animals were allowed to acclimatize for 3 weeks in the laboratory. Wood shavings were used as bedding and were changed once throughout the period of the experiment. Rats were fed standard diet and tap water was provided *ad libitum*.

Preparation of plant materials. Fresh leaves, seeds and root of *T. avicennioides* were collected in the wild around Zaria. The plant was identified at the herbarium of Department of Biological Sciences, A.B.U., Zaria, by Mr. Musa Mohammed (herbarium keeper) where voucher number 402 was deposited. The root was air-dried, made into powdered form using a slab mill (Chust, and Merie Ltd, England; Serial No. 49814). Two hundred grams (200 g) of powdered root was macerated in a separating funnel using 70% methanol. Thereafter, the extract was concentrated in a water bath to a dark brown solid residue. The yield of the extract was 22% w/w.

Phytochemical screening. The extract was evaluated for the presence of flavonoids, tannins, alkaloid, saponins and sterols/triterpenes using method described by BRAIN and TURNER (1975).

Determination of maximum tolerated doses. Rats were randomly assigned into 5 groups of 3 animals each. Groups 1, 2, 3 and 4 were treated with 100, 500, 1000 and 1500 mg/kg of extracts of *T. avicennioides*, respectively. Group 5 received normal saline and served as untreated control.

Gastroprotective studies. Twenty-five rats were randomly allocated into 5 groups of 5 animals each. Prior to the experiment, animals were fasted for 24 hours but water was provided *ad libitum*. Animals in group 1 were treated with normal saline at 5 mL/kg and served as untreated control, while animals in group 2 were treated with cimetidine (15 mg/kg) and served as treated control. Groups 3, 4, and 5 were treated with 350, 500 and 900 mg/kg of the extract, respectively. All treatments were done intragastrically via stomach tube. Prior to treatment all animals were placed under anaesthesia using ketamine hydrochloride (11-22 mg/kg). Thirty minutes after pre-treatment with cimetidine, extract or normal saline, individual animals were again intubated using stomach tube, and were given 0.6 M HCl via the stomach tube (1 mL/rat). The animals were allowed to recover from anaesthesia and were sacrificed 2½ h. after treatment with HCl in a chloroform chamber. On each animal, a ventral midline incision was made and the stomach exteriorised and opened through the greater curvature, rinsed, laid out on a flat surface and examined for the presence of mucosal lesions. A 2x hand lens was used to locate and score the lesions according to the method of (OHARA et al., 1995). Severity of the gastric mucosal damage was graded as follows; grade 0, no lesion; grade 1, haemorrhagic erosion (less than 5); grade 2, haemorrhagic erosion (more than 5); grade 3, many small linear ulcers (shorter than 2 mm); grade 4, multiple linear ulcers of marked size. The ulcer index for each group

was calculated by multiplying the number of rats in each grade by the number of grade divided by the number of rats in each group.

Gastric mucus determination. Adherent gastric mucus concentration was determined by the method of CORNE et al. (1974). Briefly, the stomachs were removed, opened along the greater curvature and rinsed in saline. They were incubated for 2 h. in 20 mL of 0.1% w/v alcian blue in 0.16 M sucrose solution buffered with 0.05 M sodium acetate (pH 5.8). The excess dye was removed by rinsing twice for 15 min. and then 30 min. in 0.25 M sucrose. The mucus-bound dye was extracted by immersing the gastric tissue in 0.5 M magnesium chloride, which was intermittently shaken for 1 min. at 30-min. intervals for a 2 hr period. The blue extract was centrifuged at 5000 g for 10 min. The clear upper aqueous layer was measured spectrophotometrically at 605 nm after preparing a standard curve with highly purified pig gastric mucin. The results are expressed as $\mu\text{g}/\text{gram}$ of wet tissue (YUSUF et al., 2004).

Statistical analysis. Data were presented as means \pm standard error of mean (SEM). Differences between means were analysed by Student's *t* test using Microsoft Excel computer software. Statistical probability of 5% was used as a criterion for significance.

Results

Phytochemical screening. Phytochemical test of the extract revealed the presence of tannins, alkaloids, saponins, sterol/triterpenes and flavonoids.

Determination of maximum tolerated doses. The extract at doses of 100, 500 and 1000 mg/kg produced no apparent toxic signs or mortality. However, at 1500 mg/kg, depression and hard faeces were observed.

Effect on HCl-induced gastric damage. The result is depicted in Fig. 1. The ulcers indices in rats treated with cimetidine (15 mg/kg) and *T. avicennioides* (350 mg/kg) were found to be significantly ($P < 0.05$) lower than that of normal saline (control) treated rats. In addition, animals that received the *T. avicennioides* (TA) methanol extract at 500 and 900 mg/kg showed a significant ($P < 0.05$) lower ulcer indices than those treated with normal saline, cimetidine or TA (350 mg/kg).

Effect on gastric mucus production. The effect of *T. avicennioides* methanol extract on gastric mucus is depicted in Fig. 2. There was a significant ($P < 0.05$) decrease in the concentration of gastric mucus in rats treated with cimetidine (15 mg/kg) when compared with the normal saline treated group. Furthermore, animals treated with TA at 350, 500 and 900 mg/kg showed a significant ($P < 0.05$) increase in mucus production compared to NS (5 ml/kg) and CD (15 mg/kg) treated rats (Fig. 2).

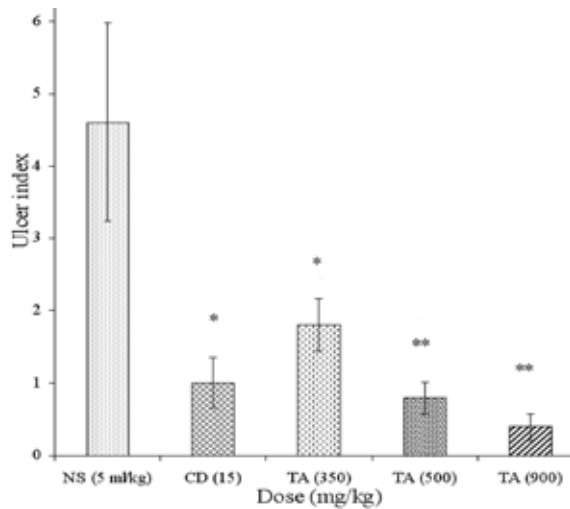


Fig. 1. The effect of *T. avicennioides* (TA) (350-850 mg/kg) and cimetidine (CD) (15 mg/kg) on HCl-induced gastric ulcers in rats. Control group was dosed with normal saline at 5 ml/kg. Values are mean \pm SEM. ** $P < 0.01$ and * $P < 0.05$ show significant difference when compared with normal saline treated control group.

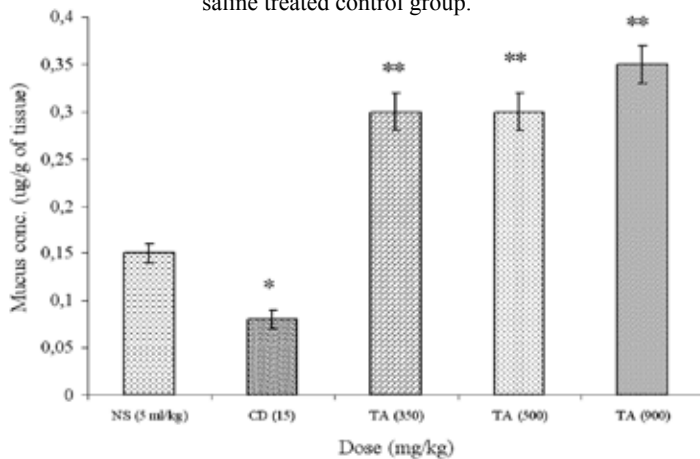


Fig. 2. The effect of *T. avicennioides* (TA) (350-850 mg/kg) and cimetidine (CD) (15 mg/kg) on gastric mucus production in rats. Control group was dosed with normal saline at 5 ml/kg. Values are mean \pm SEM. ** $P < 0.001$ and * $P < 0.05$ show significant difference when compared with normal saline treated control group.

Discussion

Ethnomedicines, such as *T. avicennioides*, are used with apparent success in West Africa, particularly among the rural people, to treat various ailments, in part because of their rich history and confidence in their use but also because orthodox medicines are expensive and beyond the reach of the majority of our communities. Traditional medical practices have employed herbal remedies worldwide for the prevention and treatment of different diseases. Scientific research and clinical trials have confirmed the efficacy of several plants for the treatment and prevention of a number of diseases. Gastroduodenal ulcers are among those diseases that are treated using herbal remedies. These were demonstrated in researches carried out by some workers (BISHAYEE and CHATTERJEE, 1994; KANNER and LAPIDOL, 2001; MEYER et al., 2002). The result of this study showed that the methanol extract of the root of *T. avicennioides* significantly ($P < 0.05$) reduced gastric damage produced by HCl in rats. The extract produced its gastroprotective effects in a dose-dependent manner.

In the present study, the methanol extract of *Terminalia avicennioides* was shown to have no apparent toxic effect at a dose of 1000 mg/kg or less. ABDULLAHI et al (2001) showed the LD_{50} of *T. avicennioides* administered by the intraperitoneal route to be 875 mg/kg. Agents administered via the oral route may be metabolised and partially or completely removed by the liver. Perhaps this explains why *T. avicennioides* at 1000 mg/kg administered orally did not produce any apparent toxic effect.

Gastric mucus is known to protect the gastric mucosa against damage by HCl produced by parietal cells. It consists of viscous, elastic, adherent and transparent gel formed by 95% water and 5% glycoproteins that cover the entire gastrointestinal mucosa. Moreover, mucus is capable of acting as an antioxidant and thus can reduce mucosal damage mediated by oxygen-free radicals (REPETTO and LLEUSY, 2002). The protective properties of the mucus barrier depend not only on gel structure but also on the amount or thickness of the layer covering the mucosal layer (PENISSI and PIEZZI, 1999). A decrease in gastric mucus renders the mucosa susceptible to injuries induced by acid, aspirin or cold restraint stress (CROSS et al., 1984). The effect of *T. avicennioides* in gastric mucus production was investigated. The results showed that the extract significantly ($P < 0.05$) enhances gastric mucus production when compared with cimetidine and normal saline treated rats. The production of gastric mucus by *T. avicennioides* was also shown to be dose-dependent. In a study carried out by HO et al. (1986), cimetidine showed a significant suppression of gastric mucus synthesis in rats. The biosynthesis of mucin in rat gastric corpus mucosa was enhanced by histamine in a dose-dependent manner (CHIKAWA et al., 1998). These findings agreed with the result of this study, where gastric mucus production is significantly ($P < 0.05$) lower in rats treated with cimetidine when compared with *T. avicennioides*-treated rats. It is therefore assumed that the gastroprotective effect of *T.*

avicennioides is due to its ability to enhance gastric mucus production, which protects the gastric mucosal membrane against aggressive factors such as HCl, pepsin and bile pigments. This action is similar to the action of prostaglandin analogue (misoprostol), which produces its cytoprotective effect mainly by causing enhanced gastric mucus production (WANG et al., 1989).

Reactive oxygen species generated by the metabolism of arachidonic acid in platelets, macrophages and smooth muscle cells may contribute to gastric mucosal damage. Free radical scavengers, therefore, could prove useful in protecting the gastric mucosa from oxidative damage or by accelerating healing of gastric ulcers (HAHN et al., 1997). Antioxidants act as radical scavengers, inhibit lipid peroxidation and other free radical-mediated processes and therefore they protect the human body from several diseases attributed to the reaction of radicals. Plant chemical substances such as flavonoids, tannins, have been shown to scavenge free radicals and therefore are viewed as promising therapeutic drugs for free radicals pathologies (CZINNER et al., 2001; SATOSHI et al., 2003). Phytochemical test revealed the presence of flavonoids and tannins in the extract of *T. avicennioides*. In addition, tannins extracted from the plant *Syzygium cumini* exhibited a gastroprotective effect and significantly lowered free radical concentrations in the stomach of rats (REBECCA and CAMILO, 2004). These findings might well suggest that tannins present in *T. avicennioides* have gastroprotective and anti-ulcerogenic effects.

T. avicennioides possessed antibacterial activity, as revealed through its effect on *Vibrio cholera* (AKINSIDE and OLUKOYO, 1995). *H. pylori* (a bacterium) infects the stomach of more than 50% people worldwide and is responsible for most peptic ulcer diseases, gastritis and gastric malignancies of ulcer (FORMAN et al., 1991; BLASER, 1992; PARSONNET et al., 1994). Eradication of *H. pylori* infection is strongly recommended in duodenal and gastric ulcers, whether they are active or not. Cure of the infection not only promotes peptic ulcer healing but also reduces ulcer relapse (WEI-HAO et al., 2005). Antimicrobial agents (clarithromycin, amoxicillin or metronidazole) have been shown to be effective in the treatment of gastroduodenal ulcers. It may therefore be reasonable to assume that the ulcer-healing effect of *T. avicennioides* is partly due to its antibacterial action, particularly against *H. pylori* infection.

Conclusion

The study showed that *T. avicennioides* affords a gastroprotective effect against HCl-induced gastric damage in normal rats. Furthermore, the plant also enhances gastric mucus production in rats. This action perhaps explains its mechanism of action. Further studies to elucidate the active compounds contained in the extract and to evaluate the efficacy of the plant against *H. pylori* infection are required. Moreover, there is a need

M. M. Suleiman et al.: Gastroprotective effect of the crude methanol extract of *Terminalia avicennioides* in rats

to conduct detailed toxicity studies, using the plant on both laboratory and target animal species, to justify clinical investigation in other species of animals and in humans.

References

- ABDULLAHI, A. L., M. O. AGHO, S. AMOS, K. S. GAMANIEL, C. WAMBEBE (2001): Antidiarrhoeal activity of the aqueous extract of *Terminalia avicennioides* roots. *Phytother. Res.* 15, 431-434.
- AKINSIDE, K. A., O. K. OLUKOYA (1995): Vibriocidal activities of some local herbs. *J. Diarr. Dis. Res.* 13, 127-129.
- AKINYEMI, K. O., C. BAYAGBON, A. O. B. OYEFOLU, K. A. AKINSIDE, E. A. OMONIGBEYIN, A. O. COKER (2003): Antibacterial screening of five indigenous Nigerian medicinal plants against *S. typhi* and *S. paratyphi*. *J. Nig. Inf. Dis. Contr. Assoc.* 3, 30-33.
- BISHAYEE, A., M. CHATTERJEE (1994): Protective effects of *Mikania cordata* root extract against physical and chemical factors induced gastric erosions in experimental animals. *Pl. Med.* 60, 110-113.
- BLASER, M. J. (1992): Hypotheses on the pathogenesis and natural history of *Helicobacter pylori*-induced inflammation. *Gastroenterol.* 102, 720-727.
- BRAIN, K. R., T. D. TURNER (1975): The practical evaluation of Phytopharmaceuticals. Wright-Scientifica, Bristol, pp.10-30.
- BRUNTON, L. L. (1996): Agents for control of gastric acidity and treatment of peptic ulcer. In: Goodman and Gilman's The Pharmacological Basis of Therapeutics (HARDMAN, J. G., L. E. LIMBIRD, P. B. MOLINOFF, R. W. RUDDON, A. G. GILMAN, Eds.), 9th ed., McGraw-Hill, New York. pp 901-915.
- CORNE, S. J., S. M. MURISSEY, R. J. WOOD (1974): A method for the qualitative estimation of gastric barrier mucus. *J. Physiol.* 242, 116-117.
- CROSS, C., B. HALLIWELL A. ALLEN (1984): Antioxidant protection: A function of tracheobronchial and gastrointestinal mucus, *Lancet* 1, 1328-1330.
- CZINNER, E., K. HAGYMASIK, A. BLAZOVICS, E. KERRY, A. SZOKE, E. LEMBERKOVICS (2001): The *in vitro* effect of *Helichysiflos* on microsomal lipid peroxidation. *J. Ethnopharmacol.* 77, 31-35.
- DALZIEL, J. M. (1955): The useful plants of west tropical Africa. Crown Agents for Overseas Governments and Administration. London, pp. 81.
- DAVIES, N. M., J. L. WALLACE (1997): Nonsteroidal anti-inflammatory drug-induced gastrointestinal toxicity: New insight into an old problem. *J. Gastroenterol.* 32, 127-133.
- FORMAN, D., D. G. NEWELL, F. FULLERTON, J. W. YARNELL, A. R. STACEY, N. WALD, F. SITAS (1991): Association between infection with *Helicobacter pylori* and risk of gastric cancer: evidence from a prospective investigation. *Br. Med. J.* 302, 1302-1305.

M. M. Suleiman et al.: Gastroprotective effect of the crude methanol extract of *Terminalia avicennioides* in rats

- HAHN, K., I. PARK, Y. KIM, J. KIM, S. CHOS, S. LEE, J. YOUNG (1997): Role of ethanol and arachidonic acid pathway inhibitors on the effectiveness of gastric mucosa cytoprotection. *Folia Morphologica*. 60 (Supp 1), 47-56.
- HO, M. M., C. W. OGLE, S. DAI (1986): Morphine enhances gastric mucus synthesis in rats. *Eur. J. Pharmacol.* 122, 81-86.
- HOOGERWERF, W. A., P. J. PASRICHA (2001): Agents used for control of gastric acidity and treatment of peptic ulcers and gastroesophageal reflux disease. In: Goodman and Gilman's The Pharmacological Basis of Therapeutics (eds. Hardman, J.G., L.E. Limbird, P.B. Molinoff, R.W. Ruddon, A.G. Gilman), 10th ed. New York: Tata Mc Graw Hill, pp. 1005-1019.
- IBRAHIM, M. A., N. NWUDE, P. A. OGUNSUSI, Y. O. ALIU (1983): Screening of West African plants for anthelmintic activity. *Int. Livest. Cent. Afr. Bull.* 17, 19-23.
- ICHIKAWA, T., K. ISHIHARA, Y. KOMURO, K. SAIGENJI, K. HOTTA (1998): Effects of new histamine H₃ receptor antagonist, F RG-8813, on gastric mucin in rats with or without acidified ethanol-induced gastric damage. *Lif. Sci.* 54, 159-164.
- KANNER, J., T. LAPIDOL (2001): The stomach as a bioreactor: dietary lipid peroxidation in gastric fluid and effects of plant derived antioxidants. *Free Rad. Biol. Med.* 31 (Suppl. 11), 1388-1395.
- KEAY, R. W. J., C. F. A. ONOCHE, D. P. A. STANFIELD (1960): *Nigeria Trees*. 1st ed. Clarendon Press, Oxford, 93 pp.
- MEYER ALBIERO, A. L., J. A. ABION SERTIE, E. M. BACCHI (2002): Antiulcer activity of *Sapindus saponaria* in the rat. *J. Ethnopharmacol.* 82, 41-44.
- OHARA, S., M. TSURUI, T. WATANABE, T. ICHIKAWA, K. HOTTA (1995): Gastric mucosal damage accompanying changes in mucin induced by histamine in rat. *Pharmacol. Toxicol.* 77, 397-401.
- PARSONNET, J., S. HANSEN, L. RODRIGUEZ, A. B. GELB, R. A. WARNKE, E. JELLUM, N. ORENTREICH, J. H. VOGELMAN, G. D. FRIEDMAN (1994): *Helicobacter pylori* infection and gastric lymphoma. *N. Engl. J. Med.* 330, 1267-1271.
- PENISSI, A. B., R. S. PIEZZI (1999): Effect of dehydroleucodine on mucus production: a quantitative study. *Dig. Dis. Sci.* 44, 708-712.
- RANG, H. P., M. M. DALE, J. M. RITTER, P. K. MOORE (eds.). (2003): *Pharmacology*, 5th edition. Churchill, Livingstones, Edinburgh, pp. 797.
- RASKIN, J. B., R. H. WHITE, J. E. JACKSON, A. L. WEAVER, E. A. TINDALL, R. B. LIES, D. S. STANTON (1995): Misoprostol dosage in the prevention of non-steroidal anti-inflammatory drug-induced gastric and duodenal ulcers. A comparison of three regimens. *Ann. Int. Med.* 123, 344-350.
- REBECCA, O. R., C. R. CAMILO (2003): The gastroprotective effect of tannins extracted from duhat (*Syzygium cumini* Skeels) bark on HCl/ethanol induced gastric mucosal injury in Sprague-Dawley rats. *Clin. Hemorheol. Microcirc.* 29, 253-261.
- REPETTO, M. G., S. F. LLESUY (2002): Antioxidant properties of natural compounds used in popular medicine for gastric ulcers. *Brazilian J. Med. Biol. Res.* 35, 523-534.

M. M. Suleiman et al.: Gastroprotective effect of the crude methanol extract of *Terminalia avicennioides* in rats

- SATOSHI, T., G. M. AHMED, A. R. ROSS, F. DANEEL, E. A. MAHMOUD, S. I. ABDEL-RAHIM, S. E. FAROUK (2003): Antioxidant effect of flavonoids on DCF production in HL-60 cells. *Phytother. Res.* 17, 963-966.
- WANG, J. Y., S. YAMASAKI, K. TAKEUCHI (1989): Delayed healing of acetic acid induced gastric ulcers in rats by indomethacin. *Gastroenterol.* 96, 393-402.
- WEI-HAO, S., O. XI-LONG, C. DA-ZHONG, Y. QIAN, Y. TING, H. JIN-MING, Z. FENG, S. YUN-LIANG, F. XI-LING, S. HAN (2005): Efficacy of omeprazole and amoxicillin with either clarithromycin or metronidazole on eradication of *Helicobacter pylori* in Chinese peptic ulcer patients. *World J. Gastroenterol.* 11, 2477-2481.
- YUSUF, S. A., A. J. NOK, D. A. AMEH, A. B. ADELAIYE, E. O. BALOGUN (2004): Quantitative changes in gastric mucosal glycoproteins: effects of cholinergic agonist and vagal stimulation in the rat. *Neurogastroenterol.* 16, 613-619.

Received: 20 January 2006

Accepted: 2 July 2007

SULEIMAN, M. M., I. O. ROMANUS, S. YUSUF: Učinak sirovoga metanolskoga iscrpka biljke *Terminalia avicennioides* na zaštitu želučane sluznice štakora. *Vet. arhiv* 77, 345-354, 2007.

SAŽETAK

Istražen je učinak različitih doza metanolskoga iscrpka biljke *Terminalia avicennioides* (Combretaceae) na akutno oštećenje želučane sluznice i proizvodnju želučane sluzi u štakora. Akutno oštećenje želučane sluznice bilo je izazvano 0,6 M otopinom HCl-a. Životinje obrađene iscrpkom *T. avicennioides* u dozi od 350 mg/kg pokazale su statistički značajno ($P < 0,05$) slabije oštećenje želučane sluznice. U usporedbi s kontrolnom skupinom (štakori koji su dobivali fiziološku otopinu), isti učinak bio je statistički visoko značajan ($P < 0,01$) pri dozama od 500 i 900 mg/kg. Također, iscrpak *Terminalia avicennioides* u dozama od 350, 500 i 900 mg/kg potaknuo je značajan ($P < 0,05$) porast proizvodnje želučane sluzi u usporedbi s kontrolnom i skupinom obrađivanom cimetidinom. Učinci iscrpka iz *Terminalia avicennioides* na oštećenja želuca i proizvodnju sluzi ovisе o dozi. Rezultati istraživanja potvrdili su tvrdnju da biljka ima učinke koji pospješuju liječenje želučanoga vrieda.

Ključne riječi: *Terminalia avicennioides*, želučani vried, zaštita želuca
