

Feline small intestinal lymphosarcoma - a case report

**Valent Ledecký^{1*}, Zuzana Ševčíková², Bronislava Magicová¹,
Marian Hluchý¹, Anton Ševčík¹, Igor Capik¹, Martin Mihály¹,
and Dušan Magic³**

¹Department of Surgery, Orthopaedics and Radiology, University of Veterinary Medicine, Košice

²Department of Pathological Anatomy, University of Veterinary Medicine, Košice

³ I. Internal Clinic, University of Veterinary Medicine, Košice

LEDECKÝ, V., Z. ŠEVČÍKOVÁ, B. MAGICOVÁ, M. HLUCHÝ, A. ŠEVČÍK, I. CAPIK, M. MIHÁLY, D. MAGIC: Feline small intestinal lymphosarcoma. Vet. arhiv 73, 55-62, 2003.

ABSTRACT

We describe a clinical case of a 4-year-old cat suspected to be suffering from a kidney disease, sent to our clinic by a private veterinarian. During the preceding two weeks the cat suffered from anorexia and in the past three days she had vomited food and water. Clinical examination revealed dehydration and abdominal palpation identified two solid, walnut-sized formations in the centre of the cat's abdominal cavity. A blood sample was taken for biochemical examination and the abdominal cavity was examined by X-ray. On the basis of the results obtained a diagnostic laparotomy was performed, which established the presence of two tumorous formations protruding from jejunum. The affected part of the intestine was resected, intestinal ends were joined by end-to-end everted anastomosis and the laparotomic wound was closed using the common procedure. The cat was treated by infusions and antibiotics. The excised portion of the intestine was sent for histological examination, which identified a lymphosarcoma.

Key words: sarcoma, intestinal neoplasm, cat

* Contact address:

Assoc. Prof. MVDr. V. Ledecký, PhD, Department of Surgery, Orthopaedics and Radiology, University of Veterinary Medicine, Komenského 73, 040 81 Košice, Slovak Republic. Phone/Fax: +421 55 633 7832, E-mail: Ledecky@uvm.sk

Introduction

Intestinal tumours, either malignant or benign, are infrequent in domestic animals and represent a diagnostic and therapeutic challenge to small animal veterinary practice. An interesting aspect of gastrointestinal tumours is their frequent association with environmental carcinogens (MORRISON, 1998)

The incidence of feline epithelial tumours exceeds that of mesenchymal ones. Besides lymphosarcomas the most frequent mesenchymal tumours are probably leiomyomas and leiomyosarcomas (PIEMONTE et al., 1996).

Intestinal neoplasms affect most frequently the rectum and colon of dogs and small intestine of cats. Most of these tumours are malignant. Dogs are affected mostly by adenocarcinomas and lymphosarcomas and cats by lymphosarcomas (McGAWIN et al., 2001).

Intestinal neoplasms may result in intramural or intraluminal mechanical obstructions. They attack mostly the muscular layer of the intestinal wall and decrease the intestinal lumen (HEDLUND, 1997).

Materials and methods

History. A 4-year-old cat weighing 2.5 kg suspected to be suffering from kidney disease was admitted to our clinic on the recommendation of a private veterinarian. The clinical examination revealed anorexia lasting for 14 days and vomiting of food and water for the past three days, with irregular intervals between food consumption and vomiting.

Clinical examination. Body temperature was 38.7 °C, conjunctivae and mucous membranes were light-pink, CRT-2s, elasticity of skin was decreased (10 sec), abdominal cavity was soft, palpable, painless, intestinal content palpable, thin and soft and two solid, walnut-sized formations were palpable in the centre of the abdominal cavity, the urinary bladder was palpable and the size of a plum. Biochemical examination: ALP - 0.146 μ kat/l (0.084 - 0.410), urea - 11.4 mmol/l (3.33-6.33), serological examination for FeLV and FLV - negative, examination of urine-specific weight 1.026, pH 8, proteins ++, blood ++, after two day antibiotic therapy specific weight 1.033, pH 6, proteins +, blood +. X-ray examination in a lateral position provided non-specific findings, the stomach and small and large intestines were empty, the urinary bladder full, and the size of kidneys was unchanged.

The cat was subjected to infusion and antibiotic and vitamin therapy and supplied with Whiskas low-protein diet. Its condition improved for about 5 days after which the cat began to vomit again. A contrast X-ray examination in a lateral position showed evident extension of the small intestine lumen in the medial abdomen pointing to obstipation in that site (Fig.1).

Diagnostics and evaluation. Slightly increased urea level resulting from prerenal azotemia due to dehydration caused by repeated vomiting. On the basis of palpation and radiographic examination diagnostic laparotomy was performed which established the presence of two solid spherical formations the size of a walnut that surrounded the jejunal lumen. The affected portion of jejunum was resected, and the intestinal ends were joined by end-to-end intestinal anastomosis using the everted method. The abdominal cavity was closed using the common procedure. The excised intestinal portion was sent for histological examination.

The cat's status improved after surgery, the animal began to accept food, did not vomit and excreted droppings. On day 5 after the operation the animal again began to vomit, its body temperature reached 37.6 °C and the cat appeared apathetic. It was subjected to infusion, antibiotic and antiemetic therapy; however, its status failed to improve. On the basis of clinical symptoms and histological results the owner decided in favour of euthanasia.

Histopathological examination. Samples were fixed in 10% neutral phosphate-buffered formalin, paraffin-embedded, sectioned at 5 µm, and stained with haematoxylin and eosin. Giemsa staining was used for the detection of specific mast cells granules in their cytoplasm.

To prove the origin of tumour its reactivity to immunohistochemical markers was carried out by means of the biotin streptavidin amplified peroxidase detection (B-SA) system (Biogenex, San Ramon, CA, U.S.A.). The antibodies used are summarized in Table 1. Immunological reactions were revealed by diaminobenzidine (DAB – Dakopatts, DAKO, Denmark) substance.

All samples were evaluated microscopically to determine the presence and cellular location of positive staining.

Histopathological examination indicated infiltrative tissular growth with dominance of rounded cells with high mitotic activity (Fig. 2). Regressive changes were also observed. Only a portion of the intestinal wall (Lieberkühn crypts) was partially preserved (Fig. 3). The negative reaction was found after Giemsa staining.

The mesenchymal origin was proved by positive reaction of the neoplastic cells against cytoskeletal protein vimentine. Low-molecular

Table 1. Antibodies used for tumour identification

Specific antibody used	Pretreatment	Type	Dilution	Source
LMW Cytokeratine	Digested	Monoclonal antimouse	1:50	Biogenex
Vimentine	Undigested	Polyclonal antirabbit	1:10	Biogenex
CD3	Digested	Polyclonal antirabbit	1:300	Dakopatts
Desmine	Undigested	Polyclonal antirabbit	1:8	Biogenex

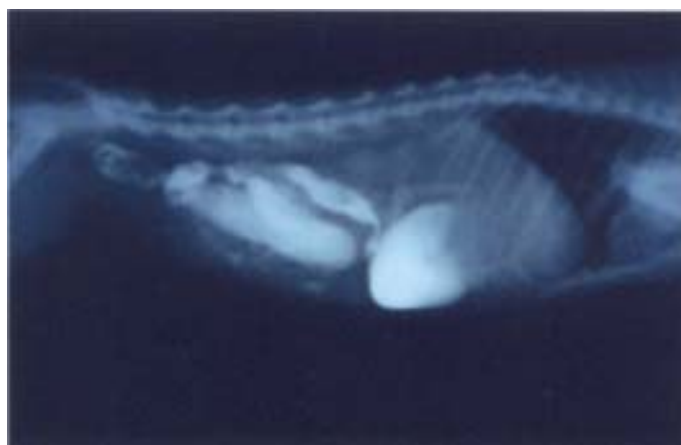

Fig. 1. Contrast X-ray picture taken 3 hours after administration of the contrast substance

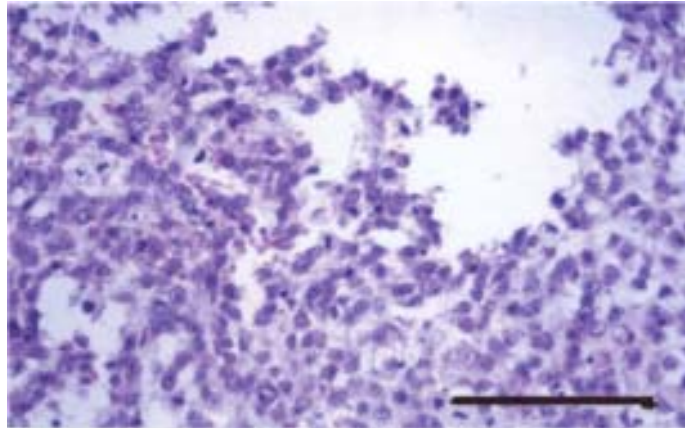


Fig. 2. Neoplastic tissue with predomination cells with high mitotic activity. H&E; scale bar = 10 μ m

cytokeratine and desmine cytoskeletal protein expressions were not observed. The tumour was characterized as a lymphosarcoma after the diffuse and intensive positive reaction of neoplastic cells against antiserum to CD3 T lymphocytes (Fig. 4).

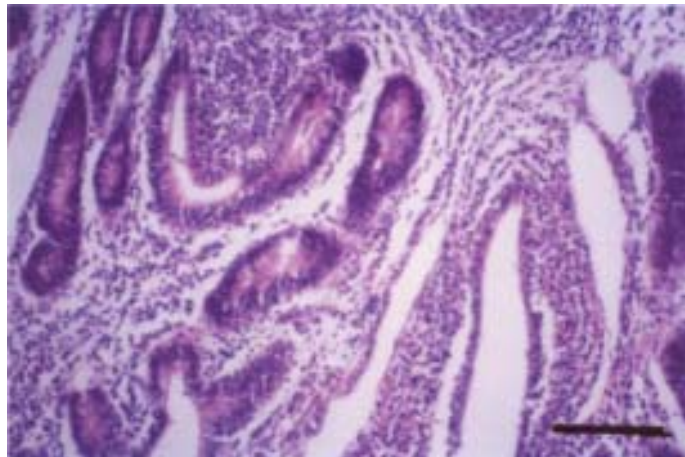


Fig. 3. Partially preserved cryptic portion of the intestine. Scale bar = 10 μ m

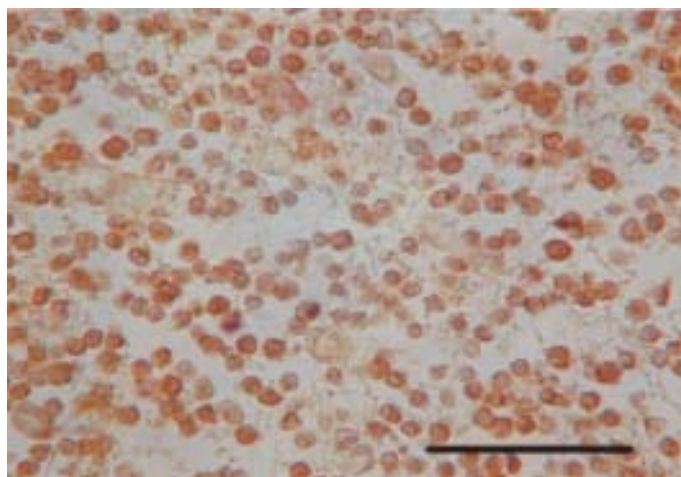


Fig. 4. The positive brown-coloured reaction of the neoplastic cells labelled by rabbit CD3 antiserum to human T cells. (Biotin-Streptavidin detection system).
Scale bar = 5 μ m

Discussion

HEDLUND (1997) and DVOŘÁK et al. (1999) described clinical symptoms in relation to tumour location. In the beginning, patients demonstrate depression, anorexia and lethargy, which can lead to diarrhoea and vomiting. Additional symptoms include loss of mass, dehydration, melaena, haematemesis, anaemia, fever, icterus, and abdominal effusions. Symptoms of intestinal obstruction, abscedation and malabsorption may also occur. Abdominal palpation reveals solid masses, thickened intestinal loops or mesenterial lymphadenopathy. Haematological and biochemical profiles are frequently without any changes.

In rare cases the disease is manifested only by acute post-perforation abdominal symptoms. We can detect anaemia due to chronic loss of blood, leukocytosis, panhypoproteinaemia and increase in liver enzymes (KLIMEŠ et al., 2000).

A pronounced loss of mass occurs in animals with small intestine neoplasms, but not in dogs with colon adenocarcinomas (FENEY et al., 1982).

The mass losses most probably result from a combination of decreased uptake of food, impaired absorption ability of the small intestine and possible cancerous cachexy. Intestinal villi may be filled with neoplastic cells and lose their absorption abilities. Malabsorption develops also due to partial or total obstruction of the intestinal lumen and blocking the passage of the intestinal content. Obstruction of the small intestine results in an increase in aerobic and anaerobic microflora, leading to de-conjugation of bile acids, hydroxylation of fatty acids and production of bacterial metabolites toxic to epithelial cells.

Cancerous cachexia is a syndrome of decreased condition of an organism. It develops due to impaired metabolism rather than decreased feed uptake and absorption disorders. Patients with neoplasms suffer from altered carbohydrate, lipid and protein metabolism, impaired parameters of electrolytes, minerals and internal environment, and changes in endocrine and immunological functions (FENEY et al., 1982).

KLIMEŠ et al. (2000) described masses visible in native X-ray pictures, or signs of obstruction, such as accumulation of gases and liquids proximal to the site of obstruction. Contrast roentgenological examination has in some cases revealed irregular indentation of the boundary between the mucosa and the contrast substance, thickening of the wall and partial obstruction of an intestinal section. The clinical course described agrees with the symptoms observed in our clinical case.

Differential diagnostics should be used to distinguish partial obstructions caused by intussusception or a linear foreign body. They have, however, an acute onset and are of shorter duration.

Definitive diagnosis of small intestine neoplasms can be made only after diagnostic laparotomy and histopathological examination of intestinal wall samples.

Conclusion

We describe feline small intestinal lymphosarcoma, diagnosed through histological examination of the affected intestinal wall following laparotomy and enterectomy. Due to an unfavourable therapeutic prognosis the cat was subjected to euthanasia with the approval of the owner.

References

- DVOŘÁK, M., A. NEČAS, J. ZATLOUKAL (1999): Tumory kostí u psů. *Veterinářství* 49, 526-530.
- FENEY, D. A., J. S. KLAUSNER, G. R. JOHNSTON (1982): Chronic bowel obstruction caused by primary intestinal neoplasia: A report of five cases. *J. Am. Anim. Hosp. Assoc.* 18, 67-77.
- HEDLUND, CH. S. (1997): Intestinal neoplasia. In: *Small Animal Surgery*. (Fossum, T. W. Ed.). Mosby-Year Book, Inc. pp. 309-311.
- KLIMEŠ, J., M. VLAŠÍN, V. SVOBODOVÁ (2000): Diseases of dogs and cats. In: *Small Intestine Neoplasms* (in Czech). (Svoboda, M., ed.). Noviko, a. s., Brno. pp. 830-833.
- McGAWIN, M. D., W. W. CARLTON, J. F. ZACHARY (2001): *Thompson's Special Veterinary Pathology*. Mosby Inc. A Harcourt Health Science Company USA. p. 77.
- MORRISON, W. B. (1998): *Cancer in Dogs and Cats*. RR Donnelley & Sons Company, USA. p. 555.
- PIEMONTE, F., V. D'AVINO, G. BARONE, S. DI MARZO, G. M. RIZZO, G. CONSTANZO, A. MERCOGLIANO, G. DE SIMONE (1996): Leiomyoma of the small intestine - a rare cause of emergency abdominal surgery. *Minerva Chir.* 51, 989-991.

Received: 3 August 2002

Accepted: 14 February 2003

LEDECKÝ, V., Z. ŠEVČÍKOVÁ, B. MAGICOVÁ, M. HLUCHÝ, A. ŠEVČÍK, I. CAPIK, M. MIHÁLY, D. MAGIC: Limfosarkom tankog crijeva mačke. *Vet. arhiv* 73, 55-62, 2003.

SAŽETAK

Opisana je klinička slika u mačke u dobi 4 godine koja je na kliniku upućena pod sumnjom na bolest bubrega. Dva tjedna prije toga pokazivala je znakove anoreksije, a posljednja tri dana povraćala je hranu i vodu. Mačka je bila izrazito dehidrirana, a palpacijom abdomena ustanovljene su dvije čvrste tvorbe veličine oraha i to u središnjem području trbušne šupljine. Provedena je klinička i biokemijska pretraga krvi i rendgenografija abdomena. Na temelju dobivenih nalaza izvršena je dijagnostička laparotomija kojom su dokazane dvije tumorske tvorbe na taštom crijevu. Promijenjeni dio crijeva je reseciran nakon čega su krajnji dijelovi spojeni anastomozom. Mačka je nakon operacije bila liječena infuzijama i antibioticima. Odstranjen dio crijeva bio je dostavljen na histološku pretragu te je potvrđen limfosarkom.

Ključne riječi: sarkom, crijevna neoplazma, mačka
