

Occurrence of pulmonary aspergillosis after prolonged antibiotic therapy in a horse - a case report

Azizollah Khodakaram Tafti^{1*}, and Ali Rezakhani²

¹Department of Pathology, School of Veterinary Medicine, Shiraz University, Shiraz, Iran

²Clinical Studies, School of Veterinary Medicine, Shiraz University, Shiraz, Iran

TAFTI, A. K., A. REZAKHANI: Occurrence of pulmonary aspergillosis after prolonged antibiotic therapy in a horse. Vet. arhiv 71, 361-366, 2001.

ABSTRACT

A 7-year-old horse was referred to the Veterinary Teaching Large Animal Hospital of Shiraz Veterinary School, Iran, with fever, dyspnea, tachypnea, cough and nasal discharge. Treatment with antibiotics and antihistamines was ineffective and the animal died 3 weeks post-admission. Post-mortem examination revealed bronchopneumonia with the presence of a large amount of fibrinopurulent exudate in the tracheobronchial airways. Histopathological study of lung sections showed severe necrotizing bronchitis and bronchiolitis, fibrinopurulent pneumonia and numerous branched septate aspergillus hyphae in the exudate and lung tissue. *Aspergillus fumigatus* was isolated from exudate and lung tissue. The risk of establishment or exacerbation of a mycotic infection during antibiotic therapy should be taken into consideration.

Key words: horse, pulmonary aspergillosis, prolonged antibiotic therapy

Introduction

Aspergillosis occurs in humans and in many species of birds and mammals, domesticated and wild, infected primarily by inhalation and which starts as a pulmonary disease, although sometimes involving other organs (COLLIER et al., 1998). *Aspergillus* spp. are saprophytic moulds that are

* Contact address:

Assoc. Prof. A. Khodakaram Tafti, DVM, PhD, Department of Pathology, School of Veterinary Medicine, Shiraz University, Shiraz, Postal code 71345, P.O. Box 1731, Islamic Republic of Iran, Fax: +98 7127 962, E-mail: tafti@hafez.shirazu.ac.ir

extremely common in nature, occurring on foodstuffs and plants as a white, fluffy, sporulating mould (COLLIER et al., 1998; JONES et al., 1997). Ordinarily, they are not pathogens but once established in a susceptible host aspergillosis can be a serious disease (JONES et al., 1997). Aspergillosis of the respiratory tract often appears to be a complication of some other debilitating disease, or following antibacterial and systemic corticosteroid therapy, but there are cases in which no clear predisposition can be found (JUBB et al., 1993). Most infections are established by inhalation of spores, leading to pneumonia. The infection may develop as an implantation on the mucous membranes of the conductal and tracheobronchial airways. Pulmonary aspergillosis can be classified in three forms: the acute form, which is characterized by fibrinous pneumonia with fever, dyspnea, tachypnea, cough, nasal discharge, groaning, and a short course to death. The sub-acute and chronic forms are less severe, exhibiting mainly anorexia, weight loss and mild respiratory signs, lesions consisting of multiple small, white discrete granulomas with necrotic centres, or nodular bronchopneumonia (SMITH, 1996). In this report, acute aspergillus pneumonia is described in a horse after receiving antibiotic therapy for a prolonged period.

Case history and results

A 7-year-old horse was referred to the Veterinary Teaching Large Animal Hospital of Shiraz Veterinary School, Iran, with fever, dyspnea, tachypnea, cough and nasal mucopurulent discharge. Although the owner had administered several remedies, such as low doses of certain antibiotics some 15 days previously, the horse's condition failed to improve. At the time the animal was admitted the vital signs - respiratory rate, heart rate and rectal temperature - were 56/min, 88/min, and 39.5 °C, respectively. Primary diagnosis of this case was purulent pneumonia and treatment involved intramuscular injections of daily doses of penicillin k (5000000 IU), streptomycin sulfate (4 g) and flunixinmeoglumine or finadyne (1.8 mg/kg) over a 7-day period. The horse responded well initially but 9 days after last treatment the condition of the animal became progressively worse and hypoxemic. Treatment with antibiotics (including combizide i/m V32 kg B.W.) and antihistamines was ineffective and the animal died 3 weeks

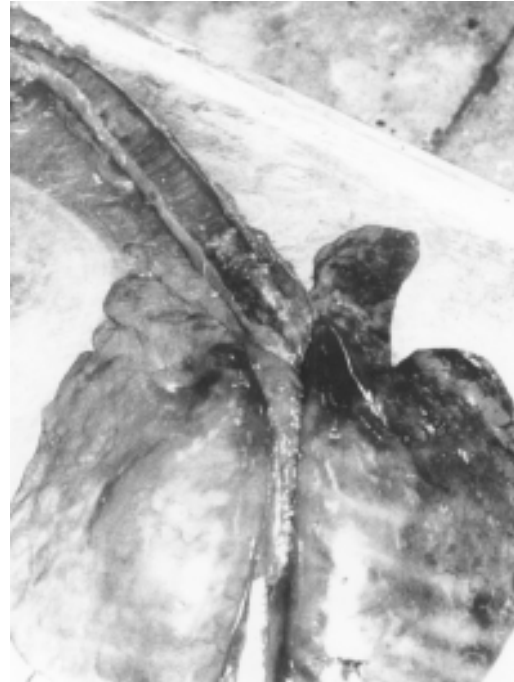

Fig. 1. Aspergillus pneumonia in the lung of a horse. The presence of a large amount of fibrinopurulent exudate in the bifurcation and consolidation of anteroventral lobes

after primary admission. The animal underwent necrotomy and all organs were carefully and systematically examined. Suspect tissues were fixed in 10% buffered formalin, cut at 5 μ m, and stained with hematoxylin and eosin (HE). Selected tissues were stained using Periodic Acid-Schiff (PAS) technique. Bacteriologic specimens were cultured on Blood agar, Sabouraud's agar and differential media (TIMONEY et al., 1998). Post-mortem examination of the respiratory system revealed congestion, edema and petechial haemorrhages of trachea and the presence of a large amount of yellowish fibrinopurulent exudate in the tracheobronchial airways, particularly in the bifurcation, and also reddish-grey consolidation of anteroventral lobes of lung (Fig. 1). Histopathological study of lung sections showed fibrinopurulent pneumonia, severe necrotizing bronchitis and bronchiolitis with purulent and mononuclear inflammatory response, and existence of large colonies of irregularly dispersed hyphae in the lumen of

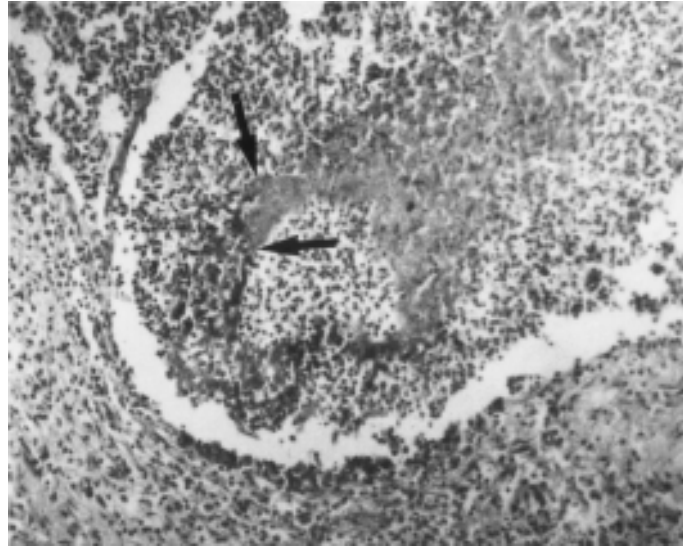


Fig. 2. Aspergillus pneumonia in a horse. Extensive necrotizing bronchitis with inflammatory reaction and existence of large colonies of Aspergillus hyphae in exudates (arrows). H&E; $\times 240$

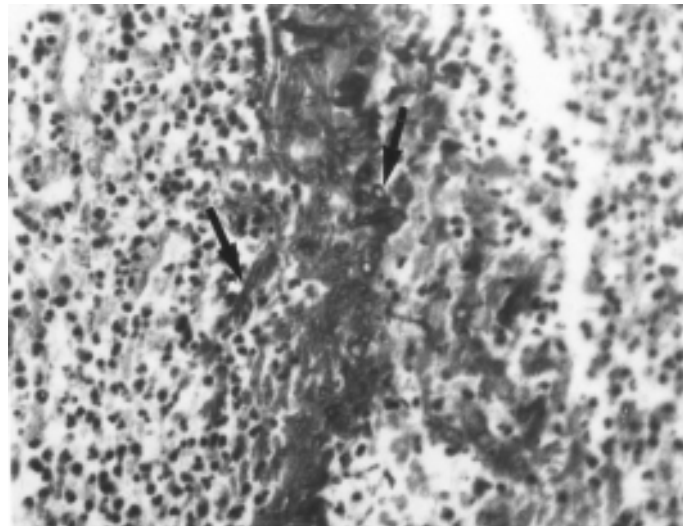


Fig. 3. Higher magnification of Aspergillus hyphae. They are basophilic, of uniform diameter, septate and branching (arrows). H&E; $\times 400$

the bronchi (Fig. 2). The hyphae were well stained with HE and PAS. They were basophilic, of uniform diameter, septate and branching (Fig. 3). No significant lesions were found in other tissues. Cultures of tracheobronchial exudate and lung tissue on blood agar produced no growth, but on Sabouraud's agar they produced growth and *Aspergillus fumigatus* was isolated.

Discussion

Aspergillus pneumonia is a rare condition in the horse but has been reported previously (ROSENSTEIN and MULLANEY, 1996; GREEN et al., 1987; SLOCOMBE and SLAUSON, 1988; SUDARIC et al., 1979; ERTURK and ALIBASOGLU, 1974). Aspergillosis usually occurs in those cases that have undergone chronic antibiotic and or corticosteroid therapy or that are otherwise immunosuppressed or chronically ill and debilitated (COLLIER et al., 1998; JUBB et al., 1993; SMITH et al., 1981). ROSENSTEIN and MULLANEY (1996) reported acute pulmonary aspergillosis in a Quarter horse mare. GREEN et al. (1987) described acute diffuse mycotic pneumonia in a colt. Fungal culture of lung tissue produced *Aspergillus fumigatus* growth, and a histological study of lung revealed numerous branched septate fungal hyphae throughout the lung parenchyma. SUDARIC et al. (1979) reported pathological changes in acute and chronic aspergillus pneumonia of horses. Purulent bronchitis and aspergillous myceliae were found in the lumen of the small and large bronchi. One or two cases of *Aspergillus fumigatus* were isolated from all lung lesions. In the case reported on here, pathological lesions in the pulmonary airways seem to be pulmonary. Aspergillosis associated with corticosteroid therapy has been reported (SMITH et al., 1981), but this is the first report of aspergillus pneumonia following long-term antibiotic therapy in a horse. The risk of the establishment or exacerbation of a mycotic infection during antibiotic therapy should be taken into consideration.

References

- COLLIER, L., A. BALOWS, M. SUSSMAN, L. AJELLO, R. J. HAY (1998): Topley & Wilson's Microbiology and Microbial Infections. 9th ed., Vol. 4, Medical Mycology, Oxford University Press, Inc., New York. pp. 281-307.

A. K. Tafti and A. Rezakhani: Occurrence of pulmonary aspergillosis after prolonged antibiotic therapy in a horse

- ERTURK, E., M. ALIBASOGLU (1974): Fungus disease of domestic animals in Ankara. *Veteriner Fakultesi Dergisi* 21, 224-242.
- GREEN, S. L., D. A. HAGER, M. B. C. MAYS, A. M. MERRITT, M. B. CALDERWOOD-MAYS (1987): Acute diffuse mycotic pneumonia in a 7-month-old colt. *Vet. Radiol.* 28, 216-219.
- JONES, T. C., R. D. HUNT, N. W. KING (1997): *Veterinary pathology*. 6th ed., Williams & Wilkins, Inc, Maryland. pp. 505-508.
- JUBB, K. V. F., P. C. KENNEDY, N. PALMER (1993): *Pathology of domestic animals*. 4th ed., Vol. 2, Academic Press, Inc, San Diego, CA. pp. 665-666.
- ROSENSTEIN, D. S., T. P. MULLANEY (1996): Acute pulmonary aspergillosis and severe enterocolitis in a Quarter Horse mare. *Equine Vet. Edu.* 8, 200-203.
- SLOCOMBE, R. F., D. O. SLAUSON (1988): Invasive pulmonary aspergillosis of horses: an association with acute enteritis. *Vet. Pathol.* 25, 277-281.
- SMITH, B. P. (1996): *Large Animal Internal Medicine*. 2nd ed., Mosby -Year Book, Inc, St. Louis, Missouri. pp. 671-672,
- SMITH, D. A., M. G. MAXIE, B. P. WILCOCK (1981): Disseminated mycosis: a danger with systemic corticosteroid therapy. *Can. Vet. J.* 22, 276.
- SUDARIC, F., B. MARZAN, L. OZEGOVIĆ (1979): Pathological changes in acute and chronic aspergillus pneumonia of horses. *Vet. Yugoslavia* 28, 383-396.
- TIMONEY, J. F., J. H. GILLESPIE, F. W. SCOTT, J. E. BARLOUGH (1988): Hagan and Bruner's *Microbiology and Infectious Diseases of Domestic Animals*. 8th ed., Comstock Publishing Associates, Cornell University Press, Ithaca and London. pp. 407-409.

Received: 25 April 2001

Accepted: 20 December 2001

TAFTI, A. K., A. REZAKHANI: Pojava plućne aspergiloze nakon produžene antibiotske terapije u konja. *Vet. arhiv* 71, 361-366, 2001.

SAŽETAK

Na Veterinarskom fakultetu u Shirazu bio je hospitaliziran konj u dobi od sedam godina sa znakovima vrućice, otežanog i ubrzanog disanja, kašlja i nosnog iscjetka. Premda liječen antibiotcima i antihistaminicima konj je uginuo tri tjedna od početka liječenja. Razudbom je utvrđena bronhopneumonija s mnogo fibrinopurulentnog eksudata u traheji i bronhima. Histološka se slika odlikovala snažnim nekrotizirajućim bronhitisom i bronhiolitisom, fibrinopurulentnom pneumonijom te mnoštvom septiranih hifa u eksudatu i tkivu pluća. Iz eksudata i tkiva pluća izdvojena je vrsta *Aspergillus fumigatus*. Autori zaključuju da je aspergiloza mogla nastati i kao posljedica liječenja antibiotcima.

Ključne riječi: konj, plućna aspergiloza, produžena antibiotska terapija
