

## **A histopathological study of carp (*Labeo rohita*) exposed to hexachlorocyclohexane**

**Basanta Kumar Das\* and Subhas Chandra Mukherjee**

*Aquatic Animal Health Division, Central Institute of Freshwater Aquaculture,  
Kausalyaganga, Bhubaneswar, India*

---

**DAS, B. K., S. C. MUKHERJEE: A histopathological study of carp (*Labeo rohita*)  
exposed to hexachlorocyclohexane. Vet. arhiv 70, 169-180, 2000.**

### **ABSTRACT**

Indian major carp (*Labeo rohita*) were exposed to 1/10 and 1/5 sub-lethal doses of hexachlorocyclohexane during a 45-day trial period. Fish were sacrificed at the end of the trial period to study light microscopic changes associated with toxicity. Organ tissues, viz., liver, kidney, gill, skin, muscle, heart and brain were examined for histopathological study. Swelling of the hepatocytes with diffuse necrosis and marked swelling of blood vessels were observed in the liver tissue. Tubules of the kidney were distended, with tubular cells of posterior kidney exhibiting marked necrotic changes. Gill tissue showed fusion of primary lamellae, congestion of blood vessels and hyperplasia of branchial plates. Pericardial sac was moderately thickened and extensively infiltrated with leucocytes. Marked neuronal cell degeneration with loss of Nissl substances and microglial nodules could be observed at the cerebrum.

**Key words:** *Labeo rohita*, hexachlorocyclohexane, histopathology

---

### **Introduction**

Pesticides drained to the aquatic environment are primarily of agricultural origin and which may also stem from effluent from manufacturing plants. Since there is great concern about toxic hazards in the aquatic ecosystem due to pesticides, either from surface run-off from paddy fields or through direct application into ponds for the control of parasites, it is necessary to study the cellular changes in fish tissue associated with this toxicity. The effects of organochlorine pesticides on fishes have been experimentally recorded by several workers (GHOSH and

---

\* Contact address:

Dr. Basanta Kumar Das, Central Institute of Freshwater Aquaculture, Kausalyganga, Bhubaneswar-751002, (Orissa), India, Phone: 91 674 463421; Fax: 91 674 463407; E-mail: cifa@x400nicgw.nic.in

CHATTERJEE, 1989; THAIN et al., 1990). The toxicity of benzene hexachloride has been studied by BHATIA (1971) in *Cirrhinus mrigala* and *Colisa facitata*. Distribution of benzene hexachlorides on different tissues of *Limanda limanda* was studied by KLINK MEYER and STEINHART (1989).

Considerable interest has been shown in recent years in histopathological study while conducting sub-lethal tests in fish. Tissue changes in test organisms exposed to a sub-lethal concentration of toxicant are a functional response of organisms which provides information on the nature of the toxicant. Histological changes associated with pesticides in fish have been studied by many authors (KING, 1962; COPE, 1966; ELLER, 1971; RAZANI et al., 1986; MUKHOPADHYAY et al., 1987; BRUNO and ELLIS, 1988; NARAYAN and SINGH, 1991; MERCY et al., 1996).

Indian major carp (*Labeo rohita*), being the prime cultured species in poly-culture practices in India, occupy a prominent position in the aquatic system, hence the impact of hexachlorocyclohexane on the cellular level of this candidate species was chosen for the study.

## Materials and methods

### *Test animals*

One hundred and sixty fingerlings of rohu (*L. rohita*) with a masses of  $8.2 \pm 2.34$  g and a mean body length of  $6.11 \pm 2.52$  cm were used for chronic toxicity test of hexachlorocyclohexane (HCH). Apparently healthy fishes were collected from the pond complex of the Central Institute of Freshwater Aquaculture (CIFA), Kausalyaganga, Bhubaneswar, India and brought to the laboratory for acclimatization in a plastic pool for a period of two weeks.

### *Test containers*

Plastic pools of 300 l capacity were used as test container for acclimatizing the fingerlings. To avoid introducing disease into stock tanks, the fish were briefly bathed in a potassium permanganate solution (5 ppm) before introducing them into the experimental area. After the quarantine period they were transferred to 40 l stock tanks for chronic toxicity test.

### *Test medium*

An organochlorine compound, hexachlorocyclohexane ( $C_6H_6Cl_6$ ), supplied by Hindustan Insecticides Limited, India, was used for the

experimental study. Fish were maintained for a period of 45 days under 1/10 and 1/50 of 96 h LC<sub>50</sub> of HCH for chronic exposure studies. Physicochemical parameters were studied every 15 days and recorded for analysis.

### *Chronic exposure studies*

Two sub-lethal concentrations (1/10 and 1/50 of 96 h LC<sub>50</sub>) i.e. 0.35 ppm and 1.73 ppm respectively, were selected for chronic exposure study, and three sets of each concentration and two groups of control fish were maintained for HCH exposure (ANONYMOUS, 1985). Fish were fed with pellet feed at 5% of body mass once a day and water exchange was made at three-day intervals with fresh test solutions in each experimental tank. Test media were kept well aerated. Twenty fish were maintained in each tank. After 45 days test fish were sacrificed for histopathological studies.

Parameters such as temperature, dissolved oxygen, pH, conductivity, total dissolved solids, total hardness, free carbon dioxide and total alkalinity of the test solutions were measured at 15-day intervals, following the procedures of ANONYMOUS (1985).

### *Histopathology*

Organ tissues, liver, kidney, gill, skin and muscles, heart and brain collected in 10% neutral buffered formalin were processed for paraffin blocks (56-58 °C) and sectioning at 3-5 μm. Stained sections were examined under a Zeiss compound binocular microscope (Axiophot, Germany) fitted with a photomicrographic attachment.

## **Results**

### *Physicochemical studies*

Subtle concentration of 0.35 ppm (1/50) and 1.73 ppm (1/10) was conducted for a 45-day period. Physicochemical characteristics of tests solution are shown in Table 1.

### *Histopathology*

*Liver* - No significant changes were observed in the liver tissue except for mild congestion of blood vessels at 0.35 ppm concentration. Alternately, at 1.73 ppm concentration there was marked swelling of the hepatocytes in places with areas of diffuse necrosis (Fig. 1 and 2). The normal architecture of liver tissue was markedly disrupted. Sinusoids in

most cases were distended and central veins appeared severely damaged due to marked swelling and degeneration of the endothelial lining cells.

Table 1. Physico-chemical parameters of water exposed to sublethal concentration of HCH (mean±SD)

Parameter	0 day			15 <sup>th</sup> day			30 <sup>th</sup> day			45 <sup>th</sup> day		
	Concentration											
	C	1/10	1/50	C	1/10	1/50	C	1/10	1/50	C	1/10	1/50
CO <sub>2</sub> (ppm)	0.88±0.14	0.88±0.24	0.76±0.32	1.10±0.20	0.72±0.22	0.86±0.32	0.77±0.22	0.84±0.11	0.68±0.44	0.66±0.44	0.90±0.22	0.56±0.34
TA (ppm)	86.5±4.6	86.0±4.2	86.0±4.6	84.4±3.8	85.5±3.5	82.3±3.6	80.8±4.4	82.5±2.6	82.4±2.8	82.6±4.8	82.4±3.6	83.6±4.5
TH (ppm)	78.0±3.6	78.4±2.8	78.0±3.0	78.6±2.4	68.5±4.8	70.0±2.8	80.4±2.8	72.6±6.2	70.0±3.6	80.2±3.6	74.0±3.6	72.5±2.8
TDS (ppm)	231±2.2	239±1.6	238±2.0	240±3.0	243±2.0	242±2.0	242±1.5	249±2.2	245±2.0	243±2.0	259±3.0	253±3.0
pH	7.2±0.5	7.4±0.2	7.2±0.3	7.3±0.2	7.0±0.4	7.4±0.6	7.2±0.2	7.2±0.6	7.1±0.4	7.6±0.4	6.8±0.4	7.0±0.6
DO (ppm)	5.6±0.4	5.8±0.4	5.6±0.4	5.4±0.4	4.8±1.2	5.0±1.4	5.6±0.2	5.2±0.8	5.6±0.6	6.0±0.4	5.6±1.2	6.0±1.2
Temp. (°C)	26.5±1.0	26.0±1.5	26.2±0.8	27.0±0.5	27.0±0.5	27.0±1.0	27.2±0.4	26.2±1.0	26.0±1.0	26.5±0.6	27.0±0.5	27.5±1.5

C=control; TA=total alkalinity; TH=total hardness; TDS=total dissolved solids; DO=dissolved oxygen

*Kidney* - Only mild degenerative changes of tubular epithelium could be noticed in a 0.35 ppm exposure level. At 1/10 concentration tubular epithelium showed necrotic changes characterized by karyorrhexis and karyolysis at the nuclei of the affected cells. Lumen of the tubules were invariably dilated (Fig. 3). Interstitium was markedly infiltrated with mononuclear cells (Fig. 4).

*Gill* - Mild congestion of blood vessels were seen in the primary lamellae at 0.35 ppm exposure level, where a fusion of primary lamellae and marked hyperplasia of the branchial arch was evident at 1.73 ppm concentration.

*Skin and muscle* - No specific change could be observed at 0.35 ppm exposure level. However, at 1.73 ppm muscle tissue exhibited dystrophic changes with marked thickening and separation of muscle bundles in addition to severe intramuscular oedema (Fig. 5).

*Heart* - Heart showed no change at 1/10 sub-lethal concentration. At 1.73 ppm level, heart tissue exhibited remarkable changes in the pericardium, as well as myocardium. The pericardial sac was moderately thickened and infiltrated extensively by leucocytes (Fig. 6). Myocardial tissue was severely infiltrated by polymorphs, mononuclears and

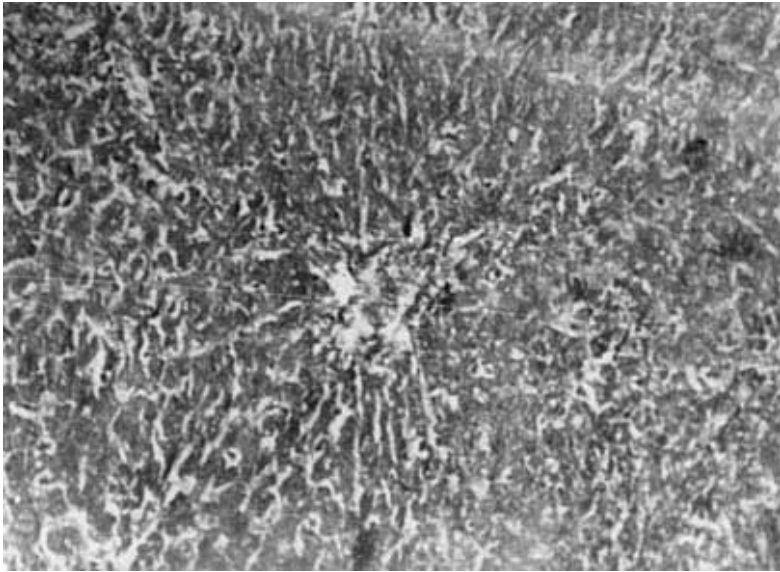


Fig. 1. Liver tissue in Indian carp showing marked swelling of hepatocytes and diffuse necrosis at 1.73 ppm HCH. H&E; 200.

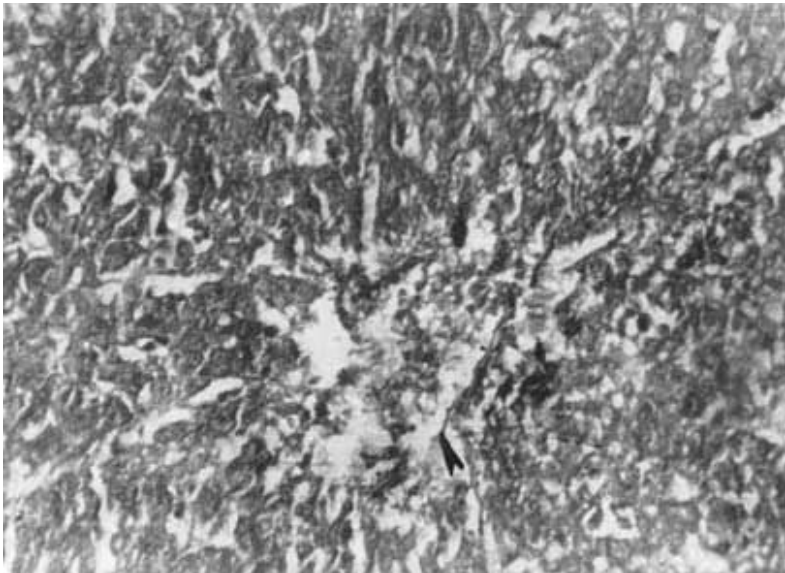


Fig. 2. Higher magnification of Fig. 1. Complete degeneration of the endothelial lining cells of the central vein (arrow). H&E; 400.

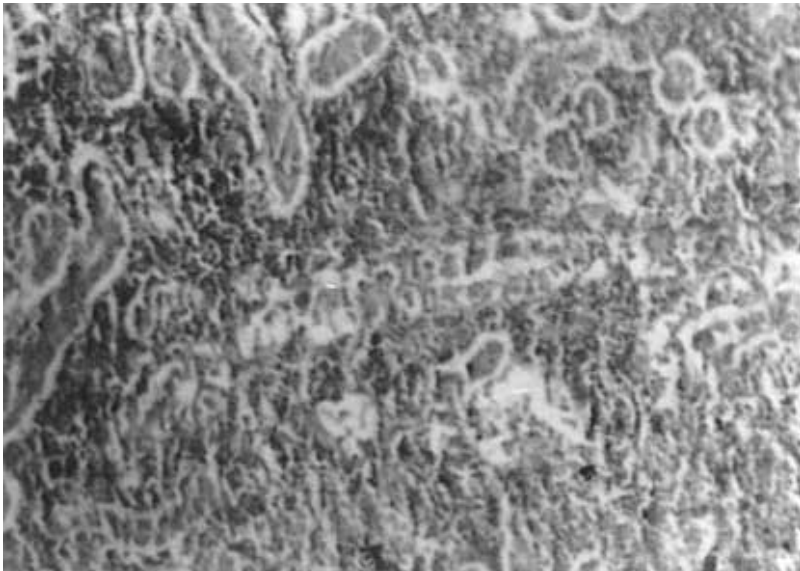


Fig. 3. Photomicrograph showing marked tubular necrosis. Distended tubules showing desquamation of the epithelium. H&E; 200.

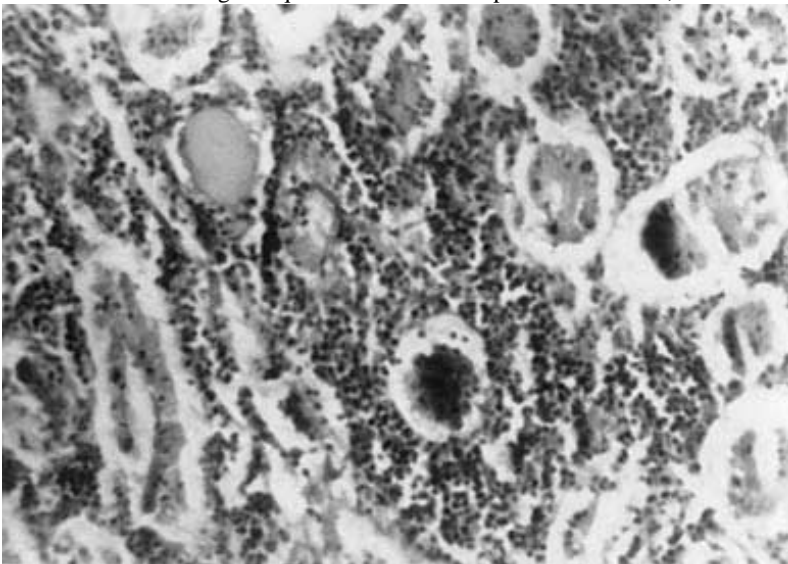


Fig. 4. Marked mononuclear cell infiltration around a glomerulus whose capillary tuft is shrunken. Tubules show necrosis in epithelial linking. H&E;

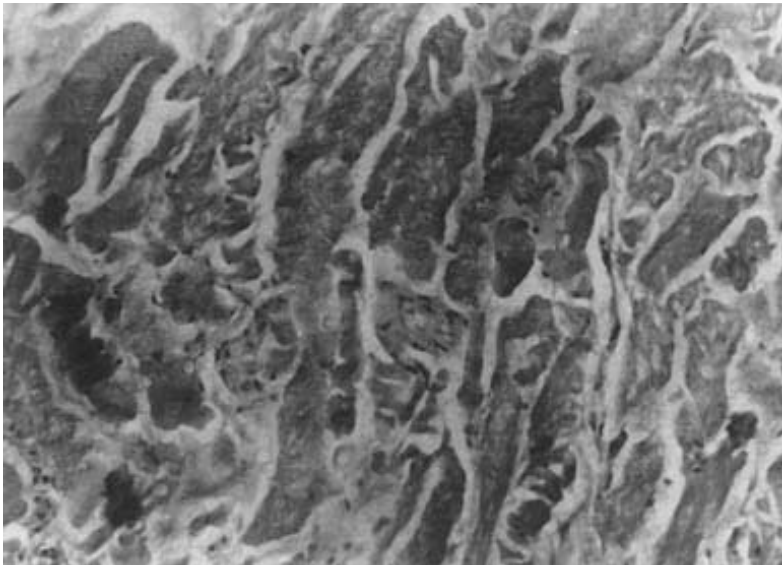


Fig. 5. Muscle tissue of Indian carp exposed to HCH (1.73 ppm) showing thickening and separation of muscle bundles due to intramuscular oedema. H&E; 400.

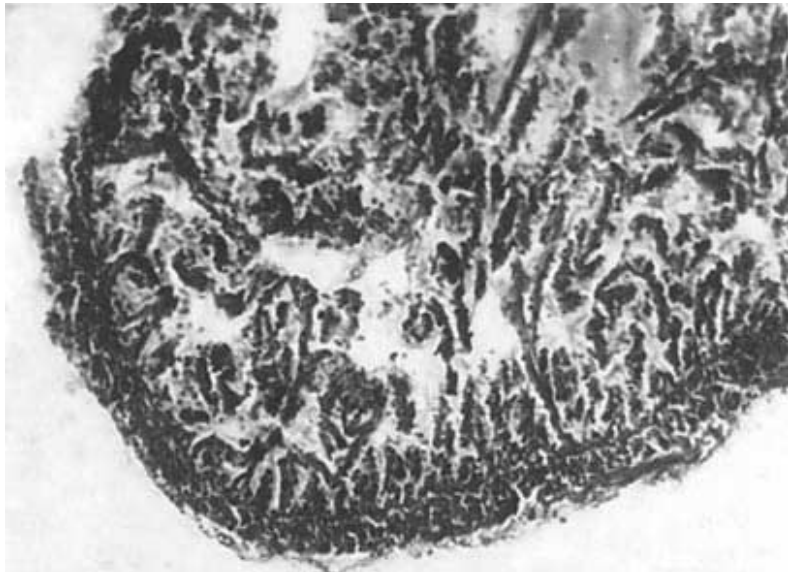


Fig. 6. Heart of Indian carp exposed to HCH (1.73 ppm) showing thickened pericardial sac with infiltrating leucocytes. H&E; 200.

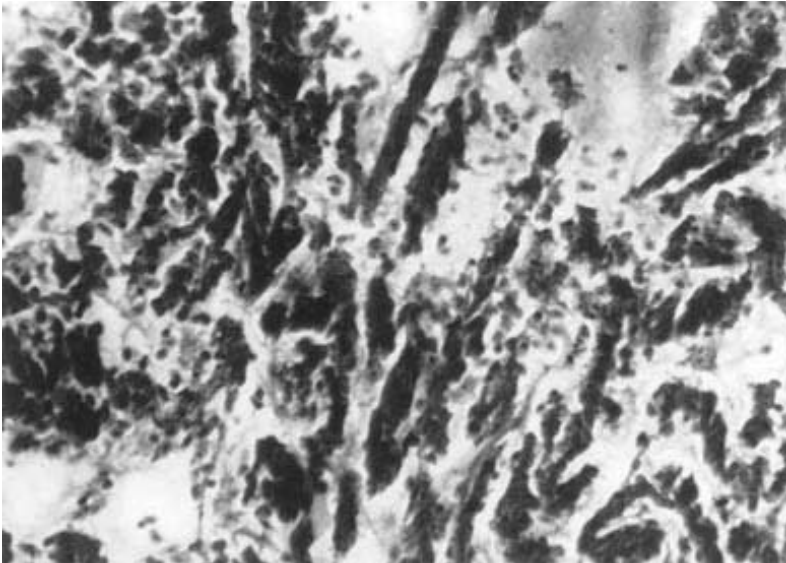


Fig. 7. Heart of Indian carp exposed to (1.73 ppm) HCH showing fragmentation of myocardial muscle fibres with extensive infiltration of polymorphs, mononuclears and macrophages. H&E; 400.

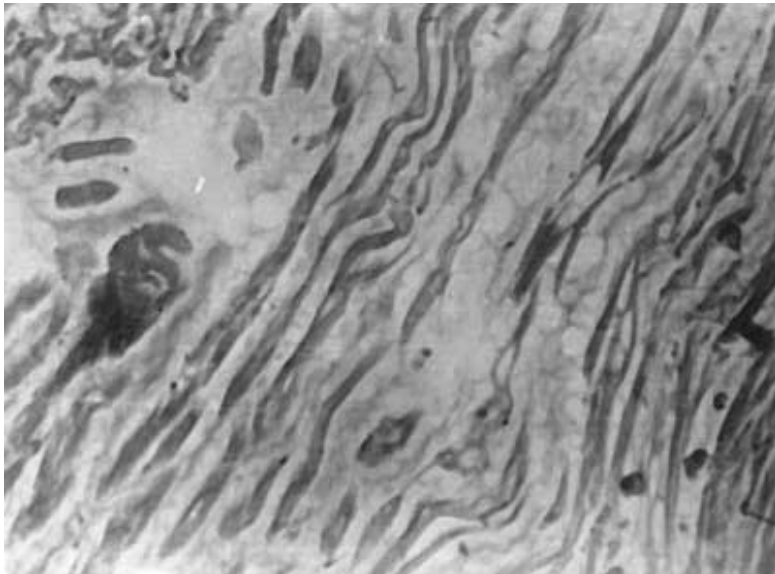


Fig. 8. Heart of Indian carp - accumulation of oedema fluid in atrium muscle bundle exposed to HCH (1.73 ppm). H&E; 400.



macrophages (Fig. 7). At the atrium, muscle bundles were separated by an accumulation of oedema fluid (Fig. 8).

*Brain* - In cases of 0.35 ppm exposure, cerebrum showed mild vacuolar changes with empty spaces which appeared as "moth eaten" areas, whereas at 1.73 ppm exposure severe necrosis of neuronal cells of cerebrum was evident, which indicated loss of Nissl substance. Moderate swelling of pyramidal cells were seen with occasional accumulation of glial cells which in places formed microglial nodules.

## Discussion

The liver is the primary organ for detoxication of organic xenobiotics. Wide varieties of insecticides and other toxic by-products tend to accumulate in high concentrations within it (METELEV et al., 1971) and the organ suffers harmful effects. HINSEN et al. (1971) studied fish exposed to pesticides under laboratory conditions and observed that the liver contained highest pesticide concentration. KING (1962) found many small vacuoles in hepatic cells in brown trout fry and adult guppies exposed to 0.0032 to 3.2 ppm DDT. According to him, this might be related to resorption of fatty yolk by the young trout. It appears to be a general feature of the liver of intoxicated fish that the degree of structural heterogeneity is enhanced with increasing concentrations of the toxicant (HAWKES, 1980). NARAYAN and SINGH (1991) observed extensive degeneration of cytoplasm with pyknosis of nuclei and loss of glycogen in liver tissue of *Heteropneustes fossilis* while subjecting them to acute thiodan toxicity. Similar changes were recorded in our present study, with HCH at higher concentration.

Tissue changes in liver are linked with histological abnormalities of kidney and gill. Once absorbed, toxicant is transported by blood circulation to liver for transformation and/or storage, and if transformed in the liver it may be excreted through the bile or pass back into blood for possible excretion by kidney or gill (LINDSTOMA-SEPPA et al., 1981). GUPTA and DALELA (1987) reported histological changes in kidney of *Notopterus notopterus*, exhibiting degeneration and dissolution of epithelial cells of renal tubules, hypertrophy and necrosis following subtle exposure to phenolic compounds. Similar observations were made by CSEPAI (1978) in *Cyprinus carpio* chronically exposed to Anthio 40 EC, Satox and Basuden 10G, the organochlorine and organophosphate compounds. Interestingly, most of the alterations in our cases were seen in the tubular cells rather than in the glomeruli, which were spared. Moderate to marked cellular infiltrations comprised mostly of mononuclear cells were

discernible in the interstitium, which might be explained as a defence mechanism in the fish to counter toxic metabolites.

Several authors have reported histopathological changes in the gill tissue of fish exposed to miscellaneous pesticides (LOWE, 1964; ELLER, 1971; JAUCH, 1979; NOWAK, 1992; RIJJOHN and JAYABALAN, 1993). In most cases histological changes were characterized by damage in the epithelial cells and/or hyperplasia, lamellar swelling, telangiectasis and aneurysm. The diagnosis values of these observation are limited by the fact that similar changes have been recorded in fish from natural environments, and have been reported to be caused by bacterial and nutritional gill disease and ammonia toxicity (RIBELIN and WALSH, 1975). The change in gill tissues found in the present experiments were mild to moderate congestion of the primary lamellae and hyperplasia of branchial plates (0.35 ppm exposure). The changes were indicative of diminished oxygen supply to the test fish, resulting in hypoxic respiratory responses. Although not lethal, gill damage caused by environmental pollutants is important from the aspect of morbidity as it retards growth and affects reproduction.

As with gills, skin and muscle tissue come into close contact with pollutants dissolved in water. Hence, reactions in the skin cells were spontaneous. The fish showed an increased level of mucous over the body surface, which was reflected by the hyperplastic glandular cells in the dermis of exposed fish. The concomitant appearance of inflammatory cells were indicative of a secondary defence mechanism of the body.

Separation of muscle bundles and intracellular oedema were an interesting observation. Initial stimulus of HCH can induce hyperactivity and excitability in animals, leading to a release of lactic acid and subsequent muscular fatigue. All these changes were clearly evident as clinical signs at the initial stage of the experiment and were subsequently reflected through histopathological changes in muscle and brain tissue (DAS, 1998).

Changes in the pericardium as well as the myocardium was spectacular, with severe myocardial changes characterized by fragmentation of myofibrils and cellular infiltrations. After passing through the blood vascular system the toxic substance could have targeted the cardiac tissue, causing extensive damage.

Changes associated with the brain to subtle exposure of HCH are not reported in the available literature. The present experimental trials revealed that HCH may also be neurotoxic, as evidenced by the histopathological changes characterized by vacuolation of brain parenchyma and moderate swelling of pyramidal cells of the cerebrum.

Vacuolation may have been due to glycolysis leading to microsomal and mitochondrial dysfunctions. Loss of Nissl substances and glial cell reaction, with evidence of glial nodule formation in places, were proof of the neurotoxic nature of the chemical.

#### Acknowledgements

The authors gratefully acknowledge the assistance extended by Dr. S. Ayyappan, Director CIFA, Kausalyaganga, Bhubaneswar for providing facilities for undertaking the studies. The senior author is also grateful to the Indian Council of Agricultural Research, New Delhi, for financial assistance awarded as a fellowship for carrying out the research.

#### References

- ANONYMOUS (1985): Standard methods for the examination of water sewage and industrial waters. Am. Publ. Health Org. (10<sup>th</sup> ed.) NewYork. pp. 522-532.
- BHATIA, H. L. (1971): Toxicity of some insecticides to *Cirrhinus mrigala* (Ham.) and *Colisa faciatia* (Bloch and Schneider). J. inland Fish. Soc. India. 2, 114-116.
- BRUNO, D. W., A. E. ELLIS (1988): Histological effects in Atlantic salmon, *Salmo salar* L. attributed to the use of tributiltin antifoliant. Aquaculture. 72, 14-20.
- COPE, O. B. (1966): Contamination of the freshwater ecosystem by pesticides. J. Appl. Ecol. 3, 33.
- CSEPAI, F. (1978): Histological detectable dystrophies in the carps kidney exposed to chronic effect of some pesticides. Magy. Allatorv. Lapja. 33, 55-58.
- DAS, B. K. (1998): Studies on the effect of some pesticides and commonly used chemicals on Indian major carps and their ecosystem. Ph.D. Thesis. Submitted to Orissa University of Agriculture and Technology. Bhubaneswar. Orissa.
- ELLER, E. E. (1971): Histological lesions in cutthroat *Salmo clark* exposed chronically to the insecticide endrin. Am. J. Pathol. 64, 321-336.
- GHOSH, T. K., S. K. CHATTERJEE (1989): Influenca of nuvan on the organic reserves of Indian freshwater murrel *Channa punctatus*. J. Environ. Biol. 10, 93-99.
- GUPTA, A. K., R. C. DALELA (1987): Kidney damage in *Notopterus notopterus* (Pallus) following exposure to phenolic compounds. J. Environ. Biol. 8, 167-172.
- HAWKES, J. W. (1980): The effect of xenobiotic on fish tissues: Morphological studies. Fed Proc. 39, 3230-3236.
- HINSEN, D. J., P. R. PARRISH, J. I. LOWER, A. J. WILSON JR., P. D. WILSON (1971): Chronic toxicity uptake and retention of Aroclor 1254 in two estuarine fishes. Bull. Environ. Contam. Toxicol. 6, 113.
- JAUCH, D. (1979): Gill lesions in Cichlid fishes after intoxication with the insecticides Fenthion. Experimentia. 35, 371-372.
- KING, S. F. (1962): Some effects of DDT on the guppy and the brown trout. U.S. Fish Wildlife Serv. Spec. Sci. Res. Fish. 20, 399.
- KLICK MEYER, R., H. STEINHART (1989): On the distribution of PCB congeners and hexachlorobenzene in different tissues of DAB (*Limanda limanda*) from the north sea. Chemosphere 19, 1309-1320.
- LINDSTOMA-SEPPA, P., V. KOIVUSSRI, D. O. HANNINEN (1981): Extrahepatic xenobiotic metabolism in north European freshwater fish. Comp. Biochem. Physiol. 69, 291.
- LOWE, J. I. (1964): Chronic exposure to *Leiostomus xanthurus* L. to sublethal concentration of toxophene in sea water. Trans. Amer. Fish. Soc. 93, 396-399.

B. K. Das and S. C. Mukherjee: A histopathology of carp  
(*Labeo rohita*) exposed to hexachlorocyclohexane

- MERCY, T. V. A., B. MADHUSODANA, J. R. NAIR (1996): Pesticide induced histological changes in juveniles of *Channa marulius*. Fourth Ind. Fisheries Forum. pp. 81.
- METELEV, V. V., A. L. KANAEV, N. G. DIASOKHVA (1971): Water toxicity. Amerind Publishing Co. Pvt. Ltd. New Delhi.
- MUKHOPADHYAY, M. K., B. B. GHOSH, H. C. JOSHI (1987): Biomonitoring of pollution in the Hoogly estuary by using *Rita rita* as test fish. J. Environ. Biol. 8, 297-306.
- NARAYAN, A. S., B. B. SINGH (1991): Histopathological lesions in *Heteropneustes fossilis* subject to acute thiodan toxicity. Acta Hydrochem. Hydrobiol. 19, 235-243.
- NOWAK, B. (1992): Histological changes in gills induced by residue of endosulfan. Aqua. Toxicol. 23, 65-84.
- RAZANI, H., K. NANBA, S. MURACHI (1986): Acute toxicity effect of phenol on zebra fish *Brachydanio rerio*. Bull. Jap. Soc. Sci. Fish 52, 1547-1557.
- RIBELIN, W. E., A. H. WALSH (1975): The pathology of pesticide poisoning. In: The Pathology of Fishes (Ribelin, W. E. et al.) The University of Wisconsin Press. pp. 515-557.
- RIJJOHN, K., N. JAYABALAN (1993): Sublethal effect of endosulfan on the histology and protein pattern of *Cyprinus carpio* gill. J. Appl. Ichthyology. 9, 49-56.
- THAIN, J. E., P. MATTHIESSEN, S. BIFIELD (1990): The toxicity of DDVP to some marine organisms. Copenhagen-ICES. pp. 15.

Received: 8 February 1999

Accepted: 18 April 2000

---

**DAS, B. K., S. C. MUKHERJEE: Histopatološko istraživanje šarana (*Labeo rohita*) izloženog heksaklorcikloheksanu. Vet. arhiv 70, 169-180, 2000.**

**SAŽETAK**

Indijski šarani (*Labeo rohita*) su bili izloženi 1/10 i 1/5 sub-letalnih doza heksaklorcikloheksana tijekom 45 dana pokusa. Na kraju pokusa ribe su bile žrtvovane da se pod svjetlosnim mikroskopom promatraju promjene zbog toksičnosti. Histopatološki su istraženi: jetra, bubreg, škrge, koža, mišić, srce i mozak. U jetri su uočeni nabreknuti hepatociti s difuznom nekrozom i nabreknute krvnih žila. Lumeni bubrežnih kanalića su bili prošireni s izraženim nekrotičnim. U škragama je nađeno spajanje primarnih lamela, punokrvnost krvnih žila, i hiperplazija škržnih ploča. Osrčje je bilo umjereno zadebljano i obilno infiltrirano leukocitima. U mozgu je nađena degeneracija neurona s gubitkom Nisslove tvari, te su nađeni mikroglijalni čvorići.

**Ključne riječi:** indijski šaran, *Labeo rohita*, heksaklorcikloheksan, histopatologija

---