

The incidence and distribution of radiographic changes in digital region of stud bulls without lameness

Hrvoje Capak¹, Branimir Škrilin¹, Ana Javor¹, Ivan Folnožić², Mirta Vučković³
and Zoran Vrbnac¹

¹ Department of Radiology, Ultrasound Diagnostic and Physical Therapy, Faculty of Veterinary Medicine, University of Zagreb, Zagreb, Croatia

² Clinic for Obstetrics and Reproduction, Faculty of Veterinary Medicine, University of Zagreb, Zagreb, Croatia

³ Clinic for Surgery, Orthopaedics and Ophthalmology, Faculty of Veterinary Medicine, University of Zagreb, Zagreb, Croatia

CAPAK, H., B. ŠKRLIN, A. JAVOR, I. FOLNOŽIĆ, M. VUČKOVIĆ, Z. VRBANAC: The incidence and distribution of radiographic changes in digital region of stud bulls without lameness. Vet. arhiv 94, 1-10, 2024.

ABSTRACT

Joint disease has a high correlation with bull reproductive failure at semen collection centers or in natural breeding programs. The majority of changes involve the digital region, with various etiologies and pathomorphologies. An X-ray examination is often indicated, but has not become a routine procedure in bovine practice. The aim of our research was to determine radiographically visible changes in the digital region and determine their anatomical distribution in stud bulls that do not show clinical signs of lameness. To the best of our knowledge, this is the first *in vivo* radiographic study of the digital region in Simmental stud bulls. The study included 30 adult Simmental stud bulls in breeding condition. Five (16.66%) bulls had no changes on their digits, and 25 (83.33%) had different groups of changes on their digits. The anatomical site of occurrence and the frequency of pathological changes on each individual digit were determined. In 76% of bulls, changes are visible on both the forelimbs and hindlimbs. Mostly radiographic findings of changes in the digital region in stud bulls without clinical signs of the disease correspond to chronic degenerative changes in their bones and joints, but they do not have any significant influence on the health status or semen production of stud bulls. However, the distribution of radiographic findings in these stud bulls does not correspond with the previously described distribution in other categories of cattle.

Key words: stud bull; Simmental breed; radiography; digits

*Corresponding author:

Assist. Prof. Hrvoje Capak, PhD, DVM, Department of Radiology, Ultrasound Diagnostic and Physical Therapy, Faculty of Veterinary Medicine, University of Zagreb, Heinzelova 55, 10000 Zagreb, Croatia, phone: + 385 91 2390205, e-mail: hcapak@vef.hr; hcapak@vef.unizg.hr

Introduction

Diseases of the hooves have various etiologies and pathomorphologies and, in addition to clinical examinations, an X-ray examination is often indicated (WEAVER, 1997; ŠEHIĆ et al., 2003). When lameness occurs, survey radiography in at least two imaging projections is very important for the differential diagnosis of changes in the bones and joints in cattle (MURPHY et al., 1975; WEISBRODE et al., 1982; PHARR, 1985; BARGAI et al., 1992; O'BRIEN and BILLER, 1996; TROSTLE et al., 1997; MEIMANDI-PARIZI and RADDANIPOUR, 2005; MEIMANDI-PARIZI and SHAKERI, 2007). At the same time, technical limitations and economic factors are certainly more pronounced than in the case of small animals (WEAVER, 1997), so this has not yet become a routine procedure in bovine practice (KOFLEK et al., 2014).

Many authors have established a connection between various pathological changes in the hooves, determined by clinical or postmortem examinations, and pathomorphological radiographic events (BAILEY, 1985; TROSTLE et al., 1997; ŠEHIĆ et al., 2003; MEIMANDI-PARIZI and RADDANIPOUR, 2005; MEIMANDI-PARIZI and SHAKERI, 2007).

The majority of bovine X-rays involve the digital region - the distal part of the metacarpus and metatarsus up to the distal phalanges (coffin bone), as numerous diseases affect this area (PHARR, 1985; PHARR and BARGAI, 1997; ŠEHIĆ et al., 2008).

The most commonly used and simple representation of the digital region is the dorsopalmar or dorsoplantar imaging projection. This image clearly shows the hoof, the middle and proximal phalanx and the interphalangeal joints without the superposition effect, and is sufficient for the correct diagnosis of many diseases (BARGAI, 1993; PHARR and BARGAI, 1997; VERSCHOOTEN et al., 2000). The proximal and distal sesamoid bones are superimposed with the distal part of the metacarpus, or the metatarsus and the distal part of the middle phalanx. The purpose of X-ray imaging of the distal parts of cattle limbs is to determine the type and age of changes, and link them to anamnestic data (PHARR and BARGAI, 1997).

Degenerative joint disease (DJD) has a high correlation with bull reproductive failure at semen collection centers or in natural breeding programs (PERSSON et al., 2007). *Impotentia coeundi*, one of the causes of bull infertility, is the inability to copulate caused by factors such as locomotor system diseases (FJELDASS et al., 2007; MOTTA et al., 2017).

In X-ray examinations of the distal parts of cattle limbs, chronic reactive changes in the periosteum (osteophytes, enthesophytes or exostoses) and infections (osteomyelitis) or inflammatory bone changes (osteitis) are most common (BARGAI, 1987; BARGAI et al., 1992; VERSCHOOTEN et al., 2000). Osteophytes on articular surfaces or enthesophytes on tendon and muscle insertions can be a common incidental finding in animals that do not show signs of lameness during clinical examination (BAILEY, 1985; PHARR and BARGAI, 1997).

BARGAI (1987) reviewed the X-ray archive of cattle and described reactive periosteal changes according to the place of occurrence, most often on the phalanges of the digits, then the metacarpus and metatarsus, less often on other bones.

In addition to the radiographically visible changes described on slaughter samples of macroscopically changed hooves, calcification of soft tissues, rotation of the phalanx, bone deformation, ankylosis of the digital joints, arthritis, dislocation of the palpebral bone and fractures were not very common, while osteosclerosis was found as an isolated change (MEIMANDI-PARIZI and SHAKERI, 2007). By recording the distal parts of the limbs of cattle with macroscopically changed hooves, periosteal reactions and arthritis were recorded more often on the forelimbs, while the most frequent occurrence of degenerative joint disease was on the hind limbs. Approximately 90% of inflammatory and degenerative changes are localized in the distal interphalangeal joint (MEIMANDI-PARIZI and SHAKERI, 2007). An *in vivo* study was conducted on beef zebu stud bulls, including the carpi, tarsi and interphalangeal joints. They used the semen collecting bulls with some clinical changes, and found a high correlation

of age and body weight with the severity of radiographic injuries (MOTTA et al., 2017).

The aim of the research was to determine visible changes in the digital region radiographically, and their anatomical distribution in stud bulls that do not show clinical signs of lameness. To the best of our knowledge, this is the first *in vivo* radiographic study of the digital region in Simmental stud bulls, and report of changes without clinical influence.

Materials and methods

The research was approved by a decision of the Committee for Ethics in Veterinary Medicine, Faculty of Veterinary Medicine, University of Zagreb (class: 640-01/14-17/13, reg. number: 251-61-01/139-14-2) on February 19, 2014.

In this research, 30 adult Simmental stud bulls in breeding condition were used. At the time of conducting the research, the sample represented 51.72% of the population in the Republic of Croatia (CAA, 2013). The average age of the bulls was 5.73 years (in a range from 21.2 to 138.3 months), the average body weight was 1094 kg (820-1350 kg). At the time of the research, the bulls were in the regular process of semen collecting for the market at the Centre for Livestock Reproduction in Križevci, Croatia. During the research, the bulls were not exposed to unnecessary stressful activities, unusual manipulation, transport or permanent displacement from their housing.

During the routine correction of their hooves, an inspection and palpation examination of the claw was performed. Afterwards, the animals were examined while standing and walking on soft and hard surfaces. According to the normal orthopedic findings established, X-ray imaging of the digital region of each limb was performed in dorsopalmar or dorsoplantar and lateromedial projection.

A mobile X-ray device (JOP CORPORATION: PORTA 1030, Toshiba, Japan) was used for imaging on standard X-ray film (RTG MXG film, CARESTREAM HEALTH Inc., USA), measuring 24 x 30 cm. During recording, customized exposure elements were used in the range of 44 – 52 kV and 12 – 16 mAs. During the X-ray imaging all prescribed ionization protection protocols were observed. The

films were developed in an automatic X-ray film processor (PROTEC – OPTIMAX STANDARD, PROTEC Medizintechnik GmbH&CO, Oberstenfeld, Germany) at the Department of Radiology, Ultrasound Diagnostics and Physical Therapy, of the Faculty of Veterinary Medicine, University of Zagreb.

By interpreting the X-ray images of the digits of each limb taken, the existence was established of radiographically visible changes in the metacarpophalangeal and metatarsophalangeal joints, in the bony structures of the proximal, middle and distal phalanges of the digits, the distal sesamoid bone, and the interphalangeal joints.

The type of radiographically visible pathological changes was determined with regard to the etiology of the process and distributed into groups of chronic reactive processes, traumatic events or healed infectious conditions.

Chronic reactive processes differ by anatomical position - inside the joint capsule (intra-articular) and on the periosteum (enthesophytes, periostoses).

The anatomical site of the occurrence and the frequency of pathological changes on each individual digit were determined. The anatomical areas of the region of the medial and lateral digit of cattle shown on X-rays were divided into: the metacarpo/metatarsophalangeal joint, proximal phalanx, proximal interphalangeal joint, middle phalanx, distal interphalangeal joint and distal phalanx. Proximal and distal sesamoid bones were not taken as a separate site of radiographically visible changes.

X-ray findings of chronic reactive changes with regard to the nature of occurrence and site of occurrence were divided into:

Joint area – signs of osteoarthritis (degenerative joint disease), which include osteophytes on the edges of the joint surfaces, narrowing of the joint fissure, and subchondral sclerosis of the proximal or distal bone in the joint.

Periosteum – exostoses (smaller bony accumulations), periostoses (abundant reactive periosteal accumulations) and enthesophytes (these basically etiologically correspond to osteophytes, but they appear as bony spur growths at the insertions of tendons and ligaments, outside the joint space).

X-ray findings of visible bone changes, which comprise several heterogeneous anatomical elements in the bone macrostructure (periosteum, compact bone, cortex and medulla), included: healed inflammatory changes (osteitis) or infectious conditions (osteomyelitis). In the case of healed inflammatory or infectious processes, radiographically visible signs in the form of bone swellings of varying degrees remain permanently visible on the bones.

By observing the findings of radiographically visible changes on the digits of all the limbs of one animal, the bulls were divided into two groups: Group 1 - without radiographically visible changes on the digits and Group 2 - with radiographically visible changes on the digits.

Within each group, the average age and weight of bulls without prominent and with prominent radiographically visible changes was determined.

The frequency of changes found in the digital joints (metacarpophalangeal, metatarsophalangeal, proximal interphalangeal and distal interphalangeal joints), on the periosteum (proximal, middle and distal phalanges) and in the bone macrostructure (proximal, middle and distal phalanges) was expressed according to the positions of the limbs (forelimbs and hindlimbs) and digits (third and fourth digit, i.e. the medial and lateral claw). Considering previous knowledge about similarities or possible differences, and the level of clinical importance in this examination, the division into left and right limbs was not included as a criterion.

The digits of all limbs, with regard to the presence of radiographically visible changes, were classified within the following groups: negative findings (digits without radiographically visible changes), with radiographically visible changes in the joints, with radiographically visible change on the periosteum, with radiographically visible changes in the bone structure, and with several different radiographically visible changes on the same digit.

The group with several different radiographically visible changes included digits on which several types of radiographically visible changes could be observed, described as changes in the joints, changes in the periosteum, and changes in the bones, in different anatomical positions of the digit.

The analysis of the collected data was carried out using the statistical software Statistica v.12.5 (Statistica, StatSoft, SAD, 2014.). For each researched quantitative variable by group, the normality of data distribution was tested using the Kolmogorov-Smirnov test. The arithmetic mean (\bar{X}) and standard deviation (SD) were used for the quantitative and frequency for the qualitative variables in question.

The analysis of variance (ANOVA) tested the significance of the differences between the measurements of the claws according to the groups with regard to the findings of radiographically visible changes in the digital region. Individual differences between diagnoses were tested with the Tukey HSD test. The significance of the differences was tested at the $P < 0.05$ level.

Results

The radiographic findings of bull digits are presented with regard to the group of radiographically visible changes (digits without changes, digits with joint changes, digits with periosteal changes, digits with bone macrostructure changes and digits with multiple changes on the same digit). X-ray findings of changes on the digits (Fig. 1, Fig. 2, Fig. 3 and Fig. 4) are described with the corresponding X-ray image.

Out of the total number of bulls ($n=30$), five (16.66%) bulls had no changes on their digits, and 25 (83.33%) had radiographically visible changes on their digits.

Table 1 shows the age and body weight within the group of bulls, without or with radiographically visible changes. The average age of bulls without changes on the digits was 2.43 years, and their body weight 938.0 kilograms. In the group of bulls with radiographically visible changes on the digits, the average age was 6.40 years, and the average body weight 1125.2 kilograms.

The distribution of radiographically visible changes with regard to the forelimbs and hind limbs of 25 bulls within the three groups of changes (on the joints, on the periosteum and on the bones) is shown in Table 2. In the majority

of bulls (76%), changes were visible on both the forelimbs and hindlimbs. In bulls with diagnosed changes exclusively on the forelimbs or hindlimbs, a significantly higher number of changes was found

on the forelimbs (20% of bulls with changes). Of the radiographically visible changes, the most changes were found in the joints, then in the periosteum, and the least in the bone structure.

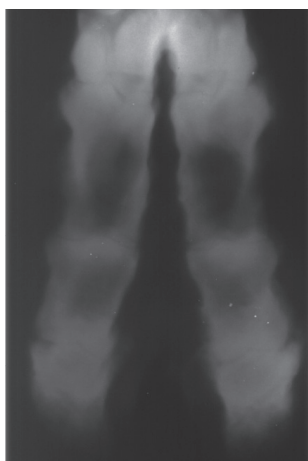


Fig. 1. Digital region of the pelvic limb of a Simmental bull in DP view

The narrowing of the joint space in the distal interphalangeal joints of the 3rd and 4th digit is visible. Medially, at the height of the distal interphalangeal joints, periarticular bony swellings were found (degenerative joint disease).

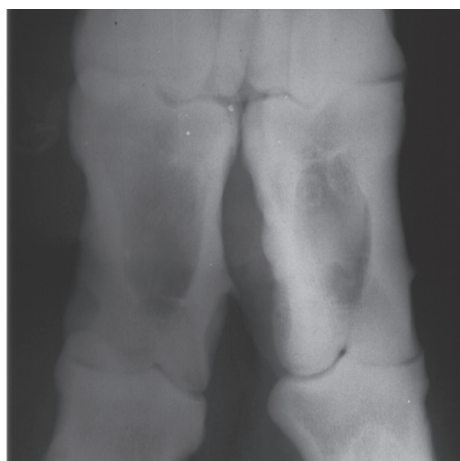

Fig. 2. DP projection of the digital region of the forelimb of a Simmental bull

On the medial side of the proximal phalanx of the 3rd digit, a thorny enthesophyte sized 3 mm is differentiated, while on the medial edge of the proximal phalanx of the 4th finger, a mild periosteal swelling (periostosis).

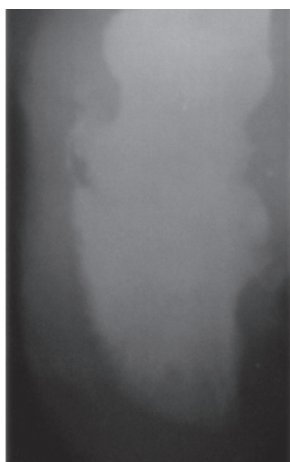


Fig. 3. In the distal part of the middle phalanx, an area of prominent bony swelling is differentiated laterally. In the distal part of the distal phalanx the radiolucent area, indicating a previous osteolytic process (osteomyelitis).

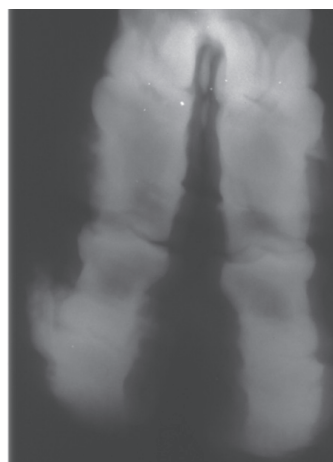


Fig. 4. DP projection of the digital region of the hind limb of a Simmental bull

On the 3rd finger of the right hind limb, there is extensive bone swelling periarticularly in the distal interphalangeal joint, with prominent narrowing of the articular space. Intraarticular and periarticular bone swellings are distributed medially and laterally (degenerative joint disease). A periosteal reaction (periostosis) extends laterally along the entire length of the proximal phalanx.

The distribution of radiographically visible changes with regard to the digits (claws) of the forelimbs and hindlimbs within the three groups of changes (on the joints, on the periosteum and on the bones) is shown in Table 3.

When comparing the digits of the forelimbs, a greater number of changes was found on the third digit (medial claw), while on the hindlimbs, an equal distribution of changes was observed on both digits (3rd and 4th digit). When comparing the

medial and lateral claws of the forelimbs and hindlimbs, significantly more changes were observed in the digits of the forelimb in both digits.

Within the groups of digits with radiographically visible changes, the distribution of changes on the joints and on the periosteum of the digits of the forelimbs and hindlimbs was equal, and the number of changes in the macrostructure of the bone in the digits of the hindlimbs was greater than in the digits of the forelimbs.

Table 1. Age and body weight of bulls without or with radiographically visible changes in the digits (claws)

Group of bulls	Age (years)			Body weight (kilograms)		
	\bar{X}	$X_{min.}$	$X_{max.}$	\bar{X}	$X_{min.}$	$X_{max.}$
Without radiographically visible changes	2.43	1.76	2.84	938.0	820.0	1140.0
With radiographically visible changes	6.40	1.84	11.53	1125.2	835.0	1350.0

Table 2. The frequency of radiographically visible changes in the digits regarding to the forelimbs and hindlimbs

Limbs (3rd or 4th digit)	Number of bulls	Radiographically visible changes		
		On the joints	On the periosteum	On the bones
Forelimbs	5 (20%)	16	5	1
Hindlimbs	1 (4 %)	1	3	0
Forelimbs and hindlimbs	19 (76 %)	141	70	12
Total	25 (100 %)	158	78	13

Table 3. The frequency of radiographically visible changes regarding to the digits (claws) of the forelimbs and hindlimbs

Limbs	Digits	Radiographically visible changes on the digits			
		On the joints	On the periosteum	On the bones	Total
Forelimbs	3rd digit (medial claw)	49 (67.12 %)	21 (28.76 %)	3 (4.10 %)	73 (100 %)
	4th digit (lateral claw)	42 (63.63 %)	23 (34.84 %)	1 (1.53 %)	66 (100 %)
Hindlimbs	3rd digit (medial claw)	35 (62.50 %)	17 (30.35 %)	4 (7.14 %)	56 (100 %)
	4th digit (lateral claw)	32 (59.25 %)	17 (31.48 %)	5 (9.25 %)	54 (100 %)

Table 4. Age and body weight of bulls regarding to radiographically visible changes observed on the digits

Radiographically visible findings on the digits	Age of bulls (years)			Body weight of bulls (kg)		
	\bar{X}	$X_{\min.}$	$X_{\max.}$	\bar{X}	$X_{\min.}$	$X_{\max.}$
No changes (n = 80)	3.46	1.76	10.19	1004.6	820.0	1260.0
Multiple changes (n = 81)	7.97	1.84	11.53	1153.2	835.0	1350.0
Changes on joints (n = 73)	5.87	1.84	11.53	1126.4	835.0	1350.0
Changes on the periosteum (n = 6)	4.31	2.28	7.87	1080.8	1000.0	1045.0

Table 4. shows the average age and body weight of the bulls with regard to the digits of all limbs classified into the corresponding group (without changes, with several different changes on the same digit, with changes on the joints, with changes on the periosteum). The arithmetic mean, minimum and maximum values are shown.

Discussion

This paper examines radiographically visible changes in the digital region of Simmental stud bulls without clinical signs of lameness. The frequency and distribution of several types of etiologically different pathomorphological and radiographically visible changes on the digits of stud bulls were determined.

X-ray examination in cattle is most often performed in the area of the distal parts of the limbs, since the largest number of pathological conditions that appear affect the area distal to the carpal or tarsal joint (PHARR and BARGAI, 1997).

The prevalence of X-ray examinations of the digital region corresponds to the occurrence of macroscopically visible pathological conditions which, especially in dairy cows, are most prevalent in the area of the hooves (NOORDSY, 1994). A significantly greater number of hoof diseases appear on the hooves of the hindlimbs, where the lateral claw of the hindlimb is biomechanically under more load than the medial one, which increases the surface of the horn and is suitable for the development of many hoof diseases.

Investigating radiographically visible changes in the digital region of macroscopically changed claws, recorded clinically or postmortem, a connection

was determined between irregularities and diseases of the horn of the hoof with X-ray findings on the digits (BARGAI, 1987; O'BRIEN and BILLER, 1996; ŠEHIĆ et al., 2003; MEIMANDI-PARIZI and RADDANIPOUR, 2005; MEIMANDI-PARIZI and SHAKERI, 2007).

With regard to the etiology of their occurrence, the described changes in the digital region diagnosed radiographically can be divided into groups of traumatic changes, infectious changes and chronic degenerative changes in joints or bones.

Chronic reactive changes can occur spontaneously in older animals, that is, they are caused by an earlier traumatic event on the anatomical area in which they appear (joint or periosteum). The appearance of reactive changes in the joints indicates the instability of the joint connection due to various causes. Osteophytes on articular surfaces or enthesophytes on tendon and muscle insertions can be a common incidental finding in animals that do not show signs of lameness during clinical examination (BAILEY, 1985; PHARR and BARGAI, 1997).

In the examinations of altered claws described previously, a significant number of periosteal reactions and exostoses, bone deformations and

degenerative joint changes were found by X-ray examination. The largest number of changes was found on the digits of the hindlimbs, which is not in accordance with the results obtained in this study.

In the observed Simmental stud bulls, the X-ray findings corresponded to the anamnestic data and the clinical examination in which no diseases or abnormalities of the hooves were found. Thus, the findings of the clinical examination performed regarding the absence of traumatic injuries to the digits, rotation of the phalanges, or acute inflammatory and infectious conditions on the digits of the examined bulls, were confirmed.

The largest number of radiographically visible changes corresponded to degenerative osteoarthritic changes. The results obtained coincide with earlier research regarding the frequency of radiographically visible pathological changes (osteoarthritis) in the distal interphalangeal joint of all digits. Periosteal reactions of varying extent are most prevalent on the proximal phalanges of the digits of all claws.

The distribution of radiographically visible changes in the digits of the forelimbs and hindlimbs showed that the largest number of animals had changes in both their forelimbs and hindlimbs. However, the distribution of radiographic findings in these stud bulls did not correspond with the previously described distribution of other categories of cattle. Thus, more changes were visible in the digits of the forelimbs (55.8%) compared to the digits of the hindlimbs.

The differences in the findings can be linked to the search for macroscopically changed claws in other studies, where a significantly greater number of diseases and abnormalities appear on the hindlimbs, and their mutual connection has already been proven.

However, the distribution of the load between the forelimbs and hindlimbs, where 60% of the load from the total body weight falls on the forelimbs, shows that in older animals, with significantly higher body weight than other categories of cattle, the greater load can favor the development of reactive bone changes in the digits.

Observing the differences between the "load claws" (OSSENT et al., 1987) and the associated

claws of the same limb, no significant difference was observed in the radiographically visible changes represented on the lateral claw of the hindlimbs compared to the medial claw of the hindlimbs. There was a slightly higher prevalence of radiographically visible changes on the medial claw of the forelimb compared to the lateral one. This regularity of distribution can again be linked to the search of the digits of animals without macroscopically changed hoof horn.

The cause of the appearance of the most frequent reactive changes on the periosteum in the area of the proximal phalanx of the digit can be connected with the dimensions of the proximal phalanx, which is the longest and, in terms of surface, the largest bone of the digit, and at the same time it is positioned on the part of the limb that is often exposed to spontaneous mechanical influences, and bumps into obstacles during movement.

Healed inflammatory or infectious changes in the digital region were rarely found, corresponding to older animals in which bone hypertrophy processes compensated for the loss of bone tissue due to earlier osteolytic processes (osteomyelitis).

The results of our study confirm earlier reports that highlight the importance of maintaining a healthy body weight in stud animals to improve the quality and length of the productive life of adult and elderly bulls due to joint relief (FJELDASS et al., 2007; RADIŠIĆ et al., 2012; MOTTA et al., 2017).

Conclusions

Most of the radiographic findings of changes in the digital region in stud bulls without clinical signs of the disease correspond to chronic reactive changes in bones and joints. Also, they did not have a significant influence on the health status and production of stud bulls. The radiographically observed changes on the digits of stud bulls with macroscopically healthy hooves and their distribution differ from the radiographically observed findings on the digits of cattle with changed hooves. In any study of radiographically visible changes on the digits of bulls without clinical signs of disease, the influence of age and body weight should be taken into the consideration as predisposition factors.

References

- BAILEY, J. V. (1985): Bovine arthritides. Classification, diagnosis, prognosis, and treatment. *Vet. Clin. North Am. Food Anim. Pract.* 1, 39-51.
- BARGAI, U. (1993): Radiology of the bovine foot: An approach for the practitioner. *Veterinary Annual* 33, 62-74.
- BARGAI, U., I. SHAMIR, A. LUBLIN, E. BOGIN (1992): Winter outbreaks of laminitis in dairy calves: aetiology and laboratory, radiological and pathological findings. *Vet. Rec.* 131, 411-414.
<https://doi.org/10.1136/vr.131.18.411>
- BARGAI, U. (1987): The nature and radiographic patterns of periosteal response in the bovine. *Vet. Radiol. Ultrasound* 28, 232-235.
<https://doi.org/10.1111/j.1740-8261.1987.tb00061.x>
- CAA (2013): Croatian Agricultural Agency. Annual Report 2013. Cattle Breeding. (in Croatian).
- FJELDASS, T., O. NAFSTAD, B. FREDRIKSEN, G. RINGDAL, A. M. SOGSTAD (2007): Claw and limb disorders in 12 Norwegian beef-cow herds. *Acta Vet. Scand.* 49, 24.
<https://doi.org/10.1186/1751-0147-49-24>
- KOFLER, J., U. GEISSBÜHLER, A. STEINER (2014): Diagnostic imaging in bovine orthopedics. *Vet. Clin. North Am. Food Anim. Pract.* 30, 11-53.
<https://doi.org/10.1016/j.cvfa.2013.11.003>
- MEIMANDI-PARIZI, A., M. A. SHAKERI (2007): Abattoir study of radiographic changes of bones and joints of digital region in cattle with abnormal claws. *Vet. arhiv* 77, 187-194.
- MEIMANDI-PARIZI, A., M. RADDANIPOUR (2005): Radiographic findings of digital bones and joints in lame cattle of Shiraz area. *Iran. J. Vet. Res.* 6, 54-58.
- MOTTA, G. A., A. M. GOIRARDI, A. F. SABES, E. S. PORTUGAL, R. P. NOCITI, G. M. BUENO, L. C. MARQUES (2017): Clinical and radiographic changes of carpi, tarsi and interphalangeal joints of beef zebu bulls on semen collection regimen. *Arq. Bras. Med. Vet. Zootec.* 69, 1357-1366.
<https://doi.org/10.1590/1678-4162-9474>
- MURPHY, P. A., E. D. WEAVER, J. N. BARRETT (1975): Epiphysitis in beef cattle fattened on slatted floors. *Vet. Rec.* 97, 445-447.
- NOORDSY, J. L. (1994): Foot and Claw Surgery. In: Food animal surgery. (Noordsy, J. L., Ed.), 3rd ed., Veterinary Learning Systems Co., Trenton, New Jersey, pp. 267-277.
- O'BRIEN, R. T., D. S. BILLER (1996): Clinical applications of radiography and ancillary imaging. *Vet. Clin. North Am. Food Anim. Pract.* 12, 263-275.
[https://doi.org/10.1016/s0749-0720\(15\)30447-3](https://doi.org/10.1016/s0749-0720(15)30447-3)
- OSSENT, P., D. J. PETERSE, H. C. SCHAMHARDT (1987): Distribution of load between the lateral and the medial hoof of the bovine hind limb. *Zentralbl. Veterinarmed. A.* 34, 296-300.
<https://doi.org/10.1111/j.1439-0442.1987.tb00283.x>
- PERSSON, Y., L. SÖDERQUIST, S. EKMAN (2007): Joint disorder; a contributory cause to reproductive failure in beef bulls? *Acta Vet. Scand.* 49, 31-45.
<https://doi.org/10.1186/1751-0147-49-31>
- PHARR, J. W. (1985): Ancillary diagnostic imaging. Angiography, Ultrasonography, Scintigraphy and Xeroradiology. *Vet. Clin. North Am. Food Anim. Pract.* 1, 205-212.
- PHARR, J. W., U. BARGAI (1997): Radiology. In: Lameness in Cattle. (Greenough, P. R., A. D. Weaver, Ed.), Saunders Elsevier, Philadelphia, London, Toronto, Montreal, Sydney, Tokyo, pp. 24-40.
- RADIŠIĆ, B., D. MATIČIĆ, D. VNUK, M. LIPAR, I. MAJIĆ BALIĆ, B. ĐITKO, O. SMOLEC, A. ORAK, H. CAPAK, J. KOS (2012): Measurements of healthy and pathologically altered hooves, their interrelation and correlation with body mass in Simmental breeding bulls. *Vet. arhiv* 82, 531-544.
- ŠEHIĆ, M., V. BUTKOVIĆ, D. STANIN, B. ŠKRLIN, B. RADIŠIĆ, J. KOS (2008): Comparison of conventional and digital radiography of phalangeal bone and soft tissue in cattle. Proceedings of the XVIth Congress of the Mediterranean Federation of Health and Production of Ruminants (FeMeSPRum), 22-26 April, Zadar, Croatia, pp. 369-375.
- ŠEHIĆ, M., V. BUTKOVIĆ, J. KOS, D. STANIN, P. BOŽIĆ (2003): Radiographic diagnosis of claw diseases in dairy cows and breeding bulls. Proceedings of the IVth Central European Buiatric Congress, 23-27 April, Lovran, Hrvatska, pp. 359-366. (In Croatian)
- TROSTLE, S. S., R. G. NICOLL, L. J. FORREST, M. D. MARKEL (1997): Clinical and radiographic findings, treatment and outcome in cattle with osteochondrosis: 29 cases (1986-1996). *J. Am. Vet. Med. Assoc.* 211, 1566-1570.
- VERSCHOOTEN, F., D. VERMEIREN, L. DEVRIESE (2000): Bone infection in the bovine appendicular skeleton: a clinical, radiographic and experimental study. *Vet. Radiol. Ultrasound* 41, 250-260.
<https://doi.org/10.1111/j.1740-8261.2000.tb01488.x>
- WEAVER, A. D. (1997): Joint conditions. In: Lameness in Cattle. (Greenough, P. R., A. D. Weaver, Ur.), Saunders Elsevier, Philadelphia, London, Toronto, Montreal, Sydney, Tokyo, pp. 162-179.
- WEISBRODE, S. E., D. R. MONKE, S. T. DODARO, B. L. HULL (1982): Osteochondrosis, degenerative joint disease, and vertebral osteophytes in middle aged bulls. *J. Am. Vet. Med. Assoc.* 181, 700-705.

Received: 14 July 2022

Accepted: 22 July 2022

CAPAK, H., B. ŠKRLIN, A. JAVOR, I. FOLNOŽIĆ, M. VUČKOVIĆ, Z. VRBANAC: Učestalost i distribucija radiografskih promjena u regiji prstiju rasplodnih bikova bez znakova hromosti. Vet. arhiv 94, 1-10, 2024.

SAŽETAK

Bolesti zglobova pokazuju visoki stupanj povezanosti s poremećajima u reprodukciji rasplodnih bikova od kojih se u centrima za umjetno osjemenjivanje prikuplja sperma ili služe u programima za prirodni pripust. Većina promjena na zglobovima pojavljuje se u regiji prstiju, a uključuje patomorfološke promjene različite etiologije. Za dijagnostiku navedenih promjena vrlo je često indicirana radiološka pretraga, koja još uvijek nije rutinska metoda u radu s govedima. Cilj je ovog istraživanja bio utvrditi radiološki vidljive promjene u području prstiju i njihovu anatomsku distribuciju u rasplodnih bikova koji ne pokazuju znakove hromosti. Koliko nam je poznato, ovo je prvo *in vivo* radiološko istraživanje regije prstiju u rasplodnih bikova simentalske pasmine. Uključeno je 30 odraslih bikova u rasplodnoj kondiciji. Kod 5 bikova (16,66 %) nisu pronađene rendgenski vidljive promjene, a kod 25 (83,33 %) pronađene su etiološki različite promjene. Za svaku promjenu definirana je njezina anatomska pozicija nakon čega je utvrđena učestalost patoloških promjena na pojedinačnim prstima. Vidljive promjene na prednjim i stražnjim ekstremitetima opažene se kod 76% istraženih bikova. Većina rendgenski vidljivih promjena u regiji prstiju rasplodnih bikova bez znakova hromosti vezana je uz kronična degenerativna stanja na kostima i zglobovima. Važno je napomenuti da promjene nisu znatnije utjecale na zdravstveno stanje i proizvodnju sperme bikova te da se distribucija promjena u regiji njihovih prstiju razlikuje od prije opisanih promjena u ostalih kategorija goveda.

Ključne riječi: rasplodni bik; simentalska pasmina; radiografija; prsti
