

## Acute deltamethrin intoxication in a cat – a case report

Şükrü Değirmençay

*Department of Internal Medicine, Faculty of Veterinary Medicine, Atatürk University, Erzurum, Turkey*

---

DEĞİRMENÇAY, Ş.: Acute deltamethrin intoxication in a cat – a case report. *Vet. arhiv* 93, 271-278, 2023.

### ABSTRACT

Deltamethrin is a synthetic type II pyrethroid insecticide that is widely used to protect vegetables, fruits and agricultural crops against pests such as mites, ants, beetles and weevils. Moreover, it is used in veterinary practice as an ectoparasiticide, but it is not approved for feline use. To my knowledge, deltamethrin intoxication in cats has never been reported before. For the first time, this report aimed to report clinical, haematological and biochemical changes due to deltamethrin intoxication in a cat. The cat had complaints of involuntary movements and difficulty in standing because the owner sprayed his kittens to treat lice infestation with a watery solution of a pesticide containing deltamethrin, and the mother cat licked its kittens. In the clinical examination of the cat – incoordination, spontaneous contractions, ataxia, hyperesthesia, hypothermia (T: 37.2°C), bradycardia (128/bpm), tachypnea, mydriasis and erosive lesions in the tongue – were detected. Hematologic examination revealed leukocytosis and neutrophilia. Biochemical analysis showed an increase in AST, LDH and CK-MB activities and potassium levels. Given that there is no specific antidote to deltamethrin toxicity, symptomatic treatment was given. Fluid therapy (0.9% NaCl and 5% dextrose solution at a dose of 40 ml/kg, IV) was administered for the elimination of the toxin from the body and coping with septic shock. Diazepam (0.5 mg/kg, IV) was administered to alleviate neurological signs. Enrofloxacin (5 mg/kg, SC) was administered for three days due to sepsis, leukocytosis and neutrophilia. In the treatment of hypothermia, blankets and hot water bottles were used. After this treatment, the cat recovered. This case report, confirms that deltamethrin, like other pyrethroids, is quite toxic to cats, the clinical findings appeared in a short time, and neurological findings, especially choreoathetosis, were dominant. Consequently, this study demonstrated that deltamethrin causes neutrophilia, leukocytosis, hyperkalaemia, and heart and skeletal muscle damage in cats.

**Key words:** deltamethrin; intoxication; neurological findings; cat

---

### Introduction

The title may surprise the reader, since to date, reports of permethrin intoxication in cats have been common, but there have been no report published on deltamethrin intoxication in cats. In this case report, deltamethrin toxicity was detected in a cat. Given that cats are sensitive to products containing permethrin (STEVEN, 2013), I speculated that they could also be sensitive to other pyrethroids,

including deltamethrin, to which they show similar reactions. On this basis, the hypothesis was formed in line with permethrin intoxication, and it was suggested that deltamethrin intoxication could also produce similar clinical, haematological and biochemical alterations, and require a similar treatment protocol.

---

\*Corresponding author:

Şükrü Değirmençay, Department of Internal Medicine, Faculty of Veterinary Medicine, Atatürk University, 25240, Erzurum, Turkey, e-mail: s.degirmencay@atauni.edu.tr

Deltamethrin (DLM) is a broad-spectrum synthetic type II pyrethroid insecticide while permethrin is a type I pyrethroid insecticide. Pyrethroids are synthetic derivatives of natural pyrethrins with a high anti-parasitic effect on mature and larval forms of many parasites from the chamomile plant (*Chrysanthemum cinerariaefolium*) (CHRUSTEK et al., 2018). Pyrethroids are divided into two types, type I and type II, depending on the composition, effect and side effects of the compound (STEVEN, 2013). Exposure to type I pyrethroids causes systemic clinical signs characterized by generalised tremors, hyperesthesia, aggressive behaviour and ataxia (COSTA, 2015). On the other hand, exposure to type II pyrethroids causes incoordination, choreoathetosis, seizures and choreoathetosis-salivation syndrome (characterized by the involvement of skeletal and cardiac muscle and salivary glands) (DORMAN and BEASLEY, 1991).

Deltamethrin is widely used to protect vegetables, fruits and agricultural crops against pests such as mites, ants, beetles and weevils. Moreover, it is used in veterinary practice as an ectoparasiticide against flies, mites, ticks and fleas, to control vector-borne illnesses (MEHLHORN et al., 2011). However, there is no licensed commercial product containing deltamethrin for use in cats. To date, deltamethrin intoxication has not been reported in cats, but there are several reports in rats. According to these studies, deltamethrin intoxication leads to the early symptoms of restlessness, respiratory distress and severe convulsions, which are highly suggestive of stimulation of the central nervous system (CNS). Characterized symptoms, such as choreoathetosis, loss of righting reflex and tonic-clonic convulsions were observed in 3-5 hours following oral administration (CROFTON and REITER, 1987).

Of all pyrethroids, permethrin intoxication is the most reported in cats. Permethrin is a type I pyrethroid with low toxicity in most mammalian species. It is a common ingredient in spot-on solutions used for flea control (BOLAND and ANGLES, 2010). Solutions licensed for use in cats, containing low concentrations of permethrin (0.05-

0.1%) are safe as long as their recommended use is followed. Spot-on solutions used in dogs contain higher concentrations (45-65%) of permethrin and cats' exposure to very small amounts of these products (for example, licking even a drop from a bulb or a used permethrin packet) has fatal consequences (HANSEN et al., 1994). The treatment protocol aims to focus on controlling clinical signs (HAWORTH and SMART, 2012), including rapid seizure control, decontamination, and supportive care during the metabolization and excretion of toxic substances (BOLAND and ANGLES, 2010).

### Case History

A 10-month old, 2.5 kg, unneutered female tabby cat was presented to our hospital with complaints of involuntary movements and difficulty in standing for 3 hours. The owner had prepared a solution with a concentration of 0.24 mg/mL, by adding 24 ml of a deltamethrin-containing pesticide called K-Othrine SC 50<sup>®</sup> to 5 Lt of water and sprayed it on the cat's kittens against intense lice infestation. The owner mentioned that the mother had licked her kittens and after about 5 hours, symptoms of intoxication appeared. The owner force-fed the cat with milk, then presented it to the animal hospital since the nervous symptoms did not resolve. The kittens showed no clinical findings.

The clinical examination of the cat showed: incoordination, generalised muscle spasms, paw flicking, ear twitching, ataxia, hyperesthesia (Fig. 1A-D), mydriasis (Fig. 1E), erosive lesions in the tongue (Fig. 1F), hypothermia (T:37.2°C), bradycardia (128/bpm), tachypnea (>40 bpm), and normal capillary refill time (<2 sec) and pulse quality. Blood pressure could not be determined because it was difficult to measure. Complete blood count revealed leukocytosis (24.81x10<sup>3</sup>/µL) and neutrophilia (21.38x10<sup>3</sup>/µL) (Table 1). Detection of hypothermia, bradycardia, tachypnea, leukocytosis and neutrophilia in this cat was compatible with sepsis criteria (BRADY et al., 2000), thus sepsis was diagnosed. In the biochemical analysis, alanine aminotransferase (ALT), aspartate aminotransferase (AST), alkaline phosphatase (ALP) activities, and calcium and glucose levels were slightly high,

while lactate dehydrogenase (LDH) and creatine kinase-myocardial band (CK-MB) activities and potassium levels were high (Table 1). Given there is no specific antidote to deltamethrin intoxication, symptomatic treatment was given. Fluid therapy (0.9% NaCl and 5% dextrose solution at a dose of 40 ml/kg intravenously) was administered to speed up the deltamethrin detoxification process. In addition, a high dose of fluid therapy was preferred to cope with septic shock (MONTEALEGRE and

LYONS, 2021). Lactated Ringer's solution was not given because of the hyperkalaemia. Diazepam at a dose of 0.5 mg/kg was administered intravenously to treat neurological signs. Antibiotic therapy was started immediately due to sepsis, leukocytosis and neutrophilia. For this purpose, enrofloxacin (5 mg/kg) was administered subcutaneously for three days. Blankets and hot water bottles were used to treat hypothermia. After these medical interventions, the clinical signs resolved.

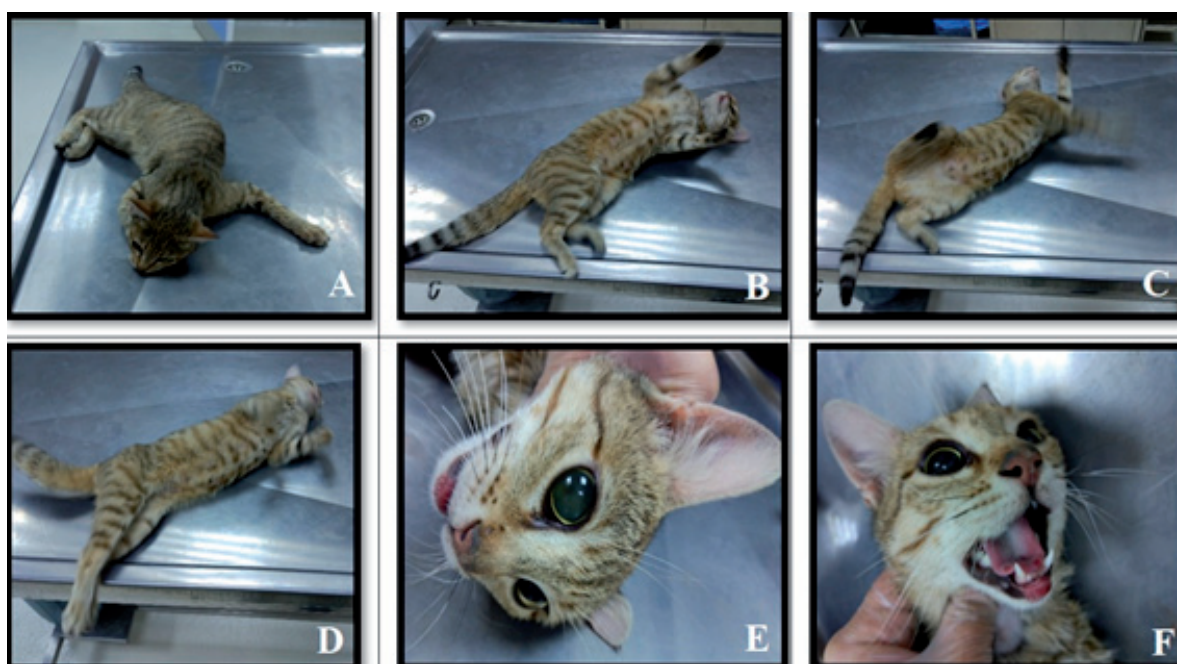


Fig. 1. The clinical findings of a cat with acute deltamethrin intoxication: incoordination, generalised muscle spasms, paw flicking, ear twitching, ataxia, hyperesthesia (A-D), mydriasis (E), erosive lesions in the tongue (F).

Table 1. Haematological and biochemical findings of the cat with acute deltamethrin intoxication.

| Parameters                                     | Result | Reference Range (FIELDER, 2015a; FIELDER, 2015b) |
|--|--------|--|
| Hematology                                     |        |  |
| White blood cell ( $\times 10^3/\mu\text{L}$ ) | 24.81  | 5.5-19.5   |
| Lymphocyte ( $\times 10^3/\mu\text{L}$ )       | 2.16   | 1.5-7  |
| Monocyte ( $\times 10^3/\mu\text{L}$ )         | 1.05   | 0-1.5  |
| Neutrophil ( $\times 10^3/\mu\text{L}$ )       | 21.38  | 2.5-14   |
| Eosinophil ( $\times 10^3/\mu\text{L}$ )       | 0.2    | 0.1-1  |
| Basophil ( $\times 10^3/\mu\text{L}$ )         | 0.02   | 0-0.5  |

Table 1. Haematological and biochemical findings of the cat with acute deltamethrin intoxication. (continued)

| Parameters                                   | Result | Reference Range (FIELDER, 2015a; FIELDER, 2015b) |
|--|--------|--|
| Red blood cell ( $\times 10^3/\mu\text{L}$ ) | 6.92   | 5-10   |
| Haemoglobin (g/dL)                           | 10.1   | 8-15   |
| Haematocrit (%)                              | 30.68  | 24-45  |
| Platelet ( $\times 10^3/\mu\text{L}$ )       | 789    | 100-800  |
| Biochemistry                                 |        |  |
| Alanine aminotransferase (U/L)               | 106    | 25-97  |
| Aspartate aminotransferase (U/L)             | 68.5   | 7-38   |
| Alkaline phosphatase (U/L)                   | 53     | 0-45   |
| Gamma-glutamyl transferase (U/L)             | 3      | 6-28   |
| Lactate dehydrogenase (U/L)                  | 1429.8 | 58-120   |
| Creatine kinase myocardial band (U/L)        | 366    | 69-214   |
| Urea (mg/dL)                                 | 35.49  | 15.00-64.20                                      |
| Creatinine (mg/dL)                           | 0.79   | 0.9-2.2  |
| Cholesterol (mg/dL)                          | 159.40 | 71-156   |
| Glucose (mg/dL)                              | 140.27 | 60-120   |
| Total Bilirubin (mg/dL)                      | 0.1    | 0.1-0.5  |
| Direct Bilirubin (mg/dL)                     | 0.0    | 0.05-0.07  |
| Total protein (g/dL)                         | 8.29   | 5.8-8  |
| Albumin (g/dL)                               | 3.1    | 2.8-3.9  |
| Phosphorus (mg/dL)                           | 6.35   | 3-6.1  |
| Sodium (mEq/L)                               | 153.08 | 146-156  |
| Potassium (mEq/L)                            | 7.1    | 3.7-6.1  |
| Chloride (mEq/L)                             | 113.29 | 115-130  |
| Calcium (mg/dL)                              | 12.352 | 8.7-11.7   |

## Discussion

In this case report, neurological findings, neutrophilia and leukocytosis, increased cardiac and skeletal muscle markers, and hyperkalaemia were detected in a deltamethrin-intoxicated cat. Since there are no reports of deltamethrin intoxication in cats, to provide a referential framework for this intoxication, reports on permethrin intoxication in cats (MEYER, 1999) and deltamethrin intoxication in rats (NCIR et al., 2016; ABDEL-DAIM et al., 2014) and fish (HAVERINEN and VORNANEN, 2016) were used.

Cats are particularly sensitive to products containing concentrated permethrin which are

commonly used in dogs. If left untreated, muscle tremors, ataxia, seizures, hyperesthesia and death may occur. These symptoms may occur in a few hours to a few days after exposure and can last for 2-3 days (MALIK et al., 2010; BOLAND and ANGLES, 2010; STEVEN, 2013). In addition to these findings, DYMOND and SWIFT (2008) reported vomiting, dyspnoea and hypothermia, and BOLAND and ANGLES (2010) reported mydriasis and temporary blindness in cats with permethrin intoxication. Deltamethrin toxicity has been reported in experiments on rats, mice and rabbits. In addition to similar clinical findings observed in

permethrin toxicity in cats, choreoathetosis was detected in these animals (BATEMAN, 2000; CLARK, 1995; SODERLUND et al., 2002). In this study, incoordination, generalised muscle spasms, paw flicking, ear twitching, ataxia, hyperesthesia, mydriasis, erosive lesions in the tongue, hypothermia (T:37.2°C), bradycardia (128/bpm), and tachypnea (>40 bpm) were detected in the cat. In addition, choreoathetosis was clearly observed. On this basis, the following inferences may be articulated:

1) Deltamethrin is highly toxic to cats and similar clinical signs observed in permethrin intoxication occur.

2) Choreoathetosis, which is reported to occur as a result of the use of type II pyrethroids (CROFTON and REITER, 1987), can also be clearly seen in cats with deltamethrin intoxication. This finding is particularly important in the differential diagnosis.

3) The following reasons could be the reason for the emergence of symptoms of deltamethrin intoxication in a short time: oral exposure, having good oral absorption and lipophilic properties, rapid distribution to the CNS, and being a neurotoxic compound (STEVEN, 2013).

4) The lack of glucuronyl transferase enzyme in cats may be one of the causes of deltamethrin intoxication, just like permethrin intoxication. Studies have suggested that cats' sensitivity to permethrin may be related to glucuronyl transferase enzyme deficiency. This deficiency causes permethrin to be metabolized by the liver more slowly, which increases the absorption time of permethrin in target tissues (BOLAND and ANGLES, 2010; HAWORTH and SMART, 2012).

There is no reported correlation between the amount of permethrin applied and the severity of the clinical signs, or the breed or age of the cat. The LD<sub>50</sub> has not been determined, but even exposure to small amounts of permethrin causes severe toxicity in cats (RICHARDSON, 2000; MEYER, 1999). Interestingly, in one study, almost two-thirds of permethrin-affected cats were aged 1 year or less, which could indicate an individual or age-related sensitivity to permethrin (LINNETT, 2008). In this case, it is very difficult to estimate how much deltamethrin the cat was exposed to. Approximately 5 hours after oral exposure to

deltamethrin, intoxication symptoms developed and nervous symptoms progressively worsened. This indicates that cats are very sensitive to deltamethrin intoxication, too. Also, in line with this (LINNETT, 2008), the mother cat was only 10 months old. The inference based on age could perhaps be related to the metabolism of the drug in the liver.

Haematological values are generally reported to be normal in permethrin intoxication (RICHARDSON, 2000; LINNETT, 2008; MARTIN and CAMPBELL, 2000). However, red blood cells, platelet counts, haemoglobin concentration and haematocrit value were reported to be low, while leukocyte values were high in rats with deltamethrin-induced intoxication (ABDEL-DAIM et al., 2014). In this case report, leukocytosis ( $24.81 \times 10^3/\mu\text{L}$ ) and neutrophilia ( $21.38 \times 10^3/\mu\text{L}$ ) were detected. Leukocytosis induced by DLM intoxication might be due to increased leukocyte recruitment and stimulation of the immune system (HEDAYATI and TARKHANI, 2014). In addition, deltamethrin has been reported to cause gastrointestinal irritation in humans (HODGSON et al., 2015). In line with this, leukocytosis can also be a response of the body to the passage of bacteria from the damaged intestinal barrier into the bloodstream due to this irritation. This could indicate that the cat was in sepsis. The detection of hypothermia, bradycardia, tachypnea and neutrophilia is also compatible with sepsis criteria (BRADY et al., 2000). In patients with sepsis, bradycardia may be caused by hyperkalaemia. The erythrocyte parameters were found to be within normal limits. This may be due to the quick presentation at the clinic.

Biochemical values are generally reported to be normal in cats with permethrin intoxication (RICHARDSON, 2000; LINNETT, 2008; MARTIN and CAMPBELL, 2000). Studies have reported that deltamethrin causes liver (NCIR et al., 2016) and kidney damage in rats (TUZMEN et al., 2008; KUCUKLER et al., 2021), and heart damage in fish (HAVERINEN and VORNANEN, 2016). DLM is metabolized by the liver's microsomal enzyme system, intestinal esterases and plasma carboxylesterases, while it is excreted mainly by the kidneys (ANAND et al., 2006). Therefore, its metabolites are accumulated in

the liver and kidneys which causes alterations in animal and human biochemical, haematological and reproductive parameters (ABDEL-DAIM et al., 2013; YOUSEF et al., 2006) by increasing the oxidative stress (ABDEL-DAIM et al., 2013). Subsequently, DLM induces hepatotoxicity, nephrotoxicity and neurotoxicity (ABDEL-DAIM et al., 2013; CHARGUI et al., 2012; EL-GERBED, 2014). In this case, AST, LDH and CK-MB activities were elevated (Table 1), which indicates cardiac and skeletal muscle damage (WILLARD and TVEDTEN, 2011). Thus, it was concluded that deltamethrin intoxication may cause heart and skeletal muscle damage in cats. High values of these parameters were also confirmed by the symptoms of choreoathetosis. ALT and ALP activities were slightly elevated. BUN and creatinine values were within normal ranges. In line with these parameters and the results, it can be stated that there was no significant liver or kidney damage, with imprecise clarity thanks to early intervention.

Biochemical analysis revealed high potassium levels (Table 1). This may be due to the toxicity mechanism on the sodium-potassium pumps in the cell membrane (HANSEN et al., 1994), or sepsis which may lead to hypotension and decreased tissue perfusion, resulting in metabolic acidosis with the subsequent potassium elevation (SIMON et al., 2021).

### Conclusions

This case study, marking the first report on deltamethrin intoxication in a cat, firstly underlines how an owner's ignorant and irresponsible use of chemicals may lead to detrimental consequences. Deltamethrin is highly toxic to cats, causes neurological signs, leukocytosis, neutrophilia, sepsis and damage to various organs, including the heart and skeletal muscles. The clinical findings of deltamethrin intoxication resemble those of permethrin intoxication, but choreoathetosis, which has also been reported in humans and rats, is a characteristic symptom of deltamethrin intoxication which makes it particularly important in the differential diagnosis. The findings of this report should be validated with further appropriate research studies.

### Funding

The author received no financial support for the research, authorship, and/or publication of this article.

### Acknowledgements

This study was presented as an oral presentation at the International VETEXPO Veterinary Science Congress, September 20-22, 2019, İstanbul/ TURKEY

### References

- ABDEL-DAIM, M. M., M. A. ABD ELDAIM, M. M. MAHMOUD (2014): *Trigonella foenum-graecum* protection against deltamethrin-induced toxic effects on haematological, biochemical, and oxidative stress parameters in rats. *Can. J. Physiol. Pharmacol.* 92, 679-685.  
DOI: 10.1139/cjpp-2014-0144
- ABDEL-DAIM, M. M., S. M. ABUZEAD, S. M. HALAWA (2013): Protective role of *Spirulina platensis* against acute deltamethrin-induced toxicity in rats. *PLoS One*, 8, e72991.  
DOI: 10.1371/journal.pone.0072991
- ANAND, S. S., J. V. BRUCKNER, W. T. HAINES, S. MURALIDHARA, J. W. FISHER, S. PADILLA (2006): Characterization of deltamethrin metabolism by rat plasma and liver microsomes. *Toxicol. Appl. Pharmacol.* 212, 156-166.  
DOI: 10.1016/j.taap.2005.07.021
- BATEMAN, D. N. (2000): Management of pyrethroid exposure. *J. Toxicol. Clin. Toxicol.* 38, 107-109.  
DOI: 10.1081/clt-100100924
- BOLAND, L. A., J. M. ANGLÉS (2010): Feline permethrin toxicity: retrospective study of 42 cases. *J. Feline. Med. Surg.* 12, 61-71.  
DOI: 10.1016/j.jfms.2009.09.018
- BRADY, C. A., C. M. OTTO, T. J. VAN WINKLE, L. G. KING (2000): Severe sepsis in cats: 29 cases (1986-1998). *J. Am. Vet. Med. Assoc.* 217:531-535.  
DOI: 10.2460/javma.2000.217.531
- CHARGUI, I., I. GRISSA, F. BENSASSI, M. Y. HRIRA, S. HAOUEM, Z. HAOUAS, H. BENCHEIKH (2012): Oxidative stress, biochemical and histopathological alterations in the liver and kidney of female rats exposed to low doses of deltamethrin (DM): a molecular assessment. *Biomed. Environ. Sci.* 25, 672-683.  
DOI: 10.3967/0895-3988.2012.06.009
- CHRUSTEK, A., I. HOLYNSKA-IWAN, I. DZIEMBOWSKA, J. BOGUSIEWICZ, M. WROBLEWSKI, A. CWYNAR, D. OLSZEWSKA-SLONINA (2018): Current Research on the Safety of Pyrethroids Used as Insecticides. *Medicina (Kaunas)*, 54:61.  
DOI: 10.3390/medicina54040061

- CLARK, J. M. (1995): Effects and mechanism of action of pyrethrin and pyrethroid insecticides. In: Handbook of neurotoxicol. (Chang, L. W., R.S. Dyer, Eds.), Marcel Dekker, New York, pp. 511–546.
- COSTA, L. G. (2015): The neurotoxicity of organochlorine and pyrethroid pesticides. *Handb. Clin. Neurol.* 131, 135-148.  
DOI: 10.1016/B978-0-444-62627-1.00009-3
- CROFTON, K. M., L. W. REITER (1987): Pyrethroid insecticides and the GABA receptor complex: motor activity and the acoustic startle response in the rat. *J. Pharmacol. Exp. Ther.* 243, 946-954.
- DORMAN, D. C., V. R. BEASLEY (1991): Neurotoxicology of pyrethrin and the pyrethroid insecticides. *Vet. Hum. Toxicol.* 33, 238-243.
- DYMOND, N. L., I. M. SWIFT (2008): Permethrin toxicity in cats: a retrospective study of 20 cases. *Aust. Vet. J.* 86, 219-223.  
DOI: 10.1111/j.1751-0813.2008.00298.x
- EL-GERBED, M. S. (2014): Protective effect of lycopene on deltamethrin-induced histological and ultrastructural changes in kidney tissue of rats. *Toxicol. Ind. Health.* 30, 160-173.  
DOI: 10.1177/0748233712448115
- FIELDER, S. E. (2015a): Serum Biochemical Reference Ranges Special Subjects - Merck Veterinary Manual. Available online: <https://www.merckvetmanual.com/special-subjects/reference-guides/serum-biochemical-reference-ranges> [accessed 13 July 2021].
- FIELDER, S. E. (2015b): Serum Hematologic Reference Ranges Special Subjects - Merck Veterinary Manual. Available online: <https://www.msdvetmanual.com/special-subjects/reference-guides/hematologic-reference-ranges> [accessed 13 July 2021].
- HANSEN, S. R., K. A. STEMME, D. VILLAR, W. B. BUCK (1994): Pyrethrins and Pyrethroids in Dogs and Cats. *Comp. Cont. Educ. Pract.* 16, 707-710.
- HAVERINEN, J., M. VORNANEN (2016): Deltamethrin is toxic to the fish (crucian carp, *Carassius carassius*) heart. *Pestic. Biochem. Phys.* 129, 36-42.  
DOI: 10.1016/j.pestbp.2015.10.014
- HAWORTH, M. D., L. SMART (2012): Use of intravenous lipid therapy in three cases of feline permethrin toxicosis. *J. Vet. Emerg. Crit. Care* 22, 697-702.  
DOI: 10.1111/j.1476-4431.2012.00804.x
- HEDAYATI, A., R. TARKHANI (2014): Hematological and gill histopathological changes in iridescent shark, *Pangasius hypophthalmus* (Sauvage, 1878) exposed to sublethal diazinon and deltamethrin concentrations. *Fish Physiol. Biochem.* 40, 715-720.  
DOI: 10.1007/s10695-013-9878-3
- HODGSON, E., M. R. ROE, R. B. MAILMAN, J. E. CHAMBERS (2015): Dictionary of Toxicology. 3rd ed., Academic Press.
- KUCUKLER, S., F. M. KANDEMIR, S. OZDEMIR, S. COMAKLI, C. CAGLAYAN (2021): Protective effects of rutin against deltamethrin-induced hepatotoxicity and nephrotoxicity in rats via regulation of oxidative stress, inflammation, and apoptosis. *Environ. Sci. Pollut. Res. Int.* 28, 62975-62990.  
DOI: 10.1007/s11356-021-15190-w
- LINNETT, P. J. (2008): Permethrin toxicosis in cats. *Aust. Vet. J.* 86, 32-35.  
DOI: 10.1111/j.1751-0813.2007.00198.x
- MALIK, R., M. P. WARD, A. SEEVERS, A. FAWCETT, E. BELL, M. GOVENDIR, S. PAGE (2010): Permethrin spot-on intoxication of cats Literature review and survey of veterinary practitioners in Australia. *J. Feline. Med. Surg.* 12, 5-14.  
DOI: 10.1016/j.jfms.2009.12.002
- MARTIN, A., A. CAMPBELL (2000): Permethrin toxicity in cats. *Vet. Rec.* 147, 639.
- MEHLHORN, H., B. SCHUMACHER, A. JATZLAU, F. ABDEL-GHAFFAR, K. A. AL-RASHEID, S. KLIMPEL, H. POHLE (2011): Efficacy of deltamethrin (Butox(R) 7.5 pour on) against nymphs and adults of ticks (*Ixodes ricinus*, *Rhipicephalus sanguineus*) in treated hair of cattle and sheep. *Parasitol. Res.* 108, 963-971.  
DOI: 10.1007/s00436-010-2141-2
- MEYER, E. K. (1999): Toxicosis in cats erroneously treated with 45 to 65% permethrin products. *J. Am. Vet. Med. Assoc.* 215, 198-203.
- MONTEALEGRE, F., B. M. LYONS (2021): Fluid Therapy in Dogs and Cats With Sepsis. *Front. Vet. Sci.* 8, 622127.  
DOI: 10.3389/fvets.2021.622127.
- NCIR, M., G. BEN SALAH, H. KAMOUN, F. MAKNI AYADI, A. KHABIR, A. EL FEKI, M. SAOUDI (2016): Histopathological, oxidative damage, biochemical, and genotoxicity alterations in hepatic rats exposed to deltamethrin: modulatory effects of garlic (*Allium sativum*). *Can. J. Physiol. Pharmacol.* 94, 571-578.  
DOI: 10.1139/cjpp-2015-0477
- RICHARDSON, J. A. (2000): Permethrin spot-on toxicoses in cats. *J. Vet. Emerg. Crit. Care* 10, 103-106.  
DOI: 10.1111/j.1476-4431.2000.tb00006x
- SIMON, L. V., M. F. HASHMI, M. W. FARRELL (2021): Hyperkalemia. In: StatPearls [Internet]. Treasure Island (FL): StatPearls Publishing, [Updated 2021 Aug 14], Available from: <https://www.ncbi.nlm.nih.gov/books/NBK470284/>
- SODERLUND, D. M., J. M. CLARK, L. P. SHEETS, L. S. MULLIN, V. J. PICCIRILLO, D. SARGENT, J. T. STEVENS, M. L. WEINER (2002): Mechanisms of

- pyrethroid neurotoxicity: implications for cumulative risk assessment. *Toxicology* 171, 3–59.  
DOI: 10.1016/s0300-483x(01)00569-8
- STEVEN, R. H. (2013): Pyrethrins and Pyrethroids. In: *Small Animal Toxicology* (Michael, E. P., A. T. Patricia, Eds.), Saunders Elsevier.
- TUZMEN, N., N. CANDAN, E. KAYA, N. DEMIRYAS (2008): Biochemical effects of chlorpyrifos and deltamethrin on altered antioxidative defense mechanisms and lipid peroxidation in rat liver. *Cell. Biochem. Funct.* 26, 119-124.  
DOI: 10.1002/cbf.1411
- WILLARD, M. D., H. TVEDTEN (2011): *Small Animal Clinical Diagnosis by Laboratory Methods-E-Book*. Elsevier Health Sciences.
- YOUSEF, M. I., T. I. AWAD, E. H. MOHAMED (2006): Deltamethrin-induced oxidative damage and biochemical alterations in rat and its attenuation by Vitamin E. *Toxicology* 227, 240-247.  
DOI: 10.1016/j.tox.2006.08.008

Received: 31 August 2021

Accepted: 3 November 2021

---

**DEĞİRMENÇAY, Ş.: Akutna intoksikacija deltametrimom u mačke – prikaz slučaja. *Vet. arhiv* 93, 271-278, 2023.**

#### SAŽETAK

Deltametrin je sintetički piretrodni insekticid tipa II koji se široko upotrebljava u zaštiti bilja, voća i poljoprivrednih usjeva protiv štetočina kao što su grinje, mravi, kornjače i korov. U veterinarskoj se praksi upotrebljava kao ekto-paraziticid, ali nije odobren za primjenu u mačaka. Prema podacima autora članka intoksikacija deltametrimom u mačaka do sada nije zabilježena i u ovom se članku prvi put bilježe kliničke, hematološke i biokemijske promjene uzrokovane trovanjem deltametrimom u te vrste životinja. U mačke su primijećeni nevoljni pokreti i poteškoće u stajanju nakon što je liznula svoje mačiće koje je vlasnik tretirao vodenastom otopinom pesticida koji je sadržavao deltametrin kako bi ih zaštitio od infestacije ušima. Kliničkim pregledom mačke ustanovljena je inkoordinacija, spontane kontrakcije, ataksija, hiperestezija, hipotermija (37,2 °C), bradikardija (128/otkucaja u minuti), tahipneja, midrijaza i erozivne lezije na jeziku. Hematološki pregled otkrio je leukocitozu i neutrofiliju. Biokemijska analiza pokazala je porast aktivnosti AST-a, LDH-a te CK-MB-a i razine kalija. S obzirom na to da ne postoji specifični antidot toksičnosti deltametrina, primijenjena je simptomatska terapija. Terapija tekućinama (0,9 %-tni NaCl i 5 %-tna otopina glukoze dekstroze u dozi od 40 mL/kg, iv.) primijenjena je kako bi se iz tijela uklonio toksin i spriječio septički šok. Diazepam (0,5 mg/kg, iv.) primijenjen je za ublažavanje neuroloških znakova. Enrofloksacin (5 mg/kg, sk.) primijenjivan je tri dana zbog sepse, leukocitoze i neutrofilije. U liječenju hipotermije upotrijebljene su deke i termofori. Nakon primjene navedenih terapijskih postupaka mačka se oporavila. Ovaj prikaz slučaja potvrđuje da je deltametrin, kao i drugi piretroidi, prilično toksičan za mačke, da su se klinički znakovi pojavili vrlo brzo i da su dominirali neurološki znakovi, posebno koreoatetoza. Ovo istraživanje također pokazuje da deltametrin uzrokuje neutrofiliju, leukocitozu, hiperkalemiju te oštećenje srca i skeletnih mišića u mačaka.

**Ključne riječi:** deltametrin; intoksikacija; neurološki znakovi; mačka

---