

## The histopathological and molecular diagnosis of myocardial sarcocystosis in sheep, and the immunohistochemical correlation of parasitic lesions with MMP - 2 and MMP - 9

Rahsan Yilmaz<sup>1\*</sup>, Adnan Ayan<sup>2</sup>, Nihat Yumusak<sup>1</sup>, and Ahmet Akkoc<sup>3</sup>

<sup>1</sup>Department of Pathology, Faculty of Veterinary Medicine, Harran University, Sanliurfa, Turkiye

<sup>2</sup>Department of Genetics, Faculty of Veterinary Medicine, Yuzuncu Yil University, Van, Turkiye

<sup>3</sup>Department of Pathology, Faculty of Veterinary Medicine, Uludag University, Bursa, Turkiye

---

**YILMAZ, R., A. AYAN, N. YUMUSAK, A. AKKOC: The histopathological and molecular diagnosis of myocardial sarcocystosis in sheep, and the immunohistochemical correlation of parasitic lesions with MMP - 2 and MMP - 9. Vet. arhiv 92, 591-598, 2022.**

### ABSTRACT

This study was aimed at the histopathological and immunohistochemical level investigate cardiac tissue lesions caused by *Sarcocystis* spp. in sheep, and thereby, to collect detailed information on the presence of these parasites and the pathogenesis of sarcocystosis in ovine animals. PCR, a molecular diagnostic method, was used for the identification of the parasite species. Microscopic examination revealed that out of the 45 ovine cardiac tissue samples examined 23 contained *Sarcocystis* spp. cysts. The PCR analysis results showed that out of the 23 cardiac tissue specimens infected with sarcocysts, 7 were determined to be infected with *Sarcocystis gigantea* and 16 with *Sarcocystis tenella*. Immunohistochemical examination demonstrated that, semiquantitatively, MMP - 9 staining was stronger than MMP - 2 staining in the periphery of the parasite cysts.

**Key words:** myocardial sarcocystosis; MMP - 2; MMP - 9; immunohistochemistry; PCR; sheep

---

### Introduction

*Sarcocystis* spp. are ubiquitous protozoan parasites found primarily in meat animals, as well as in avian species, various reptiles and humans (DUBEY et al., 1989). These parasites reproduce sexually in the intestines of their definitive hosts, which are carnivores, and asexually in the tissues of their intermediate hosts, which are herbivores

(DUBEY, 1976; DUBEY et al., 2016; HAGNER et al., 2018). *Sarcocystis* spp. form cysts in the cardiac, laryngeal, esophageal, diaphragmatic, lingual, masseter and skeletal muscles of their intermediate hosts (O'TOOLE et al., 1986). The most common species in sheep are *Sarcocystis ovis*, *Sarcocystis arieticanis*, *Sarcocystis ovifelis*

---

\*Corresponding author:

Rahsan Yilmaz, DVM, Associate Professor, Department of Pathology, Faculty of Veterinary Medicine, Harran University, Sanliurfa, Turkiye, Phone: +90 414 3183926; Fax: +90 414 3183920; E-mail: rmilliogullari@hotmail.com

and *Sarcocystis medusiformis* (DUBEY et al., 1989; LEVINE, 1986). *Sarcocystis* spp. cysts, which are visible to the naked eye, are referred to as macrocysts, whilst those not visible to the naked eye are referred to as microcysts. Depending on the parasite density, clinical symptoms such as anorexia, abortion, ataxia, hair loss, sometimes encephalomyelitis, myositis and even death can be observed in sheep infected with sarcocysts (DUBEY et al. 1989; O'TOOLE et al., 1986; MUNDAY, 1984). These oval or rice grain-like macrocysts, measuring 1 - 1.5 cm in size, detected during carcass examination at the slaughterhouse, cause major economic losses in the meat industry as they are undesirable to the consumer and require the conditional placement of meat on the market. Light microscopy and ultrastructural examination are used for detection of *Sarcocystis* species in animals. Furthermore, serological tests, such as the enzyme-linked immunosorbent assay (ELISA) and indirect fluorescence antibody test (IFAT), are also used for diagnosis of sarcocystosis in animals and humans (LATIF et al., 1999; THOMAS and DISSANAIKE, 1978). In recent years, polymerase chain reaction (PCR) has started to be used extensively and effectively for identification of *Sarcocystis* spp. (PRITT et al., 2008).

Matrix metalloproteinases (MMPs), which belong to the neutral endopeptidase family, are  $\text{Ca}^{2+}$  dependent and  $\text{Zn}^{2+}$  containing enzymes that are active at neutral pH and capable of degrading extracellular matrix (ECM) proteins and basal membrane components. Depending on the type, MMPs are secreted as proenzymes by various cells, including endothelial cells, fibroblasts, vascular smooth muscle cells, T lymphocytes, thrombocytes, osteoblasts, chondrocytes, keratinocytes, macrophages, neutrophil leukocytes, epithelial cells, and mesenchymal cells (GALIS and KHATRI, 2002; NAGASE and WOESSNER, 1999; NAGASE et al., 2006). MMP - 2 and MMP - 9, which are gelatinases, are responsible for degradation of collagen and the basal membrane, as well as for degradation of the extracellular matrix of endothelial and epithelial cells, lipocytes, myelocytes and peripheral neurons. MMP expression increases during the tissue remodeling associated with various physiological

and pathological conditions induced by factors that influence gene transcription (BEAUDEUX et al., 2004). In the heart, MMPs are localized in the cardiomyocyte sarcomere and are activated by acute cardiac injury (SCHULZ, 2007). It is reported that both the activity and expression of MMPs increase in the event of several cardiac pathologies (CREEMERS et al., 2001). It has been demonstrated that the determination of MMP - 2 and MMP - 9 levels by molecular methods is useful in the early diagnosis of certain parasitic infections (NISHIZUKA et al., 2001; BEAUDEUX et al., 2004; SCHULZ, 2007; CREEMERS et al., 2001; BRUSCHI et al., 2014; BRUSCHI et al., 2016; CHIU and LAI, 2014). Previous research is available on the determination of the presence and levels of MMP - 2 and MMP - 9 in cardiac tissue lesions by immunohistochemical methods (CABALLERO et al., 2018). The present study aimed to demonstrate both the presence of MMP - 2 and MMP - 9 in cardiac tissue, and the correlation of the presence of these enzymes with lesions by immunohistochemistry in cases of myocardial sarcocystosis.

### Materials and methods

The material for the study constituted 45 ovine heart tissues. The sheep were of different breeds and ages, and were submitted to the Pathology Department of Harran University, Faculty of Veterinary Medicine, for necropsy.

*Macroscopic examination.* No sarcocysts were found in the gross examination of the hearts of 45 sheep. The samples of heart tissue were taken randomly from the right-left ventricle and atria.

*Histopathological examination.* The heart tissues were fixed in 10% buffered formalin for histopathological examination. The samples were processed routinely, and sections were cut 4  $\mu\text{m}$  thick and examined after staining with Hematoxylin and Eosin (H&E).

*DNA extraction.* DNA was extracted from 23 cardiac tissue specimens using the Invitrogen PureLink™ Genomic DNA Mini Kit (USA, K182002). Extracted DNA was stored at - 20 °C until further use.

*PCR reaction.* The 18s rDNA gene of *Sarcocystis* spp. was amplified with the primers

F: CGCAAATTACCCAATCCTGA and R: ATTTCTCATAAGGTGCAGGAG, previously used by Braunig (BRAUNIG et al., 2016). Twenty-five mL of the mastermix was added to 10 pmol of the forward and reverse primers, 200  $\mu$ M dNTPs, 2.5 mM MgCl<sub>2</sub>, 2.5 U Taq Polymerase and 10X PCR buffer, nuclease-free water and DNA. The PCR reaction was performed as follows: After initial denaturation at 95 °C for 15 minutes, there were 40 cycles of denaturation (95 °C, 40 seconds), annealing (59 °C, 30 seconds) and elongation (72 °C, 1 min), ending with a final elongation at 72 °C for 6 min. The PCR products were stained with Safe-T-Stain, run on 1.5% agarose gel, and gel images were captured.

*Sequence Analysis of Positive Samples.* For the *Sarcocystis* spp. identification, two PCR products of 700 bp were sequenced bidirectionally. The sequencing results were aligned and compared with reference sequences deposited in the GenBank

database using the Basic Local Alignment Search Tool (BLAST) program.

*Immunohistochemical examination.* The streptavidin-biotin-peroxidase technique was used for detecting MMP - 2 (ThermoFisher, MA5 - 13590) and MMP - 9 (ThermoFisher, PA5 - 13199). The antibodies differed for the immunohistochemical staining procedure. These differences are presented in Table 1. Negative control sections were incubated with PBS instead of the primary antibody. All immunohistochemically stained sections were examined under a light microscope for the presence of cells that stained positively for MMP - 2 and MMP - 9 and for the location of the staining. In view of the distribution and intensity of the immunohistochemical staining, five regions were randomly selected in each section using a x 40 objective, and the positively stained cells were counted in these five regions.

Table 1. Antibodies used and staining process differences

Antibodies	Dilution rate	Antigen retrieval	Primer antibody application heat and time	Chromogen
Rabbit polyclonal MMP 9	1: 200	Citrat buffer 10 minutes, 100 watt, microwave,	Room temperature, 1 hour	AEC
Rabbit monoclonal MMP 2	1: 100	Citrat buffer 15 minutes, 100 watt, microwave,	37 °C incubatore, 1 hour	DAB

*Statistical analysis.* For statistical analysis, the average number of cells counted on five different microscope areas for each sample was used. The relationship between cell counts stained positive with different antibodies in parasite infected tissues was evaluated by two-way analysis of variance. The relationship between the number of cells stained with different antibodies within the control as well as the infected groups was analyzed by using Pearson correlation analysis. For statistical analysis the SPSS 17.0 package program was used.

## Results

*Histopathological results.* The prevalence of infection with *Sarcocystis* species in the sheep was 51.1% (23/45), and sarcocysts were detected in the myocardium. In the microscopic examination, sarcocysts were also observed embedded in cardiac muscle bundles and Purkinje fibers. Although numerous sarcocysts were detected in myofibers and Purkinje fibers, surrounding the sarcocyst there was no infiltration of inflammatory cells shown in the areas where the muscle bundles and muscle fibers were intact (Fig. 1).

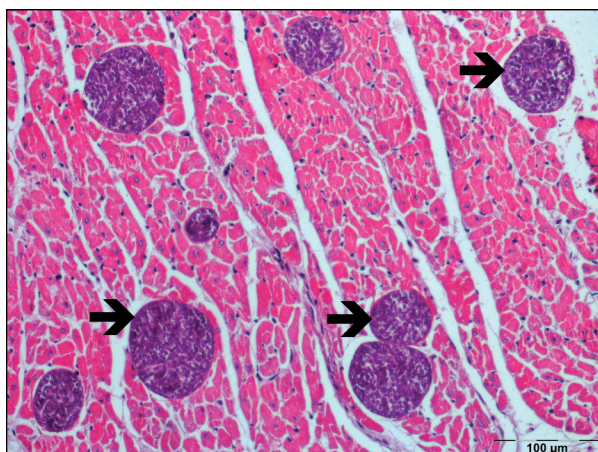


Fig. 1: The numerous sarcocysts in myofibers (black arrows), (H&E; x 20).

**PCR results.** All the 23 specimens that were tested with PCR produced specific bands of 700 bp (Fig. 2).

**Sequence analysis of the 18s rDNA gene.** PCR positive tissues were bilaterally sequenced for consensus sequencing analysis of the specimens. Comparison with the relevant reference genes deposited in the GenBank database (MK420020.1, MK045326.1, KC209733.1, MK045325.1, L24384.1, AF441290.1, MN398408.1) demonstrated that seven of the sequenced specimens were similar to *Sarcocystis gigantea* at a rate ranging from 92.74% to 99.83%. When compared to the relevant genes deposited in GenBank (MF401626.1, KP263759.1, KC209734.1, MK420019.1, MF039329.1, LC214878.1,

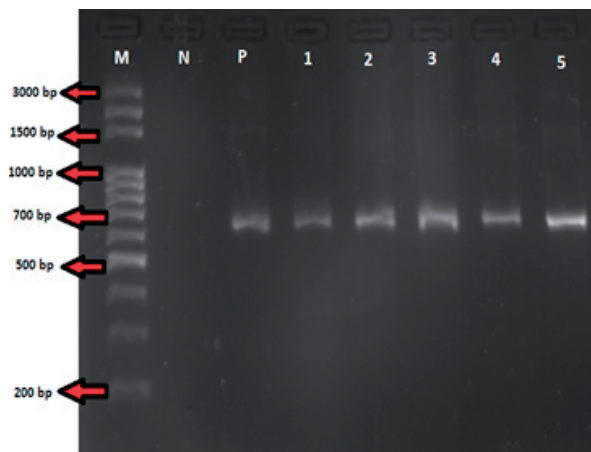


Fig. 2. PCR image of *Sarcocystis* spp (M: Marker; N: Negative control; P: Positive control; lanes 1-5).

KP263755.1, KP263753.1, KC209737.1, MK420018.1, KP263758.1, KP263756.1, KP263754.1, KP263752.1, KP263757.1, KY614537.1, LC214879.1, MH413034.1), the remaining 16 sequenced specimens were determined to show similarity to *Sarcocystis tenella* at a rate ranging from 98.14% to 98.91%. Thereby, on the basis of the results of PCR sequence analysis it was determined that, out of the 23 cardiac tissue samples containing sarcocysts, seven (30.43%) were infected with *Sarcocystis gigantea* and 16 (69.56%) were infected with *Sarcocystis tenella*.

**Immunohistochemical results.** MMP - 2 (Fig. 3a) and MMP - 9 (Fig. 3b) were stained positively in the heart tissue. Immunostaining was defined as exclusively cytoplasmic of the muscle around the parasite cyst.

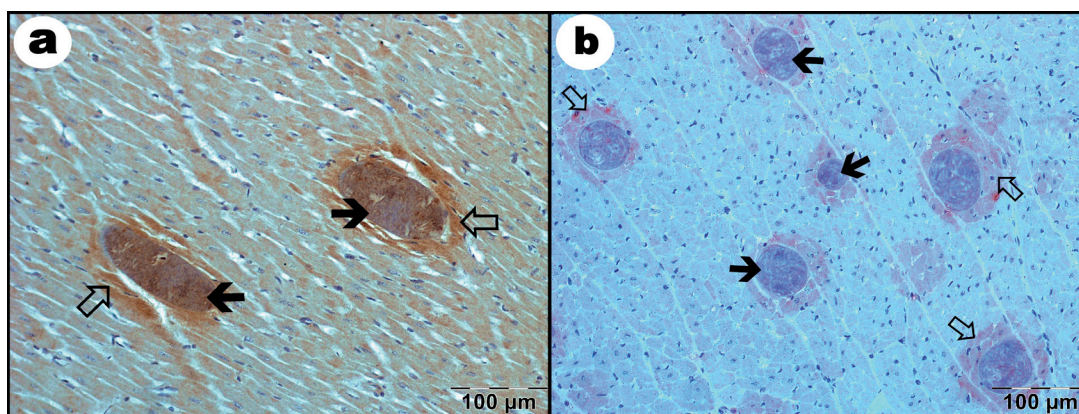


Fig. 3. (a) MMP-2 positive staining in the cytoplasm of the muscle (white arrows) around the parasite cyst (black arrows), (IHC; x 20); (b) MMP-9 positive staining in the cytoplasm of the muscle (white arrows) around the parasite cyst (black arrows), (IHC; x 20).

**Statistical results.** The antibody used and the infected with parasite status had a significant effect on the number of cells stained ( $P < 0.001$ ). While the number of cells stained with MMP - 2 was higher than those stained with MMP - 9 in the sample without parasites i.e. normal heart tissue, the number of cells stained with MMP - 9 was higher than in the sample stained with MMP - 2

in the group infected with parasites. A significant interaction was also observed between the antibody used and infected-with-parasite status ( $P < 0.001$ ).

Pearson correlation analysis revealed no significant relationship between the number of cells stained with MMP - 2 and MMP - 9 for either the control or the infected group ( $P > 0.05$ ) (Table 2).

Table 2. The effect of infection status and antibody used on the positive stained cells number

	Antibody	Mean	Std. Error	P (Antibody)	P (Infection)	P (Interaction)
Control	MMP-2	13,583	0,625	0.001	0.001	0.001
	MMP9	8,548	0,625			
Parasited	MMP-2	41,670	0,625			
	MMP9	90,504	0,625			

## Discussion

*Sarcocystis* spp. are common parasites with a worldwide distribution in humans and many animal species, and mainly infect the skeletal and cardiac muscles (NOUROLLAHI-FARD et al., 2015). The results of the present study showed a high frequency of microscopic *Sarcocystis* infection in sheep raised in southern Turkey. Previous research conducted in Turkey pointed out differences in the incidence rates of *Sarcocystis* spp. macrocysts and microcysts. Accordingly, in the Konya province and its vicinity, the incidence rates of macrocysts and microcysts were found to be 19.76% and 92.95% (SEVINC et al., 2000), respectively, whilst in the Kırkkale province, the total incidence rate of macrocysts and microcysts was 58.92%, and the incidences of macrocysts and microcysts alone were 20.53% and 47.32% (OZKAYHAN et al., 2007). Additionally, Gokpinar reported an incidence of 91% for microcysts (GOKPINAR et al., 2014). While the abovementioned studies previously conducted in Turkey were based on the examination of the esophageal, diaphragmatic and intercostal muscles of sheep, the present study was based on the examination of cardiac tissue alone. In the present study, while macrocysts were not detected in the ovine myocardial specimens examined, microcysts were determined at a rate of 51.1%. The fact that macrocysts were not detected

in the present study is in agreement with the results of previous research indicating that macrocysts are rarely formed by *Sarcocystis* spp. in cardiac tissue (DUBEY, 1976; PORTELLA et al., 2016; DONG et al. 2018). Recent studies on sarcocystosis in Turkey have revealed prevalence rates of 91% for mixed infection with *S. tenella* and *S. arieticanis* (GOKPINAR et al., 2014) and 86.5% for *S. ovis* and *S. arieticanis* (BEYAZIT et al., 2007). In a study conducted by Portella (PORTELLA et al., 2016), while macrocysts were not detected in the ovine myocardium, microcysts were present at a rate of 76.2% (61 / 80, 95% CI: 66.9 - 85.9). Although these macrocysts showed morphological similarity to *S. tenella* and *S. arieticanis*, PCR results revealed 21.2% (17 / 80, CI: 12.3 - 30.2) similarity to *Sarcocystis* spp. DNA (PORTELLA et al., 2016). Furthermore, varying incidences have been reported for ovine myocardial sarcocystosis. While Gopal et al., (2016) reported an incidence of 72.2 %, Al Quraishy et al., (2014) reported incidence rates of 40%, 44 % and 53% for the Niemy, Najdy and Sawakny regions, respectively. In the present study, the incidence rates determined for *Sarcocystis gigantea* and *Sarcocystis tenella* were 30.43% and 69.56%, respectively.

MMPs are enzymes, which are involved in physiological processes such as tissue restructuring, morphogenesis, wound healing and normal

development, as well as pathological processes such as tumor cell invasion, angiogenesis and metastasis (GALIS and KHATRI, 2002; NAGASE and WOESSNER, 1999; BEAUDEUX et al., 2004). To date, 23 types have been sequenced in humans. MMP - 2 and MMP - 9 Types IV, VII and X, all of which are classified as gelatinases according to substrate specificity, degrade collagen (VISSE and NAGASE, 2003).

Literature reports are available about the correlation of MMP - 2 and MMP - 9 with parasitic infections (NAGASE and WOESSNER, 1999; VERMA et al., 2011; HSU et al., 2005). However, the correlation of MMP - 2 and MMP - 9 with ovine myocardial sarcocystosis has not been investigated before. In the present study, immunohistochemical staining revealed that, despite the fact that MMP - 9 staining was stronger than MMP - 2 in infected cardiac tissue, MMP - 2 staining was semiquantitatively stronger than MMP - 9 in the normal heart tissue without parasites. This result obtained in control tissue samples was attributed to MMP - 2 being expressed mostly at relatively low levels in normal resting tissues, which implies the functional role of this enzyme in tissue homeostasis, for instance continuous ECM remodeling. MMP - 9 staining being stronger in infected tissues was attributed to the gelatinolytic activity of this enzyme, as previously stated by Bruschi (BRUSCHI et al., 2016). The present study demonstrates, for the first time, the correlation between myocardial lesions caused by *Sarcocystis* spp. and the presence of MMP - 2 and MMP - 9 in ovine cardiac tissue by means of immunohistochemical methods.

#### Acknowledgement

Funding for the present work was provided by Harran University Scientific Research, Projects Management Unit (grant number 18156).

#### Conflict of interest

The authors declare that there are no conflicts of interest.

#### References

- AL QURAI SHY, S., K. MORSY, A. R. BASHTAR, F. A. GHAFAR, H. MEHLHORN (2014): *Sarcocystis arieticanis* (Apicomplexa: Sarcocystidae) infecting the heart muscles of the domestic sheep, *Ovis aries* (Artiodactyla: Bovidae), from K. S. A. on the basis of light and electron microscopic data. *Parasitol. Res.* 113, 3823-3831.  
DOI: 10.1007/s00436-014 - 4050-2
- BEAUDEUX J. L., P. GIRAL, E. BRUCKERT, M. J. FOGLIETTI, M. J. CHAPMA (2004): Matrix metalloproteinases, inflammation and atherosclerosis: Therapeutic perspectives. *Clin. Chem. Lab. Med.* 42, 121-131.
- BEYAZIT, A., O. YAZICOGU, Z. KARAER (2007): The prevalence of *Sarcocystis* species in Izmir province. *Ankara Univ. Vet. Fak. Derg.* 54, 111-116.  
DOI: 10.1007/s00436-016-5158-3.
- BRAUNIG, P., L. P. PORTELLA, A. S. CEZAR, F. LIBARDONI, L. A. SANGIONI, S. S. V. FERNANDA, P. B. D. GONCALVES (2016): DNA extraction methods and multiple sampling to improve molecular diagnosis of *Sarcocystis* spp. in cattle hearts. *Parasitol. Res.* 115, 3013-3921.  
DOI: 10.1007/s00436-016-5158-3
- BRUSCHI, F., C. BIANCHI, M. FORNARO, G. NACCARATO, M. MENICAGLI, M. A. GOMEZ-MORALES, E. POZIO, B. PINTO (2014): Matrix metalloproteinase MMP - 2 and MMP - 9 as inflammation markers of *Trichinella spiralis* and *Trichinella pseudospiralis* infections in mice. *Parasite. Immunol.* 36, 540-549.  
DOI: 10.1111/pim.12138
- BRUSCHI, F., C. D'AMATO, S. PIAGGI, C. BIANCHI, B. CASTAGNA, A. PAOLICCHI, B. PINTO (2016): Matrix metalloproteinase MMP - 9: A reliable marker for inflammation in early human trichinellosis. *Parasite. Immunol.* 15, 132-136.  
DOI: 10.1016/j.vetpar.2016.04.011
- CABALLERO, E. P., M. H. SANTAMARÍA, R. S. CORRAL (2018): Endogenous osteopontin induces myocardial CCL5 and MMP - 2 activation that contributes to inflammation and cardiac remodeling in a mouse model of chronic Chagas heart disease. *Biochim. Biophys. Acta. Mol. Basis. Dis.* 1864, 11-23.  
DOI: 10.1016/j.bbadis.2017.10.006
- CHIU, P. S., S. C. LAI (2014): Matrix metalloproteinase - 9 leads to blood-brain barrier leakage in mice with eosinophilic meningoencephalitis caused by *Angiostrongylus cantoniensis*. *Acta. Tropica.* 140, 141-150.  
DOI: 10.1016/j.actatropica.2014.08.015
- CREEMERS, E. E., J. CLEUTJENS, J. F. SMITS (2001): Matrix metalloproteinase inhibition after myocardial infarction: A new approach to prevent heart failure? *Circ. Res.* 89, 201-210.

- DONG, H., R. SU, Y. WANG, Z. TONG, L. ZHANG, Y. YANG, J. HU (2018): Sarcocystis species in wild and domestic sheep (*Ovis ammon* and *Ovis aries*) from China. *BMC Vet. Res.* 14, 377.  
DOI: 10.1186/s12917-018-1712-9
- DUBEY, J. P. (1976): A review of Sarcocystis of domestic animals and of other coccidia of cats and dogs. *J Am Vet Med Assoc.* 15, 1061-1078.
- DUBEY, J. P., C. A. SPEER, R. FAYER (1989): Sarcocystosis of Animals and Man. CRC Press, Inc. Boca Raton, Florida, USA
- DUBEY, J. P., B. R. CALERO, B. M. ROSENTHAL, C. A. SPEER, R. FAYER (2016): Sarcocystosis of animals and humans. 2nd Edn. CRC Press, Taylor & Francis Group
- GALIS, Z. S., J. J. KHATRI (2002): Matrix metalloproteinases in vascular remodeling and atherogenesis: The good, the bad, and the ugly. *Circ. Res.* 90, 251-261.  
DOI: 10.1161/res.90.3.251
- GOKPINAR, S., K. YILDIZ, I. S. GURCAN (2014): Prevalence and concentration of *Sarcocystis* spp. microscopic cysts in sheep muscles using percoll gradient centrifugation. *Refu. Vet.* 69, 16-19.
- GOPAL, K., N. PAZHANIVEL, V. KUMAR, R. THANGATHURA (2016): Some Observations on Sarcocystis Infection in Sheep. *Indian Vet. J.* 93, 81-82.
- HAGNER, K., T. S. JOKINEN, A. LAVIKAINEN, A. SUKURA (2018): Acute fulminant necrotizing myopathy in a dog caused by co-infection with ultrastructural Sarcocystis caninum and Sarcocystis svanai-like apicomplexan protozoa. *Vet. Parasitol.* 15, 153-156.  
DOI: 10.1016/j.vetpar.2018.02.011
- HSU, L. S., H. H. LEE, K. M. CHEN, H. CHOU, S. C. LAI (2005): Matrix metalloproteinase - 2 and -9 in the granulomatous fibrosis of rats infected with *Angiostrongylus cantonensis*. *Ann. Trop. Med. Parasitol.* 99, 61-70.
- LATIF, B. M., J. K. AL-DELEMI, B. S. MOHAMMED, S. M. AL-BAYATI, A. M. AL-AMIRY (1999): Prevalence of *Sarcocystis* spp. in meatproducing animals in Iraq. *Vet. Parasitol.* 84, 85-90.  
DOI: 10.1016/s0304-4017(99)00046-1
- LEVINE, N. D. (1986): The taxonomy of Sarcocystis (protozoa, apicomplexa) species. *J. Parasitol.* 72, 372-382.
- MUNDAY, B. L. (1984): The effect of *Sarcocystis tenella* on wool growth in sheep. *Vet. Parasitol.* 15, 91-94.  
DOI: 10.1016/0304-4017(84)90024-4
- NAGASE, H., J. F. Jr. WOESSNER (1999): Matrix metalloproteinases. *J. Biol. Chem.* 274, 21491-21494.  
DOI: 10.1074/jbc.274.31.21491.
- NAGASE, H., R. VISSE, G. MURPHY (2006): Structure and Function of Matrix Metalloproteinases and TIMPS. *Cardiovasc. Res.* 69, 562-573.  
DOI: 10.1016/j.cardiores.2005.12.002
- NISHIZUKA, I., Y. ICHIKAWA, T. ISHIKAWA, M. KAMIYAMA, S. HASEGAWA, N. MOMIYAMA, K. MIYAZAKI, H. SHIMADA (2001): Matrilysin stimulates DNA synthesis of cultured vascular endothelial cells and induces angiogenesis in vivo. *Cancer Lett.* 173, 175-182.  
DOI: 10.1016/s0304-3835(01)00634-6
- NOUROLLAHI-FARD, S. R., R. KHEIRANDISH, S. SATTARI (2015): Prevalence and histopathological finding of thin-walled and thick-walled Sarcocysts in slaughtered cattle of Karaj abattoir, Iran. *J. Parasit. Dis.* 39, 272-275.  
DOI: 10.1007/s12639-013-0341-2
- O'TOOLE, D., S. J. DUFFELL, D. H. UPCOTT, D. FREWIN (1986): Experimental microcyst *Sarcocystis* infection in lambs: Pathology. *Vet. Rec.* 119, 525-535.  
DOI: 10.1136/vr.119.21.525
- OZKAYHAN, M. A., Z. KARAER, A. N. ILKME, H. T. ATMACA (2007): The prevalence of Sarcocystis species in sheep slaughtered in municipality slaughterhouse in Kirikkale. *Turkiye Parazit. Derg.* 31, 272-276.
- PORTELLA, L. P., G. C. CADORE, L. A. SANGIONI, M. E. M. ALVES, R. CHERMERIS, L. P. BRUM, F. S. F. VOGEL (2016): Molecular detection of protozoa of the Sarcocystidae family in sheep from the State of Rio Grande do Sul, Brazil. *Ciência Rural, Santa Maria.* 46, 1613-1617.  
DOI: 10.1590/0103-8478cr20151365
- PRITT, B., T. TRAINER, L. SIMMONS-ARNOLD, M. EVANS, D. DUNAMS, B. M. ROSENTHAL (2008): Detection of *Sarcocystis* parasites in retail beef: a regional survey combining histological and genetic detection methods. *J. Food Prot.* 71, 2144-2147.  
DOI: 10.4315/0362-028x-71.10.2144
- SCHULZ, R. (2007): Intracellular targets of matrix metalloproteinase-2 in cardiac disease: rationale and therapeutic approaches. *Annu. Rev. Pharmacol. Toxicol.* 47, 211-242.  
DOI: 10.1146/annurev.pharmtox.47.120505.105230
- SEVINC, F., F. ALTINOZ, U. USLU, O. S. ALDEMIR (2000): Koyunlarda *Sarcocystis* türlerinin yaygınlığı. *Veteriner Bilimleri Dergisi*, 16, 75-79.
- THOMAS, V., A. DISSANAİKE (1978): Antibodies to *Sarcocystis* in Malaysians. *Trans. R. Soc. Trop. Med. Hyg.* 72, 303-306.  
DOI: 10.1016/0035-9203(78)90211-0
- VERMA, A., K. N. PRASAD, K. K. NYATI, S. K. SINGH, A. K. SINGH, V. K. PALIWAL, R. K. GUPTA (2011): Association of MMP - 2 and MMP - 9 with clinical outcome of neurocysticercosis. *Parasitology.* 138, 1423-1428.  
DOI: 10.1017/S0031182011001259
- VISSE, R., H. NAGASE (2003): Matrix metalloproteinases and tissue inhibitors of metalloproteinases: Structure, function, and biochemistry. *Circ. Res.* 92, 827-839.  
DOI: 10.1161/01.RES.0000070112.80711.3D

Received: 2 November 2020

Accepted: 21 December 2020

---

**YILMAZ, R., A. AYAN, N. YUMUSAK, A. AKKOC: Histopatološka i molekularna dijagnoza sarkocistoze miokarda u ovaca i imunohistološka korelacija s parazitskim lezijama koje sadrže MMP-2 i MMP-9. Vet. arhiv 92, 591-598, 2022.**

### **SAŽETAK**

Cilj je ovog rada bio histopatološko i imunohistokemijsko istraživanje lezija srčanog tkiva uzrokovanih parazitom *Sarcocystis* spp. u ovaca te prikupljanje detaljnih informacija o prisutnosti ovih parazita i patogenezi sarkocistoze u ovaca. Molekularna dijagnostička metoda PCR upotrijebljena je za identifikaciju parazitskih vrsta. Mikroskopska analiza pokazala je da su od 45 uzoraka srčanog tkiva ovaca 23 sadržavala ciste parazita *Sarcocystis* spp. Na temelju rezultata PCR analize od 23 uzorka srčanog tkiva invadirana sarkocistama 7 uzoraka bilo je invadirano vrstom *Sarcocystis gigantea*, a 16 uzoraka vrstom *Sarcocystis tenella*. Imunohistokemijska pretraga pokazala je da je, semikvantitativno, MMP-9 obojenje bilo jače od obojenja MMP-2 na periferiji cista parazita.

**Ključne riječi:** sarkocistoza miokarda; MMP-2; MMP-9; imunohistokemija; PCR; ovca

---