

The use of an autologous platelet-rich fibrin (PRF) membrane for the treatment of deep corneal ulcers in dogs

Aynur Demir*, Dilek O. Erdikmen, Zeynep T. Sevim, and Yusuf Altundağ

Faculty of Veterinary Medicine, Istanbul University-Cerrahpasa, Department of Surgery, Avcilar, Istanbul, Turkey

DEMİR, A., D. O. ERDIKMEN, Z. T. SEVİM, Y. ALTUNDAĞ: The use of an autologous platelet-rich fibrin (PRF) membrane for the treatment of deep corneal ulcers in dogs. *Vet. arhiv* 92, 443-458, 2022.

ABSTRACT

The aim of this study was to evaluate the clinical efficacy of a platelet-rich fibrin (PRF) membrane, which is considered to be a new alternative surgical method in the treatment of vision-threatening corneal ulcers in dogs. Fourteen dogs (17 eyes) of various breeds and ages with deep corneal ulcers were treated surgically with a PRF membrane transplantation. The corneal ulcer of all the patients was closed with an autologous platelet-rich fibrin membrane. In the first 10 days after the operation, it was observed that the fibrin membrane partially melted, and corneal epithelialization and granulation tissue occurred in and around the ulcer area due to the graft material. Pain was significantly relieved, and conjunctival inflammation was noticeably improved. From the 20th day after the surgery, the granulation tissue was gradually cleaned. It was determined that all the eyes had vision. The most common complications after surgery were corneal pigmentation and fibrosis of varying severity. The use of autologous fibrin membranes is a safe and effective surgical alternative for the closure and healing of corneal ulcers. Our findings show that the autologous platelet-rich fibrin membrane is useful and effective in treating canine corneal deep ulcers.

Key words: Autologous graft; corneal ulcer; descemetocoele; dogs; platelet-rich fibrin membrane

Introduction

All corneal wounds, which are common in small animal practice and where tissue loss occurs, are called corneal ulcers (BARACHETTI, 2010; KAYA and PEKEL, 2015; SOONTORNVİPART et al., 2003). These lesions mostly develop due to trauma, such as a foreign body, tear film deficiency, eyelid dysfunction, eyelash abnormalities, and bacterial and viral infection

(BARACHETTI, 2010; DULAURENT et al., 2014; SOONTORNVİPART et al., 2003). They are defined according to the size, etiology, infection, the presence of collagenase activity, and the depth of lesion, such as superficial, deep stromal or descemetocoele (KAYA and PEKEL, 2015; CHOW and WESTERMEYER, 2016). As these lesions progress, they can deepen into the endothelial layer

*Corresponding author:

Aynur Demir, Faculty of Veterinary Medicine, University of Istanbul-Cerrahpasa, Department of Surgery, TR-34320 Avcilar, Istanbul, Turkey, Phone: +905067550873; Fax: +90 2124737240; aynurdemir_1903@hotmail.com

where perforation occurs. These deep ulcers lead to corneal perforation, endophthalmitis, glaucoma, and phthisis bulbi, resulting in the loss of vision if left untreated or not properly treated. Due to the risk of eye loss, urgent and appropriate treatment methods are often required (TUNTIVANÍCH et al., 2006). The aim of treatment is to protect the surface by providing mechanical support to the cornea, delay stromal melting, prevent the ulcer from progressing and causing perforation, and help corneal repair (DULAURENT et al., 2014; KAYA and PEKEL, 2015). Healing of deep ulcers takes a longer time than simple epithelial erosions, thus, medical treatment alone is not sufficient (KAYA and PEKEL, 2015). Corneoscleral transpositions, third eyelid and conjunctival flaps, amniotic membrane application, corneal tissue adhesives, limbal stem cell transplants, and therapeutic bandage contact lenses are preferred in operative treatment, depending on the size and depth of the defect (KAYA and PEKEL, 2015). However, there are some disadvantages and serious complications. Some new modified surgical methods have been used to reduce the disadvantages and complication rates found in the majority of alternative grafts and autografts. A novel technique using Platelet Rich Fibrin (PRF) derived from an organism, developed by CHOUKRON et al. 2006, is practical and easily accessible, and has a low biological risk in the treatment of corneal ulcers. PRF, which has already been used in many areas, is considered to be an effective method for reducing the occurrence of complications and shortening the recovery time in the treatment of corneal ulcers. This method is very easy to use, requires low cost, serves as a skeleton in cell proliferation, differentiation and migration, which are important for ocular surface regeneration, and is very effective in accelerating healing (ALÍO et al., 2013; CAN et al., 2016; SOONTORNVIPART et al., 2003). The aim of this study was to create an alternative model for

clinical applications in the surgical treatment of deep corneal ulcers, which are common lesions that cause vision loss in dogs when proper treatment is not applied, and to contribute to the existing literature.

Materials and methods

Animals. In this study, PRF membrane transplantation was performed on 17 eyes of 14 dogs (seven male and seven female) diagnosed with deep corneal ulcers. The ages of the dogs ranged from four months to 12 years, and their weight ranged from 3.5 to 42 kg. The study was approved by the Istanbul Bagcilar Training and Research Hospital Animal Experiments Local Ethics Committee (No. 2019-85). All procedures were carried out in accordance with the code of ethics for the treatment and welfare of animals. The study was carried out between May 2019 and April 2020 in the surgery clinics of Istanbul University-Cerrahpaşa Veterinary Faculty.

Surgical procedures. Detailed eye examinations were performed, including menace and pupillary light reflex, intraocular pressure measurement, and Schirmer tear and fluorescein staining tests, after obtaining an anamnesis for all patients. In cases where anterior and posterior segment examinations could not be performed, diagnostic methods, such as ultrasonography, were not undertaken for preoperative prognosis evaluation in order to avoid possible corneal perforation. The owners were informed about the width and depth of the corneal ulcers, their relationship with other ocular structures, and the treatment methods and prognosis of the disease. Data were noted, including breed, age, sex, affected eye, lesion characteristics (localization, depth and size), and the clinical findings of each case (Table 1). Complete blood count (CBC) and serum chemistry profile were evaluated before anesthesia.

Table 1. Breed, age, sex, affected eye, lesion characteristics (localization, depth and size), and the clinical findings of dogs

No.	Breed	Age	Sex	Eye	Lesion Localization-Depth	Size of Lesion (mm)	Vasc	Associated findings	Follow-up period	Clinical Outcome	Comments
1.	Pekingese	2yrs	M	OS OD	OD: Nasal-Stroma OS: Central-descement	OS: 5-6 OD: 4-8	OD: ++ OS: +	OD: Perilimbal corneal vascularization and diffuse corneal edema OS: Corneal edema and vascularization	5 months	Visual	Mild corneal fibrosis
2.	Pug	3yrs	F	OS	Central-descement	OS: 7-8	OS: +	OS: Corneal vascularization and diffuse edema	4 months	Visual	Mild corneal fibrosis and pigmentation
3.	Pug	4mths	M	OS	Central-descement	OS: 6-7	OS: +	OS: Diffuse corneal edema, perilimbal vascularization, hypopyon	6 months	Visual	Mild corneal pigmentation
4.	Pekingese	10yrs	M	OS	Central-Stroma	OS: 11-13	OS: ++	OS: Diffuse corneal edema and vascularization	6 months	Visual	Moderate corneal fibrosis-corneal pigmentation
5.	Pekingese	9yrs	F	OD	Paracentral-Stroma	OD: 4-6	OD: -	OD: Corneal edema and pigmentation	3 mths	Visual	Mild corneal fibrosis and pigmentation
6.	French Bulldog	7yrs	M	OD	Central-descement	OD: 6-8	OD: ++	OD: Perilimbal corneal vascularization, diffuse edema	2 mths	Visual	Mild corneal fibrosis
7.	Pug	5 yrs	M	OS	Paracentral-stroma	OS: 4-7	OS: ++	OS: Corneal edema, vascularization, granulation tissue	3 mths	Visual	Mild corneal fibrosis
8.	Pug	7 yrs	F	OS- OD	OS: Paracentral, stroma OD: Central, descement	OS: 2-5 OD: 7-11	OS: - OD: ++	OD: Corneal vascularization, granulation tissue and diffuse edema OS: Corneal edema	10 mths	OS: Visual OD: ---	Advanced corneal fibrosis and pigmentation
9.	Dogo Argentina	6yrs	M	OS- OD	OD: Central, OS: Central: descement	OS: 3-4 OD: 8-11	OS: + OD: ++	OD: Diffuse corneal edema, granulation tissue OS: Diffuse edema and vascularization	6 mths	Visual	Mild corneal fibrosis
10.	Pekingese	5yrs	F	OS	Central: descement	OS: 9-11	OS: +	OS: Focal corneal edema	4 mths	Visual	Mild corneal fibrosis
11.	English Setter	3yrs	F	OD	Central: descement	OD: 3-5	OD: +	Corneal edema and vascularization	3 mths	Visual	---
12.	Pug	2yrs	F	OS	OS: Central, stroma	OS: 4-6	OS: +	Diffuse corneal edema, perilimbal vascularization	3 mths	Visual	Mild corneal fibrosis
13.	Pug	12yrs	F	OD	OD: Central, descement	OD: 7-8	OD: +	Focal corneal edema, hypopyon	4 mths	---	Advanced corneal fibrosis and pigmentation
14.	Shih Tzu	5yrs	M	OD	OD: Central, descement	OD: 3-4	OD: -	Focal corneal edema	5 mths	Visual	Mild corneal fibrosis

Preparation for surgery. Ceftriaxone (Novosef, 20-30 mg/kg intravenous), and meloxicam analgesia (Melox, 0.2ml/kg subcutaneous) were administered half an hour before the operation. All the dogs were anesthetized with xylazine (Basilazin, 1 mg/kg intravenous) for premedication, ketamine (Alfamine, 5 mg/kg intravenous) for induction, and isoflurane (Forane) 2-3% for anesthesia maintenance. The surface of the affected eyes was irrigated with 0.1% povidone iodine solution while the eyelids were stained with 1% betadine, and prepared for the operation. Before the operation, the PRF membrane was prepared from the patients' blood samples under sedation.

Preparation of the canine PRF membrane. The preparation of the autologous canine PRF membrane was performed with slight modifications to the method described by CHOUKRON et al. 2006 for preparation of an autologous human PRF membrane. To obtain the PRF membrane, 5 to 8 mL of fresh blood was collected from the jugular vein into two 10mL anticoagulant-free tubes with a butterfly intra-catheter (19-21 G), under sedation prior to surgery (Fig. 1). The tubes were immediately centrifuged at 2700 rpm for 12 min using a Hettich 200 EBA model centrifuge. After centrifugation, platelet-poor plasma (PPP) was accumulated at the top of the tube, platelet-rich fibrin gel in the middle, and red blood cells at the bottom (Fig. 2). The PPP was then collected by a syringe. The fibrin gel in the middle part of the sample and the red blood cells

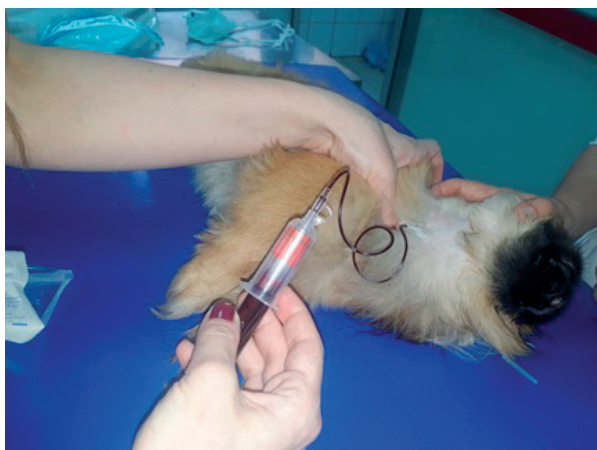

Fig. 1. Blood collection from the jugular vein into tubes



Fig. 2. After centrifugation, there is a fibrin clot in the middle of the tube between the cell free plasma layer at the top and red blood cells at the bottom.

underneath were gently removed from the tube using forceps, and the red blood cells below were cut out with sterile scissors (Fig. 3). The clots were gently pressed between a sterile gauze to obtain the PRF membrane to be sewn onto the corneal ulcer bed (Fig. 4). One sample of fibrin gel was obtained from each of the blood samples in two tubes taken

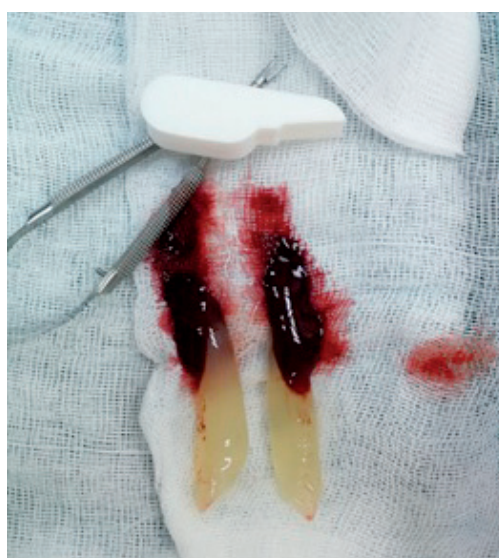

Fig. 3. The fibrin clot (platelet-rich fibrin) was separated from the underlying red bodies with the help of a pair of scissors.

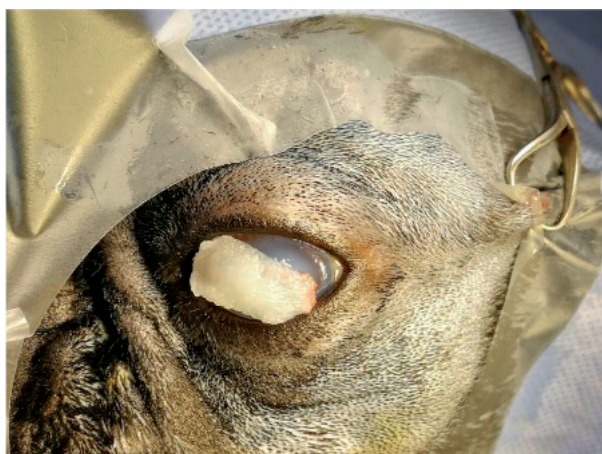

Fig. 4. The appearance of the PRF membrane

from all patients, and the other was formed into two PRF membranes thicker than the first. The PRF membranes were cut into the appropriate size for the corneal lesions.

Surgery. All patients underwent careful corneal debridement with a 3.2 mm corneal knife to remove necrotic and infected tissue from the corneal ulcer and edge. The width of the corneal defect was determined by fluorescein dye, and measured by Castroviejo calipers (Fig. 5). After corneal debridement, the PRF membrane was applied in two

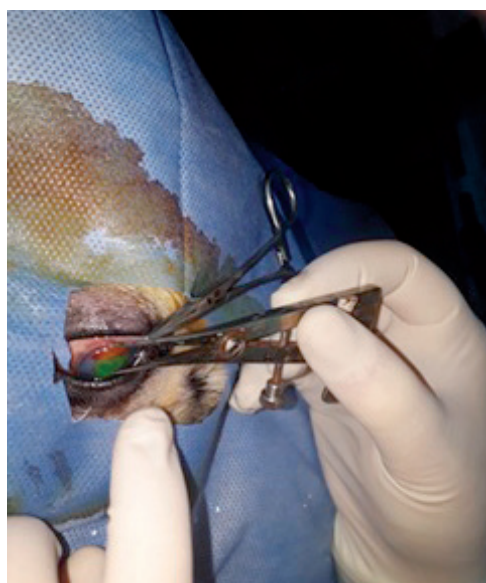

Fig. 5. Case 7: Width measurement of the deep corneal ulcer stained with fluorescein dye.

layers to fill the ulcer bed, provide corneal support, and accelerate healing. Two PRF membranes of different diameters and thicknesses were formed. The first layer membrane was prepared in the size and thickness of the ulcer bed and placed so as to completely fill the ulcer bed without overlapping the adjacent healthy cornea (Fig. 6), and fixation sutures were made from several regions. The thinner and wider second membrane was secured with 8/0 absorbable polyglycolic acid suture material, using simple separate sutures from a distance of 1-2mm to the healthy cornea, to cover the first layer PRF membrane (Fig. 7). During the suturing of the membrane to the cornea, care was taken not to tear the second layer from the areas where the needle passed. At the end of the operation, all patients in the study had a temporary U-shaped nictitating membrane suture implanted using single absorbable 2/0 polyglycolic acid suture material to prevent drying and adherence of the PRF membrane to the cornea. The suture was removed 10 days after surgery, and the PRF membrane was evaluated in all animals. A full ophthalmic examination was performed on the 45th, 60th and 90th days after the operation. The control of vision and threat response were evaluated with a dazzling reflex test. The final condition of the cornea was subjectively classified into four classes: light opacity, medium opacity, severe opacity, and pigmentation.

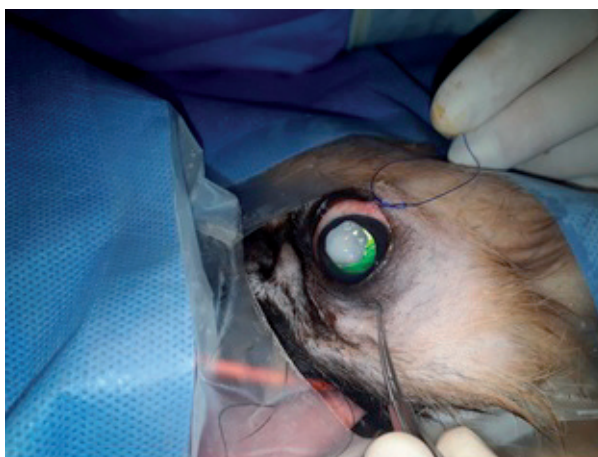

Fig. 6. The appearance of the PRF membrane on the ocular surface

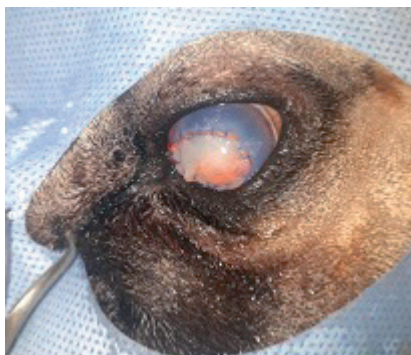


Fig. 7. The PRF membrane graft immediately after placement. The immobilization of the PRF membrane over the defective zone of the cornea with 8-absorbable suture.

Postoperative medical treatment. After the operation, all patients received an Elizabeth collar. Topical ofloxacin HCL eye drops 0.3% (Exocin®, Abdi Ibrahim, Turkey) and sodium hyaluronate (Dryex®, Abdi Ibrahim, Turkey) were administered every hour for the first three days, five times a day for two weeks, and four times a day for one week, until healing occurred and epithelization was completed. Intramuscular systemic antibiotic ceftriaxone (Novosef®, 0.5 g, Zentiva, Turkey) 25 mg/kg for seven days and analgesic meloxicam (Metacam®, 1.5mg/ml, Boehringer Ingelheim, Turkey) (0.2 mg/kg PO) were administered for 3 days. After the sutures were removed from the nictitating membrane 10 days after the operation, the cornea was stained with fluorescein, and the PRF membrane graft and ulcer were closely examined. Integration into the cornea was seen in the slightly modified PRF membrane. Opacity, vascularization, and granulation tissue were observed in the cornea. A topical lubricant carbomer (Thilo tears®, Alcon, Turkey) was applied three times a day for one to two months. Corneal healing and integrity were checked by the fluorescein staining test. Topical tobramycine/dexamethasone (Tobradex®, Novartis, Turkey) was administered four times daily for two weeks to reduce the absorption of the corneal granulation tissue and corneal vascularization, and then it was gradually terminated by reducing the dose by one unit every week. The patients were followed up at two-week intervals until complete corneal healing was achieved.

Results

This study included 14 dogs with deep corneal ulcers. Three of these dogs presented with bilateral corneal ulcers. The breeds were: Pug (6), Pekingese (4), French Bulldog (1), Shih Tzu (1), English Setter (1), and Dogo Argentino (1). In our cases, lesions were mostly seen in brachiocephalic dog breeds (12/14). Gender distribution was seven males (one sterilized) and seven females (two sterilized). The average age was 5.4 years and varied between four months and 12 years. The ulcer was central in 13 eyes (76.4%), nasal in one eye (5.8%), and paracentral in three eyes (17.6%). In addition to corneal ulcers, two dogs had an upper eyelid mass, two had medial entropion and nasal fold trichiasis, and two had pigmentary keratitis. The depth of the corneal ulcer was in the deep stroma layer in six eyes (Fig. 8,9) and the descemet membrane in 11 eyes (Fig. 10). There was no corneal vascularization in two eyes, moderate severe perilimbal cornea in four eyes (Fig. 11), a superficial layer of cornea in five eyes, and severe vascularization and granulation tissue in six eyes. In all eyes, corneal edema was not only around the corneal ulcer; but was diffuse (Fig. 12). The widths of the corneal ulcers are shown in the Table 1. Ten days after surgery, the

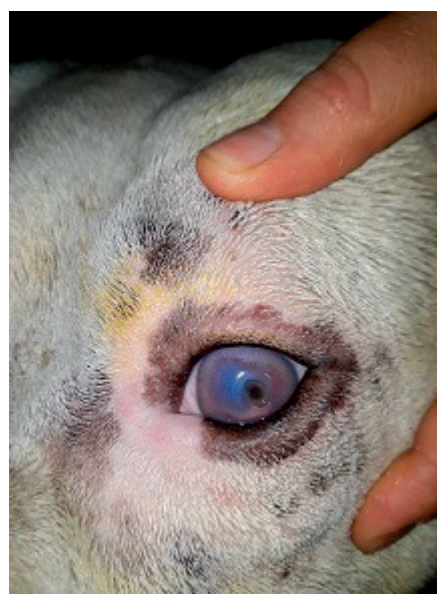

Fig. 8. Preoperative photos of the right and left eyes of case 9 showing deep corneal ulcers.

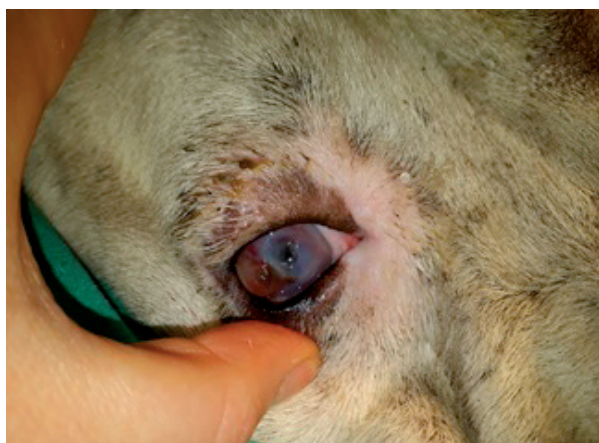

Fig. 9. Preoperative photos of right and left eye of case 9 showing deep corneal ulcer.

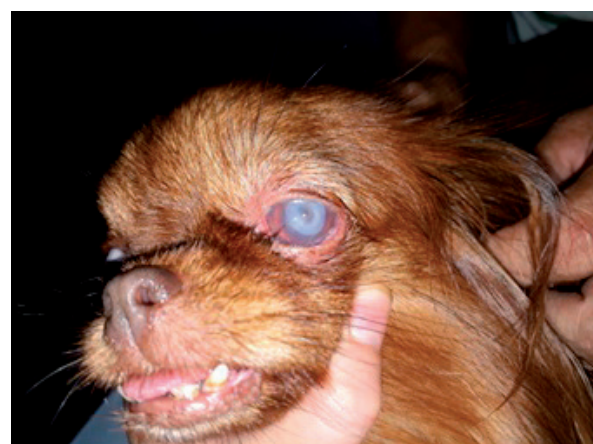

Fig. 10. Case 10 preoperative appearance of the descemetocele.

nictitating membrane flap was removed in all dogs, and the stable closure of the corneal ulcer was observed. The robust non-hypotonic ocular sphere was evaluated by a digital examination. There was mild pain and conjunctival hyperemia when the suture was opened, but no patient showed symptoms of pain or discomfort after one week of follow-up. The risk of corneal perforation disappeared, especially in descemetocele cases. No evidence of secondary infection or inflammation was detected in any case. All eyes had fibrin membrane integration, corneal edema, and moderate to severe corneal neovascularization. The partial remnants of the fibrin membrane and sutures were observed in the previously existing ulcer area, especially at the margins of the membrane.

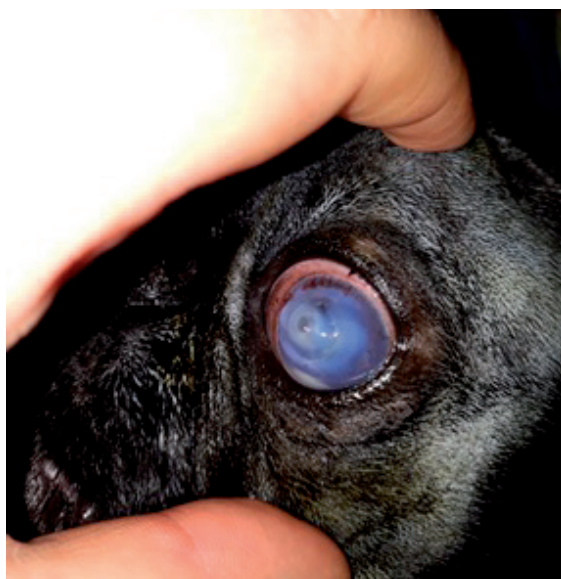


Fig. 11. Case 3: three-year old Pug with a central deep corneal ulcer. Pre-operative appearance of the deep corneal ulcer, perlimbal corneal neovascularization and hypopyon.

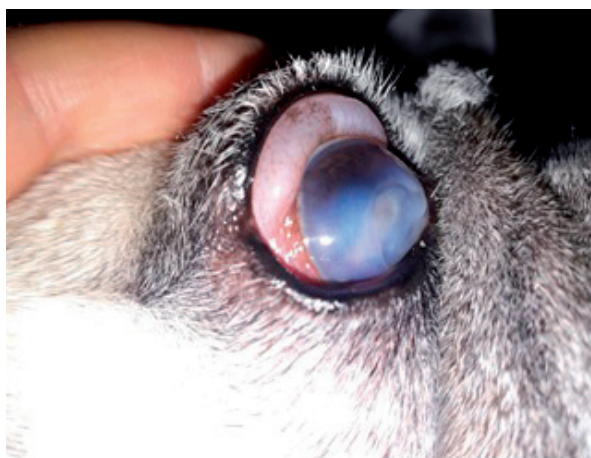


Fig.12. Case 13: 12 year- old Pug with a central deep corneal ulcer.

The presence of an inflammatory reaction with small superficial inflammatory granulomas, that were quite hemorrhagic, was observed around the sutures in all animals. This inflammatory response was evaluated as a clinical sign indicating the integration of the fibrin into the cornea (Fig. 13). It was observed that the slightly modified PRF membrane activated granulation tissue formation in the area of the corneal ulcer, and formed a skeleton for granulation tissue during the healing process.

In some cases, the remodeling of the stroma in the central part of the corneal ulcer was not complete, while in others, it was seen that granulation tissue on the membrane completely filled all the parts of the ulcer.

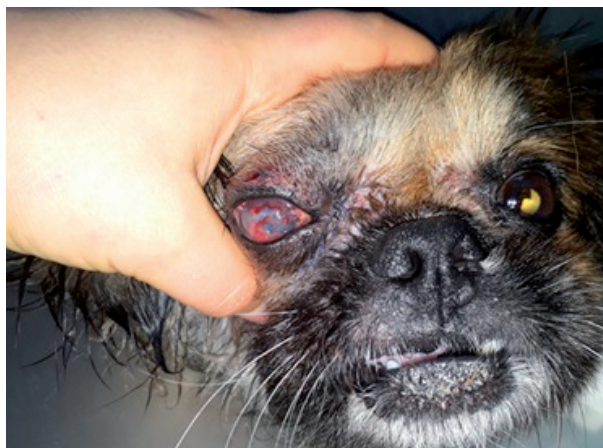

Fig. 13. Case 5: Clinical sign indicating the integration of fibrin into the cornea.

At two weeks postoperatively, no fibrin membrane was seen in the cornea. The ulcer area was thickened and filled with granulation tissue, and there was corneal vascularization and limited edema close to the granulation tissue (Fig. 14, 15). The integration of the fibrin membrane into the cornea and remodeling of the stroma were complete. Three weeks after the operation, the corneal granulation tissue regressed and became thinner, and vascularization decreased (Fig. 16). The anterior chamber of the eye began to appear even in cases of a large area of ulcer on the corneal surface. The area with vascularized, edema and granulation tissue on the surface became smaller, the tissue thinned, and the color began to fade (Fig. 17). In some cases, fibrous tissue formations and pigmentation began to appear in the cornea. The sutures on the cornea were not removed and melted over time in about 30-45 days (Fig. 18). All eyes had complete integration with re-epithelialization and moderate corneal neovascularization 30-45 days after surgery. Corneal transparency began to appear after the fourth week. The granulation tissue disappeared and was replaced by fibrous tissue formation (45-60 days) (Fig. 19). The regression of the vessels, granulation tissue on the corneal surface,

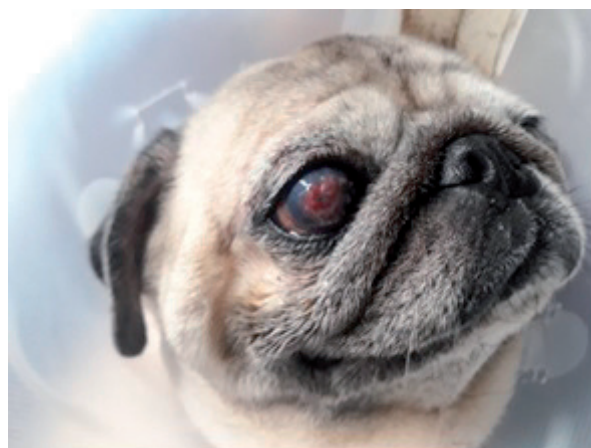


Fig. 14. Case 13: Appearance of the cornea and PRF membrane graft 2 weeks postoperatively. PRF membrane remodelling to the surrounding cornea and granulation tissue.

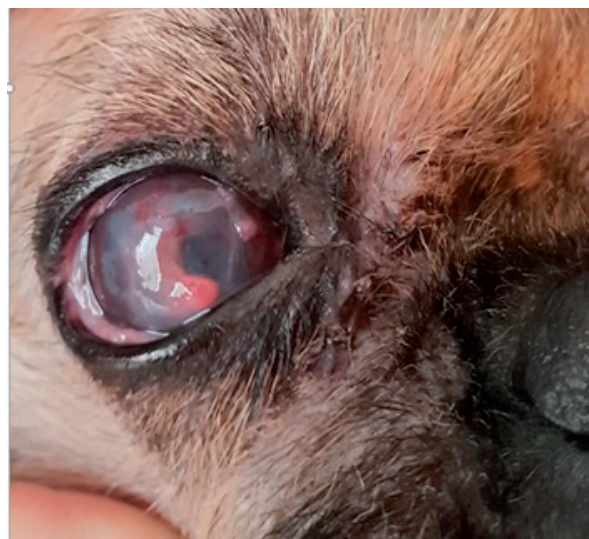

Fig. 15. Case 5: The appearance of intensive granulation tissue in the cornea 17 days after the operation

corneal transparency, and severity of the scar tissue were checked every week. All cases were followed up for at least three months after the operation. Almost all cases had a mild to severe corneal scar that negatively affected corneal transparency. Even after the third week pigmentation occurred in the eye in brachiocephalic breeds. Postoperative corneal pigmentation was mild in 17.6% (3/17) of eyes (Fig. 20), moderate in 5.8% (1/17) (Fig. 21), and advanced in 11.7% (2/17) (Fig. 22, 23); and corneal opacity was mild in 47% (9/17)

(Fig. 24), moderate in 11.7% (1/17), and advanced in 11.7% (2/17). In the study, 15 of 17 eyes recovered functional vision. Corneal pigmentation occurred in four Pugs (case 2, case 3, case 8, case 13), and in two Pekingese (case 4, case 5). In the eyes of case 8, and case 13, severe central corneal opacity and pigmentation developed around the eyes since no topical steroid drop or artificial tear gel could be used properly after epithelialization, and this was a brachiocephalic dog with macro palpebral fissure. Although light reflex was present in these eyes and corneal integrity was present, vision could not be achieved since the field of vision was impaired. In this study, the overall success rate in dogs with deep corneal ulcers was 88.2%.

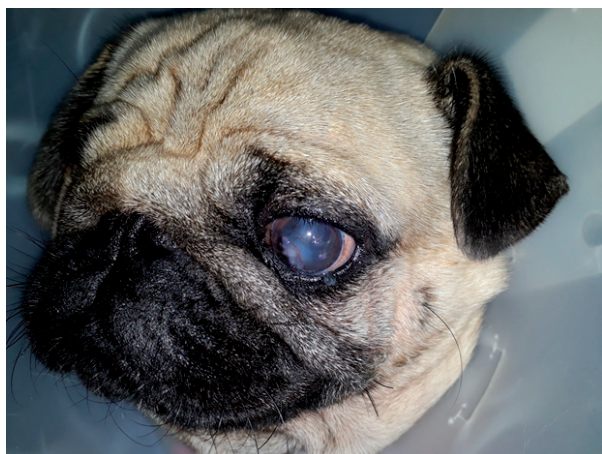


Fig. 16. Case 2: Corneal healing was complete after 21 days without any complications.

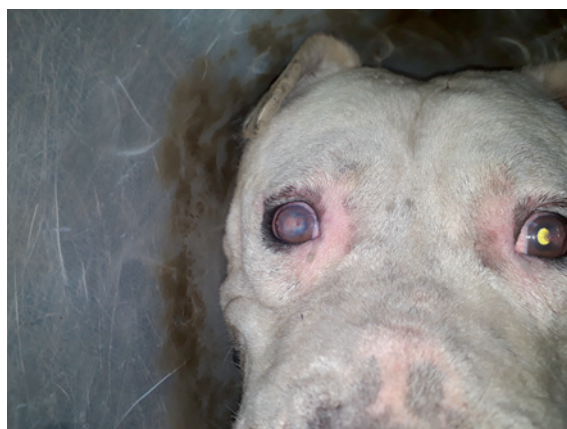

Fig. 17. Case 9: The appearance of the eyes 4 weeks postoperatively. Progressive regression of the central corneal granulation tissue on the PRF membrane.

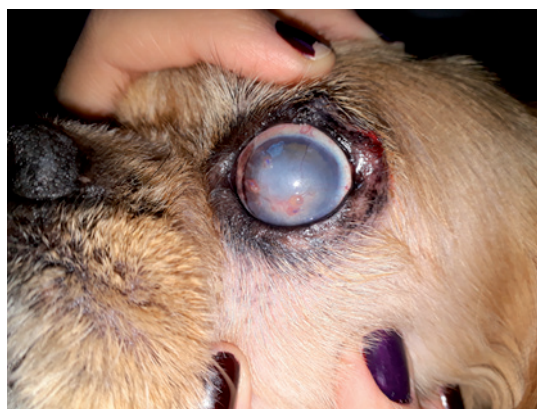

Fig. 18. Case 4: Appearance of the graft 30 days postoperatively. There was intensive corneal fibrosis in the ulcer region and progressive regression

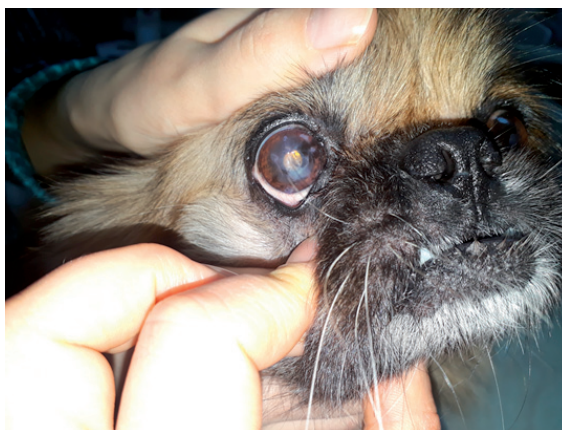


Fig. 19. Case 5: 35 days postoperatively, granulation tissue reduced and mild corneal fibrosis was seen.

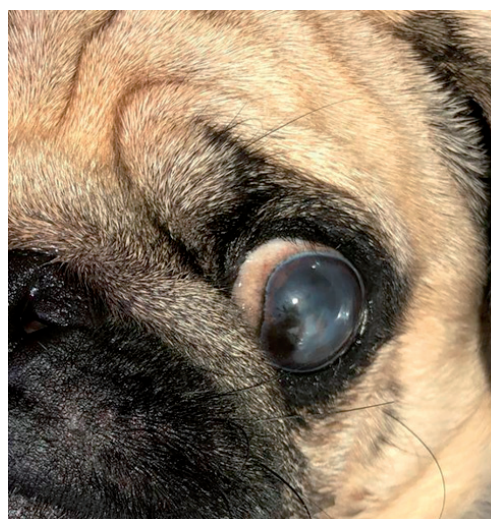


Fig. 20. Case 2: Appearance of the PRF membrane graft 2 months postoperatively.

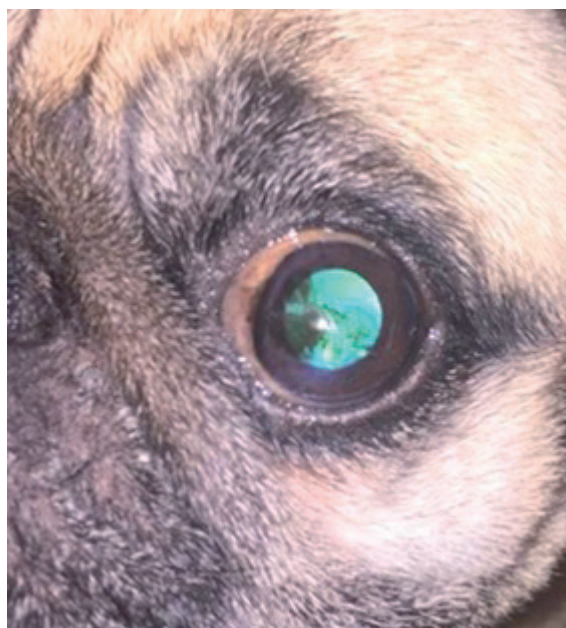


Fig. 21. Case 8: The appearance of the left eye 10 months postoperatively. Partial corneal pigmentation is present

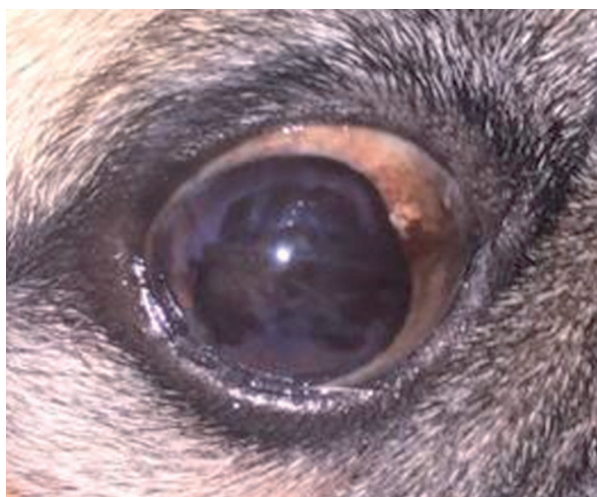

Fig. 22. Case 8: The appearance of the right eye 10 months postoperatively. Extensive corneal pigmentation is present

Discussion

Deep corneal ulcers are defined as stromal collagen loss, and in a cornea of limited thickness, stroma ulcers can deepen into the layer where the rupture occurs in the cornea. These ulcers, which are more common in dogs, especially brachiocephalic breeds, are common in veterinary

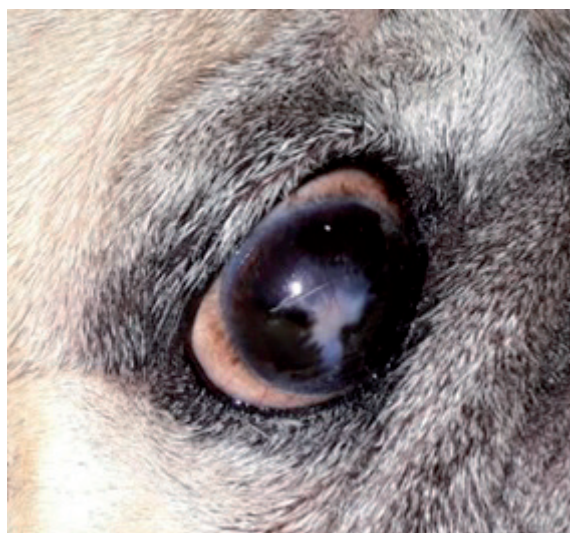


Fig. 23. Case 13: Wide and pronounced corneal opacity and pigmentation following corneal reconstruction with PRF membrane for a large and deep corneal ulcer.

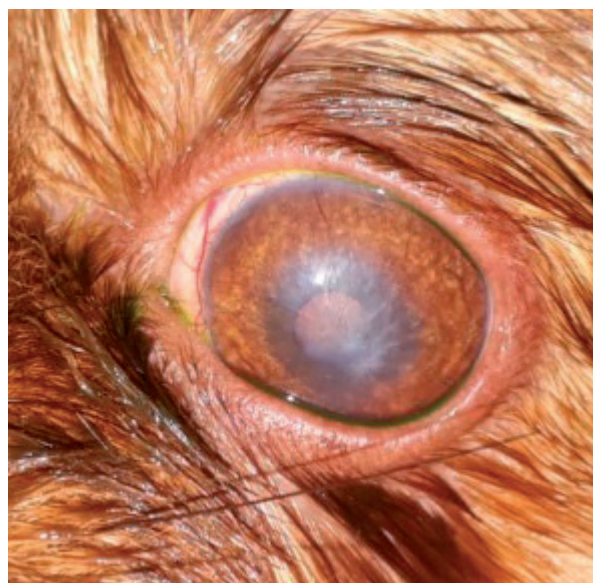

Fig. 24. Case 10: The presence of mild stromal opacity and vascularization 3 months after PRF membrane application for a deep corneal ulcer

ophthalmology and represent an ophthalmological emergency that leads to both vision and eye loss when untreated or improperly treated (BALLAND et al., 2016). Emergency treatment includes many different medical and surgical procedures to protect the integrity and intraocular structures of the

eyeball, repair stromal loss, control the infectious and inflammatory condition, and restore the former cosmetic appearance and function in the best way (DULAURENT et al., 2014). In previous studies on the treatment of these lesions, a variety of techniques have been reported in small animal practice, including tissue adhesives, conjunctivoplasty, corneal-conjunctival transposition, autologous or heterologous corneal transplantations, and biomaterial grafts (amniotic membrane, horse and bovine pericardium and small intestinal submucosa). Different surgical techniques have been described, but according to the authors' knowledge, none of the studies included the success rates for the PRF membrane grafting and treatment of deep corneal ulcers in dogs. This study shows that very good anatomical and visual results were obtained using autologous PRF membrane grafts in the surgical treatment of corneal ulcers.

Corneal transplantation techniques, one of the most preferred methods for corneal reconstruction, aim to provide good transparency and easy healing of the cornea. Unfortunately, corneal transplantation is rarely used in veterinary medicine, and it is mostly preferred for corneal reconstruction in humans since fairly good corneal transparency is achieved after the operation. The difficulty of finding and obtaining a donor cornea, the requirements of the protection medium, the limitations in ensuring endothelial cell viability with cryopreservation methods, and the limited graft size make this method less preferred for application in veterinary ophthalmology. In addition, rejection of the graft material is reported as one of the most common complications. One of the other commonly used methods is the use of conjunctival grafts, which provide reliable and strong mechanical support for many years in the surgical treatment of deep or punctured corneal ulcers in animals, and in recent years amniotic membrane grafts that provide better visual results (DAVIS et al., 2019). The conjunctival graft method, which has been applied for many years, is very successful in wound healing by providing blood vessels, fibroblast and epithelial cells to the thin and weakened corneal stroma, but it is a traumatic technique for the conjunctiva. It creates trauma in the veins on the conjunctiva

surface required for corneal healing. Especially in cases where the defect is large, it is necessary to harvest a large conjunctival tissue to create a large pedicle graft at wound closure. However, corneal fibrosis of the conjunctival tissue applied in this method causes permanent scar formation, decreased corneal clarity and even vision loss in patients with large corneal ulcers (CHOW and WESTERMEYER 2016; SOONTORNVIPART et al. 2003) Therefore, in animals amniotic membrane transposition (AMT) is reported as an alternative method to a conjunctival pedicle graft. This anti-fibrotic membrane, with anti-inflammatory properties contains growth factors. It causes less iatrogenic trauma and less fibrotic scarring than conjunctival pedicles. Although an amniotic membrane is a successful method in the surgical treatment of large and serious corneal defects, there are limitations in its use. The preparation of an amniotic membrane is complex and its availability is limited, and transmission of pathogens always occurs. Therefore, this method is not always preferred by clinicians (LACERDA et al., 2017). Although it is commercially available, it is not always easily accessible and it involves expensive material that requires special permission for use, requiring various antibiotics or special agents, such as a modified solution or special solution conditions. Viral factors can cause biological hazards due to the risk of hosting (DEL CORSO et al., 2012). Therefore, the procedure to be performed should be highly effective, reliable, cost effective, fast, and easily accessible for these lesions. The ulcers in our cases required urgent intervention since they were about to be punctured. AMT membrane, which is very advantageous in terms of vision compared to conjunctivoplasty, was not preferred because it could not be promptly supplied and it would not be accepted by all the owners due to its cost. Considering such disadvantages, the starting point of our study was to develop an alternative treatment method to amniotic membrane graft and corneal transplantation techniques, with conjunctivoplasty which have been used for many years in veterinary ophthalmology. As a fast, economical and repeatable method, it is considered that the PRF membrane can be used as an alternative to these methods.

Due to the above-mentioned limitations in ophthalmic surgery, the PRF (platelet-rich fibrin) membrane, which is considered to be a new method, presents as an alternative option, with a low biological risk and easy access for ocular surface reconstruction (ALÍO et al., 2013; DEL CORSO et al., 2012). This method is the second generation autologous, platelet concentrate developed by CHOUKRON et al. in 2006 for jaw-facial surgery applications. It is a fairly simple technique that minimizes blood manipulation during production. It is a real biomaterial obtained by collecting the venous blood of the patient into tubes, without anticoagulants and centrifuging immediately before or during surgery. During centrifugation, activated platelets and some leukocytes are trapped in the fibrin matrix (DEL CORSO et al., 2012; KANG et al., 2011; BOLUKBASÍ et al., 2013). Thrombocytes, leukocyte cytokines, stem cells, and various growth factors, such as platelet-derived growth factor, vascular endothelial growth factor, transforming growth factor β , and thrombospondin-1 in the fibrin matrix create a therapeutic effect (KANG et al., 2011). PRF ensures the long-term release of growth factors, which are very important in membrane tissue regeneration, involvement in the surrounding healthy cornea, and stimulation of new collagen lamella synthesis (DEL CORSO et al., 2012; DOHAN et al., 2010; KARDOS et al., 2018). It supports wound healing by ensuring the collection, displacement, proliferation and adhesion of cells necessary for fibrin wound repair in the surface and structure of the membrane (MOGHADDAM and KAZEMÍ 2016). It also provides mechanical support for membrane wound protection, helps primary soft tissue closure, and acts as a stable blood clot for neovascularization and accelerated tissue reconstruction in infected areas, or patients with medical conditions that may delay healing (CAN et al., 2016). When the effect of the PRF membrane on corneal ulcer treatment is evaluated, it is reported that this structure, when placed in healthy corneal tissue, provides stabilization for progressive corneal ulcers, and stimulates the development of new collagen fibers around the membrane (CAN et al., 2016). Also there is no risk of an allergic reaction, it is automatically prepared from the patient's own blood and does not pose

a risk of immunological rejection in the cornea (LACERDA et al., 2017). Studies on the use of PRF in animals are limited (TAMBELLA et al., 2018). According to the review of the literature, this is the first study to describe the use of the PRF membrane as a graft biomaterial in corneal reconstruction surgery in dogs; thus, the results were mostly compared to other methods and several similar studies in humans (CAN et al., 2016). In our study, the transfusion of the PRF membrane obtained from the dog's own blood into 17 eyes of 14 dogs with deep corneal ulcers was performed safely and effectively as an alternative to other methods. The membrane served as a stable blood clot, providing mechanical support to the corneal wounds of patients with severe stromal collagen loss, helping soft tissue closure.

The combination of the mechanical and chemotactic support of PRF makes the membrane suitable for reconstruction, healing and/or maintenance of the ocular surface, and can provide many potential clinical advantages for the surgical treatment of descemetocelles compared to the previously mentioned methods (CAN et al., 2016). The main advantage of a PRF corneal graft compared to conjunctivoplasty techniques is that it provides rapid restoration of corneal integrity in deep ulcers, especially in the emergence of the membrane (DEL CORSO et al., 2012; DOHAN et al., 2010). In conjunctival graft applications that have been routinely used in dogs for many years, it has been observed that visual impairment, severe permanent scar tissue formation and the visual loss in the anterior segment encountered in large lesions of the cornea do not occur frequently when this method is used (SOONTORNVĪPART et al., 2003). In addition, PRF membrane graft is a reconstruction material for corneal defects (excluding perforation) of almost any size and depth, and has been previously reported with low complications. When the applications in corneal reconstruction were evaluated, LACERTA et al., 2017 reported an 86% success rate by corneal graft technique; CHOW and WESTERMEYER (2016) an 81% success rate with the Acell Vet technique; BALLAND et al., 2016 achieved a 96% success rate with the acellular matrix technique, while in our study, an 88.2% success rate was achieved with the PRF technique.

As in penetrating keratoplasty applications, that have achieved very good results in human corneal reconstruction, there is no limitation in material size (HANSEN and GUANDALINI, 1999). When PRF becomes a membrane, it folds very easily due to its flexible structure, and provides easy closure of large defects and ease of manipulation. Depending on the condition of the wound, larger graft material than the existing defect can be prepared as required (CAN et al., 2016). In this study, different sizes of PRF membrane grafts were easily applied to corneal wounds ranging from 2 mm to 13 mm in 17 eyes. The membrane provided adequate mechanical support on the wound in all cases, although the size of the wound was wide, and in all cases, no sub-membrane corneal perforation occurred during the post-operative medical treatment in any of the cases.

After the graft materials are applied in corneal ulcer treatments, a temporary nictitating membrane is applied to protect the operative area mechanically from eyelid movements, to prevent dehydration of the membrane and to adhere to the tissue under it. The flaps of the nictitans membrane were left in place for 14 days by VANORE et al., 2007, 18 days in the study conducted by BALLAND et al., 2016 and 21 days by GOULLE, 2012 after small intestinal submucosa (SIS) grafts. Regarding the PRF membrane method, there are no reported studies in cats and dogs, or regarding the residence time of the sutures. We chose 10 days for the sutures in our study, having in mind the appearance of the PRF membrane on the corneal surface and the easiness of the control of the whole process. Ten days after the operation, the nictitans membrane flap sutures were removed to examine membrane integration, corneal integrity, and corneal infection status. In our experience, we observed that the application of the nictitans membrane provided good results, protected the membrane and prevented it from drying out, and the processing time was well suited for this method. However, we continued topical antibiotic and artificial tear treatment since the corneal ulcers were not epithelialized after the sutures were removed. For the antibiotic, we preferred to use ofloxacin from the broad-spectrum fluoroquinolone group, which is known to have high corneal penetration.

In the transposition of biomaterials, the response and minimal inflammation of the recipient tissue is dependent on intercellular binding, tissue absorption, and controlled cellular migration, differentiation and proliferation. Ideally, the graft material should be completely degraded and replaced with normal tissue (BALLAND et al., 2016). In human studies, it has been shown that vascularization in PRF membrane application is generally evident within 10-14 days, and epithelialization is generally completed by the third week (CHOW and WESTERMEYER, 2016). In this study, epithelialization was completed in a similar time as reported in the previous studies. Corneal vascularization occurred 10 days after surgery. When the cornea vessels entered the cornea and the graft border, healing and granulation tissue occurred rapidly (2 weeks). The presence of corneal vascularization became an indication of the healing response. After two weeks, the graft was completely dissolved, and integration with the surrounding corneal tissue was observed. Under recovery, the surface area of the PRF membrane narrowed. The border region and corneal ulcer bed were covered with granulation tissue. After three weeks, the granulation tissue began to dissolve slowly, and the cornea became translucent. Corneal vascularization and edema were reduced, and there were small corneal vesicles. After three to four weeks, the anterior segment was easily seen from the graft site. However, in some cases, pigmentation had started in the nasal region before surgery, and brachiocephalic breeds were observed to have pigment invasion into the area of the corneal scar, which made the corneal surface very uneven. The corneal ulcer had healed and was pigmented and slightly thicker than the other areas. On the basis of the appearance of the corneas treated in this study, it is seen that the timetable described was also valid for the cornea. The findings obtained during the graft integration and corneal healing process were consistent with other study results (CAN et al., 2016).

The success rate of the methods used in the surgical treatment of corneal ulcers varies depending on the technique, and the success rate of conjunctivoplasty was high 96% (BALLAND et al., 2016), 93.18% (SOONTORNVIPART et al.,

2003) and 69.8% (GOULLE, 2012). The success of autologous PRF membrane grafts in the treatment of deep corneal ulcers is measured by the repair of the cornea and the continued vision of the patient after treatment (CAN et al., 2016). The results of our procedure were similar to those achieved using other collagen matrix grafts in the treatment of deep corneal ulcers in dogs. Corneal reconstruction using PRF membrane grafts provided an anatomical sphere structure in all cases, and 88.2% of these cases retained their vision. Although epithelialization was completed and topical steroids were applied to eliminate granulation tissue and make the cornea transparent, almost all cases had varying severities of scar tissue. There was minimal scarring in 47% of eyes, moderate in 11.7%, and marked in 11.7%, but vision was still present. Pigmentation was seen in 35.2% of the patients (mild in 17.6%, moderate in 5.8%, and advanced in 11.7%) and low vision probability was present 11.7% eyes that had scars that prevented the anterior segment from being visible from the graft site. There was no incidence of serious complications that resulted in enucleation. The overall results of the study were very promising (88.2% success rate). Although the cornea was not completely transparent due to the membrane grafts in postoperative controls, the cosmetic and functional results were found to be better than conjunctival grafts, and the pet owners were more satisfied. The patient owners stated that they were satisfied with the normal visual behavior shown by their dogs. Two cases had severe corneal pigmentation that prevented postoperative anterior chamber imaging. These patients, who were brachiocephalic dogs, had visual impairment due to pigmentation.

The results of this study showed the positive effect of PRF use on corneal wound healing. The PRF graft supported and strengthened the ulcer area. In addition, its preparation was much quicker and easier than other alternative methods. Although angiogenesis and neovascularization could not be measured in this study using specific techniques, such as immunohistochemistry, VEGF was shown to support wound healing due to the release from the PRF graft. In this study, it was seen that the growth factors released from the PRF membrane

increased the filling of the corneal ulcer region with vascularization and granulation tissue in a short time. Our clinical results confirm that PRF can be considered as a biomaterial that promotes healing because it provides excellent recovery due to the presence of platelets, leukocytes, cytokines and stem cells in its molecular structure.

Conclusion

An autologous PRF membrane graft is an effective surgical method for severe corneal defects that require urgent treatment, due to its practical availability and application. The graft provides adequate ocular support, and good functional and cosmetic results. Although corneal transparency due to membrane grafts was not complete in postoperative controls, it was found that the cosmetic and functional results were better than when using conjunctival grafts, and the pet owners were more satisfied. To the best of our knowledge, this is the first animal study to demonstrate the effectiveness of PRF membranes in corneal wound healing in dogs. Although the results were quite successful, some parameters, such as wound area imaging and scar formation intensity, need to be optimized.

Acknowledgement

We acknowledge the veterinarians and owners who assisted with recruitment for this study.

Conflict of interest

The authors declare no conflicts of interest

References

- ALÍO, J. L., A. E. RODRÍGEZ, L. M. MARTÍNEZ, A. L. RÍO (2013): Autologous fibrin membrane combined with solid platelet-rich plasma in the management of perforated corneal ulcers: a pilot study. *JAMA Ophthalmol.* 131, 745-751.
DOI: 10.1001/jamaophthalmol.2013.2474
- BALLAND, O., A. S. POÏNSARD, F. FAMOSE, F. GOULLE, P. F. ISARD, I. MATHEÏSON, T. DULARENT (2016): Use of a porcine urinary bladder acellular matrix for corneal reconstruction in dogs and cats. *Vet. Ophthalmol.* 19, 454-463.
DOI: 10.1111/vop.12326

- BARACHETTI, L. (2010): Amniotic membrane transplantation for ocular surface reconstruction in veterinary medicine. Università degli Studi di Milano.
- BOLUKBAŞI, N., S. YENİYOL, M. S. TEKKESİN, K. ALTUNATMAZ (2013): The use of platelet-rich fibrin in combination with biphasic calcium phosphate in the treatment of bone defects: a histologic and histomorphometric study. *Curr Ther Res Clin E.* 75, 15-21. DOI: 10.1016/j.curtheres.2013.05.002
- CAN, M. E., G. D. CAN, N. CAGİL, H. B. ÇAKMAK, N. SUNGU (2016): Urgent therapeutic grafting of platelet-rich fibrin membrane in descemetocoele. *Cornea.* 35, 1245-1249. DOI: 10.1097/ICO.0000000000000917
- CAN, M. E., H. B. ÇAKMAK, C. G. DERELİ, H. ÜNVERDİ, Y. TOKLU, S. HÜCEMENOĞLU (2016): A novel technique for conjunctivoplasty in a rabbit model: platelet-rich fibrin membrane grafting. *J Ophthalmol.* 1965720. DOI: 10.1155/2016/1965720
- CHOUKROUN, J., A. DİSS, A. SİMONPIERİ, M. O. GİRARD, C. SCHOEFFLER, S. L. DOHAN, D. M. DOHAN (2006): Platelet-rich fibrin (PRF): a second-generation platelet concentrate. Part IV: clinical effects on tissue healing. *Oral Surg Oral Med O.* 101, e56-e60. DOI: 10.1016/j.tripleo.2005.07.011
- CHOW, D. W., H. D. WSTERMEYER (2016): Retrospective evaluation of corneal reconstruction using AC ell Vet™ alone in dogs and cats: 82 cases. *Vet Ophthalmol.* 19, 357-366. DOI: 10.1111/vop.12294
- DAVIS, A. M., C. M. RIGGS, D. W. Y. CHOW (2019): The use of porcine urinary bladder matrix (UBM) to repair a perforated corneal ulcer with iris prolapse in a horse. *Equine Vet. Educ.* 31, 172-178.
- DEL CORSO, M., A. VERVELLE, A. SİMONPIERİ, R. JİMBO, F. INCHİNGOLO, G. SAMMARTİNO, M. DOHAN, D. EHRENFEST (2012): Current knowledge and perspectives for the use of platelet-rich plasma (PRP) and platelet-rich fibrin (PRF) in oral and maxillofacial surgery part 1: Periodontal and dentoalveolar surgery. *Curr Pharm Biotechno.* 13, 1207-1230. DOI: 10.2174/138920112800624391
- DOHAN, E. D., N. LEMO, R. JİMBO, G. SAMMARTİNO (2010): Selecting a relevant animal model for testing the in vivo effects of Choukroun's platelet-rich fibrin (PRF): rabbit tricks and traps. *Oral Surg Oral Med O.* 110, 413. DOI: 10.1016/j.tripleo.2010.05.057
- DULARENT, T., T. AZOULAY, F. GOULLE, A. DULARENT, M. MENTEK, R. L. PEIFFER, P. F. ISARD (2014): Use of bovine pericardium (Tutopatch®) graft for surgical repair of deep melting corneal ulcers in dogs and corneal sequestra in cats. *Vet Ophthalmol.* 17, 91-99. DOI: 10.1111/vop.12047
- GOULLE, F. (2012): Use of porcine small intestinal submucosa for corneal reconstruction in dogs and cats: 106 cases. *J Small Anim Pract.* 53, 34-43. DOI: 10.1111/j.1748-5827.2011.01149.x
- HANSEN, P. A., A. GUANDALİNİ (1999): A retrospective study of 30 cases of frozen lamellar corneal graft in dogs and cats. *Vet Ophthalmol.* 2, 233-241. DOI: 10.1046/j.1463-5224.1999.00084.x
- KANG, Y. H., S. H. JEON, J. Y. PARK, J. H. CHUNG, Y. H. CHOUNG, H. W. CHOUNG, P. H. CHOUNG (2011): Platelet-rich fibrin is a Bioscaffold and reservoir of growth factors for tissue regeneration. *Tissue Eng Part A.* 17, 349-359. DOI: 10.1089/ten.TEA.2010.0327
- KARDOS, D., I. HORNYAK, M. SİMON, A. HİNSENKAP, B. MARSCHALL, R. VARDAI, S. NEHRER (2018): Biological and mechanical properties of platelet-rich fibrin membranes after thermal manipulation and preparation in a single-syringe closed system. *Int. J. Mol. Sci.* 19, 3433. DOI: 10.3390/ijms19113433
- KAYA, H., G. PEKEL (2015): The effects of topical and subconjunctivally injected bevacizumab and sesamol in experimental rat model. *Turk J Ophthalmol.* 45,31-36. (in Turkish)
- LACERDA, R. P., M. T. PENA GİMENEZ, F. LAGUNA, D. COSTA, J. RİOS, M. LEİVA (2017): Corneal grafting for the treatment of full-thickness corneal defects in dogs: a review of 50 cases. *Vet Ophthalmol.* 20, 222-231. DOI: 10.1111/vop.12392
- MOGHADDAM, A. J., D. KAZEMİ (2016): Evaluating the Feasibility of Esophagotomy Suture Line Reinforcement Using Platelet Rich Fibrin Membrane and Its Effect on Wound Healing. *Iran J Vet Surg.* 11, 9-15.
- SOONTORNWİPART, K., N. TUNTİVANİCH, H. KECOVA, P. RAUSER (2003): Conjunctival pedicle graft in dogs and cats: a retrospective study of 88 cases. *Acta Vet Brno.* 72, 63-69.
- TAMBELLA, A. M., S. MARTİN, A. CANTALAMESSA, E. SERRİ, A. R. ATTİLLİ (2018): Platelet-rich Plasma and Other Hemocomponents in Veterinary Regenerative Medicine. *Wounds.* 30, 329-336.
- TUNTİVANİCH, N., K. SOONTORNWİPART, P. TUNTİVANİCH (2006): The use of porcine small intestinal submucosa in ten cases of canine corneal staphyloma. *Thai J Vet Med.* 36, 29-36.
- VANORE, M., S. CHAHORY, G. PAYEN, B. CLERC (2007): Surgical repair of deep melting ulcers with porcine small intestinal submucosa (SIS) graft in dogs and cats. *Vet Ophthalmol.* 10, 93-99. DOI: 10.1111/j.1463-5224.2007.00515.x

Received: 12 September 2020

Accepted: 18 January 2021

DEMIR, A., D. O. ERDIKMEN, Z. T. SEVIM, Y. ALTUNDAĞ: Primjena autologne fibrinske membrane obogaćene trombocitima (PRF) u liječenju dubokih čireva rožnice u pasa. *Vet. arhiv* 92, 443-458, 2022.

SAŽETAK

Čirevi rožnice mogu oštetiti vid u pasa. Cilj je ovog istraživanja bio procijeniti kliničku učinkovitost fibrinske membrane obogaćene trombocitima (PRF), kao nove alternative kirurških metoda u liječenju čireva rožnice. Četrnaest pasa (17 očiju) različitih pasmina i dobi, s dubokim čirevima rožnice liječeno je kirurški transplantacijom. Čir na rožnici u svih je pacijenata bio zatvoren autolognom fibrinskom membranom obogaćenom trombocitima. Prvih 10 dana nakon kirurškog zahvata uočeno je da se fibrinska membrana parcijalno talila, dok se na čiru i oko njega pojavilo epitelizacijsko i granulacijsko tkivo zbog graft materijala. Bol je znatno ublažena, a upala konjunktive osjetno smanjena. Od 20. dana nakon kirurškog zahvata granulacijsko je tkivo postupno očišćeno. Pokazalo se da je svim psima vraćen vid. Najčešće su komplikacije nakon kirurškog zahvata bile pigmentacija rožnice i fibroza različita stupnja. Rezultati istraživanja pokazuju da je autologna fibrinska membrana obogaćena trombocitima sigurna, korisna i učinkovita kirurška alternativa u liječenju dubokih čireva rožnice u pasa.

Ključne riječi: autologni graft; čir rožnice; descemetokela; psi; fibrinska membrana obogaćena trombocitima
