

Local treatment of canine chronic ulcerative stomatitis using adipose tissue derived mesenchymal stem cells – a case report

Agustina Algorta^{1,2*}, Gabriela Turini², Juan Martín Eguren², Ana María Grande², Kevin Yaneselli¹, Uruguaysito Benavides¹, and Jacqueline Maisonnave¹

¹*Immunology and Immunotherapy Unit, Department of Patobiology, Veterinary School University of the Republic Montevideo, Uruguay*

²*Dentistry Service, Department of Clinic and Veterinary Hospital, Veterinary School University of the Republic Montevideo, Uruguay*

ALGORTA, A., G. TURINI, J. M. EGUREN, A. M. GRANDE, K. YANESELLI, U. BENAVIDES, J. MAISONNAVE: Local treatment of canine chronic ulcerative stomatitis using adipose tissue derived mesenchymal stem cells – a case report. *Vet. arhiv* 92, 359-367, 2022.

ABSTRACT

Canine chronic ulcerative stomatitis (CCUS) is a condition characterized by chronic pain, associated with oral ulceration, inflammation and mucosal necrosis. We report the case of a 5-year-old female Akita Inu canine with sialorrhea, halitosis, oral ulcers, submandibular lymphadenopathy and substantial oral discomfort. After a poor response to conventional scaling and antibiotic treatment, the patient improved when prednisolone was administered at a dose of 1mg / kg daily. Aggressive immunosuppressive treatments and teeth extractions were ruled out, so cellular therapy was started. This study evaluates the effect of allogeneic thawed and expanded canine adipose tissue-derived mesenchymal stem cells (AT-MSCs) therapy in a case of CCUS. Four local injections of AT-MSCs (3.5 to 8×10^6 cells) were administered every 3–4 weeks under general anesthesia and immediately after dental scaling. A higher dose of AT-MSCs (22×10^6 cells) was injected 5 months later under the same conditions. After the AT-MSCs treatment, the patient showed an improvement in oral lesions and reduction of oral pain for at least 4 weeks. We concluded that a dose of 1×10^6 AT-MSCs/kg body weight reduced the symptoms of CCUS for at least one month in this case. To our knowledge, this is the first description of allogeneic AT-MSC therapy on canine chronic ulcerative stomatitis.

Key words: dog; gingivostomatitis; stem cells; adipose tissue; oral ulceration

Introduction

Canine chronic ulcerative stomatitis (CCUS) is a chronic and painful clinical condition characterized by focal to diffuse oral ulceration, inflammation, and mucosal necrosis (ANDERSON et al., 2017). Erosion or ulceration usually occur

on mucosa opposite to plaque-retentive surfaces, but can progress to a generalized stage. These lesions also occur on the lateral margin of the tongue, glossopalatine folds and borders of the lips. The initial approach of scaling, home oral care,

*Corresponding author:

Agustina Algorta, Veterinary School University of the Republic Montevideo, Uruguay, Ruta 8 km18, Phone: +598 1903 int 2503; E-mail: agustinaalgorta@gmail.com

antibiotics and anti-inflammatory drugs was unable to control symptoms, and immunosuppressive drugs such as steroids and cyclosporine were necessary to control symptoms (LOMMER, 2013; LOBPRISE and DODD, 2019). Controlling plaque is crucial but not possible in every patient (LOBPRISE and DODD, 2019). When medical treatments cannot control symptoms, extraction of teeth opposite to mucosal ulcers may be proposed (LOBPRISE and DODD, 2019), but when applied, approximately 40% of the cases do not improve (ANDERSON et al., 2020). The etiology of CCUS is yet to be elucidated, but the most supported theory is that the chronic presence of dental plaque leads directly, or indirectly, to oral mucosal inflammation and ulceration. Previous studies in dogs with CCUS suggest an immune-mediated pathogenesis (ANDERSON et al., 2020, 2017). ANDERSON et al. (2017) also found that the histopathological morphology of the affected mucosa showed an interface mucositis described as a dense lichenoid lymphocytic-plasmacytic infiltrate of B cells, CD3+ T cells, Treg cells and IL-17-producing non-T cells, at the interface between the oral epithelium and subepithelial connective tissue. More recently, this group classified the histological findings into 3 types: lichenoid mucositis, granulomatous inflammation and deep stomatitis, the first being the most common (ANDERSON et al., 2020). Cells that produce IL-17 have been found in tissues affected by chronic idiopathic inflammation in dogs, including inflammatory bowel disease, chronic gingivitis, chronic rhinitis, and chronic dermatoses. Previous studies (KOL et al., 2016) demonstrated that mesenchymal stem cells (MSCs) inhibit differentiation of Th17 *in vitro*, which makes MSCs a promising alternative treatment for Th17 driven immune-mediated or autoimmune disorders. It has also been shown that canine adipose tissue-derived MSCs (AT-MSCs) produce immunomodulatory factors (KANG et al., 2008) and can suppress *in vitro* peripheral blood mononuclear cells (RUSSELL et al., 2016). Cats suffering feline chronic gingivostomatitis, another painful immune-mediated oral mucosal inflammatory disease, treated with both autologous and allogeneic AT-MSCs, showed complete or

partial remission of symptoms (ARZI et al., 2017, 2016). Feline chronic gingivostomatitis immunopathology is still elusive, but high levels of circulating activated T CD8+ were found in diseased cats, oral mucosa infiltration is characterized by B cells, T CD4+ and CD8+ (ARZI et al., 2017, 2016; VAPNIARSKY et al., 2020) and recent studies observed the upregulation of the IL17 gene in transcriptome analysis of diseased cats (VAPNIARSKY et al., 2020). For these reasons, we believe that MSC therapy could be a useful treatment for CCUS, but its use has not yet been reported in canines. The purpose of this study was to assess the effect of allogeneic canine AT-MSCs for local treatment of CCUS, without performing teeth extractions and without steroidal anti-inflammatory drugs administration.

Materials and methods

Case description. A 5-year-old female client-owned Akita Inu canine, weighing 23 kg, not neutered, presenting sialorrhea, halitosis and significant oral discomfort, was evaluated at the Dentistry Service, Faculty of Veterinary, Uruguay in 2017. These symptoms appeared after parturition and one year prior to the first dental appointment. Oral examination without sedation during the consult showed severe ulcers on the oral mucosa, gingiva, the lateral borders of the tongue contacting with the teeth, gingivitis, severe pseudomembranous ulcers with oral discomfort, vocalizations and reluctance to oral manipulation. The patient was unable to eat dry food. Physical examination of the patient revealed submandibular lymphadenopathy and dull hair. Laboratory analyses were performed. The hemogram showed microcytosis characteristic of this breed, and leukocytosis. Liver and kidney biochemistry were within normal parameters. The initial treatment was based on cefovecine (Convenia, Zoetis) 8mg/kg subcutaneously as an antibiotic, meloxicam (Meloxicvet, John Martin) 0.1mg/kg orally as a single dose in a day (SID) as the non-steroidal anti-inflammatory drug, and chlorhexidine gel (Clorhexidin gingival, Unimedical) 0.12% daily as a local antiseptic for three weeks. There was slight improvement. Periodontal treatment based

on scaling was conducted under general anesthesia. Abundant plaque was removed from the tooth surfaces. There were no missing teeth, and no extractions were made. No periodontal pockets were found. Mucosal cytological analysis was performed by fine needle aspiration and showed lymphoplasmacytic inflammation. A biopsy of the inflamed oral mucosa was performed. An ulcerated mucosal fragment of approximately 0.5cm × 0.5cm was obtained by performing a deep cut using a N°15 surgical blade and fixed in 4% paraformaldehyde. Histopathological analysis showed a total loss of the mucosa, with a slight to moderate increase in conjunctive tissue in the submucosa and mild to moderate diffuse inflammatory exudate of plasma cells (Fig.1). There was no evidence of neoplasia. The histopathological diagnosis was moderated ulcerative plasmacytic stomatitis, which corresponds to a lichenoid inflammation according to the classification of histological CCUS subtypes proposed by ANDERSON et al., (2020). Radiographs were performed without any relevant finding. After one week, the patient's response to conventional treatment with scaling, oral home care consisting of tooth brushing, topical chlorhexidine, topical gel of lidocaine and antibiotics was poor. Prednisolone (Prednisolona, Unimedical) was administered for 3 weeks in decreasing doses, starting with 1mg/kg daily in the first week, 0.5 mg/kg daily for the second week, and 0.5 mg/kg every other day in the third week. The patient

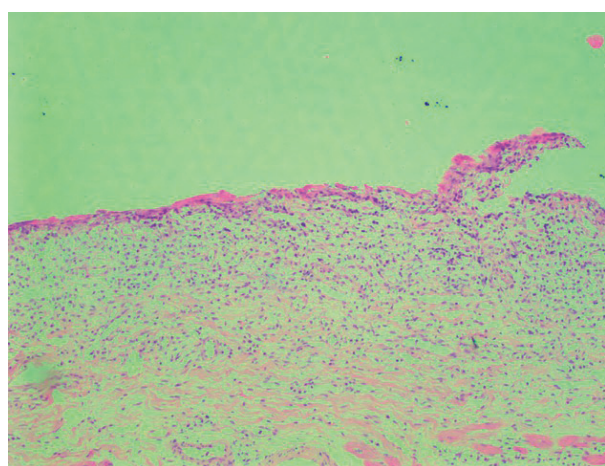


Fig. 1. Histopathology image showing moderated ulcerative plasmacytic stomatitis.

showed clinical improvement when prednisolone was administered at a dose of 1mg/kg daily, but did not control the symptoms at a dose of 0.5 mg/kg daily, suggesting an immune-mediated disorder. Thus, we opted not to perform teeth extraction or aggressive treatment with immunosuppressive drugs, but to use local MSC therapy.

AT-MSCs preparation. Adipose tissue derived MSCs were obtained from healthy young canines during routine ovariectomy, isolated, expanded, characterized by tri-differentiation, cryopreserved in low passage, and stored in the biobank at the Veterinary Faculty, Uruguay (YANESELLI et al., 2018). AT-MSCs from the biobank were thawed and expanded in medium containing Dulbecco's Minimal Essential Medium (DMEM) (Invitrogen), 10% fetal bovine serum (FBS) (Capricorn) and 1% penicillin-streptomycin (Capricorn) at 37°C and 5% CO₂. The culture medium was changed every 3 days. Cells were harvested when they reached 70–80% confluency using trypsin (0.25%). Trypsin was inactivated with a maintenance medium with 10% FBS. The cells were centrifuged at 250×g for 5 minutes and washed 3 times with phosphate buffered saline (PBS). The cells were counted in a Neubauer chamber. After the last washing and centrifugation, the supernatant was extracted and cells were resuspended in 8 mL of saline solution and distributed into two plastic sterile syringes. A low suspension density was used in the different treatments ranging from 437 to 2759 cells/μL. Cells were harvested immediately prior to the procedure and were transported in constant agitation from the laboratory to the hospital, to avoid cell aggregation. The time between loading the cells into the syringes and the injection was a maximum of 20 minutes.

Treatment strategy. The patient received allogeneic AT-MSCs (3.5 to 8 × 10⁶ cells) at weeks 0, 3, 6, 9, and a last higher dose (22 × 10⁶) at week 28, referred to hereafter as treatments 1, 2, 3, 4, and 5, respectively (Table 1); the number of cell passages (P) was P9, P4, P9, P4, and P4, respectively, according to available MSC stock in the biobank. Different donors were used for each treatment. Each treatment was made under general anesthesia and after thorough dental scaling in treatments 1, 3, 4, and 5. The patient was premedicated with

midazolam (Midazolam, Richmond) (0.3 mg/kg), and ketamine (Ketonal, Richmond) (4 mg/kg) intramuscularly. An 18-gauge intravenous catheter was placed in the left cephalic vein. Anesthesia was induced with propofol (Propofol, Fresenius-Kabi) (4 mg/kg) given intravenously until the desired level of induction was achieved. A size 7.5-cuffed endotracheal tube was inserted and isoflurane (Forane, Abbott) anesthesia was maintained at 1.5 – 3% via a low flow, closed-circuit technique. The patient was monitored via continuous electrocardiogram, pulse oximetry and indirect blood pressure. An isotonic electrolyte

solution was administered intravenously at a rate of 5.0 mL/kg/h. Dental scaling was performed with an ultrasonic piezoelectric dental scaler, followed by polishing. Immediately after this, the MSCs suspension was injected with a 22 – 23G needle into the oral mucosa at 4 points per hemiarcade, a total of 16 injection points (Fig. 2.I). Physical and oral examinations were performed 2, 3 and 4 weeks after each treatment. They included blood extraction for hemogram, liver and kidney blood biochemistry, lymph node palpation, any oral discomfort was registered, and ulcers or erosions were registered as mild, moderate or severe. Gingivitis was scored as

Table 1. Clinical presentation of the patient at the moment of each treatment with mesenchymal stem cells (MSCs) + scaling and following controls are shown

Week	Treatment 1			Treatment 2			Treatment 3			Treatment 4			Treatment 5				
	0*	1	2	3*	4	5	6*	7	8	9*	11	12	28*	29	30	31	33
Gingivitis	3	1	2	3	3	3	3	1	2	3	1	2	3	2	2	2	3
Oral ulceration	+++	+	++	++	++	++	++	++	++	++	+	++	++	+++	+	+	+++
Sialorrhea	yes	no	yes	yes	yes	yes	yes	no	yes	yes	no	no	yes	yes	no	no	yes
Halitosis	yes	no	no	yes	yes	yes	yes	no	yes	yes	no	no	yes	yes	no	no	yes
Oral discomfort	yes	no	no	yes	yes	yes	yes	no	yes	yes	no	no	yes	yes	no	no	yes
limphadenopathy	+++	+	+	++	++	++	++	+	+	++	+	+	++	+	+	++	++
Tolerates tooth brushing	no	yes	yes	yes	no	no	no	yes	no	no	yes	yes	no	yes	yes	yes	no
Tolerates dry food	no	yes	yes	no	no	no	no	yes	yes	yes	yes	yes	yes	yes	yes	yes	yes
Tolerates oral manipulation	no	yes	yes	no	no	no	no	yes	no	no	yes	yes	no	yes	yes	yes	no

Abbreviations: Severe +++, moderate ++, mild +. Gingivitis graded 1 to 3. * Moment of MSC injection.

grade 1, 2 or 3, that is, slight, moderate and severe respectively. The presence of halitosis, excessive sialorrhea, reluctance to allow oral manipulation or vocalization during oral examination was also registered, as well as the owner’s perception of oral comfort and appetite. Tooth brushing was indicated daily. Topical lidocaine gel was indicated to control pain. The fifth treatment was done 19 weeks after treatment 4, to avoid overexposure of the patient to general anesthesia. No other anti-inflammatory or immune suppressor drugs, such as prednisolone, were used during treatments 1,2,3 and 4. However, during the period between the fourth and fifth AT-MSC treatments (between weeks 13 and 28), the patient received prednisolone 1mg/kg

intermittently, which was suspended 2 weeks before MSC treatment. To control symptoms during the period without MSC treatment, clindamycin (Clinda-cap, Spifar) 10 mg/kg SID and amoxicillin - clavulanic acid (Clavamox, Zoetis) 25 mg/kg BID and oral home care were administered. We considered the poor response to conventional treatment as the patient’s own control prior to MSCs treatments. This type of self-control has been reported previously for MSC administration (ARZI et al., 2020). The owner of the patient signed an informed consent accepting the MSC treatment. All procedures were approved by the Institutional Ethics Committee on the Use of Animals (CEUA FVET Protocol 887). The total follow-up period of

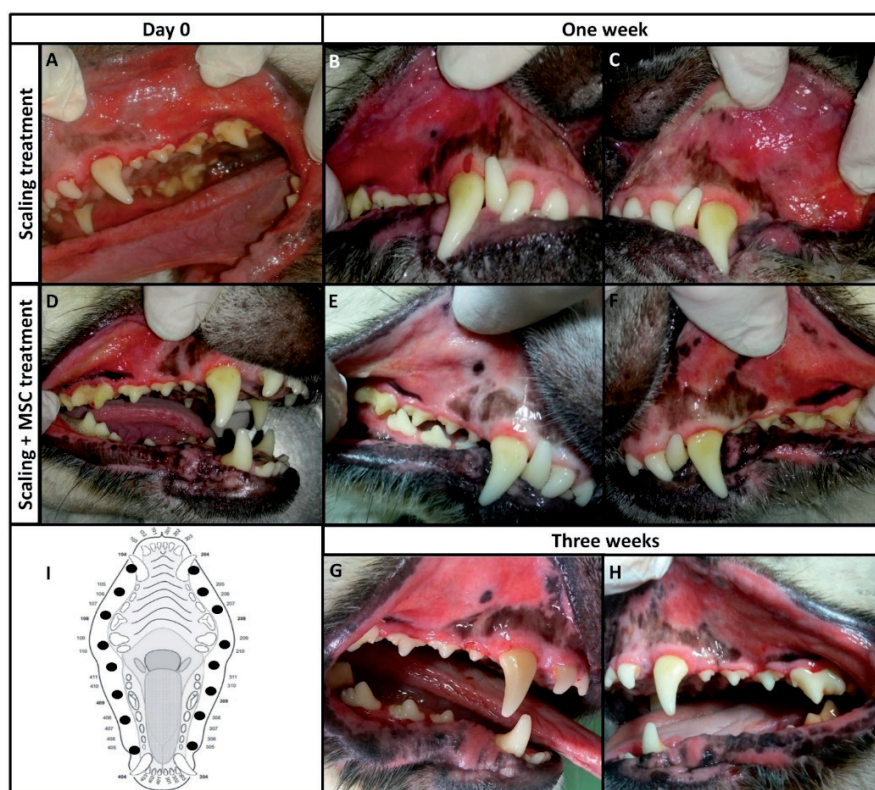


Fig. 2. Clinical evolution of the patient with conventional treatment of scaling at day 0 (A), a week after (B and C) and treatment of scaling plus mesenchymal stem cells (MSCs) injections at day 0 (D), a week later (E and F) and 3 weeks later (G and H).

I. The black dots indicate the mucosal anatomical sites injected with MSCs suspension

the AT-MSC treatment reported in this article was 37 weeks.

Results

After the traditional treatment of scaling and antibiotics, the patient showed only a slight improvement, with return of the original symptoms of sialorrhea, mucosal ulcers, grade 3 gingivitis, oral discomfort and reluctance to tooth brushing or oral manipulation after one week. However, after one week of allogeneic AT-MSCs treatment, the patient showed a partial remission of symptoms: reduction of gingivitis from grade 3 to 1 and general oral mucosa congestion, slight mucosal ulcers, with a notable reduction in oral discomfort, resulting in acceptance of oral manipulation and examination. The owner observed that the patient became more active, started playing again, eating dry solid food, and allowing tooth brushing. After two weeks, the patient still accepted dry solid food and oral

manipulation, showing only slight inflammation of oral mucosa. Three weeks later the patient started to show oral discomfort, sialorrhea was present but she still accepted tooth brushing. This pattern of signs was repeated after the first 4 treatments, except after the second treatment, in which scaling was not performed prior to treatment and the symptoms showed less improvement compared to the MSC treatments with scaling. A summary of clinical evaluations is shown in Table 1 and Figure 2. Biochemical parameters were always within normal values. Hemogram parameters, showing variations in leucocyte count at each treatment are shown in Figure 3. Prior to the fifth treatment, the patient presented severe oral inflammation, severe ulcers, grade 3 gingivitis and intense oral discomfort. After the fifth treatment sialorrhea was observed at week 4, oral mucosa congestion was moderate and ulcers were still present, but the patient could tolerate tooth brushing, eat

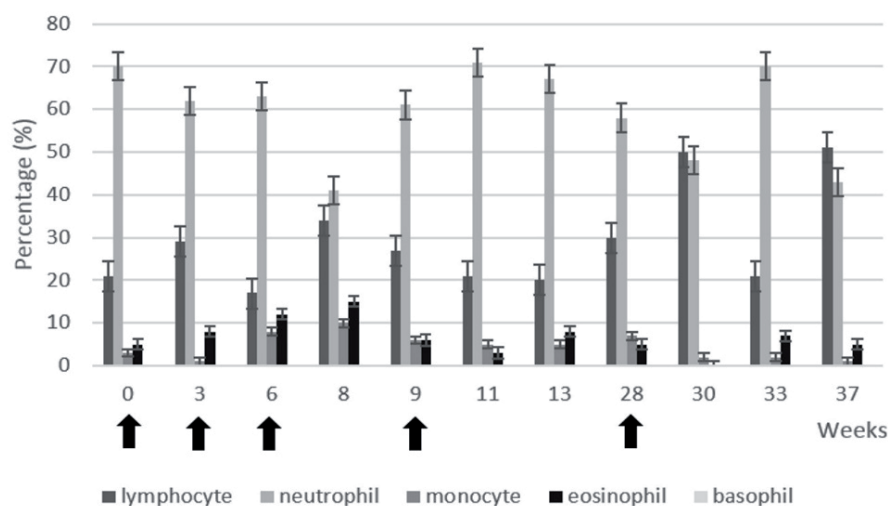


Fig. 3. Relative leukocyte count throughout the mesenchymal stem cells (MSCs) treatment. The black arrows indicate the moment of MSCs injections under general anesthesia

without signs of discomfort and could tolerate oral manipulation up to 6 weeks. No adverse clinical reactions or side effects were observed after local injections of allogeneic AT-MSCs. No clinical improvements were observed after week 6 of treatment 5, when oral ulceration, oral discomfort and sialorrhoea returned and conventional treatment with prednisolone was restarted. We did not use the CUSDAI scoring system because it was published the same year we started this treatment (ANDERSON et al., 2017), so a descriptive record was kept.

Discussion

Clinical improvement was observed after MSC treatment, showing less oral discomfort, a reduction in inflammation and an improvement in general condition for 3 to 4 weeks after the low dose treatments and up to 6 weeks after the high dose treatment.

The AT-MSCs were delivered in low suspension density using plastic sterile syringes. Additionally, we maintained the cell suspension in constant agitation to reduce aggregation and clotting. Over 100,000 cells/ μL is considered highly concentrated and may cause needle clogging and uneven injection (AMER et al., 2017). We preferred several injection sites with a low volume to a few sites

with high volume, to cover an extended mucosal area and to avoid excessive tissue distention in the injection sites, which could lead to chewing lesions or be uncomfortable for the patient. Additionally, the lower volume per injection site was intended to reduce the backflow along the penetration tract due to the applied force (AMER et al., 2017). The MSCs doses used ranged from 0.15 to 0.36×10^6 cells/kg of body weight in treatments 1, 2, 3 and 4. A low dose local treatment produced a 3–4 week improvement of clinical signs. As the local treatment avoids the pulmonary trapping of MSCs, a low dose protocol was designed (less than 0.5×10^6 cells/kg of body weight) and performed. The differences in doses used were due to differences in growth rate between different batches of MSC cultures, which is reflected in the different numbers of harvested cells. Aiming for a long lasting effect, we increased the 5th treatment to 1×10^6 cells/kg of body weight, similar to systemic doses used in other immune mediated diseases (DIAS et al., 2019). MSC treatments have been shown to produce positive results in inflammatory and autoimmune disorders, such as inflammatory bowel disease in dogs treated with 2×10^6 cells/kg body weight AT-MSCs (PÉREZ-MERINO et al., 2015), or refractory atopic dermatitis in dogs treated with 1.5×10^6 cells/kg body weight (VILLATORO et al., 2018). Cats

with refractory gingivostomatitis after full mouth extractions received 2 intravenous transfusion of 20×10^6 cells per cat, almost 5×10^6 cells/kg, showing partial or complete remission up to 24 months of follow-up (ARZI et al., 2017, 2016). Intravenous administration may require higher doses of MSCs than local treatments, possibly due to the MSCs reaching specific inflamed tissues and nonspecific tissues, such as lungs, kidney, liver and bone marrow when administered intravenously (KARP and LENG TEO, 2009). Without MSC treatment, gingivitis and oral mucosa ulcers re-appeared 1 week after scaling, which served as the control prior to MSC injection. After plaque removal, biofilm re-attaches to the dental surface and stabilizes in 48h, causing gingivitis a week later in healthy patients without dental cleaning (UZEL et al., 2011; HARTENBACH et al., 2018). Clinical improvement was observed for three weeks after AT-MSC injection, compared to one week with little improvement when scaling was performed without MSC injection, showing that AT-MSC injection had an effect on the duration of symptom remission. Also, AT-MSC injection without scaling did not show as much improvement as when AT-MSCs and scaling were combined. As expected, no adverse clinical reactions or side effects were observed after local injection of allogeneic AT-MSCs. In general, no adverse effects are observed in local injections of MSCs in companion animals, except for mild inflammation (VOGA et al., 2020). Two weeks after the third and fifth cell injections an increase in lymphocytes and a decrease in neutrophils were observed, as well as symptom remission. This variation could be explained by MSC immunomodulatory properties and their capacity to inhibit Th17 cells (KOL et al., 2016), reducing neutrophil recruitment and increasing the Treg population. However, this variation was not constant, therefore more studies are necessary. Similar results were reported for leukocyte counts in felines with chronic refractory gingivostomatitis treated by systemic MSCs, where decreased neutrophils and lymphocytes were seen after MSC treatment (ARZI et al., 2016, 2017).

Although this is the first report on MSC use for CCUS, future study cases must include the CUSDAI scoring system to generate easily comparable results. Further studies to confirm the effectiveness of allogeneic AT-MSCs for treatment of CCUS will be necessary.

Conclusion

To our knowledge this is the first description of a case of CCUS receiving local treatment with allogeneic AT-MSCs. Doses of 1×10^6 cells/kg body weight or higher may be effective for local treatment of CCUS. Local injection of thawed and expanded allogeneic AT-MSCs, combined with dental scaling should be further studied, as it may be a therapeutic adjuvant to scaling and periodontal treatment for CCUS, although more cases need to be evaluated and protocols standardized.

Acknowledgements

The authors are grateful for the technical support of the veterinary pathologist Dr. Deborah Cesar who performed the histopathological analysis.

References

- AMER, M. H., F. R. A. J. ROSE, K. M. SHAKESHEFF, M. MODO, L. J. WHITE (2017): Translational considerations in injectable cell-based therapeutics for neurological applications: concepts, progress and challenges. *npj Regen. Med.* 2, 23.
DOI: 10.1038/s41536-017-0028-x
- ANDERSON, J. G., A. KOL, P. BIZIKOVA, B. P. STAPELTON, K. FORD, A. VILLARREAL, R. J. JIMENEZ, D. VASILATIS, B. G. MURPHY (2020): Immunopathogenesis of canine chronic ulcerative stomatitis. *PLoS One* 15, 1–19.
DOI: 10.1371/journal.pone.0227386
- ANDERSON, J. G., S. PERALTA, A. KOL, P. H. KASS, B. MURPHY (2017): Clinical and Histopathologic Characterization of Canine Chronic Ulcerative Stomatitis. *Vet. Pathol.* 54, 511–519.
DOI: 10.1177/0300985816688754
- ARZI, B., K. C. CLARK, A. SUNDARAM, M. SPIRET, F. J. M. VERSTRAETE, N. J. WALKER, M. R. LOSCAR, N. FAZEL, W. J. MURPHY, N. VAPNIARSKY, D. L. BORJESSON (2017): Therapeutic Efficacy of Fresh, Allogeneic Mesenchymal Stem Cells for Severe Refractory Feline Chronic Gingivostomatitis. *Stem Cells Transl. Med.* 6, 1710–1722.
DOI: 10.1002/sctm.17-0035

- ARZI, B., E. MILLS-KO, F. J. M. VERSTRAETE, A. KOL, N. J. WALKER, M. R. BADGLEY, N. FAZEL, W. J. MURPHY, N. VAPNIARSKY, D. L. BORJESSON (2016): Therapeutic Efficacy of Fresh, Autologous Mesenchymal Stem Cells for Severe Refractory Gingivostomatitis in Cats. *Stem Cells Transl. Med.* 5, 75–86.
DOI: 10.5966/sctm.2015-0127
- ARZI, B., S. PERALTA, N. FIANI, N. VAPNIARSKY, N. TAECHANGAM, U. DELATORRE, K. C. CLARK, N. J. WALKER, M. R. LOSCAR, M. J. LOMMER, A. FULTON, J. BATTIG, D. L. BORJESSON (2020): A multicenter experience using adipose-derived mesenchymal stem cell therapy for cats with chronic, non-responsive gingivostomatitis. *Stem Cell Res. Ther.* 11, 115.
DOI: 10.1186/s13287-020-01623-9
- DIAS, I. E., P. O. PINTO, L. C. BARROS, C. A. VIEGAS, I. R. DIAS, P. P. CARVALHO, (2019): Mesenchymal stem cells therapy in companion animals: useful for immune-mediated diseases? *BMC Vet. Res.* 15, 358.
DOI: 10.1186/s12917-019-2087-2
- HARTENBACH, F. A. R. R., C. M. SILVA-BOGHOSSIAN, A. P. V. COLOMBO (2018): The effect of supragingival biofilm re-development on the subgingival microbiota in chronic periodontitis. *Arch. Oral Biol.* 85, 51–57.
DOI: 10.1016/j.archoralbio.2017.10.007
- KANG, J. W., K. KANG, H. C. KOO, J. R. PARK, E. W. CHOI, Y. H. PARK (2008): Soluble Factors–Mediated Immunomodulatory Effects of Canine Adipose Tissue–Derived Mesenchymal Stem Cells 694, 681–694.
DOI: 10.1089/scd.2007.0153
- KARP, J. M., G. S. LENG TEO (2009): Mesenchymal Stem Cell Homing: The Devil Is in the Details. *Cell Stem Cell.*
DOI: 10.1016/j.stem.2009.02.001
- KOL, A., N. J. WALKER, M. NORDSTROM, D. L. BORJESSON (2016): Th17 Pathway As a Target for Multipotent Stromal Cell Therapy in Dogs: Implications for Translational Research. *PLoS One* 11, e0148568.
DOI: 10.1371/journal.pone.0148568
- LOBPRISE, H. B., J. R. DODD (2019): *Wigg’s Veterinary Dentistry. Principles and Practice*, 2nd ed. John Wiley & Sons, Ltd, New York, United States.
- LOMMER, M. J. (2013): Oral inflammation in small animals. *Vet. Clin. North Am. Small Anim. Pract.* 43, 555–71.
DOI: 10.1016/j.cvsm.2013.02.004
- PÉREZ-MERINO, E.M., J. M. USÓN-CASAÚS, J. DUQUE-CARRASCO, C. ZARAGOZA-BAYLE, L. MARIÑAS-PARDO, M. HERMIDA-PRIETO, M. VILAFRANCA-COMPTÉ, R. BARRERA-CHACÓN, M. GUALTIERI (2015): Safety and efficacy of allogeneic adipose tissue-derived mesenchymal stem cells for treatment of dogs with inflammatory bowel disease: Endoscopic and histological outcomes. *Vet. J.* 206, 391–397.
DOI: 10.1016/j.tvjl.2015.07.023
- RUSSELL, K. A., N. H. C. CHOW, D. DUKOFF, T. W. G. GIBSON, J. LAMARRE, D. H. BETTS, T. G. KOCH (2016): Characterization and Immunomodulatory Effects of Canine Adipose Tissue- and Bone Marrow-Derived Mesenchymal Stromal Cells.
DOI: 10.1371/journal.pone.0167442
- UZEL, N. G., F. R. TELES, R. P. TELES, X. Q. SONG, G. TORRESYAP, S. S. SOCRANSKY, A. D. HAFFAJEE (2011): Microbial shifts during dental biofilm re-development in the absence of oral hygiene in periodontal health and disease. *J. Clin. Periodontol.* 38, 612–620.
DOI: 10.1111/j.1600-051X.2011.01730.x
- VAPNIARSKY, N., D. L. SIMPSON, B. ARZI, N. TAECHANGAM, N. J. WALKER, C. GARRITY, E. BULKELEY, D. L. BORJESSON (2020): Histological, Immunological, and Genetic Analysis of Feline Chronic Gingivostomatitis. *Front. Vet. Sci.* 7, 1–11.
DOI: 10.3389/fvets.2020.00310
- VILLATORO, A. J., M. HERMIDA-PRIETO, V. FERNÁNDEZ, F. FARIÑAS, C. ALCOHOLADO, M. I. RODRÍGUEZ-GARCÍA, L. MARIÑAS-PARDO, J. BECERRA (2018): Allogeneic adipose-derived mesenchymal stem cell therapy in dogs with refractory atopic dermatitis: clinical efficacy and safety. *Vet. Rec.* 183, 654.
DOI: 10.1136/vr.104867
- VOGA, M., N. ADAMIC, M. VENGUST, G. MAJDIC (2020): Stem Cells in Veterinary Medicine–Current State and Treatment Options. *Front. Vet. Sci.*, 7, 278.
DOI: 10.3389/fvets.2020.00278
- YANESELLI, K., V. CAMPBELL, A. ALGORTA, C. BONFIGLIO, J. MIRAZO, S. FERNANDEZ, M. RÍOS, S. LLAMBÍ, J. MAISONNAVE (2018): Isolation and characterization of canine, equine and feline mesenchymal stem cells in Uruguay. *Vet.* 54, 18–25.
DOI: 10.29155/VET.54.209.3

Received: 11 February 2021

Accepted: 26 June 2021

ALGORTA, A., G. TURINI, J. M. EGUREN, A. M. GRANDE, K. YANESELLI, U. BENAVIDES, J. MAISONNAVE: Lokalno liječenje kroničnog ulcerativnog stomatitisa pasa primjenom mezenhimnih matičnih stanica iz adipoznog tkiva - prikaz slučaja. Vet. arhiv 92, 359-367, 2022.

SAŽETAK

Kronični ulcerativni stomatitis u pasa (CCUS) obilježava kronični bol, povezan s oralnom ulceracijom, upalom i sluzničnom nekrozom. Ovo je prikaz slučaja petogodišnje ženke pasmine akita inu sa sijalorejom, halitozom, oralnim ulceracijama, submandibularnom limfadenopatijom i supstancijalnim oralnim smetnjama. Nakon slabog odgovora na konvencionalno čišćenje kamenca i antibiotsko liječenje, stanje se poboljšalo s primjenom prednizolona u dozi od 1 mg/kg na dan. Odgođena je agresivna imunosupresija i vađenje zubi te je započeta terapija matičnim stanicama. U istraživanju je procijenjen učinak alogenskih odmrznutih i ekspanziranih mezenhimnih matičnih stanica iz adipoznog tkiva (AT-MSCs) u liječenju CCUS-a. Lokalno su primijenjene četiri injekcije AT-MSC-a ($3,5$ do 8×10^6 stanica) svaka 3 – 4 tjedna pod općom anestezijom i neposredno nakon čišćenja zubnog kamenca. Veća doza AT-MSC-a (22×10^6 stanica) primijenjena je pet mjeseci poslije pod jednakim uvjetima. Nakon liječenja AT-MSC-om došlo je do poboljšanja u cijeljenju oralnih lezija i smanjenju boli tijekom namanje četiri tjedna. Zaključujemo da, u ovom slučaju, doza od 1×10^6 AT-MSC-a po kilogramu tjelesne mase ublažava simptome CCUS-a tijekom najmanje jednog mjeseca. Ovo je prema našim spoznajama prvi opis alogenskog liječenja kroničnog ulcerativnog stomatitisa u pasa AT-MSC-om.

Ključne riječi: pas; gingivostomatitis; matične stanice; adipozno tkivo; oralna ulceracija

