

Subclinical dirofilariosis in dogs in Croatia – results of retrospective research based on archived blood samples

Lea Lovrić¹, Vedrana Vavžik², and Tatjana Živičnjak^{1*}

¹Department of Parasitology and Parasitic Diseases with Clinic, Faculty of Veterinary Medicine, University of Zagreb, Zagreb, Croatia

²"SplitVet" - Small Animals Practice, Split, Croatia

LOVRIĆ, L., V. VAVŽIK, T. ŽIVIČNJAK: Subclinical dirofilariosis in dogs in Croatia– results of retrospective research based on archived blood samples. Vet. arhiv 92, 323-330, 2022.

ABSTRACT

Dirofilariosis is an emerging vector-borne disease of dogs and other canids transmitted by female mosquitoes of the Culicidae family, and caused by filarial nematodes of the genus *Dirofilaria*. *Dirofilaria immitis* mainly infects the pulmonary arteries and right heart chambers, and it can cause heartworm disease in dogs, while *D. repens* is found mainly in subcutaneous tissue and causes subclinical infection. Both have zoonotic potential. Human infections caused by *D. repens* are increasing in Europe, and it is emerging as a serious public health threat. Scientific interest has tended to focus mostly on *D. immitis* because of its pathogenicity and veterinary importance. This study aimed to update the information about dirofilariosis in the canine population in Croatia. Therefore, 531 blood samples were tested for the presence of microfilariae using a modified Knott's test and a commercial test for detection of *D. immitis* circulating antigens. Microfilaremia was detected in 8.1% of the tested dogs, of which 7.9% were caused by *D. repens* and 0.4% by *D. immitis*. A single sample (0.2%) showed a mixed infection with both *D. repens* and *D. immitis*. The seroprevalence for *D. immitis* was 0.4%. No occult *D. immitis* infection was detected, and microfilariae were detected in all antigen-positive samples.

Key words: *Dirofilaria*; microfilariae; Knott's-test; dog; Croatia

Introduction

Dirofilariosis is an emerging vector-borne disease transmitted by female mosquitoes of the Culicidae family, caused by the nematodes *Dirofilaria immitis* and *Dirofilaria repens*, respectively (GENCHI et al., 2011a; LATROFA et al. 2012; ALHO et al., 2014). Both parasites primarily affect domestic and wild canids, but felids and humans can also be affected (JOEKEL et al., 2017). *D. immitis* has worldwide distribution,

but *D. repens* is currently found only in Europe, Asia, and Africa (GENCHI and KRAMER, 2020). *D. immitis* can cause severe cardiopulmonary disease in dogs, while *D. repens* usually causes subcutaneous infection without visible clinical signs, although dermatological symptoms (nodules under the skin and/or pruritus) sometimes occur (ALBANESE et al., 2013; ĐORĐEVIĆ et al., 2010; ROCCONI et al., 2012; IONICĂ et al.,

*Corresponding author:

Tatjana Živičnjak, Department of Parasitology and Parasitic Diseases with Clinic, Faculty of Veterinary Medicine Zagreb, 10 000 Zagreb, Croatia, E-mail: tatjanaz@vef.unizg.hr

2017). While a low burden of *D. immitis* adults in dogs is usually subclinical, a high burden results in a chronic cough, progressive weight loss and exercise intolerance. The most severe disease is the result of adult parasite accumulation in the right side of the heart, with congestive right heart failure and acute vena cava syndrome, as the most dramatic consequence of the infection (POLIZOPOULOU et al., 2000; BOWMAN and ATKINS, 2009; CARRETÓN et al., 2017).

There is evidence that *D. repens* is spreading faster than *D. immitis* from the endemic areas of southern Europe to the north. Climate change affecting mosquito vectors, and the facilitation of pet travel seem to have contributed to this expansion, although the major factor could be that many infected dogs remain undetected due to the benign/subclinical nature of the disease (SAŁAMATIN et al., 2013; GENCHI and KRAMER, 2017; CAPELLI et al., 2018).

Both *D. immitis* and *D. repens* are zoonotic and can cause benign to severe conditions in humans, but usually the parasite is not able to develop to the sexually mature adult stage in the accidental host (SIMÓN et al., 2012; JAYASINGHE et al., 2015; FUEHRER et al., 2016), although a few cases of microfilaremia (*D. repens*) have been recorded (GENCHI et al., 2011a; FONTANELLI SULEKOVA et al., 2016; CAPELLI et al., 2018). The zoonotic potential of *D. repens* is much higher than *D. immitis* in Europe, thus giving *D. repens* considerable public health significance (SIMÓN et al., 2012; GENCHI and KRAMER 2017; CAPELLI et al., 2018.)

Regardless of the zoonotic nature and emergence of *D. repens*, scientists and veterinarians are still much more concerned about *D. immitis* (IONICĂ et al., 2017). Indeed, canine *D. repens* infections are usually subclinical, and infections remain undetected. Furthermore, several antigen tests with high sensitivity and specificity are available for serological diagnosis of heartworm infection, but no serological test is available for *D. repens* while blood tests for circulating microfilariae is a diagnostic method many veterinarians are not familiar with (GENCHI and KRAMER, 2017).

In the last 15 years in Croatia a few monitoring studies investigating the prevalence of microfilaremia in dogs were performed. In these studies, 15-30% microfilaremic dogs were detected, with *D. repens* found to be abundant throughout Croatia, while *D. immitis* was found in coastal areas of Croatia, primarily on the Istrian Peninsula and in the city of Dubrovnik (ŽIVIČNJAK et al., 2006; ŽIVIČNJAK et al., 2007; JURICĆ et al., 2007; HOLLER et al., 2010). Two recent studies conducted in Croatia showed a seroprevalence of *D. immitis* circulating antigens in 0.46% and 0.6% dogs, respectively (MRLJAK et al., 2017; JURKOVIĆ et al., 2019).

Since 1996, 30 cases of human dirofilariosis have been reported in Croatia. In terms of anatomical location, 43.3% cases were subcutaneous, 40% were ocular and 16.7% occurred in the reproductive organs. In all 30 cases, *D. repens* was identified as the causative agent (PUZICĆ-IVICĆ et al., 2003; MARUŠIĆ et al., 2008; JANJETOVIĆ et al., 2010; SVIBEN et al., 2013; PUPIĆ-BAKRAČ et al., 2020).

The aim of this survey was to update the available information about dirofilariosis in the canine population in Croatia. This retrospective study was based on stored blood samples that remained after diagnostic processing non-related to dirofilariosis.

Materials and methods

Blood samples. The survey included 531 privately owned dogs of various ages, genders, and breeds. The dogs were brought from the city of Zagreb (Table 1) for routine clinical examination at the Faculty Internal Diseases Clinic during the period from July 2018 to January 2019. Blood samples were collected in EDTA-containing vacutainers for routine hematological assay. The remainder of each sample was stored at +4°C for 2 - 4 days until further testing. Dogs suspected of having heartworm disease were not included in this study, there were no data on macrocyclic lactone application. Only patients' archived data and samples processed for diagnostic purposes were used. The survey was approved by the ethics review committee of the institution (256-61-01/130-17-2).

Knott's test. All samples were examined using a modified Knott's test for detecting and differentiating *D. immitis* and *D. repens* microfilariae (GENCHI et al., 2007). Briefly, 1 ml of blood with EDTA was added to a tube containing 9 ml of distilled water, mixed and centrifuged at 400 G (Eppendorf centrifuge 5804) for 3-5 minutes. The supernatant was discarded and the whole sediment was examined for the presence of microfilariae by light microscopy (Olympus BH-2) at 100x power magnification. Furthermore, in all positive samples the microfilariae were counted and presented as the number of microfilariae per mililiter (mf/ml) (Table 2).

Morphometric analysis. In order to identify the species the length and the width (morphometric analysis) of the microfilariae were measured according to the criteria reported by CRINGOLI et al. (2001) and MAGNIS et al. (2013). This analysis was performed on the extended microfilariae using an ocular micrometer (calibrated for Olympus BH-2).

Detection of *D. immitis* circulating antigen. All blood samples were tested for *D. immitis* circulating antigens with a commercial immunochromatographic FASTest® HW (Megacor Diagnostik, Austria) test, following the manufacturer's instructions (Fig. 1a and 1b).

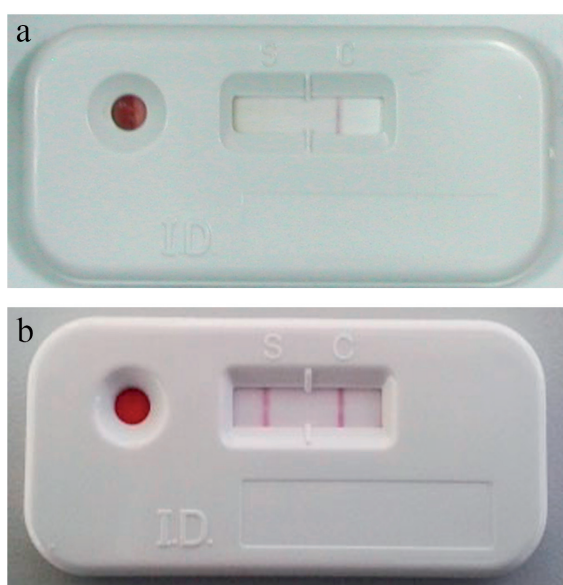


Fig. 1. Negative (a) and positive (b) *D. immitis* circulating antigen test

Statistical analysis. Descriptive statistical analysis was performed (MS Office Professional Plus 2019, Excel 2019).

Results

Microfilariae were found in 43/531 blood samples (8.1%), while 488/531 samples (91.9%) were amicrofilaremic (Fig. 2).

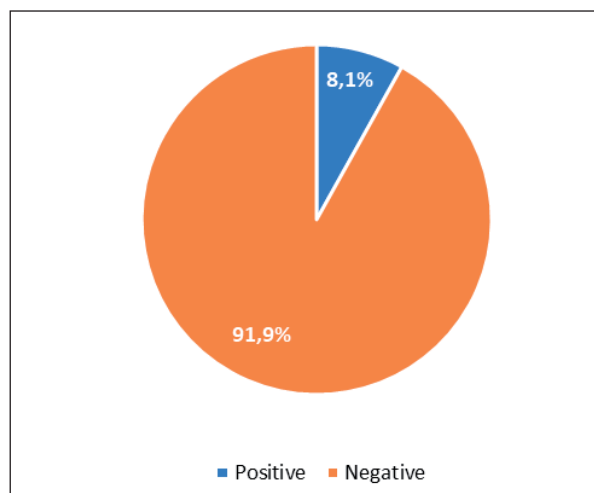


Fig. 2. Percentage of blood samples with microfilariae

D. immitis microfilariae were found in 2/43 positive samples (4.6%), *D. repens* in 42/43 (97.6%), and 1/43 (2.3%) positive sample contained microfilariae of both nematodes (Table 1, Fig. 3 and Fig 4).

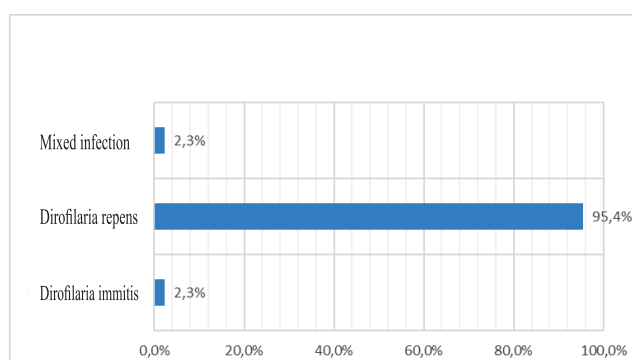


Fig. 3. *D. immitis* and *D. repens* percentage in positive blood samples

Table 1. Dogs' origins and test results

County	Tested samples	HW antigen positive	Knott's test results		
			Negative	Positive	
				<i>D. repens</i>	<i>D. immitis</i>
City of Zagreb	424	1	386	37	1
Zagrebačka County	31	0	29	2	0
Primorsko-Goranska County	9	0	9	0	0
Karlovačka County	7	0	6	1	0
Krapinsko-Zagorska County	6	0	6	0	0
Varaždinska County	6	0	6	0	0
Sisačko-Moslavačka County	5	0	4	1	0
Međimurska County	2	1	1	1*	1*
Bjelovarsko-Bilogorska County	2	0	2	0	0
Osiječko-Baranjska County	2	0	2	0	0
Splitsko-Dalmatinska County	2	0	2	0	0
Dubrovačko-Neretvanska County	1	0	1	0	0
Istarska County	1	0	1	0	0
Koprivničko-Križevačka County	1	0	1	0	0
unknown	32	0	32	0	0
Σ	531	2	488	42	2

* a single blood sample contained microfilariae of both species

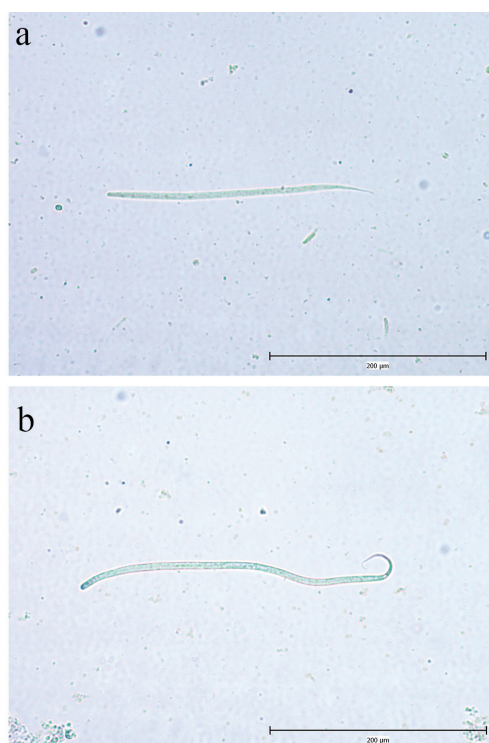


Fig. 4. Microfilaria of *D. immitis* (a) and *D. repens* (b)

The total number of microfilariae per milliliter of blood ranged from 3 to 15,200 (Table 2).

Table 2. *D. repens* and *D. immitis* microfilariae count

No. of microfilariae in 1 ml blood (mf/ml)	<i>D. repens</i>	<i>D. immitis</i>
1-100	16	1
100-1000	11	0
1000-3000	12	0
3000-7000	1	0
7000-15000	1	0
>15000	1*	1*
Σ	42	2

* a single blood sample contained 15,200 mf/ml of both species (microfilariae of each species were not counted separately)

The sample with mixed infection had the highest number of microfilariae per milliliter of blood (15,200 mf/ml). The size of the *D. repens* microfilariae ranged from 354.1 to 378.3 µm in length and 6.09 to 6.71 µm in width, while the

size of the *D. immitis* microfilariae ranged from 301.8 to 320.8 µm in length and 5.81 to 6.11 µm in width. The overall seroprevalence of the *D. immitis* antigen was 0.4% in 2/531 positive blood samples (Table 1).

Discussion

Dirofilaria immitis and *D. repens* are endemic throughout Europe and southern eastern regions of Asia, and are being reported with increasing frequency in Africa (GENCHI and KRAMER, 2020). Climate changes towards higher temperatures that favour the reproduction of mosquitoes and accelerate the development of parasites in the vector, increased mobility of reservoirs (mostly, microfilaraemic dogs), and the introduction of new, competent vectors, such as *Aedes albopictus*, have caused the spread of these parasites from the well-known enzootic, southern regions of Europe to northern and eastern countries, with an increasing number of cases of human infection (CANCRINI et al., 2003; GENCHI et al., 2009; GENCHI et al., 2011b; OTRANTO et al., 2013; SEMENZA and MENNE, 2009; TASIĆ-OTAŠEVIĆ et al., 2015.)

In our survey, the prevalence of microfilaraemic dogs was lower (8.1% vs 15-35%) than previously reported (ŽIVIČNJAK et al., 2006; ŽIVIČNJAK et al., 2007; HOLLER et al., 2010). Administration of macrocyclic lactones in dogs (prescribed and over-the-counter) has been increasing in recent years in Croatia, and some seropositive dogs among the amicrofilaraemic samples were expected. However, in our study, occult heartworm disease was not detected. The list of reasons implies the absence of occult infection, a too low worm burden to be detected, or even low test sensitivity. We consider the specificity of the test to be good because no cross-reaction with *D. repens* was observed and in all seropositive samples *D. immitis* microfilariae were identified by morphometric analysis.

The low seroprevalence (0.4%) of *D. immitis* antigens in our study is in accordance with previous surveys that investigated seroprevalence in Croatia (MRLJAK et al., 2017; JURKOVIĆ et al., 2019). Until 2019 *D. immitis* had only been detected in the littoral area (ŽIVIČNJAK et al., 2006; ŽIVIČNJAK et al., 2007; JURIĆ et al., 2007; HOLLER et al.,

2010). Our study and the study by JURKOVIĆ et al. (2019) are evidence of the expansion of *D. immitis* in continental Croatia.

Severe microfilaraemia has been attributed to immunosuppression induced by some other disease (HARRUS et al., 1999; DŽAJA et al., 2008), and we may speculate that this was the case in the single sample with the highest microfilarial number. The number of microfilariae in the blood is an important factor for vectors becoming infected with *Dirofilaria sp.* which increases the possibility of having an infective meal. However, the high microfilariae load in reservoirs might be lethal for some mosquito species (LAI et al., 2000; MONTARSI et al., 2015; SILAGHI et al., 2017). It was speculated that dogs with low microfilaraemia, as in our study, might be the relevant reservoirs for *Dirofilaria* transmission (LAI et al., 2000).

Conclusion

Considering the geographical and climatic characteristics of Croatia and the current findings of *Dirofilaria* parasites in dogs and humans, priority should be given to the implementation of measures such as prophylaxis and treatment of infected dogs. These include routine monitoring, (Knott's test and test for the detection of *D. immitis* circulating antigens, which are mutually complementary), the introduction of chemoprophylaxis and therapy programs in dogs with macrocyclic lactones, and vector control (application of repellents on dogs, insecticides and growth regulators in the environment). Educating physicians, veterinarians and dog owners should also contribute to the efficient prevention of dirofilariosis.

References

- ALBANESE, F., F. ABRAMO, C. BRAGLIA, C. CAPORALI, L. VENCO, A. VERCELLI, G. GHIBAUDO, F. LEONE, F. CARRANI, A. GIANNELLI, D. OTRANTO (2013): Nodular lesions due to infestation by *Dirofilaria repens* in dogs from Italy. *Vet. Dermatol.* 24, 255-256.
DOI: 10.1111/vde.12009
- ALHO, A. M., M. LANDUM, C. FERREIRA, J. MEIRELES, L. GONCALVES, L. MADEIRA DE CARVALHO, S.

- BELO (2014): Prevalence and seasonal variations of canine dirofilariosis in Portugal. *Vet. Parasitol.* 206, 99-105.
DOI: 10.1016/j.vetpar.2014.08.014
- BOWMAN, D. D., C. E. ATKINS (2009): Heartworm Biology, Treatment, and Control. *Vet. Clin. N. Am-Small.* 39, 1127-1158.
DOI: 10.1016/j.cvsm.2009.06.003
- CANCINI, G., A. FRANGIPANE DI REGALBONO, I. RICCI, C. TESSARIN, S. GABRIELLI, M. PIETROBELLI (2003): *Aedes albopictus* is a natural vector of *Dirofilaria immitis* in Italy. *Vet. Parasitol.* 118, 195-202.
DOI: 10.1016/j.vetpar.2003.10.011
- CAPELLI, G., C. GENCHI, G. BANETH, P. BOURDEAU, E. BRIANTI, L. CARDOSO, P. DANESI, H. P. FUEHRER, A. GIANNELLI, A. M. IONICĂ, C. MAIA, D. MODRÝ, F. MONTARSI, J. KRUCKEN, E. PAPADOPOULOS, D. PETRIĆ, M. PFEFFER, S. SAVIĆ, D. OTRANTO, S. POPPERT, C. SILAGHI (2018): Recent advances on *Dirofilaria repens* in dogs and humans in Europe. *Parasite Vector.* 11, 663.
DOI: 10.1186/s13071-018-3205-x
- CARRETÓN, E., R. MORCHÓN, J. A. MONTOYA-ALONSO (2017): Cardiopulmonary and inflammatory biomarkers in heartworm disease. *Parasite Vector.* 10, 534.
DOI: 10.1186/s13071-017-2448-2
- CRINGOLI G., L. RINALDI A V. VENEZIANO A, G. CAPELLI (2001): A prevalence survey and risk analysis of filariosis in dogs from the Mt. Vesuvius area of southern Italy. *Vet. Parasitol.* 102, 243–252.
- DŽAJA, P., A. BECK, G. KIŠ, A. GUDAN KURILJ, T. ŽIVIČNJAK, B. ARTUKOVIĆ, R. BECK, M. HOHŠTETER, I. C. ZUCKERMANN ŠOŠTARIĆ, Ž. ŽELJKO (2008): *Dirofilaria repens* infection in a dog in Croatia – a case report. *Vet. Arhiv.* 78, 521-527.
- ĐORĐEVIĆ, J., S. TASIĆ, N. MILADINOVIĆ-TASIĆ, A. TASIĆ (2010): Diagnosis and Clinical Importance of Human *Dirofilariosis*. *Scientific Journal of the Faculty of Medicine in Niš*, 81-84.
- FONTANELLI SULEKOVA, L., S. GABRIELLI, M. DE ANGELIS, G. MILARDI, C. MAGNANI, B. DI MARCO, G. TALIANI, G. CANCRINI (2016.): *Dirofilaria repens* microfilariae from a human node fine needle aspirate: a case report. *BMC Infect. Dis.* 16: 248.
DOI: 10.1186/s12879-016-1582-3
- FUEHRER, H. P., H. AUER, M. LESCHNIK, K. SILBERMAYR, G. DUSCHER, A. JOACHIM (2016): *Dirofilaria* in humans, dogs, and vectors in Austria (1978-2014) – from imported pathogens to the endemicity of *Dirofilaria repens*. *PLOS Neglect. Trop. D.* 10:5, 1-13.
DOI: 10.1371/journal.pntd.0004547
- GENCHI, C., L. RINALDI, G. CRINGOLI (2007): *Dirofilaria immitis* and *D. repens* in dog and cat and human infections. Free Communications presented at the First European *Dirofilaria* Days, Zagreb, Croatia. First edition. February 22-25, pp 41-125.
- GENCHI, C., L. RINALDI, M. MORTARINO, M. GENCHI, G. CRINGOLI (2009): Climate and *Dirofilaria* infection in Europe. *Vet. Parasitol.* 163, 286-292.
DOI: 10.1016/j.vetpar.2009.03.026
- GENCHI, C., L. H. KRAMER, F. RIVASI (2011a): *Dirofilarial* Infections in Europe. *Vector-Borne Zoonot.* 11:1307-1317.
DOI: 10.1089/vbz.2010.0247
- GENCHI, C., M. MORTARINO, L. RINALDI, G. CRINGOLI, G. TRALDI, M. GENCHI (2011b): Changing climate and changing vector-borne disease distribution: The example of *Dirofilaria* in Europe. *Vet. Parasitol.* 176, 295-299.
DOI: 10.1016/j.vetpar.2011.01.012
- GENCHI, C., L. KRAMER (2017): Subcutaneous dirofilariosis (*Dirofilaria repens*): an infection spreading throughout the old world. *Parasite Vector.* 10, 517.
DOI: 10.1186/s13071-017-2434-8
- GENCHI, C., L. H. KRAMER (2020): The prevalence of *Dirofilaria immitis* and *Dirofilaria repens* in the Old World. *Vet. Parasitol.* 280:108995
DOI: 10.1016/j.vetpar.2019.108995.
- HARRUS, S., A. HARMELIN, S. RODRIG, G. FAVIA (1999): *Dirofilaria repens* infection in a dog in Israel. *Am. J. Trop. Med. Hyg.* 61, 639-641.
- HOLLER, D., A. RACZ, J. BOŠNIR, O. PETRAK (2010): The prevalence of dirofilariosis in the hinterland of the Istrian peninsula. *Med. Jad.* 40, 67–74.
- IONICĂ, A. M., I. A. MATEI, G. D'AMICO, L. V. BEL, M. O. DUMITRACHE, D. MODRÝ, A. D. MIHALCA (2017): *Dirofilaria immitis* and *D. repens* show circadian co-periodicity in naturally co-infected dogs. *Parasite Vector.* 10, 116.
DOI: 10.1186/s13071-017-2055-2
- JANJETOVIĆ, Ž., Ž. V. ARAR, T. M. PARADŽIK, L. ŠAPINA, M. BITUNJAC, G. LOJEN, A. MARINCULIĆ (2010): Ocular dirofilariosis: A case report. *Acta Med. Croatica.* 64, 41-45.
- JAYASINGHE, R. D., S. R. GUNAWARDANE, M. A. M. SITHEEQUE, S. WICKRAMASINGHAIE (2015): A Case Report on Oral Subcutaneous *Dirofilariosis*. *Case Reports in Infectious Diseases*, 1-4.
DOI: 10.1155/2015/648278
- JOEKEL, D. E., S. MAIER, K. HUGGEL, R. SCHAPER, P. DEPLAZES (2017): Specific Antibody Detection in Dogs with Filarial Infections. *Parasitol. Res.* 116, S81-S90.
DOI: 10.1007/s00436-017-5494-y
- JURIĆ, B., R. BECK, F. MARTINKOVIĆ, A. MILOSAVLJEVIĆ, S. PAHOVIĆ, A. MATIĆ (2007): The prevalence of *Dirofilaria* infections among dogs in Istria. *Proceedings of the First European Dirofilaria Days Zagreb, Croatia*, pp 33-34.

- JURKOVIĆ, D., A. BECK, D. HUBER, Ž. MIHALJEVIĆ, A. POLKINGHORNE, F. MARTINKOVIĆ, D. LUKAČEVIĆ, M. PILAT, R. BREZAK, S. BOSNIĆ, R. BECK (2019): Seroprevalence of vector-borne pathogens in dogs from Croatia. *Parasitol. Res.* 118, 347-352.
DOI: 10.1007/s00436-018-6129-7
- LATROFA, M. S., F. MONTARSI, S. XIOXXHETTA, G. ANNOSCIA, F. DANTAS-TORRE, S. RAVAGNAN, G. CAPELLI, D. OTRANTO (2012): Molecular xenomonitoring of *Dirofilaria immitis* and *Dirofilaria repens* in mosquitoes from north-eastern Italy by real-time PCR coupled with melting curve analysis. *Parasite Vector.* 5, 76.
DOI: 10.1186/1756-3305-5-76
- LAI, C.H., K. C. TUNG, H. K. OOI, J. S. WANG (2000): Competence of *Aedes albopictus* and *Culex quinquefasciatus* as vector of *Dirofilaria immitis* after blood meal with different microfilarial density. *Vet. Parasitol.* 90, 231-237.
DOI: 10.1016/s0304-4017(00)00242-9
- MAGNIS, J., S. LORENTZ, L. GUARDONE, F. GRIMM, M. MAGI, T. J. NAUCKE, P. DEPLAZES (2013): Morphometric analyses of canine blood microfilariae isolated by the Knott's test enables *Dirofilaria immitis* and *D. repens* species-specific and *Acanthocheilonema* (syn. *Dipetalonema*) genus-specific diagnosis. *Parasite Vector.* 6, 48.
DOI: 10.1186/1756-3305-6-48
- MARUŠIĆ, Z., T. STASTNY, I. KIRAC, D. STOJČEVIĆ, B. KRUSLIN, D. TOMAS (2008): Subcutaneous dirofilariosis caused by *Dirofilaria repens* diagnosed by histopathologic and poly-merase chain reaction analysis. *Acta Dermatovener. Cr.* 16, 222-225.
- MONTARSI, F., S. CIOCCHETTA, G. DEVINE, S. RAVAGNAN, F. MUTINELLI, A. F. DI REGALBONO, D. OTRANTO, G. CAPELLI (2015): Development of *Dirofilaria immitis* within the mosquito *Aedes* (*Finlaya*) *koreicus*, a new invasive species for Europe. *Parasite Vector.* 8, 177.
DOI: 10.1186/s13071-015-0800-y
- MRLJAK, V., J. KULEŠ, Ž. MIHALJEVIĆ, M. TORTI, J. GOTIĆ, M. CRNOGAJ, T. ŽIVIČNJAK, I. MAYER, I. ŠMIT, M. BHIĐE, R. BARIĆ RAFAJ (2017): Prevalence and geographic distribution of vector-borne pathogens in apparently healthy dogs in Croatia. *Vector Borne Zoonot.* 17, 398-408.
DOI: 10.1089/vbz.2016.1990
- OTRANTO, D., F. DANTAS-TORRES, E. BRIANTI, D. TRAVERSA, D. PETRIĆ, C. GENCHI, G. CAPELLI (2013): Vector-borne helminths of dogs and humans in Europe. *Parasite Vector.* 6, 16.
DOI: 10.1186/1756-3305-6-16
- POLIZOPOULOU, Z. S., A. F. KOUTINAS, M. N. SARIDOMICHELAKIS, M. N. PATSIKAS, L. S. LEONTIDIS, N. A. ROUBIES, A. K. DESIRIS (2000): Clinical and laboratory observations in 91 dogs infected with *Dirofilaria immitis* in northern Greece. *Vet. Rec.* 146, 466-469.
DOI: 10.1136/vr.146.16.466
- PUPIĆ-BAKRAČ, A., J. PUPIĆ-BAKRAČ, D. JURKOVIĆ, M. CAPAR, L. LAZARIĆ STEFANOVIĆ, I. ANTUNOVIĆ ČELOVIĆ, J. KUČINAR, A. POLKINGHORNE, R. BECK (2020): The trends of human dirofilariosis in Croatia: Yesterday – Today – Tomorrow. *One Health.* 10, 100153.
DOI: 10.1016/j.onehlt.2020.100153
- PUZIĆ-IVIĆ, N., N. DŽAKULA, J. BEZIĆ, V. PUNDA-POLIĆ, S. SARDELIĆ, I. KUZMIĆ-PRUSAC (2003): First two cases of human dirofilariosis recorded in Croatia. *Parasite.* 10, 4, 382-384.
- ROCCONI, F., M. DI TOMMASO, D. TRAVERSA, C. PALMIERI, F. PAMPURINI, A. BOARI (2012): Allergic dermatitis by *Dirofilaria repens* in dog: clinical picture and treatment. *Parasitol. Res.* 111, 493-496.
DOI: 10.1007/s00436-012-2833-x
- SAŁAMATIN, R. V., T. M. PAVLIKOVSKA, O. S. SAGACH, S. M. NIKOLAYENKO, V. V. KORNUSHIN, V. O. KHARCHENKO, A. MASNY, D. CIELECKA, J. KONIECZNA-SAŁAMATIN, D. B. CONN, E. GOLAB (2013): Human dirofilariosis due to *Dirofilaria repens* in Ukraine, an emergent zoonosis: epidemiological report of 1465 cases. *Acta Parasitol.* 58, 592-598.
DOI: 10.2478/s11686-013-0187-x
- SEMENZA, J. C., B. MENNE (2009): Climate change and infectious diseases in Europe. *Lancet. Infect. Dis.* 9, 365-375.
DOI: 10.1016/S1473-3099(09)70104-5
- SILAGHI, C., R. BECK, G. CAPELLI, F. MONTARSI, A. MATHIS (2017): Development of *Dirofilaria immitis* and *Dirofilaria repens* in *Aedes japonicus* and *Aedes geniculatus*. *Parasite Vector.* 10, 94.
DOI: 10.1186/s13071-017-2015-x
- SIMÓN, F., M. SILES-LUCAS, R. MORCHÓN, J. GONZALEZ-MIGUEL, I. MELLADO, E. CARRETÓN, J. A. MONTOYA-ALONSO (2012): Human and Animal Dirofilariosis: the Emergence of a Zoonotic Mosaic. *Clin. Microbiol. Rev.* 25, 3, 507-544.
DOI: 10.1128/CMR.00012-12
- SVIBEN, M., T. MEŠTROVIĆ, K. NEMER, K. PALKO-BARTULOVIĆ, R. ŠKARA, G. MLINARIĆ GALINOVIĆ (2013): *Dirofilaria repens* as a cause of subconjunctival infection in a 77-years old female patient from Croatia – a case report. *Coll. Antropol.* 37, 3, 995-997.

- TASIĆ-OTAŠEVIĆ, S., M. S. TRENKIĆ BOŽINOVIĆ, S. V. GABRIELLI, C. GENCHI (2015): Canine and human *Dirofilaria* infections in the Balkan Peninsula. *Vet. Parasitol.* 209, 151-156.
DOI: 10.1016/j.vetpar.2015.02.016
- ŽIVIČNJAK, T., F. MARTINKOVIĆ, R. BECK (2006): *Dirofilariosis in Croatia: Spread and Public Health Impact.* 5th Croatian Congress on Infectious Diseases, 23-27 September, Zadar, Croatia.
- ŽIVIČNJAK, T., F. MARTINKOVIĆ, R. BECK (2007): *Canine dirofilariosis in Croatia: Let's face it.* Proceedings of the First European *Dirofilaria* Days (FEDD), 22-25 February, Zagreb, Croatia, p 35.

Received: 25 January 2021

Accepted: 30 April 2021

LOVRIĆ, L., V. VAVŽIK, T. ŽIVIČNJAK: Subklinička dirofilarioza u pasa u Hrvatskoj – rezultati retrogradne pretrage arhivskih uzoraka krvi. *Vet. arhiv* 92, 323-330, 2022.

SAŽETAK

Dirofilarioza je vektorski prenosiva bolest pasa i drugih kanida, koju prenose ženke komaraca iz porodice Culicidae, a uzrokuju je oblići iz roda *Dirofilaria*. *D. immitis* parazitira u plućnim arterijama i desnoj strani srca te može prouzročiti kardiopulmonalnu bolest kod pasa, dok *D. repens* parazitira uglavnom u potkožju i invazija je supkličičkog tijeka. Zoonotskog su potencijala. U Europi raste broj ljudi invadiranih s *D. repens*, što je ozbiljn javno-zdravstveni problem. Znanstveni interes je uglavnom usmjeren na *D. immitis* zbog patogenosti i značaja u veterinarskoj medicini. Cilj je ovog istraživanja ažuriranje informacija o učestalosti dirofilarioze u populaciji pasa u Hrvatskoj. U tu svrhu, primjenom modificiranog testa po Knott-u i komercijalnog brzog testa za detekciju cirkulirajućeg antigena *D. immitis* testiran je 531 uzorak krvi pasa. Otkriveno je 8,1 % pasa s mikrofilarijama od čega se 7,9 % odnosilo na *D. repens*, a 0,4 % na *D. immitis*. Jedan je uzorak (0,2 %) bio pozitivan na *D. repens* i *D. immitis*. Seroprevalencija za *D. immitis* bila je 0,4 %. Okultna dirofilarioza nije otkrivena, a u svim uzorcima koji su bili pozitivni na cirkulacijski antigen parazita *D. immitis* pronađene su i mikrofilarije.

Ključne riječi: *Dirofilaria*; mikrofilarije; Knottov test; pas; Hrvatska
