

## Electroencephalographic manifestations during propofol and xylazine-ketamine anaesthesia in goats

Mrigakshi Yadav<sup>1\*</sup>, Sunil K. Rastogi<sup>1</sup>, Arup K. Das<sup>2</sup>, Malini Pant<sup>1</sup>, Arun K. Madan<sup>3</sup>, and Ruokuobeinuo Huozha<sup>1</sup>

<sup>1</sup>Department of Veterinary Physiology and Biochemistry, College of Veterinary and Animal Sciences, GBPUAT, Pantnagar, Uttarakhand, India

<sup>2</sup>Department of Veterinary Surgery and Radiology, College of Veterinary and Animal Sciences, GBPUAT, Pantnagar, Uttarakhand, India

<sup>3</sup>Department of Veterinary Physiology, College of Veterinary Sciences and Animal Husbandry, U.P. Pandit Deen Dayal Upadhyaya Pashu Chikitsa Vigyan Vishwavidyalaya Evam Go Anusandhan Sansthan (DUVASU), Mathura, Uttar Pradesh, India

---

**YADAV, M., S. K. RASTOGI, A. K. DAS, M. PANT, A. K. MADAN, R. HUOZHA: Electroencephalographic manifestations during propofol and xylazine-ketamine anaesthesia in goats. Vet. arhiv 92, 45-52, 2022.**

### ABSTRACT

The use of intravenous anaesthesia for short term surgical procedures in animal husbandry practices is increasing. However, information on the quality of an anaesthetic regime in goats has remained inadequate. Therefore, electroencephalographic studies were conducted on twelve apparently healthy adult female Barbari crossbred goats, aged 2 to 4 years, to assess the anaesthetic quality of a propofol and xylazine-ketamine combination. Quantitative analysis of EEG parameters [Total power, Median Frequency, Spectral Edge Frequency 90 (SEF-90) and Relative Power (RP) of different frequency bands delta ( $\delta$ ), theta ( $\theta$ ), alpha ( $\alpha$ ) and beta ( $\beta$ )] were assessed pre-experimentally (control), and at one, five, 10, 30 min, one hr, and two hr after intravenous propofol (4 mg/kg) and xylazine (0.05 mg/kg)-ketamine (4 mg/kg) administration. After propofol and xylazine-ketamine administration total power, RP- $\delta$  and  $\theta$  increased significantly ( $P < 0.05$ ) while SEF 90, MF, RP- $\alpha$  and RP- $\beta$  decreased. Most of the EEG changes were adequately depicted in vertex and parietal channels. Spectral analysis of EEG tracings suggested that propofol produced minimum anaesthetic stress and is a safer and better choice for short term anaesthesia in goats.

**Key words:** anaesthesia; electroencephalography; goat; propofol; xylazine-ketamine

---

### Introduction

Information on the appropriate anaesthetic for short term surgical interventions in goats is lacking. Moreover, EEG changes associated with veterinary anaesthesia are largely unexplored. Monitoring anaesthetic depth and intraoperative pain perception through brain functions is becoming

of increasing concern to anaesthesiologists in recent times. It makes it possible to recognize the extent of stress to the body system, and to make adjustments in the anaesthetic protocol to prevent untoward effects on the patient (FISH et al., 2011). Electroencephalography (EEG) is a non-invasive

---

\*Corresponding author:

Mrigakshi Yadav, MVSc, PhD Scholar, Department of Veterinary Physiology and Biochemistry, College of Veterinary and Animal Sciences, G. B. Pant University of Agriculture and Technology, Pantnagar, Uttarakhand, India, E-mail: dr.mrigakshiyadav@gmail.com

method where the recorded waveforms reflect the cortical electrical activity generated by the brain cells in the time course of extracellular field potentials in a synchronous action. EEG has been found to be an effective tool for evaluation of brain function in animals (SILVA and ANTUNES, 2012), quantifying painful distress (HUOZHA et al., 2011) and detecting stress induced under different physiological (ANAND et al., 2013; HUOZHA et al., 2015) and clinical conditions (HUOZHA et al., 2018) in goats. It also helps to monitor the adequacy of anaesthesia (SEITSONEN et al., 2005). Quantitative EEG analysis is the numerical analysis of EEG data, and is the standard for evaluating brain activity (BERGAMASCO et al., 2006; OTTO, 2008).

With the evolution of new anaesthetic agents, the use of intravenous anaesthetics has increased as they provide complete surgical anaesthesia within short periods of time and are very effective, safe and allow rapid recovery from anaesthesia. Propofol (2, 6-diisopropylphenol) is a short-acting, intravenously administered hypnotic agent with smooth and rapid induction, causing minimal residual effects on the central nervous system (STOELTING and MILLER, 2000; PRASSINOS et al., 2005) and producing safe and effective anaesthesia (BUFALARI et al., 1996). Xylazine (2-(2, 6-xylidino)-5, 6-dihydro-4H-1, 3-thiazine hydrochloride) is a  $\alpha_2$  adrenergic agonist inducing deep sedation, muscle relaxation, and analgesia, and is commonly used for sedation in ruminants (KHAN, 2007). Ketamine ((*RS*)-2-(2-Chlorophenyl)-2-(methylamino) cyclohexanone) is a "dissociative" anaesthetic with hypnotic, analgesic and amnesic effects, and has a shorter duration of action with a smaller psychomimetic profile. Xylazine-ketamine is considered to be a very reliable anaesthetic combination, where xylazine is used as premedication and ketamine for the induction and maintenance of anaesthesia.

Hence, the present study was planned to analyze the regional activity of the brain in goats during anaesthesia, evaluating the different EEG changes, and to ascertain the suitability of propofol and xylazine-ketamine anaesthesia in goats during short term surgical interventions.

## Materials and methods

**Animals.** The initial proposal of the experiment was duly scrutinized by the Institutional Animal Ethical Committee, GBPUAT, Pantnagar, Uttarakhand, India (Vide approval no.: IAEC/VPB/CVASc/116). Twelve healthy (Local X Barbari) female goats weighing  $23.66 \pm 2.22$  kg, aged 2 to 4 years were kept under optimum managerial and environmental conditions throughout the experimental period, under the provisions of ethical treatment of experimental animals. Prior to the start of the experiment, all the goats were acclimatized to the experimental conditions as described (HUOZHA et al., 2009, MADAN et al. 2017) until a uniform resting EEG was obtained. The relevant areas of electrode placement on the scalp were shaved aseptically one day before the experiment.

**Anaesthetic protocol.** The goats were allocated by simple randomization into two groups (P i.e. propofol and XK i.e. xylazine-ketamine) comprised of six animals in each group. Food was withheld for 12 hours and water for 6 to 8 hours from all the goats before anaesthesia. All the animals under the study were premedicated with glycopyrrolate (Pyrolate, Neon Laboratories Ltd., Mumbai, India) at the dose rate of 0.02 mg/kg, injected intramuscularly (IM). After 5 minutes, the P propofol group (Profol, Claris Life Sciences Ltd., Ahmedabad, India) anaesthesia was induced intravenously at the dose rate of 4 mg/kg. Likewise in the XK group, anaesthesia was induced by intravenous administration of xylazine (Xylazin, Indian Immunologicals Ltd., Hyderabad, India) at the dose rate of 0.05 mg/kg IV, followed after five minutes by ketamine (Aneket, Neon Laboratories Ltd., Mumbai, India) at the dose rate of 4 mg/kg IV.

**Electroencephalographic recordings.** A seven-channel monopolar montage: F3-Ref., F4-Ref., Cz-Ref., P3-Ref., P4-Ref., O1-Ref., and O2-Ref. (even number: right hemisphere, odd number: left hemisphere; F: Frontal; Cz: Vertex; P: Parietal; O: Occipital; R: Reference electrode) was used in the goats in sternal recumbency as described (MADAN et al., 2017) to record brain bioelectric activity. The leads were connected to the head box of the EEG recording instrument - RMS Brain View Plus (Recorder & Medicare Systems, Ambala

Cantt., India). The sensitivity of the instrument was maintained at  $7.5\mu\text{V}/\text{mm}$ ; speed:  $30\text{mm}/\text{sec}$ ; time constant:  $0.02\text{ sec}$ ;  $H_f = 70\text{ Hz}$ ;  $L_f = 1\text{ Hz}$ ; notch filter inserted; impedance  $<10\text{ k}\Omega$ ; acquisition band pass:  $0.1\text{ to }30\text{ Hz}$ , using the 10 to 20 system conventions (International Federation of Societies for Electroencephalography and Clinical Neurophysiology). A standardized silver disc electrode ( $1\text{ cm}$  diameter) filled with bentonite EEG paste was used to maintain conductivity. Before placement of the electrodes, the sites were rubbed with ethanol to remove skin oil. Five minutes after the electrodes were placed and after achieving a stable plane of anaesthesia, EEG recording was started. The data generated were stored in an acquisition station (RMS SSEEg 2.1 acquisition, RMS Brain View Plus). During the EEG recording, the serial behavioural activities of each animal were noted. EEG readings were recorded pre-experimentally (control) at one, five, 10, 30 min, one hr, two hr after the induction of propofol or xylazine-ketamine. Special emphasis was placed on eliminating obvious artifacts due to ocular movements, muscular activity such as ear shaking, limb movement etc., and inadvertent movement of the handler and animals. Three recordings of artifact-free, acceptable qualitative EEG of 3 s each were utilized for spectral analysis.

*Quantitative/spectral analysis (q-EEG)*. Spectral analysis of each recording was performed with the help of a server (RMS Super Spec) using integrated software (Fast Fourier transformation). Fast Fourier transformation was performed for the complete frequency spectrum ( $0.1\text{ to }30\text{ Hz}$ ) to generate total power ( $\mu\text{V}^2$ ), Median Frequency (Hz), Spectral Edge Frequency 90 (Hz) (Fig. 1) while relative power (%) was generated over different frequency bands including delta ( $\delta$ ,  $0.1\text{ to }4.0\text{ Hz}$ ), theta ( $\theta$ ,  $4.1\text{ to }8\text{ Hz}$ ), alpha ( $\alpha$ ,  $8.1\text{ to }12.0\text{ Hz}$ ), and beta ( $\beta$ ,  $12.1\text{ to }30\text{ Hz}$ ) to discover the relative strength of each bandwidth within the spectrum (MURRELL and JOHNSON, 2006). These parameters of bioelectric activity were generated for each electrode at each time point. Data from each electrode were analysed separately. The mean of the three recordings for each time interval and for both the experiments was calculated to generate a single value for a particular animal from a particular electrode. The Kolmogorov–Smirnov test was employed for analysis of data for normal distribution. Thereafter, the data obtained for each parameter from both the groups of goats were analysed by two-way ANOVA, carried out with the help of STPR 3 and STPR 43 (Standard programme 3 and 43) which was developed to generate statistically significant differences between each electrode amongst the

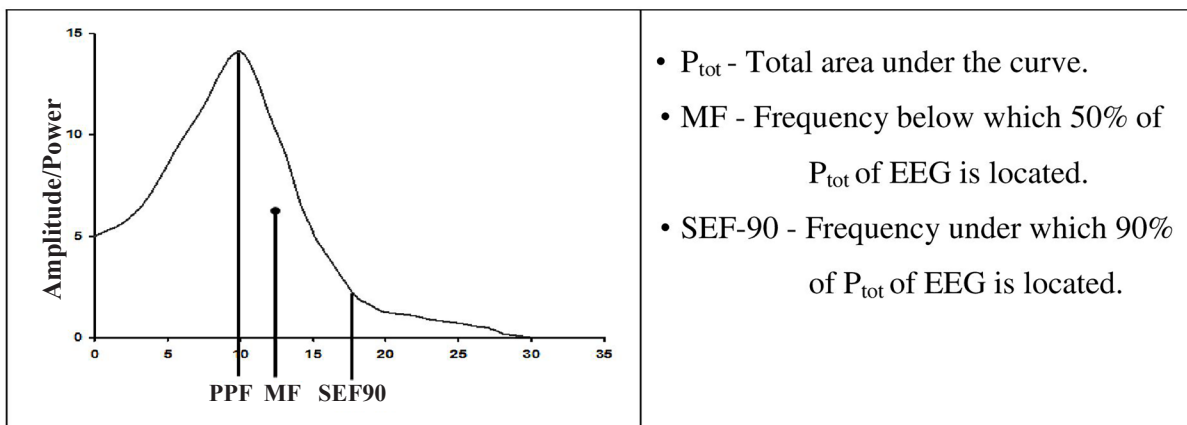


Fig. 1. Schematic representation of EEG Power Spectrum

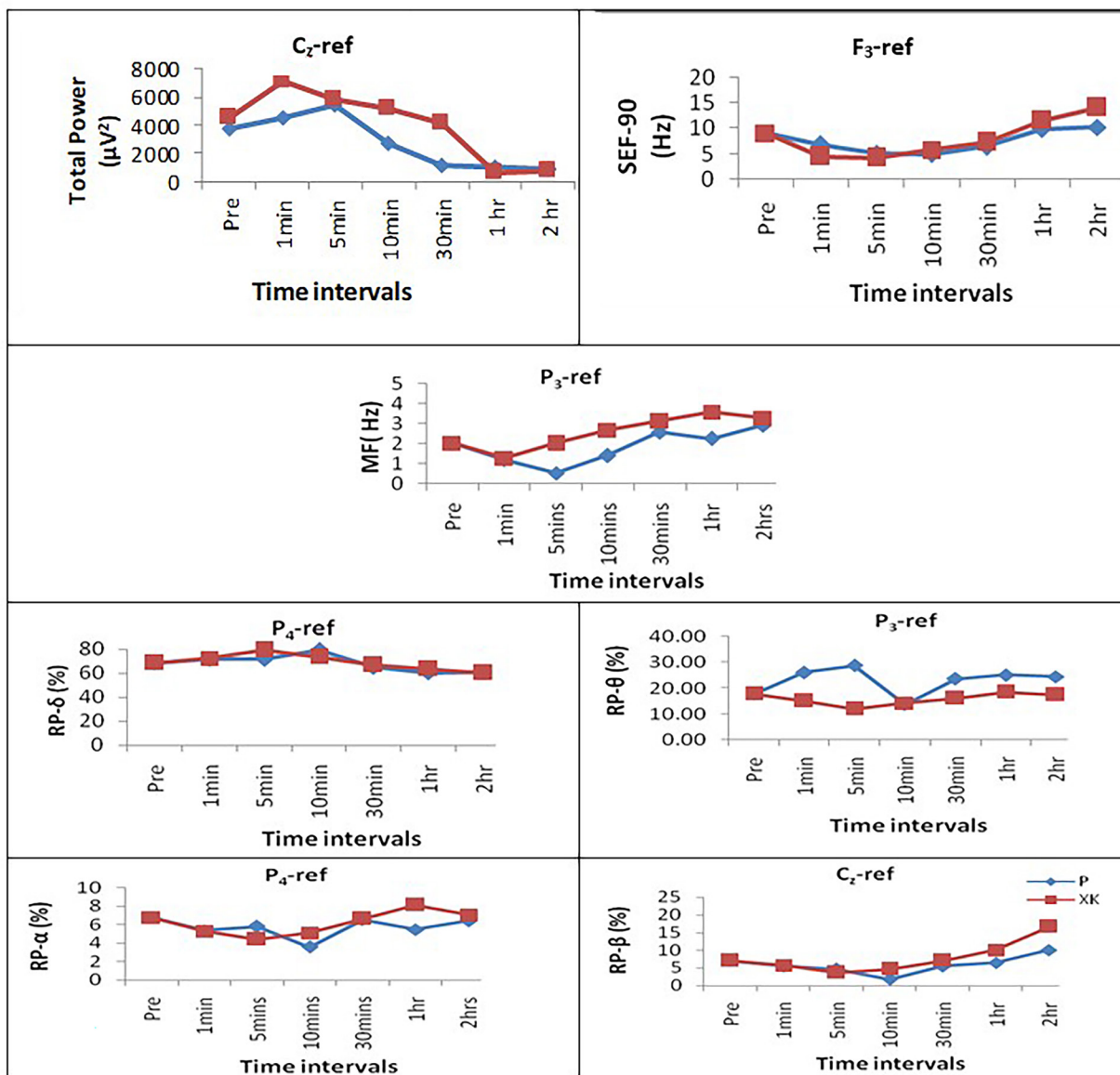


Fig. 2. Line diagrams depicting q-EEG parameters of best channel under different anaesthetic conditions in goats

anaesthetic groups at each time interval, and between different time intervals in each group. The data are presented as mean ± standard error of mean difference, and statistical significance was fixed at  $P < 0.05$ .

### Results

During the study, while inducing propofol anaesthesia in group P and xylazine-ketamine in group XK in goats, pain perception evaluation was done by EEG tracings which are summarized in Fig.

2. Throughout, anaesthesia induction was smooth, except that apnoea developed in two goats after propofol administration, but the goats recovered spontaneously.

Amongst the q-EEG parameters, Total Power ( $P_{tot}$ ) specifying the total area under the EEG wave, increased significantly ( $P < 0.05$ ) in both groups with the adequacy of anaesthesia within one minute of induction, being best exhibited in the vertex ( $C_z$ ) channel of EEG. Total power in  $C_z$  channel



increased from  $3726.04 \pm 743.54 \mu V^2$  (control) to  $4538.88 \pm 379.37 \mu V^2$  (at 1 min) then  $5444.64 \pm 350.25 \mu V^2$  (at 5 min) after propofol, and  $7163.67 \pm 1025.05 \mu V^2$  (at 1 min) then  $5831.60 \pm 834.64 \mu V^2$  (at 5 min) after xylazine-ketamine administration. Group XK revealed significantly ( $P < 0.05$ ) greater values achieved earlier.

Spectral Edge Frequency 90 (SEF-90) in both groups decreased significantly ( $P < 0.05$ ) with anaesthetic adequacy within one minute of induction. The results were best exhibited in the left frontal channel. SEF-90 in the  $F_3$  channel decreased from  $9.02 \pm 0.72$  Hz (control) to  $5.02 \pm 0.72$  Hz after propofol and  $4.27 \pm 1.20$  Hz after xylazine-ketamine administration, at 5 min.

Similarly, Median Frequency (MF) in both groups decreased significantly ( $P < 0.05$ ) with the effectiveness of anaesthesia, with the best results in the left parietal region of the brain. MF in the  $P_3$  channel decreased from  $2.03 \pm 0.18$  Hz (control) to  $1.20 \pm 0.18$  Hz (at 1 min) then  $0.53 \pm 0.21$  Hz (at 5 min) after propofol, and  $1.28 \pm 0.26$  Hz (at 1 min) then  $2.01 \pm 0.17$  Hz (at 5 min) after xylazine-ketamine administration. In group XK, after decreasing maximally at 1 min, MF increased to pre-experimental values at 5 min, earlier than in group P.

Relative power (RP), depicted in Fig. 2, showed that RP- $\delta$  in both groups significantly ( $P < 0.05$ ) increased from the control value of  $68.76 \pm 1.74\%$  to  $71.47 \pm 1.75\%$  at 5 min, then gradually reached its maximum value ( $79.50 \pm 3.41\%$ ) after 10 min in group P, while attaining maximum RP ( $79.49 \pm 1.66\%$ ) at 5 min and decreasing to  $72.29 \pm 1.66\%$  at 10 min after anaesthesia induction in group XK. The best results were exhibited in right parietal region. The RP- $\theta$  values were significantly ( $P < 0.05$ ) higher in group P goats up to 5 minutes of induction, as compared to goats of group XK. The pre-anaesthesia values in the  $P_3$  channel increased from  $17.84 \pm 2.28\%$  to  $26.14 \pm 2.28\%$  (at 1 min) and  $28.77 \pm 2.28\%$  (at 5 min) after propofol, and  $15.00 \pm 3.47\%$  (at 1 min) and  $11.99 \pm 2.47\%$  (at 5 min) after xylazine-ketamine induction. The results revealed significantly ( $P < 0.05$ ) higher RP- $\theta$  values in group P, which was exhibited best in the left parietal region of the brain. RP- $\alpha$  and RP- $\beta$  significantly ( $P < 0.05$ )

decreased with anaesthetic efficacy in both groups, with the best results in the right parietal (RP- $\alpha$ ) and vertex channels (RP- $\beta$ ). RP- $\alpha$  in  $P_4$  channel decreased from  $9.37 \pm 1.36\%$  (control) to  $5.94 \pm 1.10\%$  (at 5 min) and  $2.74 \pm 0.75\%$  (at 10 min) after propofol, and  $4.85 \pm 0.85\%$  (at 5 min) and  $5.51 \pm 0.88\%$  (at 10 min) after xylazine-ketamine administration. RP- $\beta$  in the  $C_z$  channel decreased from  $7.05 \pm 1.59\%$  (control) to  $4.62 \pm 1.58\%$  (at 5 min) and  $1.73 \pm 0.57\%$  (at 10 min) after propofol, and  $3.72 \pm 1.27\%$  (at 5 min) and  $4.66 \pm 1.27\%$  (at 10 min) after xylazine-ketamine administration. Group P revealed significantly ( $P < 0.05$ ) lower RP- $\alpha$  and RP- $\beta$  values.

### Discussion

Electroencephalography is a non-invasive method, where the recorded waveforms reflect the cortical electrical activity generated by the brain cells in the time course of extracellular field potentials in a synchronous action.

The primary objective of surgical anaesthesia is insensitivity to pain. General anaesthesia is associated with neuroelectric changes in the brain, which are partly detected by EEG recordings from scalp electrodes. Alertness and somnolence are associated with the level of nervous activity of the diencephalons and ascending reticular formation of the brainstem (MAGOUN, 1950). EEG has become an adjudicated tool for anaesthesiologists to recognize the wakefulness, sedation, or unresponsiveness state of the animal, and thereby: (1) decreasing the incidence of intraoperative awareness by detection of inadequate anaesthesia; (2) reducing time to awakening and overall anaesthetic consumption; and (3) providing surrogate information on cerebral perfusion. Inadequate information is available to determine the appropriate anaesthetic for short term surgical procedures in goats. Moreover, EEG changes associated with veterinary anaesthesia are largely unexplored.

This study analyses the brain's regional activity in goats during anaesthesia, evaluating the different EEG changes, and thus ascertaining the better anaesthetic between propofol and xylazine-ketamine in goats for short term surgical interventions. Propofol is a short acting lipophilic intravenous

general anaesthetic resulting in hypnosis. Xylazine is methyl benzene, an  $\alpha_2$  adrenergic agonist and an analogue of clonidine, inducing deep sedation, muscle relaxation, and analgesia. Ketamine is a NMDA receptor antagonist and a “dissociative” anaesthetic with hypnotic, analgesic and amnesic effects. The Xylazine-ketamine combination is a reliable anaesthetic, where xylazine is used as premedication and ketamine for the induction and maintenance of general anaesthesia.

EEG power indicates the number of neurons discharging synchronously. It could be assumed that EEG power is a measure that reflects the capacity or performance of cortical processing information. Relative power tends to give higher estimates for dominant frequency range and lower estimates for frequencies which fall outside this range (BERGAMASCO et al., 2005).

The results showed a significant ( $P < 0.05$ ) increase in total power post-anaesthesia and a decrease during recovery from the anaesthetic state, supporting previous observations in propofol anaesthetized goats (ANTOGNINI et al., 2001; MADAN et al., 2010) and halothane anaesthetized chicken (MCILHONE et al., 2018). With increasing concentrations of the anaesthetic drug, cortical activity is depressed (GEORGE et al., 2017). Higher amplitudes during anaesthesia occur due to the improved merger of electrical potentials from individual neurons when fired at lower frequency (CUNNINGHAM, 1997). Group P revealed significantly ( $P < 0.05$ ) lower values in most electrodes compared to the XK group, suggesting xylazine-ketamine elicits better anaesthetic effects than propofol.

SEF-90 refers to the power of frequency accounting for 90% of the total EEG power, while median frequency refers to the power of frequency accounting for 50% of the total EEG power. In different studies a significant decrease in SEF was observed during general anaesthesia (KULKA et al., 2012; KOCH et al., 2017; MCILHONE et al., 2018) in different species. ANTOGNINI et al. (2001) hypothesized that propofol indirectly depresses EEG and midbrain reticular formation neuronal responses to noxious stimulation, in part by subcortical action.

Also, MF significantly increased from the awake baseline data with anaesthetic adequacy. Our result supports previous observations in pigs (MARTÍN-CANCHO et al., 2006), chicken (MCILHONE et al., 2018) and rainbow trout (BOWMAN et al., 2019). MF after xylazine-ketamine administration started advancing to its pre-anaesthetic values earlier (after 1 min) compared to after propofol administration. Therefore, propofol elicited slightly better anaesthetic effects on MF.

The  $\delta$  and  $\theta$  relative power increased (synchronization) with the anaesthetic efficacy. In contrast, slow-wave activity was observed with a simultaneous decrease (synchronization) in  $\alpha$  and  $\beta$  activity. These changes reversed with the return to consciousness. Our results are similar to the anaesthetic studies in children (KOCH et al., 2017), and rainbow trout (BOWMAN et al., 2019). A decrease in frequency was reported in goats during epidural anaesthesia (HUOZHA et al., 2011), and drowsiness (HUOZHA et al., 2009). Also, MADAN et al. (2017) observed similar changes in RP- $\theta$  and  $-\alpha$  during resting phases in goats. RP- $\delta$  reached its peak steadily (at 5 min) after xylazine-ketamine administration. Therefore, xylazine-ketamine was observed to be more effective on RP- $\delta$ . Group P revealed significantly ( $P < 0.05$ ) higher RP- $\theta$  values in most electrodes, but significantly ( $P < 0.05$ ) lower RP- $\alpha$  and  $-\beta$  values, suggesting that propofol has better anaesthetic effects.

A pre-eminent depiction of EEG power spectrum parameters: MF, RP- $\theta$  in the left parietal channel; RP- $\alpha$ ,  $-\delta$  in right parietal and  $P_{tot}$ , RP- $\beta$  in vertex channels was observed in both the anaesthetic groups (Fig. 2). Therefore, it was inferred that the parietal and vertex areas of the brain are most active during the anaesthetized state in goats. Propofol manifested superior anaesthetic effects on q-EEG parameters: RP- $\theta$ ,  $-\alpha$ ,  $-\beta$ , and MF, while xylazine-ketamine exhibited better effects on total power and RP- $\delta$ . Both the anaesthetics displayed a non-significant effect on SEF-90. Among the four frequency bands of relative power analysed, the theta oscillating networks are fastest in discrimination (BERGAMASCO et al., 2005). The anaesthetic effects on EEG tracings also indicated

that propofol anaesthesia is metabolised faster and exhibits easier and quicker recovery.

Therefore, considering the anaesthesia exhibiting the best effects on RP- $\theta$  and exhibiting better anaesthetic effects on the majority of q-EEG parameters, propofol can be said to be the better anaesthetic for short term anaesthesia in goats.

### Conclusion

EEG is a reliable tool for assessment of pain perception at the depth of surgical anaesthesia, as revealed in this study of propofol and xylazine-ketamine anaesthesia in goats. Propofol and the xylazine-ketamine combination are widely used short term anaesthetics for minor surgeries in goats. q-EEG changes were best depicted in parietal and vertex channels under both anaesthetic regimens. EEG tracing conveniently evaluated the better anaesthetic between propofol and xylazine-ketamine. Spectral analysis of EEG tracings suggested that propofol produced minimum anaesthetic stress and is the safer and better choice for short period anaesthesia in goats. Propofol anaesthesia can be incorporated in minor surgeries in other ruminants as well, and the anaesthetic regimen can be used as such or with some modifications depending on the species.

### Acknowledgments

The costs of this work were supported by the College of Veterinary and Animal Sciences, G.B. Pant University of Agriculture and Technology, Pantnagar, India.

### References

- ANAND, M., J. P. KORDE, S. K. RASTOGI, A. K. MADAN (2013): Electro-encephalographic studies on crossbred (Local x Jamunapari) female goats subjected to different feeding practices. *Indian J. Anim. Res.* 47, 236-239.
- ANTOGNINI, J. F., J. SAADI, X. W. WANG, E. CARSTENS, M. PIERCY (2001): Propofol action in both spinal cord and brain blunts electroencephalographic responses to noxious stimulation in goats. *Sleep.* 24, 26-31.  
DOI: 10.1093/sleep/24.1.26
- BERGAMASCO, L., E. MACCHI, C. FACELLO, P. BADINO, R. ODORE, G. RE, M. C. OSELLA (2006): Electroencephalographic power spectral analysis of growing goat kids (*Capra hircus*). *Small Rumin. Res.* 66, 265-72.  
DOI: 10.1016/j.smallrumres.2005.08.025
- BERGAMASCO, L., E. MACCHI, C. FACELLO, P. BADINO, R. ODORE, S. PAGLIASSO, C. BELLINO, M. C. OSELLA, G. RE (2005): Effects of brief maternal separation in kids on neurohormonal and electroencephalographic parameters. *Appl. Anim. Behav. Sci.* 93, 39-52.  
DOI: 10.1016/j.applanim.2004.12.002
- BOWMAN, J., P. HELMSTEDT, A. GRÄNS (2019): Non-invasive recording of brain function in rainbow trout: Evaluations of the effects of MS-222 anaesthesia induction. *Aquac. Res.* 50, 3420-3428.  
DOI: 10.1111/are.14300
- BUFALARI, A., C. E. SHORT, C. GIANNONI, O. VAINIO (1996): Comparative responses to propofol anaesthesia alone and with alpha 2-adrenergic medications in a canine model. *Acta Vet. Scand.* 37, 187-201.  
DOI: 10.1186/BF03548111
- CUNNINGHAM, J. G. (1997): Textbook of Veterinary Physiology. 2<sup>nd</sup> ed., W.B. Saunders Company, India.
- FISH, R., P. J. DANNEMAN, M. BROWN, A. KARAS (2011): Anesthesia and analgesia in laboratory animals. 2<sup>nd</sup> ed., Academic press, London.
- GEORGE, E., D. G. GLAN, K. K. AVINASHE, S. VIJAYAN (2017): Study of different spectral parameters to measure depth of anesthesia. *Biomed. Res.* 28.
- HUOZHA R., S. K. RASTOGI, J. P. KORDE, A. K. MADAN (2011): Electroencephalographic changes during experimental pain induction in goats. *Vet. arhiv* 81, 359-368.
- HUOZHA, R., S. K. RASTOGI, A. K. MADAN (2015): Electroencephalography (EEG) of rumination state and during managerial distress in goats. *Int. J. Appl. Agric. Res.* 13, 462- 65.
- HUOZHA, R., S. K. RASTOGI, A. K. MADAN, A. K. SRIVASTAVA (2009): Electroencephalographic attributes of goats under conscious state. *Indian J. Physiol. Pharmacol.* 53, 353-358.
- HUOZHA, R., S. K. RASTOGI, J. P. KORDE (2018): Electroencephalography (EEG) observations on goats during intravenous fluid infusion. *Indian J. Anim. Physiol.* 5, 37-42.
- KHAN, I., A. KUMAR, J. SINGH, P. K. PESHIN, S. SINGH (2007): Evaluation of glycopyrrolate-xylazine as a sedative in buffalo calves (*Bubalus bubalis*). *Ital. J. Anim. Sci.* 6, 1011-1014.  
DOI: 10.4081/ijas.2007.s2.1011
- KOCH, S., A. M. STEGHERR, R. MÖRGELI, S. KRAMER, E. TOUBEKIS, G. LICHTNER, F. VON DINCKLAGE, C. SPIES (2017): Electroencephalogram dynamics in children during different levels of anaesthetic depth. *Clin. Neurophysiol.* 128, 2014-2021.  
DOI: 10.1016/j.clinph.2017.07.417
- KULKA, A. M., K. A. OTTO, C. BERGFELD, M. BEYERBACH, S. B. KÄSTNER (2012): Effects of

- isoflurane anesthesia with and without dexmedetomidine or remifentanyl on quantitative electroencephalographic variables before and after nociceptive stimulation in dogs. *Am. J. Vet. Res.* 73, 602-609.  
DOI: 10.2460/ajvr.73.5.602
- MADAN, A. K., J. P. KORDE, A. K. DAS, S. K. RASTOGI (2010): Propofol induced electroencephalographic, electrocardiographic and spirometric changes in goats. *Vet. arhiv* 80, 27-39.  
DOI: 10.3906/vet-1604-14
- MADAN, A. K., S. K. RASTOGI, A. K. DAS, J. P. KORDE, I. SINGH, G. K. SINGH (2017): Electroencephalographic electrode montage in goats: topographical, radiological, and physiological assessment. *Turkish J. Vet. Anim. Sci.* 41, 265-272.  
DOI: 10.3906/vet-1604-14
- MAGOUN, H. W. (1950): Caudal and cephalic influences of the brain-stress reticular formation. *Physiol. Rev.* 30, 459-474.  
DOI: 10.1152/physrev.1950.30.4.459
- MARTÍN-CANCHO, M. F., J. R. LIMA, L. LUIS, V. CRISÓSTOMO, M. A. LÓPEZ, L. J. EZQUERRA, M. S. CARRASCO-JIMÉNEZ, J. USÓN-GARGALLO (2006): Bispectral index, spectral edge frequency 95% and median frequency recorded at varying desflurane concentrations in pigs. *Res. Vet. Sci.* 81, 373-81.  
DOI: 10.1016/j.rvsc.2006.01.003
- MCILHONE, A. E., N. J. BEAUSOLEIL, N. J. KELLS, C. B. JOHNSON, D. J. MELLOR (2018): Effects of halothane on the electroencephalogram of the chicken. *Vet. Med. Sci.* 4, 98-105.  
DOI: 10.1002/vms3.91
- MURRELL, J. C., C. B. JOHNSON (2006): Neurophysiological techniques to assess pain in animals. *J. Vet. Pharmacol. Ther.* 29, 325-35.  
DOI: 10.1111/j.1365-2885.2006.00758.x
- OTTO, K. A. (2008): EEG power spectrum analysis for monitoring depth of anaesthesia during experimental surgery. *Lab. Anim.* 42, 45-61.  
DOI: 10.1258/la.2007.006025
- PRASSINOS, N. N., A. D. GALATOS, D. A. RAPTOPOULOS (2005): Comparison of propofol, thiopental or ketamine as induction agents in goats. *Vet. Anaesth. Analg.* 32, 289-296.  
DOI: 10.1111/j.1467-2995.2005.00204.x
- SEITSONEN, E. R., I. K. KORHONEN, M. J. VAN GILS, M. HUIKU, J. M. LÖTJÖNEN, K. T. KORTTILA, A. M. YLI-HANKALA (2005): EEG spectral entropy, heart rate, photoplethysmography and motor responses to skin incision during sevoflurane anaesthesia. *Acta Anaesthesiol. Scand.* 49, 284-92.  
DOI: 10.1111/j.1399-6576.2005.00654.x
- SILVA, A., L. ANTUNES (2012): Electroencephalogram-based anaesthetic depth monitoring in laboratory animals. *Lab. Anim.* 46, 85-94.  
DOI: 10.1258/la.2012.011135
- STOELTING, R. D., R. D. MILLER (2000): Intravenous anaesthetics. In: *Basics of anaesthesia*. (Stoelting, R. K., R. D. Miller, Eds.), Churchill Livingstone, Philadelphia, USA, pp. 58-60.

Received: 7 July 2020

Accepted: 5 March 2021

---

**YADAV, M., S. K. RASTOGI, A. K. DAS, M. PANT, A. K. MADAN, R. HUOZHA: Eleketroencefalografski pokazatelji za vrijeme anestezije propofolom i ksilazin-ketaminom u koza. *Vet. arhiv* 92, 45-52, 2022.**

**SAŽETAK**

U stočarskoj praksi se za kratkotrajne kirurške zahvate sve više primjenjuje intravenska anestezija. Nedostaju međutim podaci na temelju kojih bi se ustanovila kvaliteta anestezijskog protokola u koza. Kako bi se procijenila kvaliteta kombinacije anestetika propofola i ksilazin-ketamina, provedena je analiza elektroencefalografskih pokazatelja u 12 zdravih odraslih koza. Koze su bili križanci barbari pasmine u dobi od 2 do 4 godine. Kvantitativna analiza EEG pokazatelja (*total power*, *median frequency*, *SEF-90*, *relative power* delta- $\delta$ , theta- $\theta$ , alfa- $\alpha$  i beta- $\beta$  frekvencijskih pojaseva) procijenjeni su prije pokusa (kontrolna skupina), te 1, 5, 10, 30 minuta, jedan sat i dva sata nakon intravenske primjene propofola (4 mg/kg) i ksilazin (0,05 mg/kg)-ketamina (4 mg/kg). Nakon primjene propofola i ksilazin-ketamina *total power*, te *relative power*- $\delta$  i *relative power*- $\theta$  znakovito su porasli ( $P < 0,05$ ), dok su se *SEF 90*, *median frequency*, *relative power*- $\alpha$  i *relative power*- $\beta$  snizili. Većina EEG promjena odgovarajuće je prikazana u verteksu i parijetalnim kanalima. Spektralna analiza EEG-a upućuje na to da propofol u anestezijskom protokolu uzrokuje minimalan stres te je, u usporedbi sa ksilazin-ketaminom, za kratkotrajnu anesteziju koza sigurniji i bolji izbor.

**Ključne riječi:** anestezija; elektroencefalografija; koza; propofol; ksilazin-ketamin

---