

Topical application of 'Hemin' promotes wound healing in Streptozotocin-induced diabetic rats

Azad A. Ahanger¹, Shahid Prawez^{2*}, Abdul Shakoor¹, Wasif Ahmad¹, Adil M. Khan¹, and Dinesh Kumar³

¹*Division of Pharmacology and Toxicology, Faculty of Veterinary Sciences & A.H., Sher-e-Kashmir University of Agricultural Sciences and Technology-Kashmir, Shuhama, Alusteing, Srinagar, India*

²*Department of Veterinary Pharmacology & Toxicology, Faculty of Veterinary & Animal Sciences, Institute of Agricultural Sciences, RGSC-Banaras Hindu University, Barkachha, Mirzapur, India*

³*Division of Pharmacology and Toxicology, ICAR-Indian Veterinary Research Institute, Izatnagar, Bareilly (UP), India*

AHANGER, A. A., S. PRAWEZ, A. SHAKOOR, W. AHMAD, A. M. KHAN, D. KUMAR: Topical application of 'Hemin' promotes wound healing in Streptozotocin-induced diabetic rats. Vet. arhiv 91, 287-296, 2021.

ABSTRACT

Hemin may be of potential therapeutic value in wound healing management in diabetics. It is an inducer of heme oxygenase-1, an enzyme which degrades heme and participates in cellular protection against oxidative stress, inflammation and apoptosis. Thus, in the present study, hemin (0.5%) was applied topically over excision wounds, and its therapeutic effect in wound healing evaluated in diabetic rats. Topical hemin application significantly increased the percentage of wound contraction on day 2 in diabetic rats, however, povidone-iodine did the same on day 7 compared to the diabetic control. A significant increase in hydroxyproline and glucosamine content was found on day 14 in the hemin treated wounds of diabetic rats vs. the diabetic control. The histology of the hemin treated rats was in agreement with the cellular proliferation and collagen synthesis in granulation tissue. Hemin significantly increases cytokine IL-10 and decreases TNF- α in the granulation tissue of the healed wounds of diabetic rats. The finding showing the pro-healing effects of hemin was endorsed by inhibition of mRNA expression of pro-inflammatory cytokine TNF- α and adhesion molecule ICAM-1, and up-regulation of anti-inflammatory cytokine IL-10 mRNA. Hence, topical hemin application (i) helps in early and fast wound contraction (ii) enhances the hydroxyproline and glucosamine content of wounds and (iii) modulates pro-healing mRNA expression of cytokines.

Key words: hemin; diabetes; wound; mRNA expression; TNF- α ; ICAM-1; IL-10; rat

Introduction

Diabetes mellitus is a disease known for delaying normal healing processes (SINGH et al., 2005). The sequential influx of inflammatory cells, proliferation of stromal elements, growth of blood vessels and production of an extra-cellular matrix

are essential for efficient wound healing (DONALD and ZACHARY, 2004). Normal wound healing proceeds slowly, and delay in wound healing are associated with infection, diabetes mellitus, immunosuppression, obesity and malnutrition

*Corresponding author:

Shahid Prawez, Department of Veterinary Pharmacology & Toxicology, Faculty of Veterinary & Animal Sciences, Institute of Agricultural Sciences, RGSC-Banaras Hindu University, Barkachha, Mirzapur-231 001 (UP), India, E-mail: shahidprawez@gmail.com

(GUPTA et al., 1999). Delayed wound healing is a recognized problem in diabetes mellitus. Despite some recent advances in our understanding of the mechanisms, impaired wound healing in diabetics continues to cause significant mortality or physical disability (FINE and MUSTOE, 2006). Abnormalities resulting in impaired wound healing in diabetes include compromised neovascularization, a decrease in collagen synthesis, altered macrophage functions, and an increase in proteinase activity (FAHEY et al., 1991; LOOTS, 1998).

Several studies have been published on the stress proteins expressed in the body during stress, and one such protein is heme oxygenase-1 (HO-1). HO is a rate-limiting enzyme in the catabolism of heme that leads to the formation of bile pigment biliverdin, carbon monoxide (CO) and free iron- Fe^{2+} (ABRAHAM and KAPPAS, 2008). HO-1 gene expression can be induced by diverse stimuli, such as xenobiotics, endocrine factors, metals, heat-shock, cytokines, endotoxins and oxidative-stress (IMMENSCHUH and RAMADORI, 2000; SHIBAHARA et al., 1987). It is well documented that HO-1 speeds up wound healing (GROCHOT-PRZECZEK et al., 2009; HANSELMANN et al., 2001; KAMPFER et al., 2001). Degradation of heme participates in cellular defense by removing pro-oxidant heme, and increasing bilirubin and carbon monoxide, which contribute in cutaneous wound healing (AHANGER et al., 2011). Similarly, the strong prohealing effect of bilirubin has been explored in open excision cutaneous wounds in rats (AHANGER et al., 2016).

Hemin, a hemoglobin component and an inducer of HO-1, has been approved by the U.S. Food and Drug Administration for treatment of acute porphyria. Hemin induces HO-1 and thus, has a therapeutic value in conditions where higher levels of HO-1s are desired. Previous studies in our laboratory have demonstrated the strong prohealing effects of hemin onto excision wounds in normo-glycemic rats (AHANGER et al., 2010). In the present study we directly applied hemin ointment (0.5%) to excision wounds created in diabetic rats.

Materials and methods

Experimental animals. Healthy male adult Wistar rats (200-250g) were housed in polypropylene cages with free access to standard balanced feed and water, in divisional animal houses. The experimental protocols were approved by the Institutional Animal Ethics Committee, which follows the guidelines for Care and Use of Laboratory Animals published by the US National Institute of Health (NIH, 1996).

Diabetes induction. Freshly prepared streptozotocin solution (Sigma Chemicals) in a citrate buffer of pH 7.4 was administered to the rats at a dosage of 40 mg/kg body weight intraperitoneally (i.p.) to induce diabetes. Blood glucose levels were measured 48 hours after streptozotocin administration. Rats with fasting blood glucose levels greater than 200 mg/dL were selected for the experiment. Diabetic rats were kept under observation for a period of 7 days before creation of wounds (AHMAD et al., 2014).

Excision wound creation. Fifteen diabetic rats were housed at a room temperature of 22 ± 2 °C. The rats were anaesthetized using an intraperitoneal injection of Pentobarbital sodium at a dosage of 50 mg/kg body weight. An open excision wound with an area of 2×2 cm² was created to the depth of the loose subcutaneous tissue (AHANGER et al., 2010). After recovery from anesthesia, the rats were housed individually in disinfected cages and divided into three groups, namely: Group I (Diabetic Control), Group II (Povidone iodine treated) and Group III (Hemin treated). Fifteen diabetic rats were used in this study with five rats in each group. Each rat was kept individually in a cage 43x27x15 cm in size. 100 gms of simple ointment was prepared by the fusion method, containing soft paraffin (85g), hard paraffin (10g) and wool fat (5g). In Group-I the simple ointment was applied topically over the wounds of the diabetic rats once daily for 13 days. Povidone-ointment was topically applied to the wounds of Group II diabetic rats once daily for 13 days. For Group-III, hemin ointment (0.5%, Sigma Chemicals) in a simple ointment base was topically applied over the wound of the diabetic rats once daily for 13 days.

Wound area measurement. The surface area of the wound outline was measured using transparent paper on days 0, 2, 4, 7, 10 and 14 after creation of the wound. The area (mm²) within the boundaries of each tracing was determined planimetrically (AHANGER et al., 2011). The percentage of wound contraction was calculated as follows:

$$\% \text{ wound contraction} = \frac{\text{Zero day wound area} - \text{unhealed wound area}}{\text{Zero day wound area}} \times 100$$

Biochemical parameters of wound. On day 14 after wound creation, granulation tissue from the healed wound was excised to analyze the levels of hydroxyproline (WOESSNER, 1961) and glucosamine (RONDLE and MORGAN, 1995).

ELISA assay for IL-10 and TNF- α cytokines. The granulation tissue having been stored at -80 °C was pulverized in ice-cold lysis buffer containing 100 mM Tris-HCl, 0.05 mM EDTA. About 50 mg of granulation tissue, in 500 μ L of lysis buffer and a pinch of glass wool, was pulverized with the help of a chilled pestle and mortar. Pulverized tissues were converted to a homogenous mixture, transferred into 1.5 mL micro-centrifuge tubes, and centrifuged for about 10 min at 10000 rpm. From the centrifuged mixture, supernatant protein lysate was collected for the further protocols. The ELISA protocol was followed as per the instructions provided (eBioscience Inc. Catalogue Nos 88-7340-22-TNF- α and 88-7104-22-IL-10). The total protein of the lysate was also estimated to express the value of cytokine on a w/w basis (LOWRY et al., 1951).

Histological studies. Granulation tissue from the skin, kept for analysis in 10% formalin solution, was subjected to sectioning. The 6 μ m thick sections were stained with hematoxylin and eosin to show histological changes under a light microscope (LUNA, 1968).

mRNA expression studies. Granulation tissue was excised from healed wound tissue on day 14 after wound creation and used to study expression of mRNA, cytokines IL-10, TNF- α and adhesion molecule ICAM-1. Total RNA was extracted using the QIAGEN RNeasy Mini-extraction kit (QIAGEN Ltd., Valencia, USA). cDNA synthesis

was carried out using MMLV reverse transcriptase. Gene expression was determined using a real-time PCR technique. Published primer sequences specific for rat IL-10, TNF- α , Intracellular Cell Adhesion Molecule-1 (ICAM-1) and β -actin were applied (AHANGER et al., 2010; AHANGER et al., 2016). β -actin was used as the house-keeping gene for relative quantitation of other expressed mRNAs.

Real-time PCR reactions were conducted on a Stratagene Q-Cycler and analyzed using Mx3000P software, with SYBR Green as the reference dye. To ascertain the specificity of the amplified product, dissociation curves were generated at temperatures 55 °C to 95 °C. Results were expressed in terms of threshold cycle values (CT). To track relative change in gene expression, the 2^{- $\Delta\Delta$ CT} method was used (LIVAK and SCHMITTEN, 2001). This method was used to calculate the fold change in gene expression as: 'Fold change = 2^{- $\Delta\Delta$ CT} where $\Delta\Delta$ CT = (CT of target gene - CT of β -actin) treatment - (CT of target gene - CT of β -actin) control.

Statistical analysis. Values were expressed as Mean \pm SEM., with n being equal to the number of replicates. The statistical significance between the experimental and control values was analyzed by analysis of variance, followed by Dunnet's test, using Graphpad Prism v4.03 software programme (San Diego, California, USA), and the differences between experimental and control groups were considered statistically significant at P<0.05.

Results

Effect of Hemin on wound contraction. The effect of hemin on wound contraction was studied in excision wounds in diabetic rats on days 0, 2, 4, 7, 10 and 14 (Fig.1.A). The hemin-treated group showed a significant increase in wound contraction on day 2 post-treatment; however, an equally significant change was recorded in the povidone-iodine treated diabetic rats on day 7 onwards, compared to the diabetic control. Interestingly, hemin treatment initiated an early significant change in wound contraction from day 2, compared to povidone treatment from day 7 in the diabetes rats.

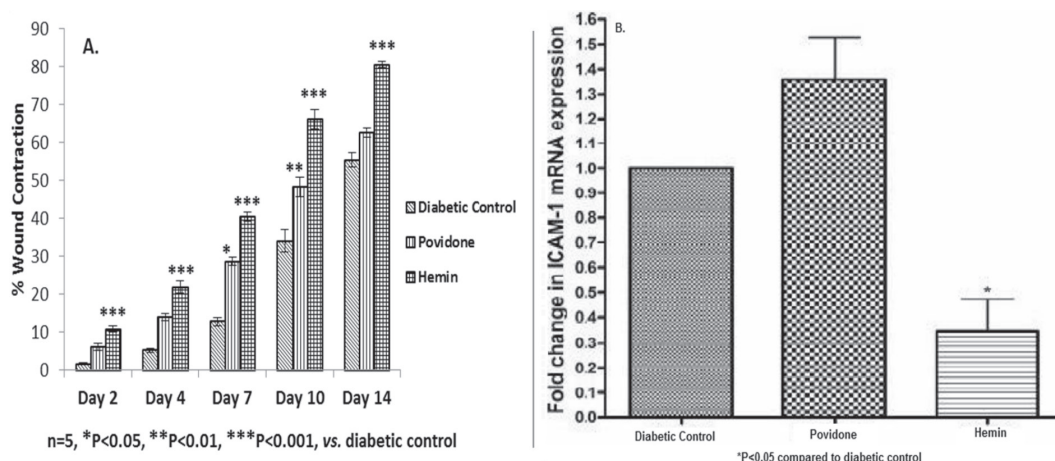


Fig. 1. The effect of topical application of hemin (0.5%) on (A). % wound contraction in diabetic rats and (B). ICAM-1 mRNA expression in wound granulation tissue on day 14 in diabetic rats.

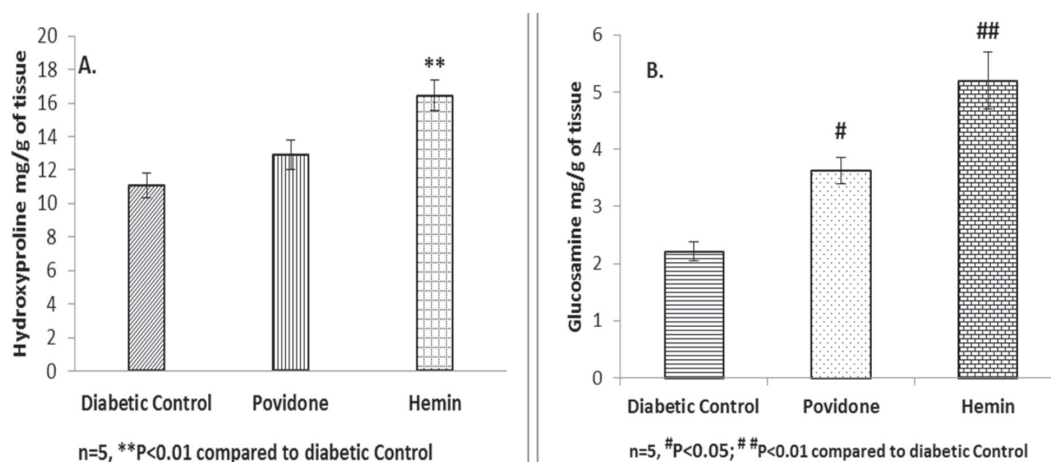


Fig. 2. The effect of topical application of hemin (0.5%) on (A). hydroxyproline content and (B). glucosamine content in the granulation tissue of excision wounds on day 14 in diabetic rats

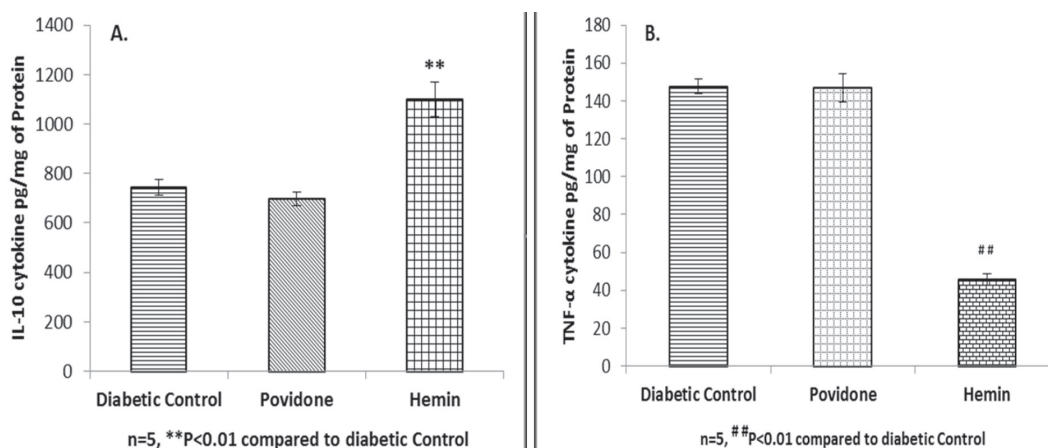


Fig. 3. The effect of topical application of hemin (0.5%) on (A). IL-10 levels and (B). TNF-α levels in granulation tissue on day 14 in diabetic rats

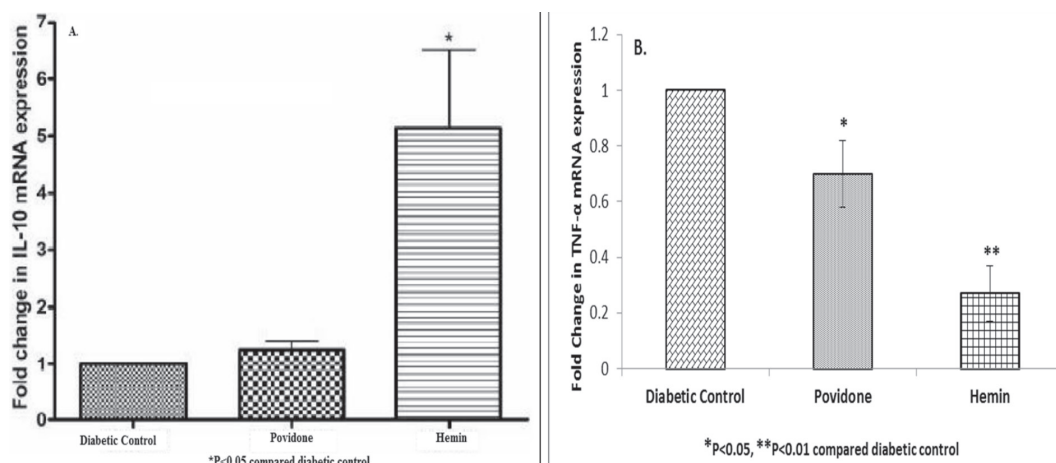


Fig. 4. The effect of topical application of hemin on (A). IL-10 mRNA expression and (B). TNF- α mRNA expression in wound granulation tissue on day 14 in diabetic rats.

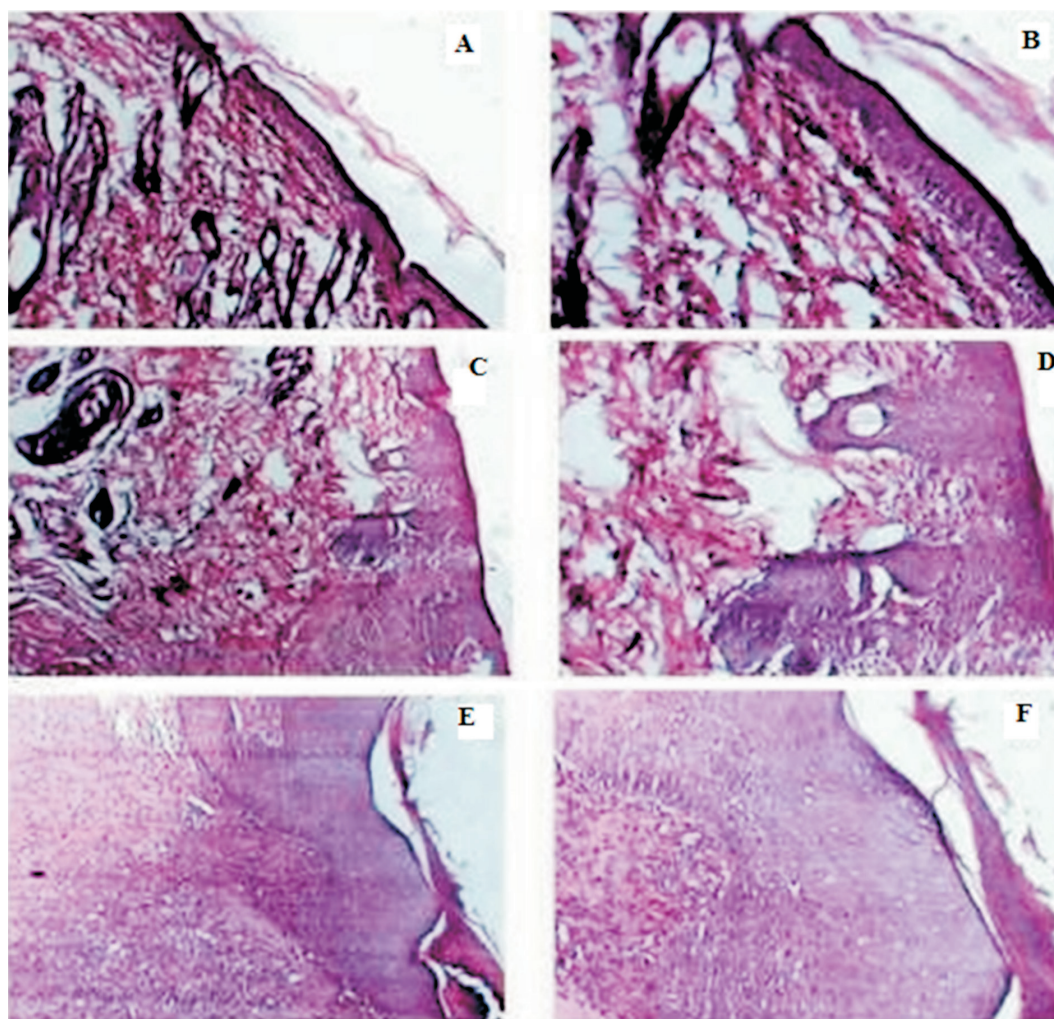


Fig. 5. The effect of topical application of hemin on wound granulation tissue on day 14 in diabetic-control rats (A & B); povidone iodine-treated diabetic group (C & D) and hemin treated diabetic group (E & F) in H and E stained under 40 \times and 100 \times magnification, respectively

Effect of Hemin on the pro-healing constituents of the wound matrix (Hydroxyproline and Glucosamine). Hemin treatment significantly increased hydroxyproline content (16.44 ± 0.93 mg/g tissue) in the granulation tissue of healed skin as compared to the diabetic control (11.05 ± 0.74 mg/g tissue; Fig. 2.A). Hemin treatment significantly increased the glucosamine content of healed skin (5.20 ± 0.50 mg/g tissue) on day 14 of hemin-treatment, as compared to the diabetic-control (2.21 ± 0.17 mg/g tissue). Similarly, povidone-iodine treatment also significantly increased glucosamine content compared to the diabetic-control (Fig. 2.B).

Effects of hemin on pro-healing inflammatory/anti-inflammatory cytokines. Cytokine levels of IL-10 and TNF- α were assayed in the granulation tissue of diabetic rats following topical application of hemin, using an ELISA kit (Fig. 3.A & B). A significant increase in IL-10 levels was found in the granulation tissue of the hemin-treated diabetic rats (1100.9 ± 69.97 pg/mg of protein) compared to the diabetic-control rats (743.06 ± 32.72 pg/mg of protein). In contrast, a significant reduction in TNF- α levels was found in the granulation tissue of the hemin-treated (45.76 ± 3.03 pg/mg protein) diabetic-rats compared to the diabetic-control rats (147.54 ± 3.85 pg/mg of protein).

Effects of hemin on adhesion molecule (ICAM-1) and cytokine (IL-10 & TNF- α) mRNA expression. The relative expression of ICAM-1 mRNA in response to hemin application, compared to the diabetic-control group, is presented in Fig. 1.B. Hemin treatment significantly decreased the relative expression of ICAM-1 mRNA (0.35 ± 0.12 folds) compared to the diabetic-control group.

The effect of topical application of hemin on the relative expression of IL-10 mRNA in the granulation tissue of the wounds in the different experimental groups is depicted in Fig. 4.A. Hemin treatment produced a significant increase in the relative expression of IL-10 mRNA (5.13 ± 1.39 folds) compared to the diabetic-control group. In povidone-treated rats, the mRNAs of IL-10 and ICAM-1 did not show significant change compared to the diabetic control.

Topical application of povidone and hemin on the wounds of diabetic rats elicited a significant reduction in the relative expression of TNF- α mRNA in the granulation tissue of the wounds (0.27 ± 0.10 folds) compared to the diabetic-control (Fig. 4.B).

Histological findings. Diabetic-control rats showed loose and vacuolated granulation tissue with massive inflammation and a few necrotic patches (Fig. 5.A & B). Povidone iodine-treated wounds (Fig. 5.C & D) showed relatively better granulation tissue, epithelialization and less inflammatory cell infiltration compared to the diabetic-control rats. The hemin-treated wounds of diabetic rats (Fig. 5.E & F) revealed compact and mature granulation tissue with dense epithelial lining and numerous neovascularization foci.

Discussion

Impairment of wound healing in diabetic mice has been attributed to delays in the transformation of fibroblasts to myofibroblasts and granulation tissue formation (DIPIETRO and BURNS, 2003). Topical application of hemin (0.5%) onto the excision wounds of the diabetic rats recorded about 80% contraction on day 14 compared to 55% in the diabetic-control group. Delayed wound healing in diabetes was partially reversed through HO-1 over-expression, which led to increased vascularization of wounded tissue (GROCHOT-PRZECZEK et al., 2009).

Chronic wounds seen in diabetic patients are caught in the inflammatory phase featuring continuous influx of neutrophils that release cytotoxic enzymes, free radicals and inflammatory mediators, which results in extensive collateral damage to the surrounding tissue. These destructive processes lead to imbalance in the healing process and delayed repair (FALANGA, 2000). The povidone-iodine group revealed a significant effect on wound contraction in diabetic wounds from day 7 onwards. This late effect may be attributed to the ability of povidone-iodine to keep the infection of the wound under control. Comparison of povidone-iodine to silver sulphadiazine in topical treatment of flame and fluid burn wounds in humans has

demonstrated a better healing response with povidone-iodine (DEKOCK et al., 1989).

Impairment in the normal process of wound healing is present in diabetic patients. Several factors have been suggested to impair healing, such as impairment in neovascularization, reduced collagen synthesis, increased activity of proteinases, and defective immunological functions (LOOTS, 1998). LOOTS (1998) reported reduced collagen synthesis and extracellular matrix in diabetes. In the present study, hydroxyproline and glucosamine content was significantly increased in the granulation tissue of hemin-treated rats compared to diabetic-control.

It has been found that the healing process inhibits expression of the pro-inflammatory mediator cytokines ICAM-1 and TNF- α and in contrast stimulates the anti-inflammatory mediator cytokine IL-10 (ABRAHAM and KAPPAS, 2008). The prolonged persistence of neutrophils and macrophages in the wounds of diabetic mice (db/db mice) leads to higher levels of pro-inflammatory mediators, such as IL-1 α , IL-1 β , IL-6 and TNF- α cytokines, which delays wound healing (WETZLER et al., 2000). Up-regulation of HO-1 through gene transfer in hyperglycemic rats demonstrated the arrest of endothelial sloughing, attenuation of glucose-mediated oxidative stress, DNA damage, and a reduction in cell death (SACERDOTI et al., 2005). Topical application of hemin (0.5%) onto wounds in diabetic rats led to pro-healing modulation of mRNA expression of adhesion molecules ICAM-1 and TNF- α , IL-10 cytokines, meaning that ICAM-1 and TNF- α mRNA expression significantly decreased and expression of IL-10 mRNA was significantly enhanced in the hemin-treated rats compared to the diabetic-control. The interaction between leukocytes and endothelial cells plays a major role in the pathogenesis of inflammation, tissue repair, or tissue damage (CIOFFI et al., 1992). Therefore, inhibition of leukocyte infiltration in tissue would be an important step in reducing tissue injury and improving immune function. The adhesion molecule ICAM-1 mediates leukocyte adhesion, and correlates with the infiltration of leukocytes into inflammatory lesions (DEFAZIO et al., 2000; RAHMAN et al., 2002). ICAM-1 and

other adhesion molecule expression is the initial marker of the inflammatory reactions involved in acute inflammatory reaction following injury (CUSCHIERI et al., 2003; DEVECI et al., 2000; MILESKI et al., 2003). Expression of TNF- α and IL-10 cytokines was modulated by hemin to favour prompt healing. Induction of HO-1 expression in obese diabetic mice demonstrated a reduction in plasma TNF- α , IL-6 and IL-1 β levels (LI et al., 2008). Bilirubin was found to reduce oxidative stress in experimental diabetes by inhibiting PKC and NADPH oxidase. This may be one mechanism by which HO-1 attenuates the diabetes-mediated generation of oxidant radicals (ABRAHAM and KAPPAS, 2008). We have also demonstrated the strong pro-healing effect of bilirubin in non-diabetic rats (AHANGER et al., 2016). Furthermore, induction of HO-1 expression in diabetic obese mice demonstrated a reduction in plasma TNF- α , IL-6 and IL-1 β levels (LI et al., 2008).

Histological evaluation involved morphometric evaluation of re-epithelialization, wound contraction, the maturity of granulation tissue, angiogenesis and inflammation. It is well known that modulation of fibroblasts toward a myofibroblast phenotype is essential for tissue remodeling during normal and pathological wound healing (CONRAD et al., 1993; TOMASEK et al., 2002). Weak and slow wound contraction in db/db mice has been attributed to delayed myosin appearance due to the altered conditions in the wound milieu. The diabetic control rats showed loose and vacuolated granulation tissue with massive inflammation and a few necrotic patches. Povidone iodine-treated wounds showed relatively better granulation tissue, but there was mild inflammatory cell infiltration. Epithelialization was also better than in the diabetic-control group. The hemin-treated group revealed relatively loose granulation tissue, but the epithelial lining was dense and there were numerous neovascularization foci. Re-epithelialization was seen to play a major role in wound healing in db/db mice, and impaired contraction was the main reason for delayed wound closure (IVETIC et al., 2009).

In conclusion, the present study showed that topical application of hemin onto the wounds of diabetic rats significantly improved the process of

wound healing. Thus, hemin topical application led to: i) early and fast wound contraction in diabetic rats, ii) significant enhancement in the constituents of the extracellular matrix of the granulation tissue of the wound and iii) pro-healing modulation of cytokines/adhesion molecules to regulate the inflammatory process that favors healing.

References

- ABRAHAM, N. G., A. KAPPAS (2008): Pharmacological and clinical aspects of hemeoxygenase. *Pharmacol. Rev.* 60, 79-127.
- AHANGER, A. A., S. PRAWEZ, M. D. M. LEO, K. KATHIRVEL, D. KUMAR, S. K. TANDAN, J. K. MALIK (2010): Pro-healing potential of hemin: An inducer of heme oxygenase-1. *Eur. J. Pharmacol.* 645, 165-170.
DOI: 10.1016/j.ejphar.2010.06.048
- AHANGER, A. A., S. PRAWEZ, D. KUMAR, R. PRASAD, AMARPAL, S. K. TANDAN, D. KUMAR (2011): Wound healing activity of carbon monoxide liberated from CO-releasing molecule (CO-RM). *N-S Arch. Pharmacol.* 384, 93-102.
DOI: 10.1007/s00210-011-0653-7
- AHANGER, A. A., M. D. M. LEO, A. GOPAL, V. KANT, S. K. TANDAN, D. KUMAR (2016): Pro-healing effects of bilirubin in open excision wound model in rats. *Int. Wound J.* 13, 398-402.
DOI: 10.1111/iwj.12319
- AHMAD, M., S. PRAWEZ, M. SULTANA, R. RAINA, N. K. PANKAJ, P. K. VERMA, S. RAHMAN (2014): Anti-hyperglycemic, Anti-hyperlipidemic and Antioxidant potential of Alcoholic-extract of *Sida cordifolia* (Areal part) in Streptozotocin-induced-diabetes in wistar-rats. *Proc. Natl. Acad. Sci. India Sect. B Biol. Sci.* 84, 397-405.
DOI: 10.1007/s40011-013-0218-2
- CIOFFI, W. C., D. G. BURLESON, B. A. PRUITT (1992): Leukocyte responses to injury. *Arch. Surg.* 112, 860-865.
- CONRAD, P. A., K. A. GIULIANO, G. FISHER, K. COLLINS, P. T. MATSUDARIA, D. L. TAYLOR (1993): Relative distribution of actin, myosin I, and myosin II during the wound healing response of fibroblasts. *J. Cell Biol.* 120, 1381-1391.
DOI: 10.1083/jcb.120.6.1381
- CUSCHIERI, J., D. GOURLAY, I. GARCIA, S. JELACIC, R. V. MAIER (2003): Modulation of endotoxin-induced endothelial activity by microtubule depolymerization. *J. Trauma.* 54, 104-112.
DOI: 10.1097/00005373-200301000-00013
- DEFAZIO, G., B. NICO, M. TROJANO, D. RIBATTI, M. GIORELLI, F. RICCHIUTI, D. MARTINO, L. RONCALI, P. LIVREA (2000): Inhibition of protein kinase C counteracts TNF- α -induced ICAM-1-expression and fluid phase endocytosis on brain microvascular endothelial cells. *Brain Res.* 863, 245-248.
DOI: 10.1016/s0006-8993(00)02127-2
- DEKOCK, M., A. E. VAN DER MERWE, C. A. STEWARTS (1989): A comparative study of povidone-iodine cream and silver sulphadiazine in the topical treatment of burns. *Wounds.* 1, 65-71.
- DEVECI, M., M. ESKI, M. SENGEZER, U. KISA (2000): Effects of cerium nitrate bathing and prompt burn wound excision on IL-6 and TNF- α levels in burned rats. *Burns.* 26, 41-45.
DOI: 10.1016/s0305-4179(99)00107-2
- DIPIETRO, L. A., A. L. BURNS (2003): Wound healing. Methods and protocols. Humana Press: Totowa, New Jersey.
- DONALD, M., J. F. ZACHARY (2004): Pathological Basis of Veterinary Diseases, 4th ed., Elsevier Publication.
- FAHEY, T. J., A. SADATY, W. G. JONES, A. BARBER, B. SMOLLER, G. T. SHIRSE (1991): Diabetes impairs the late inflammatory response to wound healing. *J. Surg. Res.* 50, 308-318.
DOI: 10.1016/0022-4804(91)90196-s
- FALANGA, V. (2000): Classifications for wound bed preparation and stimulation of chronic wounds. *Wound Repair Reg.* 8, 347-352.
DOI: 10.1111/j.1524-475x.2000.00347.x
- FINE, N., T. MUSTOE (2006): Wound Healing. Philadelphia: Lippincott Williams & Wilkins.
- GROCHOT-PRZECZEK, A., R. LACH, J. MIS, K. SKRZYPEK, M. GOZDECKA, P. SROCZYNSKA, M. DUBIEL, A. RUTKOWSKI, M. KOZAKOWSKA, A. ZAGORSKA, J. WALCZYNSKI, H. WAS, J. KOTLINOWSKI, J. DRUKALA, K. KUROWSKI, C. KIEDA, Y. HERAULT, J. DULAK, A. JOZKOWICZ (2009): Heme oxygenase-1 accelerates cutaneous wound healing in mice. *PLoS ONE.* 4, e5803.
DOI: 10.1371/journal.pone.0005803
- GUIDE FOR THE CARE AND USE OF LABORATORY ANIMALS, (1996): NIH Publication No. 85-23, revised.
- GUPTA, A., G. K. JAIN, R. RAGHUBIR (1999): A time course study for the development of an immunocompromised wound model using hydrocortisone. *J. Pharmacol. Toxicol.* 41, 183-187.
DOI: 10.1016/s1056-8719(99)00041-6
- HANSELMANN, C., C. MAUCH, S. WERNER (2001): Heme oxygenase-1: a novel player in cutaneous wound repair and psoriasis? *Biochem. J.* 353, 459-466.
DOI: 10.1042/bj3530459
- IMMENSCHUH, S., G. RAMADORI (2000): Gene regulation of heme oxygenase-1 as a therapeutic target. *Biochem. Pharmacol.* 60, 1121-1128.
DOI: 10.1016/s0006-2952(00)00443-3

- IVETIC, V., T. EVIC, S. CUZIC, J.M. PARNHAM, I. PASALIC, K. BRAJSA (2009): Differential Evaluation of Excisional Non-occluded Wound Healing in db/db Mice. *Toxicol. Pathol.* 37, 183-192.
DOI: 10.1177/0192623308329280
- KAMPFER, H., N. KOLB, M. MANDERSCHIED, C. WETZLER, J. PFEILSCHIFTER (2001): Macrophage-derived heme oxygenase-1: expression, regulation and possible functions in skin repair. *Mol. Med.* 7, 488-498.
DOI: 10.1007/bf03401854
- LI, M., D. H. KIM, P. TSENOVOY, S. J. PETERSON, R. REZZANI, L. F. RODELLA, W. S. ARONOW, S. IKEHARA, N. G. ABRAHAM (2008): Treatment of obese diabetic mice with a hemeoxygenase inducer reduces visceral and abdominal adiposity increases adiponectin levels and improves insulin sensitivity and glucose tolerance. *Diabetes* 57, 1526-1535.
DOI: 10.2337/db07-1764
- LIVAK, K. J., T. D. SCHMITTEN (2001): Analysis of relative gene expression data using real-time quantitative PCR and the 2(-DeltaDelta(CT)). *Methods* 25, 402-408.
DOI: 10.1006/meth.2001.1262
- LOOTS, M. A. (1998): Difference in cellular infiltrate and extracellular matrix of chronic diabetic and venous ulcers versus acute wounds. *J. Invest. Dermatol.* 11, 850- 857.
DOI: 10.1046/j.1523-1747.1998.00381.x
- LOWRY, O. H., N. J. ROSEBROUGH, A. L. FARR, R. J. RANDALL (1951): Protein measurement with the folin phenol reagent. *J. Biol. Chem.* 193, 265-275.
DOI: 10.1016/s0021-9258(19)52451-6
- LUNA, L. G. (1968): *Manual of Histologic Staining Methods of the Armed Forces Institute of Pathology*, 3rd ed., Mc.Graw Hill.
- MILESKI, W. J., D. BURKHART, J. L. HUNT, R. J. KAGAN, J. R. SAFFLE, D. N. HERNDON, D. M. HEIMBACH, A. LUTERMAN, R. W. YURT, C. W. GOODWIN, J. HANSBOROUGH (2003): Clinical effects of inhibiting leukocyte adhesion with monoclonal antibody to intercellular adhesion molecule-1 (enlimomab) in the treatment of partial-thickness burn injury. *J. Trauma.* 54, 950-958.
DOI: 10.1097/01.ta.0000030626.84680.11
- RAHMAN, A., A. L. TRUE, K. N. ANWAR, R. D. YE, T. A. VOYNO-YASENETSKAYA, A. B. MALIK (2002): Galpha(q) and Gbetagamma regulate PAR-1 signaling of thrombin- induced NF-kappa-B activation and ICAM-1 transcription in endothelial cells. *Cir. Res.* 91, 398-405.
DOI: 10.1161/01.res.0000033520.95242.a2
- RONDLE, C. J. M., W. I. J. MORGAN (1955): The determination of glucosamine and galactosamine. *Biochem. J.* 61, 586-589.
- SACERDOTI, D., R. OLSZANECKI, V. G. LI, C. COLOMBRITA, G. SCAPAGNINI, N. G. ABRAHAM (2005): Hemeoxygenase overexpression attenuates glucose-mediated oxidative stress in quiescent cell phase: linking heme to hyperglycemia complications. *Curr. Neurovas. Res.* 2, 103-111.
DOI: 10.2174/1567202053586802
- SHIBAHARA, S., M. MULLER, H. TAGUCHI (1987): Transcriptional control of rat hemeoxygenase by heat shock. *J. Biol. Chem.* 262, 12889-12892.
DOI: 10.1016/s0021-9258(18)45138-1
- SINGH, N., D. G. ARMSTRONG, B. A. LIPSKY (2005): Preventing foot ulcers in patients with diabetes. *JAMA.* 293, 217-228.
DOI: 10.1001/jama.293.2.217
- TOMASEK, J. J., G. GABBIANI, B. HINZ, C. CHAPONNIER, R. A. BROWN (2002): Myofibroblasts and mechano-regulation of connective tissue remodeling. *Nat. Rev. Mol. Cell. Biol.* 3, 349-363.
DOI: 10.1038/nrm809
- WETZLER, C., H. KAMPFER, B. STALLMEYER, J. PFEILSCHIFTER, S. FRANK (2000): Large and sustained induction of chemokines during impaired wound healing in the genetically diabetic mouse: prolonged persistence of neutrophils and macrophages during the late phase of repair. *J. Invest. Dermatol.* 115, 245-253.
DOI: 10.1046/j.1523-1747.2000.00029.x
- WOESSNER, J. F. Jr. (1961): The determination of hydroxyproline in tissue and protein sample containing small proportions of this imino acid. *Arch. Biochem. Biophys.* 93, 440-447.
DOI: 10.1016/0003-9861(61)90291-0

Received: 20 May 2020

Accepted: 13 October 2020

AHANGER, A. A., S. PRAWEZ, A. SHAKOOR, W. AHMAD, A. M. KHAN, D. KUMAR: Lokalna primjena hemina unapređuje liječenje rana u štakora s dijabetesom izazvanim streptozotocinom. *Vet. arhiv* 91, 287-296, 2021.

SAŽETAK

Hemin ima potencijalnu terapijsku vrijednost u liječenju rana u dijabetičara. On potiče hem-oksigenazu-1, enzim koji razgrađuje hem i sudjeluje u staničnoj zaštiti od oksidacijskog stresa, upale i apoptoze. U ovom je istraživanju

hemin (0,5 %) primijenjen lokalno na ekscizijske rane te je procijenjen njegov terapijski učinak na cijeljenje rana u dijabetičnih štakora. Lokalna aplikacija hemina znakovito je povećala postotak zatvaranja rana 2. dan u dijabetičnih štakora, što je učinio i povidon-jod 7. dan u kontrolnoj skupini. Znakovit porast sadržaja hidroksiprolina i glukozamina pronađen je 14. dan u dijabetičnih štakora čije su rane tretirane heminom, za razliku od kontrolne skupine. Histologija je u štakora tretiranih heminom bila u skladu sa staničnom proliferacijom i sintezom kolagena u granulacijskom tkivu. Hemin je znakovito povisio citokin IL-10 i smanjio TNF- α u granulacijskom tkivu dijabetičnih štakora sa zacijeljenim ranama. Taj nalaz odgovara ljekovitom učinku hemina što je podržano inhibicijom ekspresije mRNA proupalnog citokina TNF- α i adhezijom molekule ICAM-1 te regulacijom protuupalnog citokina IL-10 mRNA. Dakle, lokalna primjena hemina pomaže (i) u ranoj i brzoj kontrakciji rana (ii), poboljšava sadržaj hidroksiprolina i glukozamina u ranama i (iii) prilagođuje mRNA ekspresiju citokina u smjeru cijeljenja rane.

Ključne riječi: hemin; dijabetes; rane; izražajnost mRNA; TNF- α ; ICAM-1; IL-10; štakori
