

Anatomical landmarks for sciatic nerve access in pinnipeds

Mirela Pavić¹, Suzana Tkalčić², Lauren Palmer³, Denis Leiner¹, Maja Popović⁴,
Zvonimir Budinščak¹, Daniel Špoljarić⁴, Neda Brlek⁵, and Snježana Ćurković¹

¹Department of Anatomy, Histology and Embryology, Faculty of Veterinary Medicine, University of Zagreb, Croatia

²College of Veterinary Medicine, Western University of Health Sciences, Pomona, CA, USA

³Marine Mammal Care Center, San Pedro, CA, USA

⁴Department of Veterinary Biology, Faculty of Veterinary Medicine, University of Zagreb, Croatia

⁵Ministry of Agriculture, Zagreb, Croatia

PAVIĆ, M., S. TKALČIĆ, L. PALMER, D. LEINER, M. POPOVIĆ, Z. BUDINŠČAK, D. ŠPOLJARIĆ, N. BRLEK, S. ĆURKOVIĆ: Anatomical landmarks for sciatic nerve access in pinnipeds. *Vet. arhiv* 90, 143-148, 2020.

ABSTRACT

General anesthesia in pinnipeds is considered to involve a prolonged recovery and is associated with serious risks caused by the activation of the dive reflex during anesthesia. Therefore, regional anesthesia may provide a potential solution to alleviate the associated risks of general anesthesia. The ventral branches of the lumbosacral nerves are involved in innervation of the lateral abdomen, pelvic musculature and the pelvic limb. The aim of this study was to investigate anatomical considerations for the appropriate injection site for administration of local anesthetics for a sciatic nerve (n. ischiadicus) block. In order to describe the nerves responsible for innervation of the pelvic limb, caudal portions of previously necropsied 10 California sea lions (*Zalophus californianus*) and 4 Northern elephant seals (*Mirounga angustirostris*) were dissected. The femorotibial joint was used as an orientation point in order to reach the sciatic nerve in both the California sea lions and the Northern elephant seals. It was shown that the sciatic nerve can be reached by positioning the needle in the center of an imaginary triangle between the femorotibial joint, the dorsal midline and the basis of the tail in California sea lions, and in Northern elephant seals by positioning the needle in the center of the line joining the femorotibial joint and the dorsal midline. Although previously not investigated or considered in practical pinniped medicine, these anatomical landmarks can provide useful guidelines for the potential development of regional anesthesia and analgesia techniques for surgical procedures involving the hind limbs, as an alternative to general anesthesia.

Key words: sciatic nerve; pinniped; regional anesthesia

Introduction

The order *Pinnipedia* is comprised of the *Odobenidae*, *Otariidae* and *Phocidae* families. Otariid and phocid seals have developed many adaptive physiological and anatomical features enabling them to inhabit both terrestrial and aquatic

environments (LYNCH and BODLEY, 2007). As semiaquatic animals, pinnipeds evolved adaptive modifications in their cardiovascular, respiratory and thermoregulatory systems, which can be a special problem during general anesthesia. The

*Corresponding author:

Mirela Pavić, DVM, PhD, Department of Anatomy, Histology and Embryology, Faculty of Veterinary Medicine, University of Zagreb, Heinzelova 55, 10000 Zagreb, Croatia, Phone: +385 1 2390 244; E-mail: mpavic@vef.hr

dive response is a set of cardiopulmonary reflexes characterized by apnea, bradycardia, peripheral vasoconstriction and redirecting of blood from peripheral muscular, cutaneous and splanchnic tissues to hypoxia-sensitive tissues, such as the brain and heart (STRINGER et al., 2012). Phocid seals have better physiological adaptations to an aquatic environment, which enable them to dive deeper and for a longer time than otariid seals. Apnea and the redirection of blood may lead to pooling of anesthetics in the brain, and consequently higher concentrations locally, that can lead to negative side effects from general anesthesia, and in extreme cases to lethal anesthetic concentrations in the brain (HAMMOND and ELSNER, 1977). The thick insulating layer of subcutaneous fat tissue represents an immense storage site for fat soluble general anesthetics, leading to their slow release from the fat, and prolonged post-anesthetic recovery (GALES, 1989). Otariid seals are more adept to a terrestrial environment. They do not dive as deep or for as long as phocid seals, and subsequently their anatomical and physiological adaptations for diving are not so distinct. Therefore, otariid seals are less sensitive to general anesthesia than phocid seals (HAULENA, 2007).

Thermoregulation disorders during general anesthesia are also more common in pinnipeds than in terrestrial animals. Most of the heat loss occurs when warm arterial blood perfuses the skin and flippers. Redirection of blood from peripheral tissues, as seen during general anesthesia, can lead to changes in deep body temperature. Phocid and otariid seals tend to develop hyperthermia rather than hypothermia during general anesthesia, due to their thick insulating subcutaneous fat layer (HAMMOND and ELSNER 1977; CROCKER, 2017).

Regional anesthesia, achieved by a peripheral nerve block, provides a site-specific access which reduces the use of general anesthesia, and consequently the potential side effects. Regardless of the benefits, regional anesthesia techniques are still underused in veterinary anesthetic protocols in companion animals (LEMKE and DAWSON, 2000; KLEIN et al., 2005). Even though the use of pelvic limb regional anesthesia has increased in veterinary practice, there is still no detailed

information regarding the usage in pinnipeds. The only two papers that describe the use of regional anesthesia via a nerve block technique in pinnipeds have been published in relation to Grey seals (*Halichoerus grypus*), where the authors achieved regional anesthesia via a mandibular nerve block using a technique used in dogs (HUUSKONEN et al., 2011), and California sea lions (GUTIÉRREZ et al., 2016), which is also the only paper describing the anatomical landmarks for performing regional anesthesia in pinnipeds. GUTIÉRREZ et al. (2016) described several anatomical approach techniques for retrobulbar and auriculopalpebral nerve blocks in California sea lions. Whereas several anatomic, experimental and clinical studies have been performed to develop regional anesthesia techniques and protocols for the pelvic limb of common companion animals (PORTELA et al., 2018; MAROLF et al., 2019), very few studies have investigated the anatomic properties and innervation of the pelvic limbs in pinnipeds (NAKANISHI et al., 1978; MIHELÍĆ et al., 2014). The majority of studies conducted on pinnipeds regarding anesthesia techniques and protocols are for sedation and general anesthesia (LYNCH et al., 1999; HAULENA, 2007; LAPIERRE et al., 2007; LYNCH and BODLEY, 2007; HESPEL et al., 2013; GARCÍA et al., 2015).

Since phocid and otariid seals are mostly wild animals, without any training, any manipulation, research, treatment or surgical procedure requires the use of drugs, either for sedation or general anesthesia. It is known that marine mammals are a particularly sensitive category for general anesthesia because of the documented complications that can occur. This is why the use of regional anesthesia via a nerve block should be assessed and become a more common practice in anesthetic protocols for marine mammals. The aim of this study was to describe the anatomical landmarks to assess the appropriate injection site for local anesthetic administration in a potential sciatic nerve block.

Materials and methods

The study was conducted on 10 (4 males and 6 females) California sea lion (*Zalophus californianus*) and 4 (3 males and 1 female) Northern elephant seal (*Mirounga angustirostris*) carcasses,

collected by and brought to the Marine Mammal Care Center, San Pedro, CA, USA where necropsy was performed. Following necropsy, caudal body segments were transected cranially to the last two ribs, stored at -30 °C and thawed as needed for dissection. This was performed at the Western University of Health Sciences, Pomona, CA, USA. The ventral branches of the lumbosacral plexus, particularly those responsible for innervation of the caudal parts of the body and hind limbs, were carefully dissected and recorded. Topographic anatomy landmarks for the appropriate injection site for the administration of a local anesthetic, were assessed by a 18G needle. The study protocol was approved by the National Oceanic and Atmospheric Administration, USA.

Results

The sciatic nerve is the strongest nerve formed by the ventral branches of the lumbosacral plexus. From a lateral view, after crossing the *incisura ischiadica major*, the pinnipeds' sciatic nerve divides into two main branches connected with smaller ones (Fig. 1).

The femorotibial joint was used as an orientation point in order to reach the sciatic nerve in both the California sea lions and the Northern elephant seals. Access to the sciatic nerve and its branches in the California sea lions was possible by piercing the center of an imaginary triangle determined by

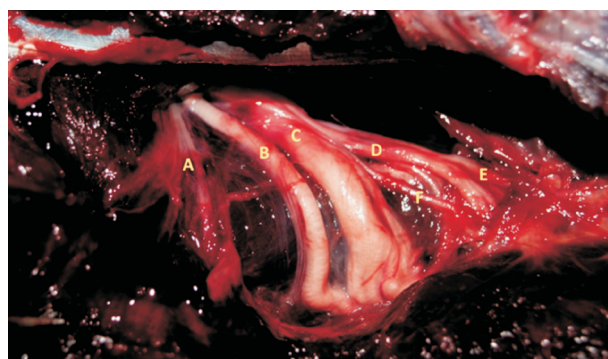


Fig. 1. Branches of the lumbosacral plexus accessible by needle in Northern elephant seals are the n. gluteus caudalis (A), the cranial branch of the sciatic nerve (B), the caudal branch of the sciatic nerve (C), the muscle branches of the sciatic nerve (D) and n. cutaneus femoris caudalis (E). The caudal gluteal artery (a. glutea caudalis) (F) lies next to the sciatic nerve.

tracing the lines between the femorotibial joint, the point on the dorsal midline, perpendicular to the femorotibial joint, and the base of the tail. The position of the needle should be in the same transversal plane, at half of the imaginary triangle's hypotenuse length (Fig. 2). The slightly caudoventral needle inclination needed for the needle position in California sea lions brings the needle to the immediate vicinity of the cranial and caudal branches of the sciatic nerve (Fig. 3).



Fig. 2. Anatomical landmarks for sciatic nerve access in California sea lions. The position of the needle (*) in the center of a triangle between the femorotibial joint (A), the dorsal midline (B) perpendicular to the femorotibial joint and the base of the tail (C).

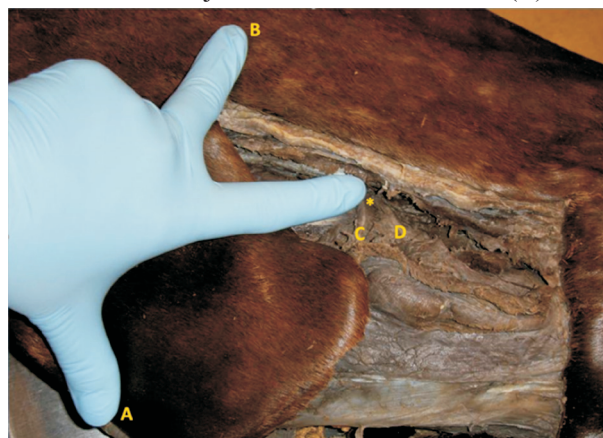

Fig. 3. Approximate distance of anatomical landmarks for sciatic nerve access in California sea lions. The position of the needle (*) in the center of a triangle between the femorotibial joint (A), the dorsal midline (B) perpendicular to the femorotibial joint and the base of the tail (not shown in this figure; shown on Fig. 2) is finger reachable. The injection site described (*) brings the needle into the immediate vicinity of the cranial branch (C) and the caudal branch (D) of the sciatic nerve.

Access to the sciatic nerve and its branches in Northern elephant seals was possible by positioning the piercing needle in the center of the line joining the femorotibial joint and the point on the dorsal midline, vertical to the femorotibial joint (Fig. 4). A 45 ° angle in a caudal direction was needed for the needle position in the Northern elephant seals.

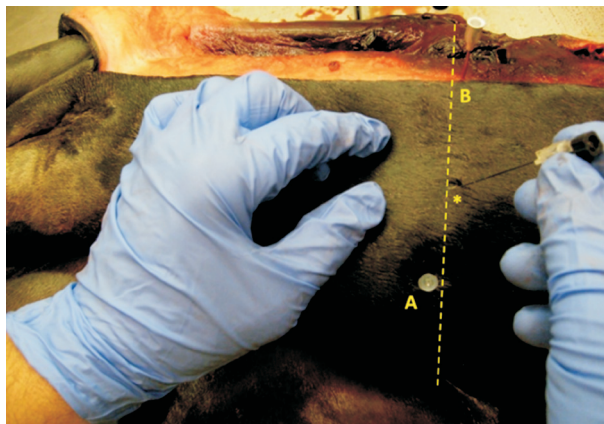


Fig. 4. Anatomical landmarks for sciatic nerve access in Northern elephant seals. The position of the needle (*) is in the center of the line between the femorotibial joint (A) and the point on the dorsal midline (B) vertical to the femorotibial joint.

Discussion

Many minor surgical procedures can be performed with a combination of physical restraint, sedation and local or regional anesthesia (HAMMOND and ELSNER, 1977; GALES, 1989). The motor and sensory fibres of the sciatic nerve innervate the lateral abdomen, pelvic musculature and pelvic limb. It is formed from the ventral branches of the lumbosacral plexus, and produces two main functional and anatomical parts: the common peroneal nerve (n. peroneus communis) and the tibial nerve (n. tibialis). Regional anesthesia via the sciatic nerve block provides quality analgesia distally to the middle thigh (KLEIN et al., 2005).

The pelvic limb in California sea lions and Northern elephant seals receives its motor, sensory and autonomic innervation from the lumbosacral plexus, which is formed by the ventral branches of the last three lumbar (L3, L4, L5) and three sacral (S1, S2, S3) nerves. The sciatic nerve in California sea lions is formed by ventral branches of the L5,

S1 and S2 nerves, with a variable contribution from L4. However, in Northern elephant seals the sciatic nerve is formed by ventral branches of the L4, L5 and S1, with a variable contribution from S2 (MIHELIC' et al., 2014). Contrarily to dogs, in Northern fur seals (*Callorhinus ursinus*) no division of the plexus into the lumbar and sacral part has been described, since the L5 nerve is connected to the S1 nerve by a strong branch (NAKANISHI et al., 1978). The lumbosacral plexus in dogs is formed by the intercommunicating ventral branches of the last five lumbar (L3, L4, L5, L6, L7) and the three sacral (S1, S2, S3) nerves (KITCHELL and EVANS, 1993; MIHELIC' et al., 1996). Similar to NAKANISHI et al. (1978), we did not find a common trunk of the sciatic nerve in California sea lions and Northern elephant seals, as seen in dogs, but two separate branches intercommunicating with smaller branches. The strong cranial branch of the sciatic nerve corresponds to the common peroneal nerve, while the stronger caudal branch corresponds to the tibial nerve.

Regional anesthesia in companion animals, via the sciatic block, can be achieved by a transgluteal or a lateral proximal thigh approach. (BRKIĆ et al., 1991; PORTELA et al., 2018). A modified transgluteal approach, the parasacral approach, has been well described in dogs, where the sciatic nerve can be accessed by positioning the needle in the center of a line connecting the tuber sacrale and tuber ischiadicum. The overall success in *in vivo* experiments with administration of local anesthetic at the described position was 86% which indicates that the parasacral approach is recommended for dogs (MAROLF et al., 2019).

Since the anatomy of the pinniped pelvic limb is different than in terrestrial animals, some differences in the anatomical landmarks for accessing the sciatic nerve should be considered. The pelvic limbs in California sea lions and Northern elephant seals extend beyond the body contours from the approximate middle or end of the crus. Thus, the femorotibial joint, as an easily locatable anatomical landmark, was used as an orientation point in order to reach the sciatic nerve in both California sea lions and Northern elephant seals. The thick insulating subcutaneous fat layer

specific for pinnipeds complicates the definition of other superficial anatomical landmarks that could be used for sciatic nerve access. Despite this, the lateral parts of the femorotibial joint, the epicondylus lateralis ossis femoris and condylus lateralis ossis tibiae, are easy to locate. In studies on companion and domestic animals (BRKIĆ et al., 1991; PORTELA et al., 2018; MAROLF et al., 2019) a quality sciatic nerve block was achieved by administering the local anesthetic in the immediate vicinity after the sciatic nerve crosses the incisura ischiadica major. The injection site described for California sea lions between the femorotibial joint, the dorsal midline and the basis of the tail, brings the needle into the immediate vicinity of the sciatic nerve. Half the distance between the femorotibial joint and the dorsal midline in Northern elephant seals could be similar to the lateral proximal thigh approach, described in dogs (PORTELA et al., 2018).

Conclusions

Rapid onset of apnea and thermoregulatory disturbance are the two main undesirable side effects of general anesthesia in pinnipeds. The development of a pinnipeds' sciatic nerve block by using the described anatomical landmarks in California sea lions and Northern elephant seals may provide quality anesthesia and analgesia of the pelvic limb, especially for regions distal to the knee joint. Although a relatively small number of carcasses was included in this study, these results establish a baseline for further refinement of anatomical landmarks for accessing the sciatic nerve, not only in California sea lions and Northern elephant seals, but also in other pinnipeds. Further investigations *in vivo* are required to confirm the efficiency of regional anesthesia via the sciatic nerve block using the described anatomical landmarks.

References

BRKIĆ, A., D. MIHELIĆ, K. BABIĆ, M. ZOBUNDŽIJA, V. GJURČEVIĆ KANTURA (1991): Possibility of the n. ischiadicus blockade in the foramen ischiadicum majus in horses. *Vet. arhiv* 61, 289-295.

CROCKER, D. E. (2017): Endocrinology. In: *CRC Handbook of Marine Mammal Medicine*, (Gulland, F. M. D., L. A.

Dierauf, K. L. Whitman, Eds.) CRC Press, Boca Raton, FL, USA, pp. 137-151.

GALES, N. J. (1989): Chemical restraint and anesthesia of pinnipeds: A review. *Mar. Mamm. Sci.* 5, 228-256.

GARCÍA, A. R., G. J. SÁNCHEZ CONTRERAS, C. J. ACOSTA, G. LACAVE, P. PRINS, K. MARCK (2015): Surgical treatment of osteoarthritis in Harbor seals (*Phoca vitulina*). *J. Zoo Wildl. Med.* 46, 553-559.
DOI: 10.1638/2014-0229.1

GUTIÉRREZ, J., C. A. SIMEONE, F. M. D. GULLAND, S. P. JOHNSON (2016): Development of retrobulbar and auriculopalpebral nerve blocks in California sea lions (*Zalophus californianus*). *J. Zoo Wildl. Med.* 47, 236-243.
DOI: 10.1638/2015-0035.1

HAMMOND, D., R. ELSNER (1977): Anesthesia in phocid seals. *J. Zoo Anim. Med.* 8, 7-13.

HAULENA, M. (2007): Otariid seals. In: *Zoo Animal and Wildlife Immobilization and Anesthesia* (West, G., D. J. Heard, N. Caulkett, Eds.) Blackwell Publishing, Ames, IA, USA, pp. 469-478.

HESPEL, A. M., F. BERNARD, N. J. DAVIES, V. HUUSKONEN, C. SKELLY, F. DAVID (2013): Surgical repair of a tibial fracture in a two-week-old grey seal (*Halichoerus grypus*). *Vet. Comp. Orthop. Traumatol.* 26, 82-87.
DOI: 10.3415/VCOT-12-01-0001

HUUSKONEN, V., L. HUGHES, R. BENNETT (2011): Anaesthesia of three young grey seals (*Halichoerus grypus*) for fracture repair. *Ir. Vet. J.* 64, 3.

KITCHELL, R. L., H. E. EVANS (1993): The spinal nerves. In: *Miller's Anatomy of the Dog*. (Evans, H. E., Ed.) Saunders Elsevier, Philadelphia, PA, USA, pp. 829-893.

KLEIN, S. M., H. EVANS, K. C. NIELSEN, M. S. TUCKER, D. S. WARNER, S. M. STEELE (2005): Peripheral nerve block techniques for ambulatory surgery. *Anesth. Analg.* 101, 1663-1676.

LAPIERRE, J. L., J. F. SCHREER, J. M. BURNS, M. O. HAMMILL (2007): Effect of diazepam on heart and respiratory rates of Harbor seal pups following intravenous injection. *Mar. Mamm. Sci.* 23, 209-217.

LEMKE, K. A., S. D. DAWSON (2000): Local and Regional Anesthesia. *Vet. Clin. North Am. Small Anim. Pract.* 30, 839-857.

LYNCH, M. J., K. BODLEY (2007): Phocid seals. In: *Zoo Animal and Wildlife Immobilization and Anesthesia* (West, G., D. J. Heard, N. Caulkett, Eds.) Blackwell Publishing, Ames, IA, USA, pp. 459-468.

LYNCH, M. J., M. A. TAHMINDJIS, H. GARDNER (1999): Immobilisation of pinniped species. *Aust. Vet. J.* 77, 181-185.
DOI: 10.1111/j.1751-0813.1999.tb11231.x

MAROLF, V., H. ROHRBACH, G. BOLEN, A. VAN WIJNSBERGHE, C. SANDERSEN (2019): Sciatic nerve

- block in dogs: description and evaluation of a modified ultrasound-guided parasacral approach. *Vet. Anaesth. Analg.* 46, 106-115.
DOI: 10.1016/j.vaa.2018.10.003
- MIHELIC, D., H. SMODLAKA, S. TKALČIĆ, L. PALMER, G. MRŠIĆ, K. ŠPIRANEC, D. ŠPOLJARIĆ, M. POPOVIĆ, D. MIHELIC (2014): Creation nerves of the lumbar and sacral plexus in California sea lions (*Zalophus californianus*) and Northern elephant seals (*Mirounga angustirostris*). *Acta Vet. (Beograd)* 64, 293-306.
DOI: 10.2478/acve-2014-0028
- MIHELIC, D., M. ZOBUNDŽIJA, K. BABIĆ, V. GJURČEVIĆ KANTURA, P. DŽAJA, M. GERESŠ, G. BAČIĆ, Z. HINCAK (1996): Variation concerning the formation of femoral, obturator and ischiatic nerves in dog. *Vet. arhiv* 66, 51-60.
- NAKANISHI, T., M. YAMAMOTO, Y. SUENAGA (1978): Comparative anatomical studies on the nerves and muscles of the posterior limb of the northern fur seal and cat. *Okajimas Folia Anat. Jpn.* 54, 317-339.
- PORTELA, D. A., N. VERDIER, P. E. OTERO (2018): Regional anesthetic techniques for the pelvic limb and abdominal wall in small animals: A review of the literature and technique description. *Vet. J.* 238, 27-40.
DOI: 10.1016/j.tvjl.2018.07.003.
- STRINGER, E. M., W. VAN BONN, S. K. CHINNADURAI, F. M. D. GULLAND (2012): Risk factors associated with perianesthetic mortality of stranded free-ranging California sea lions (*Zalophus californianus*) undergoing rehabilitation. *J. Zoo Wildl. Med.* 43, 233-239.
DOI: 10.1638/2010-0148.1

Received: 11 March 2019

Accepted: 30 April 2019

PAVIĆ, M., S. TKALČIĆ, L. PALMER, D. LEINER, M. POPOVIĆ, Z. BUDINŠČAK, D. ŠPOLJARIĆ, N. BRLEK, S. ČURKOVIĆ: Anatomiska obilježja za pristup živcu n. ischiadicus kod perajara. *Vet. arhiv* 90, 143-148, 2020.

SAŽETAK

Opća anestezija perajara (*Pinnipedia*) povezana je s produljenim poslijeoperacijskim oporavkom i rizicima uzrokovanim aktivacijom ronilačkog refleksa tijekom anestezije. Stoga provodna anestezija može pružiti moguće rješenje za ublažavanje rizika povezanih s općom anestezijom. Ventralne grane lumbosakralnih živaca uključene su u inervaciju lateralne trbušne stijenke, zdjelične muskulature i zdjeličnog uda. Kaudalni dijelovi 10 kalifornijskih morskih lavova (*Zalophus californianus*) i 4 sjeverna morska slona (*Mirounga angustirostris*) secirani su kako bi se proučili živci odgovorni za inervaciju zdjeličnog uda. Cilj ovoga istraživanja bio je odrediti anatomska obilježja za pristup živcu n. ischiadicus za primjenu lokalnih anestetika za provodnu anesteziju. Femoro-tibijalni zglob korišten je kao orijentacijska točka kako bi se došlo do živca n. ischiadicus u kalifornijskoga morskog lava i sjevernoga morskog slona. Pristup živcu n. ischiadicus može se postići postavljanjem igle u središte zamišljenog trokuta između femoro-tibijalnoga zgloba, dorzalne medijane linije i osnove repa kod kalifornijskih morskih lavova, dok se kod sjevernih morskih slonova igla postavlja u sredinu pravca koji spaja femoro-tibijalni zglob i dorzalnu medijanu liniju. Iako literatura ne navodi istraživanja ili praktičnu primjenu provodne anestezije postignute blokom živca n. ischiadicus, opisana anatomska obilježja mogu pružiti korisne smjernice za primjenu provodne anestezije pri kirurškim zahvatima na zdjeličnom udu, kao alternativa općoj anesteziji.

Ključne riječi: n. ischiadicus; perajari; provodna anestezija
