

The comparative practical efficiency of short-term electrocardiography and 24-hour Holter monitoring for evaluating the cardiac electrical activity of horses

Mohammad Mazrouei Sebdani, Ali Rezakhani*, Mehrdad Pourjafar, and Aliasghar Chalmeh

Department of Clinical Sciences, School of Veterinary Medicine, Shiraz University, Shiraz, Iran

MAZROUEI SEBDANI, M., A. REZAKHANI, M. POURJAFAR, A. CHALMEH: The comparative practical efficiency of short-term electrocardiography and 24-hour Holter monitoring for evaluating the cardiac electrical activity of horses. Vet. arhiv 89, 267-277, 2019.

ABSTRACT

Assessing equine cardiac electrical activities is essential during a clinical examination of the cardiovascular system. The aim of the present study was to evaluate this activity by two methods to find the more reliable technique in this regard. Hence, standard electrocardiography (for 30 minutes) and Holter monitoring (for 24 hours) were recorded in 20 adult clinically healthy horses. Various parameters of the recorded waves, such as P-R, Q-T and R-R intervals, S-T and P-R segments, P, R, S, and T amplitudes and heart rate, were evaluated. The presence of various arrhythmias was also assessed. All the parameters studied by Holter monitoring were significantly different from standard electrocardiography, except P-R and Q-T intervals and heart rate. Sinus arrhythmia and first and second degree atrioventricular blocks were detected by both methods, but a sino-atrial block was present on Holter monitoring. Furthermore, the distribution of cardiac arrhythmias in Holter monitoring was greater than with standard electrocardiography. On the basis of the results of the current research, prolonged Holter monitoring may be considered to be the more reliable method to evaluate the cardiac electrical activity of horses.

Key words: short-term electrocardiography; 24-hours holter monitoring; cardiac electrical activity; horse

Introduction

Cardiac activities include electrical and mechanical functions, and the proper functioning of the heart's mechanical activity depends on the accuracy of its electrical performance (CONSTABLE et al., 2017). Considering the importance of the heart's electrical function, the use of methods to assess this activity is clinically essential.

*Corresponding author:

Ali Rezakhani, Department of Clinical Sciences, School of Veterinary Medicine, Shiraz University, Shiraz, P.O. box: 71345, Iran, Phone: +98 713 613 8710; Fax: +98 713 228 6940; E-mail: a.rezakhani@ias.ac.ir

Hence, researchers have applied electrocardiography, using various leads, as an efficient method in this evaluation, but the base-apex lead has been suggested for large animal electrocardiography (ALIDADI et al., 2002; SCHEER et al., 2010; VERHEYEN et al., 2010; PETERSEN, 2015). The characteristics of this lead are that it is easy to handle and animal movements have the least negative effect on the recorded waves (REZAKHANI et al., 2010). The base-apex lead system, like other leads in electrocardiography, can be used for diagnosis of cardiovascular diseases which are not detectable by clinical examination (VERHEYEN, et al., 2010). Alongside the benefits of electrocardiography, there are some disadvantages, such as the lack of detection of the heart's electrical problems, during short term recordings. In addition, this method is not suitable for long-term monitoring of patients' hearts (BAKOS and LUISE, 2009). On the other hand, long-term attachment of electrocardiograph clips to the skin may cause pressure and stimulate the sensation of pain, which causes problems in continuous and prolonged ECG recordings (DECLOEDT et al., 2015; SUZUKI et al., 1998).

The use of a method to reduce the disadvantages of standard electrocardiography was necessary, and accordingly, use of the Holter monitor in modern cardiology has been suggested as a stress-free technique to evaluate long-term cardiac electrical activities (KUWAHARA et al., 2004). Holter monitoring is a non-invasive, inexpensive and efficient method to evaluate long-term cardiac electrical activities by using electrodes attached to the chest. The number and location of these electrodes varies depending on the type and model of the device, but most of them have between 3 and 8 electrodes. This device is portable and contains hardware (for viewing, controlling and recording signals) and software (for review and processing of recorded information) (HIRAGA and SUGANO, 2015).

On the basis of these advantages and disadvantages of electrocardiography and Holter monitoring to evaluate cardiac electrical activities, and the necessity and importance of monitoring the equine heart, the present study evaluated the cardiac electrical activity of 20 clinically healthy horses, using short-term electrocardiography compared to prolonged Holter monitoring, simultaneously. Regarding the evaluation of electrical activity of the heart in both methods, comparison of the parameters recorded by each of them may indicate their reliability in assessing the cardiac electrical performance of horses.

Materials and methods

Animals. This study was performed on 20 adult horses (16 stallions and 4 mares), reared around Shiraz, in southwest Iran. The horses were aged between 2 to 15 years old, clinically healthy and without any history of severe or debilitating diseases. All the horses were at rest and, at the time of the research, were far from intense physical training and

racing activities. All the horses were evaluated immediately before the study began, and their clinical health was confirmed.

Electrocardiography. Initially, electrocardiograms were taken for 30 minutes from all of the studied horses with a base-apex lead system (25 mm/second; 10 mm/mV; Kenz-line EKG 110, Suzuken Co., Ltd., Japan). Before attaching the electrodes to the skin, the sites were prepared with alcohol and an electrocardiogram jelly. In all horses, the positive electrode (left arm) was attached to the apex of the heart between the fifth or sixth intercostal space along the left olecranon, the negative electrode (right arm) on the jugular furrow at the top of the heart base, and the neutral electrode was placed along the spine at a location far from the heart (CONSTABLE et al., 2017).

Holter monitoring. After receiving the electrocardiogram, the horse was at rest for 30 minutes, then 4 points of the horse's body were washed with alcohol, and the electrodes of the Holter monitor (Cardio Rhythm, ACT® Eng. Co. Ltd., Tehran, Iran) were attached for a continuous 24 hour recording (25 mm/sec; 10 mm/mV). A positive electrode was attached to the apex of the heart between the fifth to sixth intercostal space near the left olecranon, another positive electrode was attached to the jugular furrow at the top of the heart base, the negative electrode was attached to the left side of the chest near the spine, and the earth electrode was placed in the lower left half of the chest, aligned with the negative electrode (ZUCCA et al., 2003). All electrodes were attached to the skin by lead lock ECG electrodes, purchased from Medico Electrodes Company, India. After 24 hours, the Holter monitor was separated from the horse and the data recorded by the software analyzed.

Evaluating the cardiac electrical activities. After recording the cardiac electrical activities by both devices, various parameters of the recorded waves were evaluated, such as P-R, Q-T and R-R intervals, S-T and P-R segments, P, R, S, and T amplitudes and heart rate. The presence of arrhythmias was also assessed.

Statistical data analysis. The normality of the data was evaluated based on the results of the Kolmogorov-Smirnov test. The results of this test showed that all data were normally distributed. Data were presented as the mean \pm standard deviation (SD). Comparison of the mean of similar parameters recorded by the two different devices was performed by two independent samples *t*-test. The trend changes of each recorded parameter by electrocardiogram (within 30 minutes) and Holter monitor (during 24 hours) were evaluated by Repeated Measures ANOVA. All statistical tests were performed by SPSS software, version 21 and the level of significance was considered $P < 0.05$.

Results

The mean \pm SD of all studied parameters by standard electrocardiography and Holter monitoring and their comparison with each other are presented in Table 1. Q-T

and R-R intervals, as well as heart rate showed no significant difference between the two recording methods ($P>0.05$; Table 1). The P-R interval and P-R segment on 24-hour Holter monitoring were significantly lower than with short-term electrocardiography ($P<0.05$). The S-T segment and all amplitudes in the Holter monitoring were significantly greater than standard electrocardiography ($P<0.05$; Table 1).

Table 1. Different characteristics (mean \pm SD) of normal cardiac electrical activities of clinically healthy adult horses (n = 20) recorded by short-term electrocardiography in comparison with prolonged Holter monitoring

Parameters	Electrocardiography	Holter monitoring	P-value
P-R interval (S)	0.33 \pm 0.01	0.32 \pm 0.01	0.044*
R-R interval (S)	1.85 \pm 0.05	1.86 \pm 0.13	0.883
Q-T interval (S)	0.58 \pm 0.01	0.58 \pm 0.01	0.629
P-R segment (S)	0.19 \pm 0.01	0.17 \pm 0.01	0.001*
S-T segment (S)	0.24 \pm 0.01	0.27 \pm 0.01	0.001*
P amplitude (mV)	0.15 \pm 0.01	0.16 \pm 0.01	0.001*
R amplitude (mV)	1.06 \pm 0.01	1.11 \pm 0.02	0.006*
S amplitude (mV)	1.08 \pm 0.01	1.57 \pm 0.04	0.001*
T amplitude (mV)	0.58 \pm 0.02	0.77 \pm 0.05	0.001*
P duration (S)	0.16 \pm 0.01	0.18 \pm 0.01	0.002*
QRS duration (S)	0.20 \pm 0.02	0.24 \pm 0.03	0.005*
T duration (S)	0.24 \pm 0.02	0.25 \pm 0.02	0.002*
Heart rate (beats/min)	32.38 \pm 0.90	32.32 \pm 2.26	0.959

Statistical differences between two recording methods for each parameter are presented and significance values are indicated by a star ($P<0.05$).

The trend changes in all recorded parameters by standard electrocardiography and Holter monitoring are presented in Figs 1 to 3. All recorded intervals by both methods changed significantly during the study ($P<0.05$; Fig. 1). The P-R segment in electrocardiography did not change significantly but it was significant in Holter monitoring; alterations to the S-T segment were significant in both methods (Fig. 2). The alterations in the amplitudes recorded by each of the two methods were significant during the study ($P<0.05$; Fig. 3). Changing patterns of heart rate were also significant in both methods ($P<0.05$). The results of the Holter monitoring findings showed that P-R and R-R intervals were significantly increased during the study, which markedly increased from hour 08:00 to hour 05:00 ($P<0.05$; Fig. 1).

The distribution of the various arrhythmias recorded in this study is shown in Tables 2 and 3 and Fig. 4. The results showed that 2 of the horses studied had sino-atrial block in the Holter monitoring, recorded at 02:00. Two of them also had first degree atrioventricular block at minute 20 in electrocardiography, and 02:00 in Holter monitoring (Fig. 4B). Two of the horses showed second degree atrioventricular block recorded by Holter monitoring

at 02:00, and this arrhythmia was also detected in another horse by both methods during the study (Fig. 4B). Furthermore, sinus arrhythmia was detected by both methods in all the studied horses (Fig. 4A).

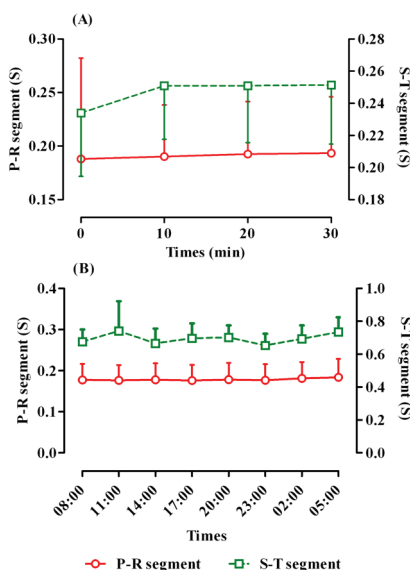
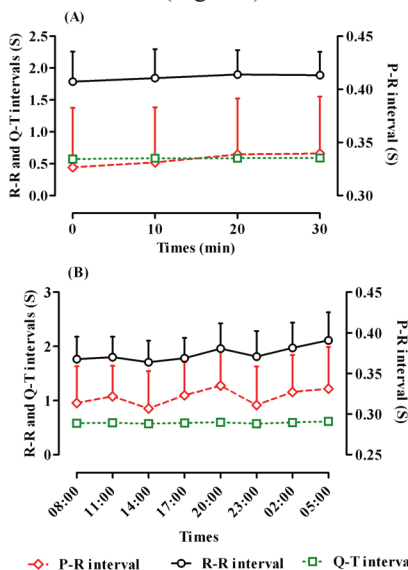


Fig. 1. P-R, R-R and Q-T intervals (mean \pm SD; Sec) recorded by 30-minute electrocardiography (A) in comparison with 24-hour Holter monitoring (B), (25 mm/sec; 10 mm/mV).
 Fig. 2. P-R and S-T segments (mean \pm SD; Sec) recorded by 30-minute electrocardiography (A) in comparison with 24-hour Holter monitoring (B), (25 mm/sec; 10 mm/mV).

Table 2. Type and distribution of cardiac arrhythmias in clinically healthy adult horses (n = 20) recorded by prolonged Holter monitoring during the study period

Arrhythmia	Hours							
	08:00	11:00	14:00	17:00	20:00	23:00	02:00	05:00
SAB	---	---	---	---	---	---	2/20	---
AVB-I	---	---	---	---	---	---	2/20	---
AVB-II	1/20	1/20	1/20	1/20	1/20	1/20	3/20	1/20
SA	20/20	20/20	20/20	20/20	20/20	20/20	20/20	20/20

SAB: sino-atrial block; AVB-I: first degree atrio-ventricular block; AVB-II: second degree atrio-ventricular block; SA: sinus arrhythmia

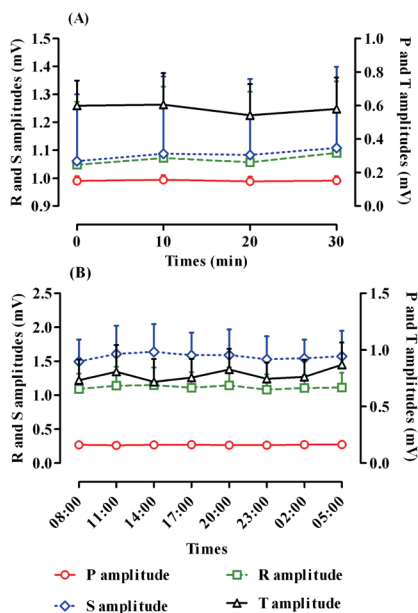


Fig. 3. P, R, S and T amplitudes (mean \pm SD; mV) recorded by 30-minute electrocardiography (A) in comparison with 24-hour Holter monitoring (B), (25 mm/sec; 10 mm/mV).

Table 3. Type and distribution of cardiac arrhythmias in clinically healthy adult horses (n = 20) recorded by short-term electrocardiography during the study period

Arrhythmia	Time (min)			
	0	10	20	30
SAB	---	---	---	---
AVB-I	---	---	2/20	---
AVB-II	1/20	1/20	1/20	1/20
SA	20/20	20/20	20/20	20/20

SAB: sino-atrial block; AVB-I: first degree atrio-ventricular block; AVB-II: second degree atrio-ventricular block; SA: sinus arrhythmia

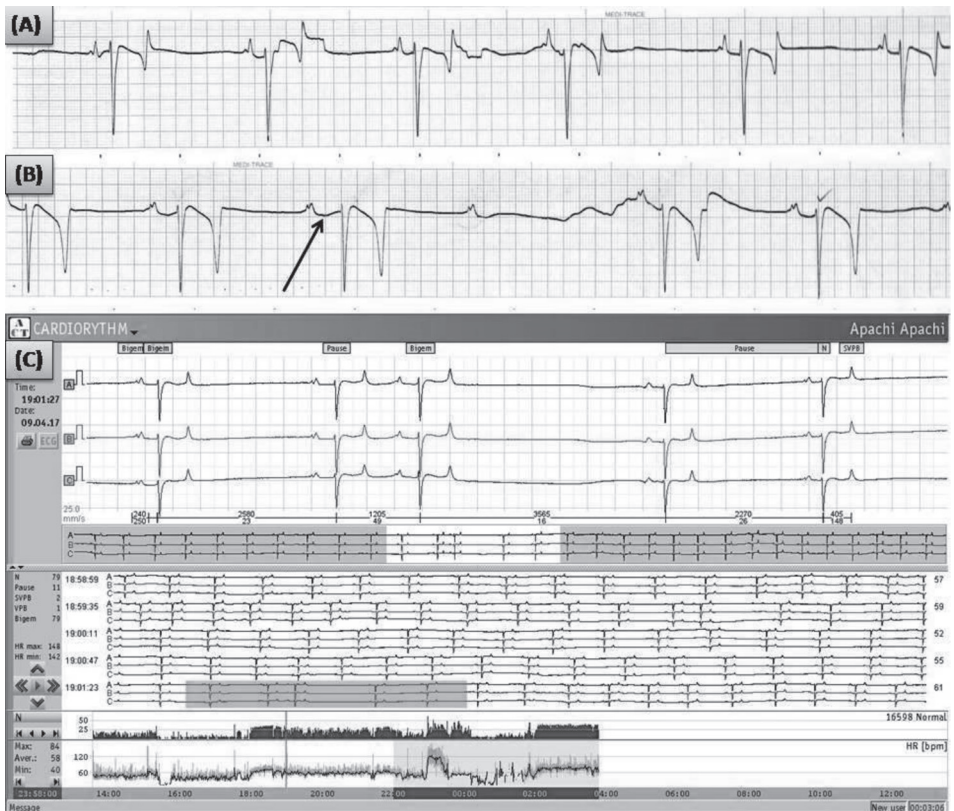


Fig. 4. Arrhythmias recorded by 30-minute electrocardiography (A and B) and 24-hour Holter monitoring (C), (25 mm/sec; 10 mm/mV). A: sinus arrhythmia; B: first (arrow) and second degree atrio-ventricular blocks; C: sinus arrhythmia.

Discussion

Evaluating the cardiac electrical activity of horses is clinically necessary, and using an effective and accurate method to examine this activity is essential. Electrocardiography is considered as the method of choice for this evaluation, but we hypothesized that some normal and abnormal cardiac electrical activities may not be detectable by short-term electrocardiography and the examination should last longer. Therefore, this study was performed to compare short-term electrocardiography and prolonged Holter monitoring to obtain the most reliable technique in evaluating cardiac electrical activity of horses. The results of the present study may lead veterinarians and researchers to use the best method in assessing the electrical activity of horses' heart.

According to the findings of the current research, the parameters recorded by 24-hour Holter monitoring were significantly different from short-term electrocardiography (Table 1), and the circadian physiological changes in the horse's body during the study may be considered as a reason for these findings. On the other hand, recording short-term electrocardiography may be considered a stressful procedure in comparison with prolonged Holter monitoring and the stressful conditions may affect the recorded parameters. Some recorded parameters and waves were lower by Holter monitoring and others were higher than in electrocardiography. The PR interval and segment reveal the duration of the conduction period of waves from the atria to the ventricles. Continuous 24 hour study of cardiac electrical activity contains high and low conduction periods during the course of the day, and the data presented in Table 1 are the averages of a large volume of data recorded by Holter monitoring. Based on the restless of the studied horses and the continuous 24 hour evaluations, it may be suggested that data from the Holter monitoring for all the recorded parameters are more reliable than short term electrocardiography.

ZUCCA et al. (2003) evaluated the cardiac electrical activity of horses by Holter monitoring while they were running on a treadmill, and they suggested that Holter monitoring could be considered as a method to be applied in this way. One-hour Holter monitoring performed by BAKOS and LOUISE (2009) on 20 healthy horses at rest, revealed significant differences between some of the parameters in the studied horses. GUCCIONE et al. (2014) recorded the cardiac electrical activity of 15 donkeys by 24-hour Holter monitoring, and the highest values of P-R and R-R intervals were detected in the early hours of the morning (between 01:00 to 03:00) when the animals were asleep or resting. They suggested that their findings may be due to low environmental stress and high vagal tone. In the present study, P-R and R-R intervals recorded by Holter monitoring significantly increased from hour 08:00 to the next 05:00 which led to different heart rates during the study period; it may be suggested that these alterations may be due to the normal balance of the autonomic nervous system (GUCCIONE et al., 2014).

The assessment of the heart rhythm in the studied horses demonstrated that the distribution and diversity of cardiac arrhythmias recorded by the two methods were different. In two studied horses, sino-atrial block was recorded only by Holter monitoring at 02:00 when the animals were at rest (Table 2). Furthermore, the highest distribution of detected cardiac arrhythmias was observed at this time (Table 2), which may be due to the higher tonicity of the vagus nerve during resting periods (GUCCIONE et al., 2014). Sinus arrhythmia was detected by both methods in all horses (Tables 2 and 3). The literature mentions that sinus arrhythmia is the most common physiological arrhythmia in large animals (HESSELKILDE et al., 2014; CONSTABLE et al., 2017) which is consistent with our results.

HESSELKILDE et al. (2014) evaluated the prevalence of various arrhythmias in horses affected by colic, in comparison with healthy ones. They found atrioventricular block and premature atrial and ventricular beats in diseased horses. In their study, sinus arrhythmia, second degree atrioventricular block and sino-atrial block were observed in clinically normal horses. They suggested that the presence of physiological arrhythmias in normal horses may be related to fluctuations in autonomic tone or increasing vagal nerve tonicity. REZAKHANI et al. (2010) studied the prevalence of cardiac arrhythmias recorded by 24-hour Holter monitoring in ponies. They found sinus arrhythmia, sinoatrial block, atrioventricular block II, and premature atrial and ventricular beats in the studied ponies. In a study by RAEKALLIO (1992), prolonged Holter monitoring was undertaken in 9 healthy horses overnight. They detected atrioventricular blocks and sinus arrhythmia during the study. BARBESGAARD et al. (2010) evaluated cardiac arrhythmias in 21 healthy horses during and after exercise by electrocardiography, and found premature atrial and ventricular beats. Some researchers mentioned that the prevalence of cardiac arrhythmias detected by prolonged Holter monitoring was greater than in short-term electrocardiography in the same horses (REEF, 1999; REZAKHANI et al., 2010) and their findings are consistent with our results, which showed that some arrhythmias were only detected by 24-hour Holter monitoring, in comparison with short-term electrocardiography (Tables 2 and 3).

Conclusion

On the basis of these findings, there were significant differences in horse cardiac electrical activities recorded by short-term electrocardiography in comparison with 24-hour Holter monitoring. Furthermore, prolonged Holter monitoring may be considered as a more reliable method to evaluate cardiac electrical activity. On the other hand, the type and distribution of cardiac arrhythmias detected by 24-hour Holter monitoring was different from short-term electrocardiography, and some arrhythmias were only recorded by prolonged cardiac rhythm evaluations. Finally, it seems that using 24-hour Holter monitoring is preferred to short-term electrocardiography to assess cardiac electrical activities in normal horses.

Acknowledgements

The authors would like to thank the trainer, Mr. Mahdi Zolfaghari, and the manager of the Melal Racing Horse Club for their help and allowing us to use the horses kept at this club.

M. Mazrouei Sebdani et al.: The comparative practical efficiency of short-term electrocardiography and 24-hour Holter monitoring for evaluating the cardiac electrical activity of horses

References

- ALIDADI, N., M. MOKHBERDEZFOULI, M. G. NADALIAN, A. REZAKHANI, I. NOUROOZIAN (2002): The ECG of the Turkman horse using the standard lead base apex. *J. Equine Vet. Sci.* 2, 182-184.
DOI: 10.1053/jevs.2002.34297
- BAKOS, Z., L. LOUISE (2009): Reference values of Holter electrocardiography in normal horses. *West Indian Vet. J.* 9, 3-7.
- BARBESGAARD, L., R. BUHL, C. MELDGAARD (2010): Prevalence of exercise-associated arrhythmias in normal performing dressage horses. *Equine Vet. J.* 42, 202-207.
DOI: 10.1111/j.2042-3306.2010.00223.x
- CONSTABLE, P. D., K. W. HINCHCLIFF, S. H. DONE, W. GRUNBERG (2017): *Veterinary Medicine: A Textbook of the Disease of Cattle, Horses, Sheep, Pigs, and Goats.* 11th ed., Elsevier, St. Louis.
- DECLOEDT, A., C. C. SCHWARZWALD, D. DE CLERCQ, N. VAN DER VEKENS, B. PARDON, V. B. REEF, G. VAN LOON (2015): Risk factors for recurrence of atrial fibrillation in horses after cardioversion to sinus rhythm. *J. Vet. Intern. Med.* 29, 946-953.
DOI: 10.1111/jvim.12606
- GUCCIONE, J., D. PIANTEDOSI, A. DI LORIA, V. VENEZIANO, P. CIARAMELLA (2014): Long-term electrocardiography recording with holter monitoring in 15 donkeys. *J. Equine Vet. Sci.* 34, 302-306.
DOI: 10.1016/j.jevs.2013.07.001
- HESSELKILDE, E., M. ALMIND, J. PETERSEN, M. FLETHOJ, K. PRAESTEGAARD, R. BUHL (2014): Cardiac arrhythmias and electrolyte disturbances in colic horses. *Acta Vet. Scand.* 56, 58.
DOI: 10.1186/s13028-014-0058-y
- HIRAGA, A., S. SUGANO (2015): History of research in Japan on electrocardiography in the racehorse. *J. Equine Sci.* 26, 1-13.
- KUWAHARA, M., Y. TSUJINO, H. TSUBONE, E. KUMAGAI, H. TSUTSUMI, M. TANIGAWA (2004): Effects of pair Housing on diurnal rhythms of heart rate and heart rate variability in miniatures Swine. *Exp. Anim.* 53, 303-309.
DOI: 10.1538/expanim.53.303
- PETERSEN, B. V. (2015): 12-Lead ECG for Horses. Master's Thesis, University of Copenhagen Faculty of Health and Medical Sciences, Copenhagen, Denmark.
- RAEKALLIO, M. (1992): Long-term ECG recording with Holter monitoring in clinically healthy horses. *Acta Vet. Scand.* 33, 71-75.
- REEF, V. B. (1999): Arrhythmias. In: *Cardiology of the Horse.* (Marr, C. M., Ed.), 1st ed., W. B. Saunders Co, London, p. 181.

M. Mazrouei Sebdani et al.: The comparative practical efficiency of short-term electrocardiography and 24-hour Holter monitoring for evaluating the cardiac electrical activity of horses

REZAKHANI, A., S. PIRIE, K. J. BLISSITT (2010): Effects of age on the prevalence of cardiac dysrhythmias in ponies. *Iran J. Vet. Res.* 11, 200-205.

SCHEER, P., P. SVOBODA, M. SEPSI, K. JANEČKOVÁ, J. DOUBEK (2010): The Electrocardiographic holter monitoring in experimental veterinary practice. *Physiol. Res.* 59, 59-64.

SUZUKI, A., H. TSUTSUMI, K. KUSAKABE, M. KUWAHARA, S. SUGANO, M. TANIGAWA (1998): Establishment of a 24-hour electrocardiogram recording system using a Holter recorder for miniature swine. *Lab. Anim.* 32, 165-172.

DOI: 10.1258/002367798780599938

VERHEYEN, T., A. DECLOEDT, D. DE CLERCQ, P. DEPREZ, S. SYS, G. VAN LOON (2010): Electrocardiography in horses - part 2: how to read the equine ECG. *Vlaams Diergeneesk. Tijdschr.* 79, 337-344.

DOI: 10.1111/j.2042-3306.2011.00526.x

ZUCCA, E., F. FERRUCCI, V. DI FABIO, C. CROCI, E. FERRO (2003): The use of electrocardiographic recording with holter monitoring during treadmill exercise to evaluate cardiac arrhythmias in racehorses. *Vet. Res. Commun.* 27, 811-814.

DOI: 10.1023/b:verc.0000014278.44422.9d

Received: 13 January 2018

Accepted: 20 December 2018

MAZROUEI SEBDANI, M., A. REZAKHANI, M. POURJAFAR, A. CHALMEH: Usporedba srčane električne aktivnosti konja praćene kratkotrajnom elektrokardiografijom i 24-satnim holterom. *Vet. arhiv* 89, 267-277, 2019.

SAŽETAK

Procjena srčane električne aktivnosti u konja ključna je u kliničkom pregledu kardiovaskularnog sustava. Cilj ovoga istraživanja bio je usporediti pouzdanost dviju metoda pri praćenju različitih pokazatelja srčane električne aktivnosti. U 20 odraslih, klinički zdravih konja učinjena je standardna elektrokardiografija tijekom 30 minuta i 24-satno praćenje holterom. Procjenjivani su različiti pokazatelji zabilježenih valova kao što su P-R, Q-T i R-R intervali, S-T i P-R segmenti, P, R, S i T-amplitude te srčani otkucaji. Utvrđena je i prisutnost različitih aritmija. Sve vrijednosti dobivene praćenjem holterom znakovito su se razlikovale od onih dobivenih standardnom elektrokardiografijom, osim P-R i Q-T intervala te srčanih otkucaja. Sinusna aritmija te prvi i drugi stupanj atrioventrikularnog bloka otkriveni su objema metodama, no sinusno-atrijski blok utvrđen je samo pri praćenju holterom. Osim toga više je srčanih aritmija otkriveno holterom nego standardnom elektrokardiografijom. Na temelju rezultata novijih istraživanja produljeno praćenje holterom moglo bi se smatrati pouzdanijom metodom u procjeni srčane električne aktivnosti konja.

Ključne riječi: kratkotrajni EKG; 24-satno praćenje holterom; srčana električna aktivnost; konji
