

**New data on *Eimeria dicentrarchi* (Apicomplexa: Eimeriidae),  
a common parasite of farmed European sea bass  
(*Dicentrarchus labrax*) from the mid-eastern Adriatic**

**Emil Gjurčević<sup>1\*</sup>, Snježana Kužir<sup>2</sup>, Branimir Baždarić<sup>3</sup>,  
Krešimir Matanović<sup>1</sup>, Iris Debelić<sup>4</sup>, Fabio Marino<sup>5</sup>, Krešimir Drašner<sup>6</sup>,  
and Benjamin M. Rosenthal<sup>7</sup>**

<sup>1</sup>Department for Biology and Pathology of Fish and Bees, Faculty of Veterinary Medicine, University of Zagreb, Zagreb, Croatia

<sup>2</sup>Department of Anatomy, Histology and Embryology, Faculty of Veterinary Medicine, University of Zagreb, Zagreb, Croatia

<sup>3</sup>Zadar County Rural Development Agency, Zadar, Croatia

<sup>4</sup>Faculty of Veterinary Medicine, University of Zagreb, Croatia

<sup>5</sup>Department of Veterinary Sciences, Centro di Ittiopatologia Sperimentale della Sicilia, University of Messina, Messina, Italy

<sup>6</sup>Fish Farm IHOR PARK, Jastrebarsko, Croatia

<sup>7</sup>Animal Parasitic Disease Laboratory, Beltsville Agricultural Research Center, Beltsville, United States

---

**GJURČEVIĆ, E., S. KUŽIR, B. BAŽDARIĆ, K. MATANOVIĆ, I. DEBELIĆ, F. MARINO, K. DRAŠNER, B. M. ROSENTHAL: New data on *Eimeria dicentrarchi* (Apicomplexa: Eimeriidae), a common parasite of farmed European sea bass (*Dicentrarchus labrax*) from the mid-eastern Adriatic. Vet. arhiv 87, 77-86, 2017.**

**ABSTRACT**

This study extends the original description of *Eimeria dicentrarchi* Daoudi and Marquès, 1987, a common coccidian parasite of European sea bass from the mid-eastern Adriatic, by providing insights into the parasite's site of infection, development and pathogenicity. *E. dicentrarchi* was found in various developmental stages in most segments, mainly anterior, of the digestive tract. In infected segments of the digestive tract, merogonic and gamogonic stages were located in the enterocyte cytoplasm, whereas sporogonic stages were situated in the epithelium and occasionally beneath it, in the lamina propria. Most oocysts in the lumen of the digestive tract were completely sporulated, indicating endogenous sporulation. *E. dicentrarchi* infection caused localised histopathological changes, restricted primarily to individual epithelial cells. Additionally, the results of our preliminary study suggest that oral administration of potentiated sulphonamide Trimetosul® (trimethoprim-sulfadiazine) may be effective against *E. dicentrarchi* infection.

**Key words:** *Eimeria dicentrarchi*, European sea bass, development, pathogenicity, treatment

---

\*Corresponding author:

Emil Gjurčević PhD, Department for Biology and Pathology of Fish and Bees, Faculty of Veterinary Medicine, University of Zagreb, Heinzelova 55, 10 000 Zagreb, Croatia, Phone: +385 1 2390 152; Fax: +385 1 2441 390; E-mail: egjurcevic@vef.hr

## Introduction

So far only two coccidia of the genus *Eimeria* Schneider, 1875 have been reported in European sea bass (*Dicentrarchus labrax*), namely *Eimeria dicentrarchi* Daoudi and Marquès, 1987 and *E. bouixi* Daoudi and Marquès, 1987. Originally, *E. dicentrarchi* was described by DAOUDI and MARQUÈS (1987) as a species that develops in the pyloric caeca epithelium. Following the first report in France, *E. dicentrarchi* has been reported in several other Mediterranean countries, in both wild and farmed European sea bass (ALVAREZ-PELLITERO et al., 1993; MERELLA et al., 2006; GJURČEVIĆ et al., 2011; SITJÀ-BOBADILLA et al., 2015). Although infections are common, little is known about this coccidian species.

Information on the control of coccidian infections in fish is scarce in the literature. Only few of the drugs developed for controlling coccidiosis in warm-blooded animals have been tried on these fish parasites (MOLNÁR, 2006). Therefore, MOLNÁR and OSTOROS (2007) investigated the efficacy of nine anticoccidial drugs for the prevention and treatment of *Goussia carpelli* infection in common carp.

This paper presents the actual site of infection of *E. dicentrarchi* and data on its development and pathogenicity. Furthermore, we attempted to assess the efficacy of Trimetosul® 48% suspension for the treatment of *E. dicentrarchi* infection in farmed European sea bass.

## Materials and methods

To gain insight into sites of *E. dicentrarchi* infection, its development and pathogenicity, we analysed 60 European sea bass from a commercial fish farm for the presence of intestinal coccidia. The farm is located in the mid-east region of the Adriatic Sea (Croatia).

Adult sea bass with an average body weight of 222.9 g (standard deviation [SD]  $\pm$  51.7) were collected from floating sea cages in March, and juvenile sea bass, with an average body weight of 48.8 g (SD  $\pm$  6.8), were collected in October. All fish were collected with a dip net. Following necropsy, samples were transported immediately to the laboratory. Fresh preparations of mucus and intestinal scrapings were analysed for infection (MOLNÁR, 2006); when oocysts were found, histology was performed to determine the site of infection. Oocysts were measured using an Olympus DP 12 digital camera and Cell B software (Soft Imaging System). Mean values of all measurements are presented in  $\mu\text{m}$ , and ranges are provided in parentheses.

*Histology.* For the purpose of histological examination, the digestive tract was divided into the pyloric caeca, anterior and posterior intestine. Small samples of each were fixed in a 10% neutral buffered formalin. Fixed material was embedded in paraffin and 5  $\mu\text{m}$  serial sections were prepared. Sections were stained with haematoxylin and eosin (H&E),

toluidine blue (TB) and periodic acid-Schiff reaction (PAS). Several sections were also stained with alcian blue at pH 2.5. Sections were analysed by light microscopy using an Olympus BX41 at magnifications of up to  $\times 2000$ .

**Field trial.** A field study was performed as a preliminary assessment of the efficacy of Trimetosul<sup>®</sup> 48% suspension to treat *E. dicentrarchi* infection. The study involved juvenile sea bass with an average body weight of 49.2 g (SD  $\pm$  7.6), reared in a floating sea cage and naturally infected with *Listonella anguillarum* and *E. dicentrarchi*. The fish were treated orally with Trimetosul<sup>®</sup> 48% suspension (Genera, Croatia) at a dose of 9.84 mg of trimethoprim and 49.2 mg of sulfadiazine per kg of body weight, once daily for nine days. The suspension was diluted in water and sprayed onto commercial pellets. The fish were hand fed, and medicated feed was eaten immediately. In this floating sea cage, fish were randomly selected, necropsied and examined for coccidial infection before (n = 30) and after (n = 30) the 9-day treatment. The infection was evaluated in fresh preparations of mucus and intestinal scrapings, as well as in histological sections.

Untreated juvenile sea bass naturally infected with *E. dicentrarchi*, with an average body weight of 50.8 (SD  $\pm$  7.1) g, from a neighbouring floating cage served as a control group. Fish were analysed for infection before and after the 9-day treatment (n = 16 at each time point).

## Results

Oocysts of *E. dicentrarchi* were found in both juvenile and adult European sea bass. The overall prevalence of infection was 16.7% (n = 60). Most oocysts in mucus and intestinal scrapings were in the sporulated condition, and smaller numbers of unsporulated and semisporulated oocysts were also observed (Fig. 1).

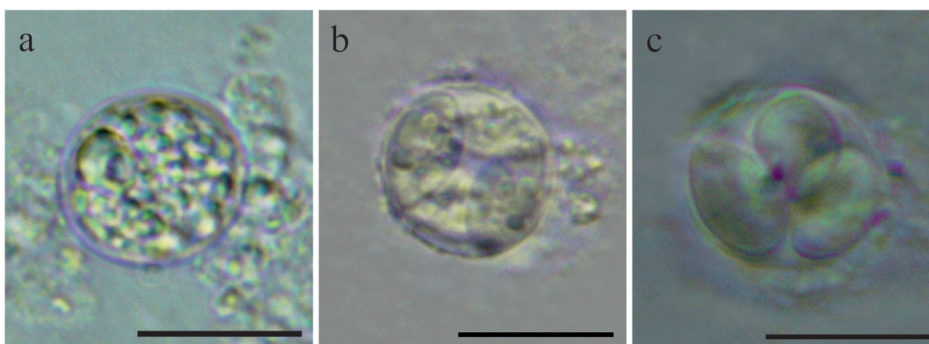


Fig. 1. Oocysts of *Eimeria dicentrarchi* from the mucus and intestinal scrapings of European sea bass; fresh mounts. Scale bar = 10  $\mu$ m. (a) Unsporulated oocyst; (b) semisporulated oocyst; (c) sporulated oocyst.

Unsporulated oocysts were round in shape, measuring 11.2 (10.7-11.6). Sporulated oocysts were round or irregularly shaped, measuring 11.3 (10.0-12.2), with a thin, membrane-like wall. Each oocyst contained four ellipsoidal, lemon-shaped sporocysts, which appeared oval in transverse section. Sporocysts filled the entire oocyst space and were positioned such that three or even four were visible in a single plane. Oocyst residuum was absent, but a single polar granule with a diameter of 1.5 (1.2-1.6) was present. Sporocysts had a length of 8.3 (8.1-8.6), a width of 4.9 (4.4-5.6), and a flattened, split-like Stieda body. Each sporocyst contained two banana-shaped sporozoites with a large, centrally located, nucleus or refractile body. The sporozoites had a length of 5.9 (4.8-6.9) and width of 1.5 (1.4-1.7) and were arranged head-to-tail in the sporocyst. Most sporozoites were reflexed on one end. Sporocyst residuum was dispersed and composed of four or five granules.

*Histology and localisation in the host.* Histological examination revealed *E. dicentrarchi* at different developmental stages (i.e. merogonic, gamogonic and sporogonic stages) in all three sections of the digestive tract (Fig. 2), although most parasites were found in the anterior intestine.

The earliest stage observed was a young meront. More advanced merogonic stages were not observed in any section of the digestive tract. Compared with gamogonic and sporogonic stages, young meronts were scarce in histological sections. Most meronts and macrogamonts were localised in the basal part of enterocytes, while most microgamonts were in the supranuclear region. Oocysts were located in the epithelium and occasionally beneath it, in the lamina propria.

Macrogamonts were spherical, with a diameter of 9.2 (8.0-10.8). They had an eccentrically situated nucleus and a large inclusion, which stained pink after H&E. Macrogamont cytoplasm contained numerous PAS-positive granules (Fig. 3a). Young microgamonts stained an intense blue with PAS, and had an oval shape with a diameter of 4.3 (3.8-4.8); their nuclei were elongated and localised to the periphery (Fig. 3b). Mature microgamonts with flagellated microgametes were irregularly shaped and twice as large as immature (Fig. 3c).

*Pathology.* No gross pathological changes were detected in any sea bass infected with *E. dicentrarchi*. Most histopathological changes were localised and restricted to individual epithelial cells. Infected epithelial cells were partially destroyed, leading to necrotic changes. The cell membrane of infected cells was damaged. Release of oocysts into the intestinal lumen was associated with complete destruction of microvilli and rupture of the host cell membrane. Vacuolisation of epithelial cells (Fig. 3d) and detachment of the lamina epithelialis from the lamina propria (Fig. 3e) were occasionally observed in infected areas. In some heavily infected parts of the digestive tract, mild infiltration of lymphocytes and macrophages was observed.

*Efficacy of Trimetosul<sup>®</sup> against E. dicentrarchi infection.* Prior to treatment, 19 of 30 fish (63.3%) were infected with *E. dicentrarchi*, and none was infected afterwards. In the control group, the prevalence of infection was 25% at baseline and also after nine days.

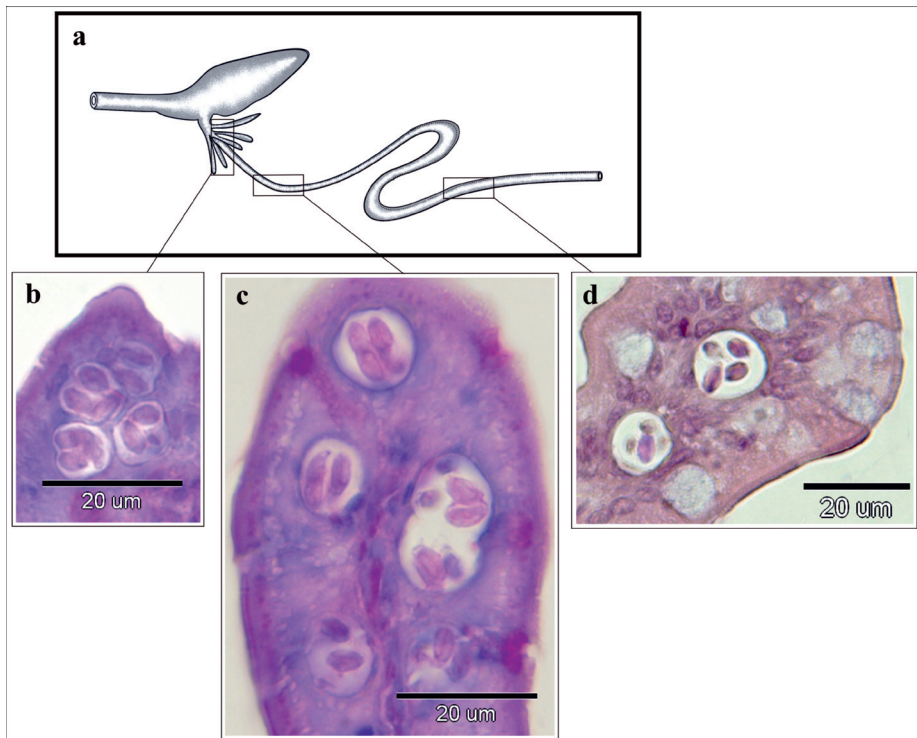


Fig. 2. (a) Schematic representation of digestive tract of European sea bass indicating the site of *Eimeria dicentrarchi* infection. (b) Histological section of oocysts in the pyloric caeca (PAS), (c) anterior part of the intestine (PAS) and (d) posterior part of the intestine (H&E).

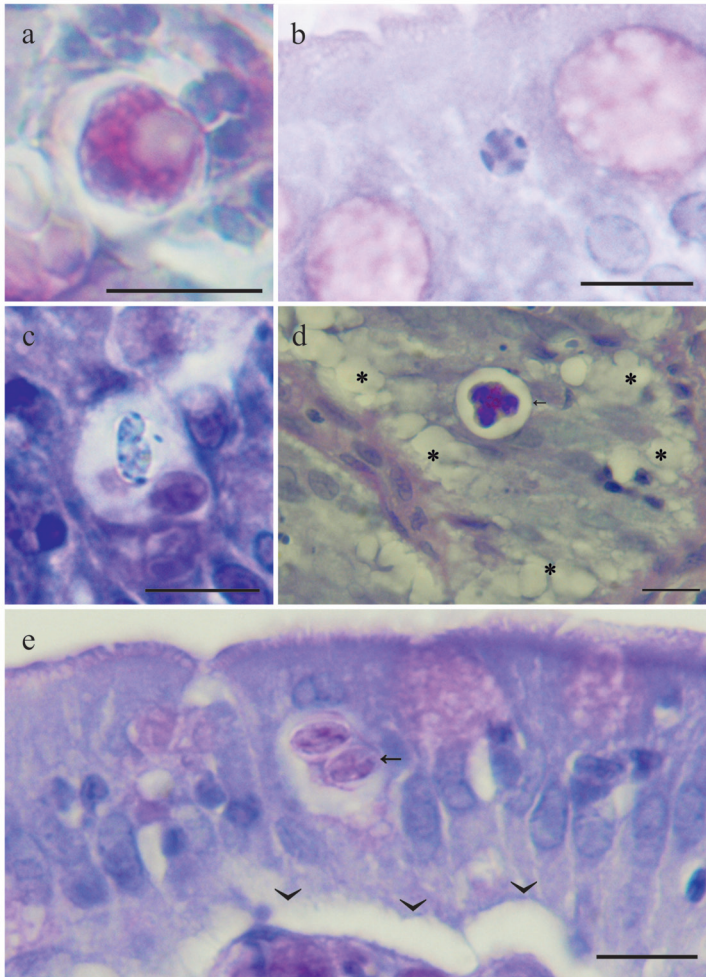


Fig. 3. Histological sections of European sea bass digestive tract infected with *Eimeria dicentrarchi*. Scale bar = 10  $\mu\text{m}$ . (a) Macrogamont with numerous PAS-positive cytoplasmic granules (PAS). (b) Young multinucleated microgamont with most nuclei arranged at the periphery (PAS). (c) Mature microgamont within a parasitophorous vacuole. Microgametes appear dark due to staining with TB. (d) Vacuolisation of epithelial cells ( $\star$ ) adjacent to the semisporulated oocyst (arrow); PAS. (e) Detachment of lamina epithelialis from lamina propria (arrowheads). The arrow indicates two sporocysts in the sporulated oocyst (PAS).



## Discussion

*E. dicentrarchi* is a coccidian species originally described from wild European sea bass in France (DAOUDI and MARQUÈS, 1987). Since that first species description, very little has been published about *E. dicentrarchi*, even though it appears to be a common parasite of sea bass in the Mediterranean. As a result, its pathogenicity is unknown.

In their original description of *E. dicentrarchi*, DAOUDI and MARQUÈS (1987) gave a detailed description of the morphological characteristics of sporulated oocysts and meronts, but they did not describe unsporulated oocysts and gamogonic developmental stages. The morphology of sporulated oocysts in our study is consistent with the original description, except that the sporocysts in our study were slightly larger and the oocysts were irregular or round in shape. To some extent, differences in oocyst shape can be influenced by pressure from the cover slip (MOLNÁR and FERNANDO, 1974).

In piscine coccidia sporulation is often endogenous, though it may be exogenous, or both endogenous and exogenous within one species (DYKOVÁ and LOM, 1981; DAVIES and BALL, 1993). DAOUDI and MARQUÈS (1987) reported that *E. dicentrarchi* oocysts leave the host in the sporulated state, meaning that the parasite sporulates endogenously. While our observations indicate that most oocysts in the digestive tract were sporulated, some unsporulated and semisporulated oocysts were also observed. Similarly, ALVAREZ-PELLITERO et al. (1993) reported the presence of sporulated and unsporulated oocysts of an *Eimeria* sp. in fresh intestinal smears from European sea bass, and this coccidium was later identified by SITJÀ-BOBADILLA et al. (2015) as *E. dicentrarchi*. BRUNO et al. (2006) observed unsporulated oocysts of an unidentified *Eimeria* species in the intestinal lumen of European sea bass, and the micrograph in Fig. 11 of that paper shows evidence of sporulated oocysts in the lamina propria. Taken together, these various studies might be interpreted to mean that *E. dicentrarchi* exhibits simultaneous endogenous-exogenous sporulation. Such sporulation has been described for several piscine coccidia from freshwater and marine fish, including *E. theostomae* from Iowa darter and Johnny darter (MOLNÁR and HANEK, 1974), *E. sillaginis* from sand whiting (MOLNÁR and ROHDE, 1988), *Goussia trichogasteri* from golden gourami (SZÉKELY and MOLNÁR, 1992) and an *Eimeria* sp. from Asian seabass (GIBSON-KUEH et al., 2011), later termed *G. kuehae* by SZÉKELY et al. (2013).

However, we consider that *E. dicentrarchi* exhibits endogenous sporulation, because in our study most oocysts in the lumen of the digestive tract were completely sporulated. We attribute the small number of unsporulated and semisporulated oocysts in the lumen to destruction of mucosal epithelium as a result of infection. The review by DYKOVÁ and LOM (1981) indicates that in the intestine of fish infected with certain coccidial species exhibiting endogenous sporulation, oocysts may leave disrupted host cells before finishing sporulation. In such cases, a small proportion of unsporulated and/or semisporulated

oocysts are discharged into the lumen of the digestive tract. Therefore we concur with DAOUDI and MARQUÈS (1987) that *E. dicentrarchi* sporulates endogenously.

In the original description, *E. dicentrarchi* was reported to develop in the pyloric caeca epithelium. Our observations suggest that it also develops in other segments of the digestive tract, mainly in the anterior part of the intestine. Furthermore, oocysts were found not only in the epithelium but also in the lamina propria, as reported for an unidentified *Eimeria* species from European sea bass (BRUNO et al., 2006). Oocyst migration from the mucosal epithelium into the lamina propria is likely a result of host tissue reaction. If so, oocyst migration may follow the pattern described by MOLNÁR (1984) and MOLNÁR (1996).

No gross pathological changes due to *E. dicentrarchi* infection were observed in the present study. Histopathological examination showed that changes were localised and mostly restricted to individual epithelial cells. Histopathological changes in the epithelial layer were similar to those described in large-scaled gurnards infected with another pathogenic *Eimeria* species (GJURČEVIĆ et al., 2008). The presence of epithelial changes and the subepithelial position of oocysts are important pathological factors. Therefore we believe that *E. dicentrarchi* could be a serious pathogen in heavily infected farmed European sea bass.

As a first step in identifying treatments for such infection, we performed a preliminary trial involving the potentiated sulphonamide Trimetosul<sup>®</sup> (trimethoprim-sulfadiazine). HARMS (1996) suggested the potential of using sulpham drugs at antibacterial doses to treat coccidiosis in fish. The results of our preliminary study suggest that oral administration of a Trimetosul<sup>®</sup> 48% suspension may be effective against *E. dicentrarchi* infection in European sea bass. These findings should be verified and extended in larger studies.

## References

- ALVAREZ-PELLITERO, P., A. SITJÀ-BOBADILLA, A. FRANCO-SIERRA (1993): Protozoan parasites of wild and cultured sea bass, *Dicentrarchus labrax* (L.), from the Mediterranean area. *Aquacult. Fish. Manage.* 24, 101-108.
- BRUNO, D. W., B. NOWAK, D. G. ELLIOTT (2006): Guide to the identification of fish protozoan and metazoan parasites in stained tissue sections. *Dis. Aquat. Org.* 70, 1-36.
- DAOUDI, F., A. MARQUÈS (1987): *Eimeria bouixi* n. sp. and *Eimeria dicentrarchi* n. sp. (Sporozoa-Apicomplexa), parasites from the fish *Dicentrarchus labrax* (Linné, 1758) in Languedoc. *Ann. Sci. Nat. Zool.* 8, 237-242. (in French)
- DAVIES, A. J., S. J. BALL (1993): The biology of fish coccidia. In: *Advances in Parasitology*, Volume 32. (Baker, J. R., R. Muller, Eds.), Academic Press Limited, London, pp. 294-366.
- DYKOVÁ, I., J. LOM (1981): Fish coccidia: critical notes on life cycles, classification and pathogenicity. *J. Fish Dis.* 4, 487-505.



- GIBSON-KUEH, S., N. T. N. THUY, A. ELLIOT, J. B. JONES, P. K. NICHOLLS, R. C. A. THOMPSON (2011): An intestinal *Eimeria* infection in juvenile Asian seabass (*Lates calcarifer*) cultured in Vietnam - A first report. *Vet. Parasitol.* 181, 106-112.
- GJURČEVIĆ, E., Z. KOZARIĆ, S. BAMBIR, Z. PETRINEC, S. KUŽIR, A. GUDAN, B. BAŽDARIĆ (2008): Histological investigations of *Eimeria* infection in large-scaled gurnards, *Lepidotrigla cavillone* (Lacepède, 1801) from the Novigrad Sea, Croatia. *Acta Parasitol.* 53, 81-84.
- GJURČEVIĆ, E., S. KUŽIR, B. BAŽDARIĆ, S. BAMBIR, K. MATANOVIĆ, B. M. ROSENTHAL (2011): Efficacy of Trimetosul® 48% suspension against *Eimeria dicentrarchi* infection in European sea bass: a preliminary study. Abstract book of the 15<sup>th</sup> International Conference of the European Association of Fish Pathologists, 12-16 September, Split, Croatia, p. 423.
- HARMS, C. A. (1996): Treatments for parasitic diseases of aquarium and ornamental fish. *Semin. Avian Exot. Pet* 5, 54-63.
- MERELLA, P., G. GARIPPA, F. SALATI (2006): Parasites of cage cultured European seabass *Dicentrarchus labrax* and gilthead seabream *Sparus aurata* from Sardinia (western Mediterranean): first results. *Parassitologia* 48, 290-290.
- MOLNÁR, K., C. H. FERNANDO (1974): Some new *Eimeria* (Protozoa, Coccidia) from freshwater fishes in Ontario, Canada. *Can. J. Zool.* 52, 413-419.
- MOLNÁR, K., G. HANEK (1974): Seven new *Eimeria* spp. (Protozoa, Coccidia) from freshwater fishes of Canada. *J. Protozool.* 21, 489-493.
- MOLNÁR, K. (1984): Some peculiarities of oocyst rejection of fish coccidia. *Symposia Biol. Hung.* 23, 87-97.
- MOLNÁR, K., K. ROHDE (1988): Seven new coccidian species from marine fishes in Australia. *Syst. Parasitol.* 11, 19-29.
- MOLNÁR, K. (1996): Remarks on the morphology, site of infection and validity of some coccidian species from fish. *Acta Vet. Hung.* 44, 295-307.
- MOLNÁR, K. (2006): Phylum Apicomplexa. In: *Fish Diseases and Disorders, Volume 1: Protozoan and Metazoan Infections*, 2<sup>nd</sup> ed., (Woo, P. T. K., Ed.), CAB International, Wallingford, pp. 183-204.
- MOLNÁR, K., G. OSTOROS (2007): Efficacy of some anticoccidial drugs for treating coccidial enteritis of the common carp caused by *Goussia carpelli* (Apicomplexa: Eimeriidae). *Acta Vet. Hung.* 55, 67-76.
- SITJÀ-BOBADILLA, A., C. ZARZA, B. FOUZ (2015): Pathology. In: *Biology of European sea bass*. (Sánchez Vázquez, F. J., J. A. Muñoz-Cueto, Eds.), CRC Press, Boca Raton, pp. 287-341.
- SZÉKELY, C., K. MOLNÁR (1992): *Goussia trichogasteri* n. sp. (Apicomplexa: Eimeriidae) infecting the aquarium-cultured golden gourami *Trichogaster trichopterus trichopterus*. *Dis. Aquat. Org.* 13, 79-81.
- SZÉKELY, C., M. H. BORKHANUDDIN, F. SHAHAROM, M. S. A. EMBONG, K. MOLNÁR (2013): Description of *Goussia kuehae* n. sp. (Apicomplexa: Eimeriidae) infecting the Asian

seabass, *Lates calcarifer* (Bloch) (Perciformes: Latidae), cultured in Malaysian fish farms. Syst. Parasitol. 86, 293-299.

Received: 9 October 2015

Accepted: 22 March 2016

---

**GJURČEVIĆ, E., Š. KUŽIR, B. BAŽDARIĆ, K. MATANOVIĆ, I. DEBELIĆ, F. MARINO, K. DRAŠNER, B. M. ROSENTHAL: Novi podatci o *Eimeria dicentrarchi* (Apicomplexa: Eimeriidae), učestalom nametniku u lubina (*Dicentrarchus labrax*) uzgajanih u istočnom dijelu srednjeg Jadrana. Vet. arhiv 87, 77-86, 2017.**

**SAŽETAK**

Ovo istraživanje doprinosi izvornom opisu kokcidije *Eimeria dicentrarchi* Daoudi i Marquès, 1987, koja se učestalo pojavljuje u lubina u istočnom dijelu srednjeg Jadrana. U radu je prikazan njezin smještaj u probavnoj cijevi, razvojni ciklus i patološki učinak na domaćina. Prisutnost razvojnih stadija *E. dicentrarchi* utvrđena je u raznim dijelovima probavne cijevi, uglavnom u prednjem dijelu crijeva. Čitav razvojni ciklus odvija se u citoplazmi enterocita, iako do sporogonije dolazi i u lamini propriji. Oociste većinom potpuno sporuliraju u probavnoj cijevi što upućuje na unutarnju sporulaciju. *E. dicentrarchi* uzrokuje lokalizirane histopatološke promjene primarno ograničene na pojedinačne epitelne stanice. Rezultati preliminarnog istraživanja pokazuju da potencirani sulfonamid Trimetosul® (trimetoprim-sulfadiazin) može biti učinkovit u liječenju invazije kokcidijom *E. dicentrarchi*.

**Ključne riječi:** *Eimeria dicentrarchi*, lubin, razvojni ciklus, patogenost, liječenje

---