

## Immunohistochemical detection of bovine herpesvirus type 1 and bovine adenovirus type 3 antigens in frozen and paraffinized lung sections of pneumonic sheep and goats

Ali O. Çeribası<sup>1\*</sup>, Songül Çeribası<sup>1</sup>, and Mustafa Ozkaraca<sup>2</sup>

<sup>1</sup>Department of Pathology, Faculty of Veterinary Medicine, Fırat University, Elazığ, Turkey

<sup>2</sup>Department of Pathology, Faculty of Veterinary Medicine, Ataturk University, Erzurum, Turkey

---

**ÇERIBASI, A. O., S. ÇERIBASI, M. OZKARACA: Immunohistochemical detection of bovine herpesvirus type 1 and bovine adenovirus type 3 antigens in frozen and paraffinized lung sections of pneumonic sheep and goats. Vet. arhiv 86, 9-21, 2016.**

### ABSTRACT

The aim of this study was to determine Bovine Adenovirus type 3 (BAV3) and Bovine Herpesvirus type 1 (BHV1) antigens in frozen and formalin-fixed paraffin-embedded lung tissues of pneumonic sheep and goats, using direct fluorescent antibody technique (DFAT) and immunoperoxidase (IP) staining. For this purpose, the lungs of 1276 male sheep and 1087 male goats, which were raised in various farms in the Elazığ province and surrounding areas and were brought to the abattoir for slaughtering between January and December 2011, were examined. Macroscopic pneumonia findings were detected only in the apical and cardiac lobes of the lungs of 132 sheep and 145 goats. The rates of mild, moderate and severe consolidations observed in the apical and cardiac lobes of pneumonic lungs were 57.5 %, 29.5 % and 12.8 % for sheep, respectively and 62.0 %, 20.0 % and 17.9 % for goats, respectively. Pneumonias were microscopically classified in sheep and goats as catarrhal-purulent (40.1 % and 33.1 %), interstitial (26.5 % and 31.7 %), fibrinous (21.2 % and 26.9 %), verminous (9.4 % and 6.2 %) and pulmonary adenomatosis (1.5 % and 2.0 %). In the examination with IP and DFAT in terms of BAV3 and BHV1 antigens, a total of 249 (116 sheep and 133 goats) pneumonic lungs, but not verminous and pulmonary adenomatosis, were considered. BAV3 and BHV1 antigens were determined to be 5.1 % and 1.7 % in sheep and 0.7 % and 2.2 % in goats by the IP method, respectively. BAV3 and BHV1 antigens were found to be 9.4 % and 5.1 % in sheep and 4.5 % and 7.5 % in goats by DFAT, respectively. In conclusion, the presence of viral antigens in lung tissues of sheep and goats may indicate that natural pneumonia may be induced by BAV3 and BHV1 or possibly other species-specific adenoviruses and herpesviruses. In addition, it is thought that sheep and goats might have a role in the transmission of these viruses to cattle.

**Key words:** bovine herpesvirus 1, bovine adenovirus 3, sheep, goat, pneumonia, immunofluorescence, immunoperoxidase

---

\*Corresponding author:

Dr. Ali Osman Çeribası, PhD., Department of Pathology, Faculty of Veterinary Medicine, Fırat University 23119 Elazığ, Turkey, Phone: +90 424 237 0000 / 4031; Fax: +90 424 238 8173; E-mail: aoceribası@firat.edu.tr

## Introduction

Respiratory tract infections caused by some viruses with cattle origin have been demonstrated in sheep and goats (CASWELL and WILLIAMS, 2007; SHARP and NETTLETON, 2007). However, the causative agents were rarely determined and many viruses associated with respiratory system diseases in cattle have been implicated in natural and experimental infections in sheep and goats (THIRY et al., 2006). Bovine herpesvirus 1 (BHV1) is a member of the *Herpesviridae* family and is one of the most important emerging diseases of domestic and wild cattle, causing huge economic losses (BISWAS et al., 2013). Moreover, cross transmission of ruminant herpesviruses has been reported among ruminant species (GIULIANI and SHARMA, 1995; HAGE et al., 1997; LEHMKUHL et al., 1985; SHANKAR and YADAV, 1987; YESILBAG and DAGALP-BILGE, 2003). The detection of antibodies against BHV1 in sheep indicates that this species may play a role in the epidemiology of BHV1 (ELAZHARY et al., 1984; JETTEUR et al., 1990; SURESH and SURIBABU, 1993; WHETSTONE and EVERMANN, 1988), but it has been suggested that they have no major role in the transmission of BHV1 infections from sheep to cattle (HAGE et al., 1997). Although latency and reactivation of BHV1 in goats have previously been demonstrated (SIX et al., 2001; TOLARI et al., 1990; WAFULA et al., 1985) no data are currently available in sheep. Adenovirus infections are primarily host specific; however, cross infections can occur among closely related species (TURY et al., 1978). Adenoviral infection of sheep is common, and to date, six ovine and two bovine adenovirus serotypes have been isolated from healthy and diseased sheep (ADAIR et al., 1982; BELAK and PALFI, 1974; LEHMKUHL et al., 1985; LEHMKUHL et al., 1993). Adenovirus infections are most often subclinical, and diseases occur more commonly in the intestinal or respiratory tracts (DEBEY et al., 2001). Natural or experimental adenovirus infections in sheep cause lesions mainly in the respiratory tract (BELAK and PALFI, 1974; RUSHTON and SHARP, 1977). In addition, experimental infections in lambs with adenoviruses and BHV1 usually produce lesions, and they are confined to the respiratory tract (BELAK et al., 1976; CUTLIP and LEHMKUHL, 1986; CUTLIP and LEHMKUHL, 1983; GIULIANI and SHARMA, 1995). BHV1 was isolated from a single lamb suffering from a respiratory disease (TRUEBLOOD et al., 1978). Natural BHV1 infection was reported to have caused severe respiratory disease and keratitis in two goats, where the virus was recovered from the eyes and nose (MOHANTY et al. 1972).

Destroyed ciliary activity and markedly decreased mucosiliar cleaning in the respiratory tract have been reported in both viral infections (CUTLIP et al., 1996; JERICHO, 1983). Although BAV3 and BHV1 pathogenicity has been well defined in cattle (CASWELL and WILLIAMS, 2007; JERICHO, 1983; NARITA et al., 2000; NARITA et al., 2003), few natural pneumonia cases related to these agents have been reported in small ruminants (MAHMOUD and AHMED, 2009). Routine histopathologic examination has been reported to be insufficient for the diagnosis, due to similar pulmonary lesions in BAV3 and

BHV1 infections (CASWELL and WILLIAMS, 2007). The confirmative diagnosis of these infections is made by virus isolation in cell culture, PCR, electron microscopy, serum neutralisation analysis, fluorescence antibody and immunoperoxidase techniques (DEBEY et al., 2001; MAHMOUD and AHMED, 2009; NARITA et al., 2003; NARITA et al., 2000; OKUR GUMUSOVA et al., 2007).

The purpose of this study was to determine the prevalence of BAV3 and BHV1 antigens using direct fluorescent antibody technique (DFAT) and immunoperoxidase (IP) staining of frozen and formalin-fixed, paraffin embedded lung tissues of pneumonic sheep and goats in the Elazığ province and surrounding areas in Turkey.

### **Materials and methods**

*Sample collection.* The lungs of 1276 male sheep and 1087 male goats, which were raised in the Elazığ province and surrounding areas and were brought to the abattoir for slaughtering between January and December 2011, were examined. Macroscopic pneumonia findings were detected only in the apical and cardiac lobes of the lungs belonging to 132 sheep and 145 goats. The tissue samples taken from affected lungs were separated into two parts; one part was fixed in formalin, the other was stored at - 80 °C to obtain frozen sections.

*Gross and histopathological examination.* The severity of pneumonia in the apical and cardiac lobes was scored based on the extent of consolidation. Lesions determined as less than 10 %, between 10 % and 20 %, and more than 20 % of the apical and cardiac lobe volumes were evaluated as “mild”, “moderate” and “severe”, respectively. Tissue samples taken from grossly consolidated lungs were fixed in 10 % buffered formalin for 48 h and were embedded in paraffin wax before sectioning. The tissues were then stained with haematoxylin and eosin (H&E), and finally examined under light microscopy. IP and DFAT methods were applied to the total number of 249 (116 sheep and 133 goats) lungs, which were microscopically characterized as having catarrhal-purulent, interstitial or fibrinous pneumonia, but not verminous and pulmonary adenomatosis.

*Immunoperoxidase staining.* IP staining was performed with the avidin-biotin-peroxidase complex procedure, using commercially available IP kits (Ultravision Detection System, Antipolyvalent, HRP/DAB, Thermo Scientific, Cat No: TP-015-HD). For IP staining, deparaffinized tissue sections were placed in citrate buffer solution (10 mM citric acid, pH 6.0) and were kept in a microwave for 20 min for antigen retrieval stage. The sections were incubated in 70 % methanol with 3 % H<sub>2</sub>O<sub>2</sub> for 10 min to inhibit endogenous peroxidase activity, and they were then washed three times in phosphate-buffered saline (PBS). The sections were treated with blocking solution for 10 min. After draining of blocking serum, the sections were incubated with primary antibodies [monoclonal mouse anti-adenovirus type 3 for BAV3 (Cat No: BIO 292, BIOX Jemelle, Belgium) and monoclonal mouse anti-bovine herpesvirus type 1 for BHV1 (Cat No:

BIO 289, BIOX Jemelle, Belgium)] diluted to 1:50 rate in PBS at 4° C overnight in a humidified chamber. After washing three times with PBS, the sections were treated with biotinylated anti-goat polyvalent secondary antibody for 10 min. Then the sections were washed three times in PBS and treated with the peroxidase-conjugated streptavidin for 10 min. After another PBS bath, the sections were incubated with 3.3 diaminobenzidine (DAB). After color change, the sections were washed in tap water and then counterstained with Mayer's hematoxylin (MH). Unaffected sheep and goat lungs were used as negative controls. For positive controls, primary sera were used instead of non-immun rabbit serum in the pneumonic lung tissues.

*Direct fluorescent antibody technique.* DFAT was used for the detection of BAV3 and BHV1 antigens. Frozen sections cut at 6 microns were placed on 0.01 % poly-D-lysine hydrobromide coated slides and air-dried. Then, the sections were fixed in acetone/PBS mixture for 10 min at room temperature. After washing with PBS, the sections were treated with the conjugates [monoclonal mouse anti-BAV3 FITC (Cat No: BIO 039, BIOX Jemelle, Belgium) and monoclonal mouse anti-BHV1 FITC (Cat No: BIO 026, BIOX Jemelle, Belgium)] diluted in a 1:20 ratio with PBS-Evans Blue at room temperature for 1 h. After washing with PBS again, the slides were mounted with glycerol. Finally, the sections were examined under a fluorescent microscope, and the results were evaluated. The processes mentioned for the IP method were applied for the negative and conjugate controls.

## Results

*Gross pathological findings.* A total of 1276 sheep and 1087 goat lungs were grossly examined, and pneumonia was detected in the apical and cardiac lobes in 132 cases (10.34 %) in sheep and 145 cases (13.34 %) in goats. The severity and type of pneumonic lesions are presented in Table 1. The rates of mild, moderate and severe consolidations observed in the apical and cardiac lobes of pneumonic lungs were 57.58 %, 29.55 % and 12.88 % in sheep, respectively and 62.07 %, 20.00 % and 17.93 % in goats, respectively. Generally, the lesions in the apical and cardiac lobes were characterized with patchy or confluent consolidated purple-red or grey foci and irregular lobular atelectatic foci. Thickening and dull view in the pleura and adhesions between the lobes were found in 55 cases (21 sheep and 34 goats).

In the microscopic examination, pneumonias were classified in sheep and goats as catarrhal-purulent (40.15 % and 33.10 %), interstitial (26.52 % and 31.72 %), fibrinous (21.21 % and 26.90 %), verminous (9.43 % and 6.21 %) and pulmonary adenomatosis (1.52 % and 2.07 %), respectively. Catarrhal-purulent, interstitial or fibrinous pneumonia, excluding verminous and pulmonary adenomatosis, were determined in 116 sheep and 133 goat lungs which were examined by IP and DFAT staining for the presence of BAV3 and BHV1 antigens.



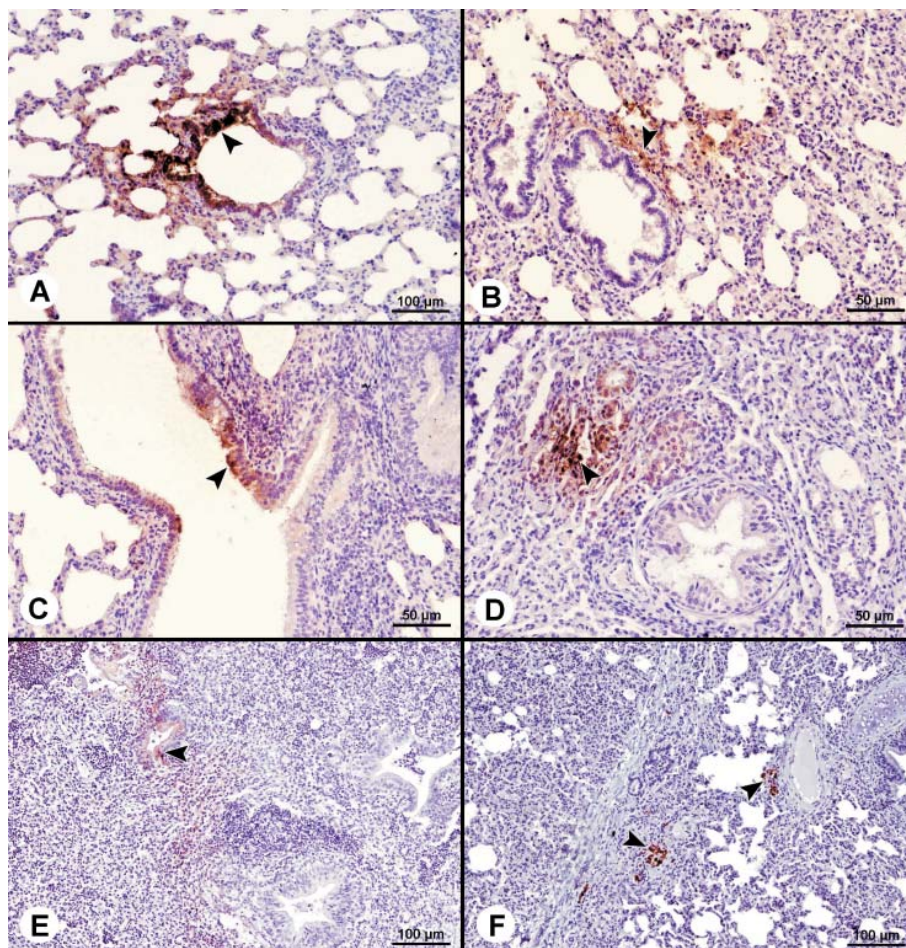


Fig. 1A. BAV3 positivity in bronchioles epithelium (arrowhead) in a sheep. 1B. BHV1 positivity in alveoli adjacent to bronchiole (arrowhead) in a sheep. 1C. BAV3 positivity in bronchioles epithelium (arrowhead) in a goat. 1D. BAV3 positivity in alveolar epithelium (arrowhead) in a goat. 1E. BHV1 immunopositivity in bronchiole epithelium (arrowhead) in a goat. 1F. BHV1 immunoreaction in perivascular cell infiltrations (arrowheads) in a goat. Counterstained with MH.

*Immunoperoxidase staining (IP) findings.* Of the 249 pneumonic lungs, while BAV3 antigens were detected in 6 cases (5.17 %) in sheep and 1 case (0.75 %) in goats, BHV1 antigens were determined in 2 cases (1.72 %) in sheep and 1 case (0.75 %) in goats. It was noticed that positive staining was generally present in the pneumonic areas. Specific IP staining associated with both viral antigens were observed generally in the granular appearance and in the cytoplasm of epithelial cells in the airways. Although severe BAV3 immunostaining was found in the bronchiole epithelium (Fig. 1A), it was more scant in the alveolar epithelium of pneumonic lungs in sheep. In addition, BAV3 antigens were detected in bronchiole associated lymphoid cells. Mild specific IP staining with BHV1 antigens was observed in alveoli adjacent to bronchioles in sheep (Fig. 1B). Generally IP staining associated with both viral antigens was quite limited in goats. BAV3 positivity was observed in bronchiole (Fig. 1C) and alveolar epithelium (Fig. 1D), and BHV1 positivity in bronchiole or alveolar epithelium (Fig. 1E), and perivascular cell infiltrations (Fig. 1F) were found. No immunopositive staining was observed in tissue from healthy sheep and goat lungs (negative control) or in non-immune rabbit serum (serum control) added pneumonic lung tissue.

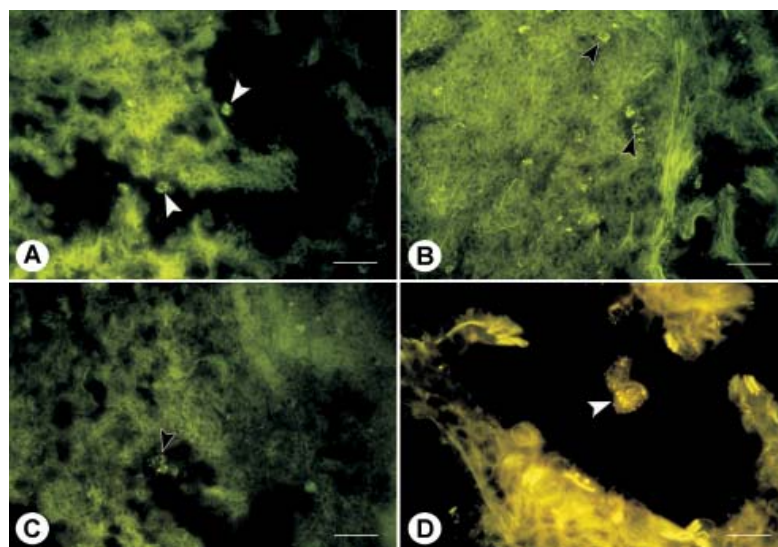


Fig. 2A. DFAT positivity in desquamative necrotic cells in bronchioles lumen (arrowheads) of a BHV1 positive sheep, Bar = 100  $\mu$ m. 2B. DFAT positivity in alveolar epithelium (arrowheads) of a BAV3 positive goat, Bar = 150  $\mu$ m. 2C. DFAT positivity in desquamative epithelial cells in alveol lumen (arrowhead) of a BAV3 positive sheep, Bar = 100  $\mu$ m. 2D. Cytoplasmic and intranuclear fluorescence staining in alveolar epithelium cells of a BHV1 positive goat, scale bar = 50  $\mu$ m.

*Direct fluorescent antibody technique findings.* BAV3 and BHV1 antigens were detected in 9.48 % (11/116) and 5.17 % (6/116) of sheep lungs and, 4.51 % (6/133) and 7.52 % (10/133) of goat lungs, which characterized catarrhal-purulent, interstitial or fibrinous pneumonia, respectively by DFAT. All the positive cases by the IP method were also positive for fluorescent staining, with varying severity and distribution. With respect to the degree of DFAT staining, no differences were observed between species and between viral antigens. The fluorescence staining related to both viral antigens was found in the epithelium of bronchiole (Fig. 2A) and alveoli (Fig. 2B), and within the exudates of the airways (Fig. 2C). Fluorescence staining was seen commonly in the cytoplasm and less commonly in the nucleus of some cells, ranging from small to large homogeneous granular masses (Fig. 2D). No fluorescence staining was detected in control sections.

*Histopathological findings.* Cases which were positive for only BAV3 and/or BHV1 antigens were evaluated histopathologically. The microscopic findings are summarized in Table 2. Thickening of interalveolar septa and fibrosis, hyperplasia or desquamation of bronchiolar epithelium, and peribronchiolar and interalveolar mononuclear cell infiltrations were the most prominent microscopic changes in all positive cases for both viral antigens. In some BAV3 or BHV1 positive cases, lymphoid hyperplasia, necrotic bronchiolitis and atelectasis were noticed. In some cases, alveolar lumina were filled with dark basophilic, oat-shaped clustered leucocytes, having elongated or streaming nuclei. It was observed that pleuritis, characterized by fibrinous exudate with mononuclear and neutrophil infiltration, was associated with pneumonia in these cases.

## Discussion

Previous studies have reported that fluorescent antibody technique (FAT) is an advantageous technique in terms of achieving rapid results because preparation and examination of the samples are performed within a short period of time (EDWARDS et al., 1988; FORGHANI, 2010; NETTLETON et al., 1983). However, the efficiency of FAT is limited in terms of determining appropriate morphological details in tissues (STEVENSON, 1969). While processing formalin-fixed tissues takes more time, the histopathology results of retrospective studies show that formalin-fixed sections are superior to frozen sections in terms of accurate identification of cell and tissue types. However, immunogenic epitopes and many antisera used for IP diagnosis are unreactive in fixed specimens, due to the damaging effect of fixation (HAINES and CHELACK, 1991). In the present study, BAV3 antigens were identified in six sheep (5.17 %) and one goat (0.75 %) while BHV1 antigens were determined in two sheep (1.72 %) and three (2.26 %) goats by IP. However, BAV3 and BHV1 antigens were detected in 11 (9.48 %) and 6 (5.17 %) of 116 sheep lungs and in 6 (4.51 %) and 10 (7.52 %) of 133 goat lungs by DFAT. With respect to distribution of viral antigens, more detailed findings were observed by the IP method when compared

to DFAT staining. In addition, the results of this study are the first in Turkey in terms of determination of BAV3 and BHV1 viral antigens by DFAT in lung tissues of sheep and goats with natural pneumonia.

It has been reported that viral antigens were detected in epithelial cells of the bronchi, bronchiole and alveoli of one week old calves, experimentally infected with BAV3, but not in three-month-old calves by the IP method. It has been suggested that increased CD8 T lymphocytes in pneumonia are important for host defense against BAV3 infection in calves (NARITA et al., 2003). In the experimental infection of calves with BHV1, viral antigens were observed in bronchi, bronchioles and alveolar epithelium by IP (NARITA et al., 2000). The IP findings of the present study are consistent with the results of previous studies performed in cattle, in terms of the distribution and localization of BAV3 and BHV1 viral antigens in lungs (NARITA et al., 2003; NARITA et al., 2000). In addition, it is epidemiologically important to determine localization of both viral agents throughout the epithelium of the respiratory tract in sheep and goats, in terms of the spread of antigens to susceptible animals by nasal secretions and coughing (CASWELL and WILLIAMS, 2007).

It has been reported that experimental adenovirus and BHV1 infections are microscopically characterized by proliferative bronchiolitis, degeneration, desquamation or hyperplasia of bronchial and alveolar type II epithelium, atelectasis, lymphocyte, macrophage and neutrophil infiltrations, thickening of the interalveolar septum and intranuclear inclusions in endothelial and epithelial cells in ruminants (BELAK et al., 1980; CUTLIP et al., 1996; CUTLIP and LEHMKUHL, 1986; LEHMKUHL et al., 1997; NARITA et al., 2000; SHARP and NETTLETON, 2007). The histopathological findings of the present study were similar to the results of previous studies, with the exception of inclusion bodies. Earlier studies have suggested that the determination of viral pneumonia-specific lesions, such as inclusion bodies in experimental adenovirus infections, may depend on many factors, including animal species and age, virulence of agent, amount of virus, infection period and the presence of secondary bacterial infections (CUTLIP et al., 1996; CUTLIP and LEHMKUHL, 1986; CUTLIP and LEHMKUHL, 1983). Thus, definitive diagnosis of BAV3 or BHV1 associated pneumonia has been reported to be made with PCR, culture, electron microscopy, FAT, IFAT and IP techniques (BISWAS et al., 2013; CUTLIP and LEHMKUHL, 1986). Moreover, it has been emphasized that failure to determine the virus or antigens by electron microscopy and immunofluorescence staining might be experienced due to low concentrations of virus in the lesions (CUTLIP and LEHMKUHL, 1986).

In previous studies, serological evidence was obtained for the presence of BHV1 in sheep and goats. LEHMKUHL et al. (1985) reported the presence of BHV1 at the rate of 5.4 % in lambs in their seroepidemiological study. The percentage of BHV1 isolates was determined as 5.8 % by PCR in the lung tissues of sheep and goats raised in Egypt, and it was suggested that this situation may be due to overcrowding and bad hygienic measures,



which play a role in the transmission of respiratory disease in an animal population (MAHMOUD and AHMED, 2009). The prevalence of BHV1 antibodies was found to be between 11.2 and 13 % in goats and between 0 and 2.9 % in sheep raised in Africa (JESSET and RAMPTON, 1975; MAURICE and PROVOST, 1970; TAYLOR et al., 1977). ELAZHARY et al. (1984) reported that 6.9 % of the tested goats had BHV1 antibodies in Quebec, Canada while FULTON et al. (1982) detected that 13.2 % of tested goats were positive in the USA. In addition, BHV1 seropositivity in sheep was reported to be 10.8 % (ELAZHARY et al., 1984). Surveys using bovine adenovirus to detect adenovirus antibodies in goats in Iran (AFSHAR, 1969), India (DUBEY et al., 1985), and the United States (FULTON et al., 1982) indicate low adenovirus infection rates. Although BAV3 seropositivity rate was found to be 5.2 % in goats in the Marmara region of Turkey (OKUR GUMUSOVA and AKCA, 2002), it was determined as 11.0 % by ELISA in *Gazelle subgutturosa* in the Ceylanpinar region of Turkey (GUR et al., 2008). Besides, it has been reported that BHV1 prevalence ranges from 0.7 to 5.52 % in goats (ATASEVEN et al., 2010; YESILBAG et al., 2003) and from 2.44 to 9.6 % in sheep in Turkey (ALBAYRAK et al., 2007; ATASEVEN et al., 2010; CABALAR and ATASEVEN, 1999; YESILBAG and DAGALP-BILGE, 2006). In another study conducted on cattle in the Elazığ province of Turkey, prevalences of BAV3 and BHV1 were detected as 5.26 % and 2.43 % by IP and 6.88 % and 4.45 % by DFAT, respectively. When all the data obtained so far for BHV1 seropositivity are considered, it is plausible (CERIBASI et al., 2014) to suggest that urgent prevention measures are required in order to control these infections in Turkey.

In conclusion, in the present study, BAV3 and BHV1 antigens were determined as 9.4 % and 5.1 % by DFAT, as 5.1 % and 1.7 by IP in pneumonic sheep lungs and as 4.5 % and 7.5 % by DFAT, as 0.7 % and 2.2 % by IP in pneumonic goat lungs, respectively. The presence of viral antigens in the lung tissues of sheep and goats may indicate that natural pneumonia may be induced by BAV3 and BHV1, or possibly other species-specific adenoviruses and herpesviruses. In addition, it is thought that sheep and goats might have a role in transmission of these viruses to cattle.

### References

- ADAIR, B. M., J. B. McFERRAN, E. R. McKILLOP (1982): A six species of ovine adenovirus isolated from lambs in New Zealand. *Arch. Virol.* 74, 269-275.
- AFSHAR, A. (1969): The occurrence of precipitating antibodies to bovine adenovirus in sera of farm animals and man in Iran. *Vet. Rec.* 84, 571-572.
- ALBAYRAK, H., Z. YAZICI, S. OKUR GUMUSOVA (2007): Seroprevalence to bovine herpesvirus type 1 in sheep in Turkey. *Vet. Arhiv* 77, 257-263.
- ATASEVEN, V. S., Z. BASARAN, V. YILMAZ, S. DAGALP-BILGE (2010): Seroprevalance of parainfluenza virus-3 and herpesvirus type-1 infections in goats of Van region. *J. Fac. Vet. Med. Yuz. Yil* 21, 7-9.

- A. O. Çeribasi et al.: Bovine herpesvirus type 1 and bovine adenovirus type 3 in pneumonic sheep and goats
- BELAK, S., V. PALFI, V. PALYA (1976): Adenovirus infections in lambs, I. Epizootiology of the disease. *Zbl. Vet. Med. B.* 23, 320-330.
- BELAK, S., V. PALFI (1974): An adenovirus isolated from sheep and its relationship to type 2 bovine adenovirus. *Arch. ges. Virusforsch.* 46, 366-369.
- BELAK, S., F. VETESI, V. PALFI, L. PAPP (1980): Isolation of a pathogenic strain of ovine adenovirus type 5 and a comparison of its pathogenicity with that of another strain of the same serotype. *J. Comp. Pathol.* 90, 169-176.
- BISWAS, S., S. BANDYOPADHYAY, U. DIMRI, P. H. PATRA (2013): Bovine herpesvirus-1 (BHV-1) - a re-emerging concern in livestock: a revisit to its biology, epidemiology, diagnosis, and prophylaxis. *Vet. Quart.* 33, 68-81.
- CABALAR, M., V. S. ATASEVEN (1999): Serological survey for parainfluenza-3 virus, bovine respiratory syncytial virus and bovine herpes-1 virus in sheep in Van. *J. Fac. Vet. Med. Yuz. Yil* 5, 73-78.
- CASWELL, J., K. WILIAMS (2007): Respiratory system. In: Jubb, Kennedy, and Palmer's *Pathology of Domestic Animals* (Maxie, M., Ed.), Edinburgh, UK. Elsevier, pp. 594-622.
- CERIBASI, A. O., M. OZKARACA, S. CERIBASI, H. OZER (2014): Histopathologic, immunoperoxidase and immunofluorescent examinations on natural cattle pneumonia originated from Parainfluenza type 3, Respiratory Syncytial virus, Adenovirus type 3 and Herpesvirus type 1. *Revue Med. Vet.* 165, 201-212.
- CUTLIP, R. C., H. D. LEHMKUHL, K. A. BROGDEN, N. J. HSU (1996): Lesions in lambs experimentally infected with ovine adenovirus serotype 6 and *Pasteurella hemolytica*. *J. Vet. Diagn. Invest.* 8, 296-303.
- CUTLIP, R. C., H. D. LEHMKUHL (1986): Pulmonary lesions in lambs experimentally infected with ovine adenovirus 5 strain RTS-42. *Vet. Pathol.* 23, 589-593.
- CUTLIP, R. C., H. D. LEHMKUHL (1983): Experimental infection of lambs with ovine adenovirus isolate RTS-15 1: Lesions. *Am. J. Vet. Res.* 44, 2395-2402.
- DEBEY, B. M., H. D. LEHMKUHL, C. CHARD BERGSTROM, L. A. HOBBS (2001): Ovine adenovirus serotype 7-associated mortality in lambs in the United States. *Vet. Pathol.* 38, 644-648.
- DUBEY, S. C., D. V. JOSHI, S. N. SHARMA (1985): Serological evidence for ovine adenovirus antibodies in sheep, goats and bovine in Punjab. *Indian J. Anim. Sci.* 55, 652-653.
- EDWARDS, S., H. WHITE, R. H. NEWMAN, P. NIXON (1988): A veterinary services scheme for the rapid diagnosis of viral infections in ruminants, using immunofluorescence. *State Vet. J.* 42, 41-47.
- ELAZHARY, M. A., A. SILIM, S. DEA (1984): Prevalence of antibodies to bovine respiratory syncytial virus, bovine viral diarrhea virus, bovine herpesvirus-1, and bovine parainfluenza-3 virus in sheep and goats in Quebec. *Am. J. Vet. Res.* 45, 1660-1662.
- FORGHANI, B. (2010): Diagnosis by viral antigen detection. In: *Lennette's Laboratory diagnosis of viral infections*. (Jerome, K. R., Ed.), Informa Healthcare, pp. 113-132.

A. O. Çeribası et al.: Bovine herpesvirus type 1 and bovine adenovirus type 3 in pneumonic sheep and goats

- FULTON, R. W., M. M. DOWNING, H. V. HAGSTAD (1982): Prevalence of bovine herpes virus-1, bovine viral diarrhoea, parainfluenza-3, bovine adenoviruses-3 and -7 and goat respiratory syncytial viral antibodies in goats. *Am. J. Vet. Res.* 43, 1454-1457.
- GIULIANI, S., R. SHARMA (1995): Experimental infection of lambs with bovine herpesvirus type-1 (BHV-1). *Int. J. Anim. Vet. Adv.* 10, 73-75.
- GUR, S., T. AYDINOGLU, Y. AKCA (2008): Serologic investigation of respiratory viruses in captive Goitred Gazella (*Gazella subgutturosa subgutturosa*). *Revue Med. Vet.* 159, 221-223.
- HAGE, J. J., P. VELLEMA, Y. H. SCHUKKEN, H. W. BARKEMA, F. A. RIJSEWIJK, J. T. VAN OIRSCHOT, G. H. WENTINK (1997): Sheep do not play a major role in bovine herpesvirus-1 transmission. *Vet. Microbiol.* 57, 41-54.
- HAINES, D. M., B. J. CHELACK (1991): Technical considerations for developing enzyme immunohistochemical staining procedures on formalin-fixed paraffin-embedded tissues for diagnostic pathology. *J. Vet. Diagn. Invest.* 3, 101-112.
- JESSETT, D. M., C. S. RAMPTON (1975): The incidence of antibody to infectious bovine rhinotracheitis virus in Kenyan cattle. *Res. Vet. Sci.* 18, 225-226.
- JERICO, K. W. F. (1983): Histological changes in the respiratory tract of calves exposed to aerosols of bovine herpesvirus 1 and *Pasteurella haemolytica*. *J. Comp. Pathol.* 93, 73-82.
- JETTEUR, P., E. THIRY, P. P. PASTORET (1990): Serological survey concerning the IBR, CHV2, BVD, PI3, BRS and rinderpest viruses in small ruminants in Zaire. *Rev. Elev. Med. Vet. Pays Trop.* 43, 435-437.
- LEHMKUHL, H. D., R. C. CUTLIP, S. R. BOLIN, K. A. BROGDEN (1985): Seroepidemiologic survey for antibodies to selected viruses in the respiratory tract of lambs. *Am. J. Vet. Res.* 46, 2601-2604.
- LEHMKUHL, H. D., R. C. CUTLIP, K. A. BROGDEN (1993): Seroepidemiologic survey for adenovirus infection in lambs. *Am. J. Vet. Res.* 54, 1277-1279.
- LEHMKUHL, H. D., R. C. CUTLIP, J. T. MEEHAN, B. M. DEBEY (1997): Pathogenesis of infection induced by an adenovirus isolated from a goat. *Am. J. Vet. Res.* 58, 608-611.
- MAHMOUD, M. A., S. A. AHMED (2009): Prevalence of bovine herpes virus-1 in sheep and goats in Egypt. *Global Vet.* 3, 472-479.
- MAURICE, Y., A. PROVOST (1970): Essai d'infection des chevres tchadiennes par le virus de la rhinotracheite infectieuse bovine. Enquete serologique dans l'Ouest Tchadien. *Rev. Elev. Med. Vet. Pays Trop.* 23, 419-423.
- MOHANTY, S. B., M. G. LILLIE, N. P. CORSELIUS, J. D. BECK (1972): Natural infection with Infectious bovine rhinotracheitis virus in goats. *J. Am. Vet. Med. Assoc.* 160, 879-880.
- NARITA, M., M. YAMADA, T. TSUBOI, K. KAWASHIMA (2003): Bovine Adenovirus Type 3 Pneumonia in Dexamethasone-treated Calves. *Vet. Pathol.* 40, 128-135.
- NARITA, M., K. KIMURA, N. TANIMURA, T. TSUBOI (2000): Pneumonia induced by endobronchial inoculation of calves with bovine herpesvirus 1. *J. Comp. Pathol.* 122, 185-192.

A. O. Çeribası et al.: Bovine herpesvirus type 1 and bovine adenovirus type 3 in pneumonic sheep and goats

- NETTLETON, F., J. A. HERRING, A. J. HERRING (1983): Evaluation of an immunofluorescent test for the rapid diagnosis of field infections of infectious bovine rhinotracheitis. *Vet. Rec.* 112, 298-300.
- OKUR GUMUSOVA, S., Y. AKCA (2002): Survey for antibodies against to ovine adenoviruses (OAV-1,2,3,5) and bovine adenoviruses (BAV-1,2,3) in goats of Marmara region. *Vet. J. Ankara Univ.* 49, 125-128.
- OKUR GUMUSOVA, S., Z. YAZICI, H. ALBAYRAK, D. CAKIROGLU (2007): Seroprevalence of bovine viral respiratory diseases. *Acta Vet. (Beograd)* 57, 11-16.
- RUSHTON, B., J. M. SHARP (1977): Pathology of ovine adenovirus type 4 infection in SPF lambs: pulmonary and hepatic lesions. *J. Pathol.* 121, 163-167.
- SHANKAR, H., M. P. YADAV (1987): Experimental infection of sheep with BHV-1 (IBR/IPV virus) and its possible role in epizootiology. *Indian Vet. Med. J.* 11, 71-76.
- SHARP, J. M., P. F. NETTLETON (2007): Acute respiratory virus infections. In: *Diseases of Sheep*. (Aitken I. D., Ed.), Blackwell Publishing, pp. 207-208.
- SIX, A., M. BANKS, M. ENGELS, C. ROS BASCUNANA, M. ACKERMAN (2001): Latency and reactivation of bovine herpesvirus 1 (BHV-1) in goats and of caprine herpesvirus 1 (CapHV-1) in calves. *Arch. Virol.* 146, 1325-1335.
- STEVENSON, R. G. (1969): Immunofluorescence studies of parainfluenza 3 virus in the lungs of lambs. *J. Comp. Pathol.* 79, 483-490.
- SURESH, P., T. SURIBABU (1993): Serological survey of bovine herpesvirus 1 (BHV-1) in sheep in Andhra Pradesh. *Indian J. Anim. Sci.* 63, 146-147.
- TAYLOR W. P., A. N. C. OKEKE, N. N. SHIDALI (1977): Prevalence of bovine viral diarrhea and infectious bovine rhinotracheitis antibodies in Nigerian sheep and goats. *Trop. Anim. Health Prod.* 9, 171-175.
- THIRY, J., V. KEUSER, B. MUYLKENS, F. MEURENS, S. GOGEV, A. VANDERPLASSCHEN, E. THIRY (2006): Ruminant alphaherpesviruses related to bovine herpesvirus 1. *Vet. Res.* 37, 169-190.
- TOLARI, F., H. WHITE, P. NIXON (1990): Isolation and reactivation of bovid herpesvirus 1 in goats. *Microbiol.* 13, 67-71.
- TRUEBLOOD, M. S., B. L. SWIFT, L. McHOLLAND RAYMOND (1978): A bovine Herpesvirus isolated from sheep. *Can. J. Comp. Med.* 42, 97-99.
- TURY, E., S. BELL, V. PALFI, T. SZEKERES (1978): Experimental infection of calves with an adenovirus isolated from sheep and related to bovine adenovirus type 2. II. pathological and histopathological studies. *Zbl. Vet. Med. B.* 25, 45-51.
- WAFULA, J. S., E. Z. MUSHI, H. WAMWAYI (1985): Reaction of goats to infection with infectious bovine rhinotracheitis virus. *Res. Vet. Sci.* 39, 84-86.
- WHETSTONE, C. A., J. F. EVERMANN (1988): Characterization of bovine herpesviruses isolated from six sheep and four goats by restriction endonucleases analysis and radioimmunoprecipitation. *Am. J. Vet. Res.* 49, 781-785.

A. O. Çeribası et al.: Bovine herpesvirus type 1 and bovine adenovirus type 3 in pneumonic sheep and goats

YESILBAG, K., S. DAGALP-BILGE (2006): Seroprevalance of bovine herpesvirus 1 infection in sheep in Turkey. *Vet. J. Ankara Univ.* 53, 141-143.

YESILBAG, K., S. DAGALP, S. OKUR GUMUSOVA, B. GUNGOR (2003): Studies on herpesvirus infections of goats in Turkey: prevalence of antibodies to bovine herpesvirus 1. *Revue Med. Vet.* 154, 772-774.

YESILBAG, K., S. DAGALP-BILGE (2003): Small Ruminants: A Source of Bovine Herpesvirus 1 (BHV1) for cattle. *Rumin. Sci.* 1, 1-4.

Received: 11 August 2014

Accepted: 10 August 2015

---

**ÇERIBASI, A. O., S. ÇERIBASI, M. OZKARACA: Imunohistokemijski dokaz antigena govedeg herpesvirusa 1 i govedeg adenovirusa 3 u smrznutim i parafiniranim rezovima pluća u pneumoničnim ovnova i jaraca uzgojenih za klanje. *Vet. arhiv* 86, 9-21, 2016.**

**SAŽETAK**

Cilj ovog istraživanja bio je dokazati antigene govedeg adenovirusa 3 i govedeg herpesvirusa 1 izravnom imunofluorescencijom i imunoperoksidaznim testom u smrznutom i formalinom fiksiranom te u parafin uklopljenom tkivu pluća pneumoničnih ovnova i jaraca uzgojenih za klanje. Pretraženo je tkivo pluća od 1276 ovnova i 1087 jaraca, uzgajanih na različitim farmama na području Elaziga i okolice te dovedenih na klanje između siječnja i prosinca 2011. Upala pluća dokazana je makroskopski samo u apikalnim i kardijalnim režnjevima 132 ovna i 145 jaraca. Blaga konsolidacija dokazana je u 57,5 %, srednje jaka u 29,5 % te jaka u 12,8 % ovnova, dok je u 62,0 % jaraca dokazana blaga, 20,0 % srednje jaka te 17,9 % jaka konsolidacija plućnog tkiva. Upala pluća bila je mikroskopski dijagnosticirana kao kataralno-purulentna u 40,1 % ovnova i 33,1 % jaraca, intersticijska u 26,5 % ovnova i 31,7 % jaraca, fibrinozna u 21,2 % ovnova i 26,9 % jaraca, verminozna u 9,4 % ovnova i 6,2 % jaraca te kao plućna adenomatoza u 1,5 % ovnova i 2,0 % jaraca. Imunoperoksidaznim i izravnim fluorescentnim testom na prisutnost antigena za goveđi adenovirus 3 i goveđi herpesvirus 1 bilo je ukupno pretraženo 249 (116 od ovnova i 133 od jaraca) pneumoničnih pluća. U tu brojku nije bila uključena verminozna pneumonija ni plućna adenomatoza. Antigeni za goveđi adenovirus 3 bili su dokazani imunoperoksidaznim testom u 5,1 % ovnova i 0,7 % jaraca, dok su antigeni za goveđi herpesvirus 1 bili dokazani u 1,7 % ovnova i 2,2 % jaraca. Izravnim imunofluorescentnim testom antigeni za goveđi adenovirus 3 bili su dokazani u 9,4 % ovnova i 4,5 % jaraca, dok su antigeni za goveđi herpesvirus 1 bili dokazani u 5,1 % ovnova i 7,5 % jaraca. Prisutnost virusnih antigena u plućnom tkivu ovaca i koza može upućivati na zaključak da u njih upala pluća u terenskim uvjetima može biti uzrokovana goveđim adenovirusom 3 i goveđim herpesvirusom 1 ili nekim drugim adenovirusima i herpesvirusima specifičnima za vrstu. Smatra se da ovce i koze mogu imati određenu ulogu u prijenosu tih virusa na govedo.

**Ključne riječi:** goveđi herpesvirus 1, goveđi adenovirus 3, ovce, koze, pneumonija, imunofluorescencija, imunoperoksidazni test

---



