

## Percutaneous laser disc decompression in a dog - a case report

**Monika Barczewska<sup>1</sup>, Zbigniew Adamiak<sup>2\*</sup>, Andrzej Pomianowski<sup>3</sup>,  
Joanna Głodek<sup>2</sup>, Paulina Przyborowska<sup>2</sup>, Yauheni Zhalniarovich<sup>2</sup>,  
and Wojciech Maksymowicz<sup>1</sup>**

<sup>1</sup>*Department of Neurosurgery, Faculty of Medical Sciences, University of Warmia and Mazury in Olsztyn, Olsztyn, Poland*

<sup>2</sup>*Department of Surgery and Radiology, Faculty of Veterinary Medicine, University of Warmia and Mazury in Olsztyn, Olsztyn, Poland*

<sup>3</sup>*Department of Internal Medicine, Faculty of Veterinary Medicine, University of Warmia and Mazury in Olsztyn, Olsztyn, Poland*

---

**BARCZEWSKA, M., Z. ADAMIAK, A. POMIANOWSKI, J. GŁODEK, P. PRZYBOROWSKA, Y. ZHALNIAROVICH, W. MAKSYMOWICZ: Percutaneous laser disc decompression in a dog - a case report. Vet. arhiv 85, 475-480, 2015.**

### ABSTRACT

Percutaneous laser disc decompression (PLDD) is a minimally invasive technique for treatment of lumbar disc herniation in human medicine. There is little information available concerning PLDD usage in dogs. The article describes treatment of a disc protrusion in a dog with percutaneous laser disc decompression (PLDD). To the authors' knowledge the presented technique is described here for the first time in a dog with thoracolumbar disc herniation. The surgical procedure was performed in a dog with Th13-L1 disc protrusion using a photofiber device, which was inserted into the intervertebral space under C-arm control. The purpose of this report is to evaluate PLDD effectiveness in Hansen type II disc herniation in a dog.

**Key words:** percutaneous laser disc decompression, protrusion, dog

---

### Introduction

There are several percutaneous methods that are used for the treatment of herniated disc. The first one is percutaneous chemonucleolysis. The others are: percutaneous microdiscectomy, percutaneous microendoscopic discectomy, electrothermal nucleoplasty (SATO et al., 2011). The first percutaneous laser disc decompression was performed in

---

\*Corresponding author:

Zbigniew Adamiak, Department of Surgery and Radiology, Faculty of Veterinary Medicine, University of Warmia and Mazury in Olsztyn, ul. Oczapowskiego 14, 10-957 Olsztyn, Poland, E-mail: zbigniew.adamiak@wp.pl

humans with a Yag-Neodymium laser for a herniated nucleus pulposus in the L4-L5 disc space (MAKSYMOWICZ et al., 2004).

The PLDD procedure relies on light energy, which is absorbed by the intervertebral disc. Heated disc tissue is partially vaporized and partially burned. The volume of the nucleus pulposus is decreased to reduce pressure within the disc structure. Consequently, the pressure exerted by the disc on the dural sac and nerve roots is reduced, facilitating the flow of cerebrospinal fluid in the dural sac at the compression site. The use of percutaneous laser disc decompression in the treatment of intervertebral disc protrusion has been scantily documented in veterinary medicine (LEW-KOJRYS et al., 2013).

This case report presents the results of disc protrusion treatment in a dog with the use of PLDD. The detailed rationale of the method, surgical procedures, outcomes and follow up is explained.

#### **Materials and methods**

PLDD was performed in a female mix-breed dog aged 6 years, 18 kg in weight, for neurological symptoms of paraparesis.

The clinical symptoms were indicative of neurological problems in the Th3-L3 region, and they were manifested by pelvic limb acute paresis, impaired proprioception, incoordination and exaggerated spinal reflex in the pelvic limbs, and back pain. Survey lateral and ventrodorsal radiographic examinations of thoracolumbar spine were performed. Somatosensory evoked potential (SSEP) tests were carried out using an electrodiagnostic unit (Viasys Nicolette, USA) and the tibial nerve was stimulated. SSEP recordings were made under anesthesia, using a protocol identical to that applied in MRI. Disposable stainless steel EEG needles were used. The first channel comprised a Cz (negative electrode) needle placed into the frontal lobe region, and a Fpz (positive electrode) needle between the eyes. The second channel was a positive electrode needle positioned between the eyes and a negative electrode needle in the C5 region. The third channel consisted of a pair of needles in the TH13- L1 segment. Fourth channel electrodes were placed in the L7-S1 region. A ground electrode was applied subcutaneously to the fossa subpoplitea. The stimuli for the SSEP recording were square-wave pulses with a duration of 0.2 milliseconds, applied at 8V intensity, generated by a stimulator and initiated by a computer signal. Stimulus intensity was set at a level that evoked clear, visually detectable digital flexion and tarsal extension. After the SSEP test of the left tibial nerve, the patient was turned onto its other side and the procedure was repeated by stimulating the right tibial nerve. The SSEP examination was followed by magnetic resonance imaging (MRI).

The patient was anesthetized using medetomidine at 10 µg/kg i.v. (Sedator, Novartis) and propofol at 3 mg/kg i.v. (Disoprivan, Zeneca), and positioned in sternal recumbency.

A spine coil was used for MR imaging at 0.25 Tesla (Vet Grande, Esaote, Italy). The MRI procedure was performed in both sagittal and transverse planes, using FSE REL (TR 3000, TE 120), and X BONE (TR 970, TE 28) sequences. Protrusion of an intervertebral disc was observed at Th13-L1 level (Fig.1).

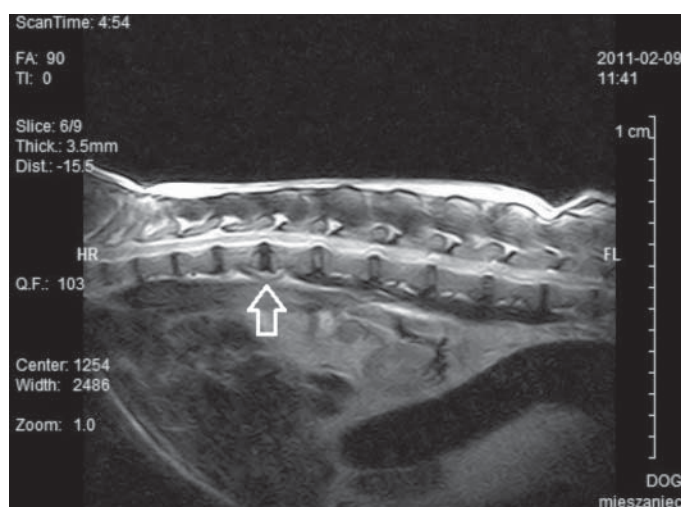


Fig. 1. MR image of Th13-L1 disc protrusion in FSE sequences

For the PLDD surgical procedure, the patient was positioned in sternal recumbency and the operative site was then prepared aseptically. The dog was premedicated with atropine (Atropinum Sulfuricum, WZF Polfa, Warszawa, Poland) at 0.005 mg/kg and medetomidine (Domitor, Pfizer Animal Health, Australia) at 0.02 mg/kg. Anesthesia was maintained with propofol (Plofed, Polfa S.A., Poland) in a bolus at 5 mg/kg of body weight. General inhalatory anesthesia was induced with 1 % isoflurane (Florane®, Baxter, U.S.A). Monitoring of the surgical procedure was conducted using a mobile C-arm intensifier (Luminax X-21, Farum S.A., Poland). At the beginning of surgery the puncture needle was inserted into the Th13-L1 intervertebral space in the treated dog (Fig. 2). During PLDD, a photofiber was implanted in the herniated disc through a puncture needle, using a Medilas D MultiBeam (Dornier, Germany) laser device with output of up to 80 W, and a 980 nm diode. The herniated nucleus pulposus was vaporized. The patient was administered cephalexin at 18 mg/kg i.m. one hour before laser therapy and one day after surgery (Cefalexim, ScanVet, Poland). Additionally, the dog was administered tramadol hydrochloride (Tramal, Polfa, Poland) at 5 mg/kg of body weight in a 150 mL slow fluid infusion for one day after laser surgery. The therapy was continued with tramadol hydrochloride (Tramal, Polfa, Poland), administered intramuscularly over the next three days.

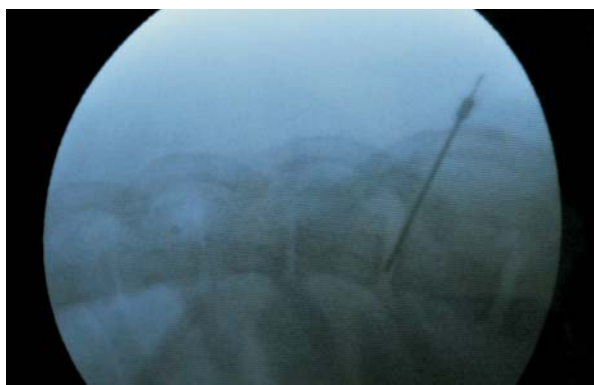

Fig. 2. C-arm image of implanted photofiber in the Th13-L1 herniated disc

In the treated dog, neurological symptoms were eliminated as the result of PLDD. Pain and ataxia subsided on the second day after surgery. Voluntary motor function and normal pain responses returned within two weeks. The results of clinical and neurological tests were consistent with SSEP readings. Before surgical treatment, recorded waveforms were reduced. When the SSEP waveforms were registered two days after treatment, their latencies were shorter and amplitudes increased. Moreover, the SSEP test repeated two days after surgery demonstrated the functional integrity of afferent pathways of the spinal cord, thus verifying the effectiveness of the applied surgical technique (Fig. 3).

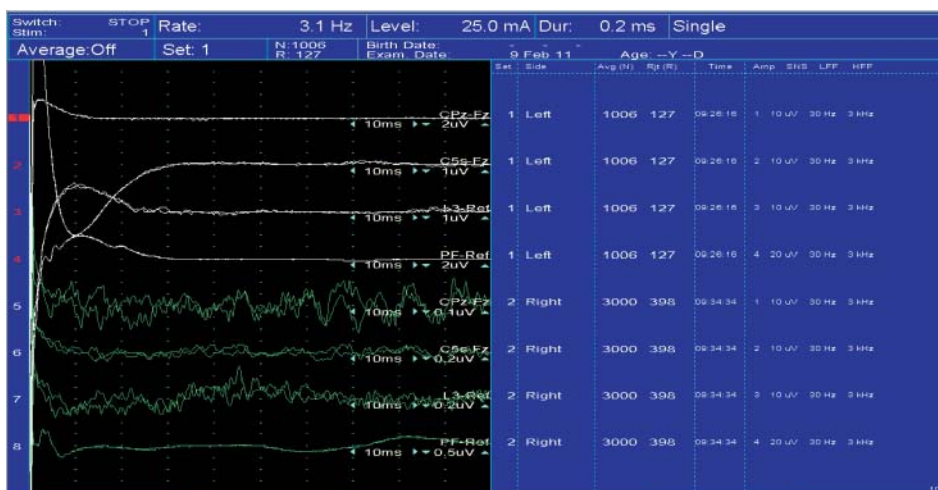


Fig. 3. The SSEP test image two days after surgery, demonstrated the functional integrity of afferent pathways of the spinal cord

### Discussion

Studies in human medicine seem to suggest that the mechanism of PLDD's therapeutic efficacy limits its scope of application. PLDD may offer an alternative to conventional surgery by eliminating the pressure exerted by a herniated disc without disc sequestration. The absolute and relative contraindications for the treatment of lumbar discopathy by PLDD include the presence of dislocated fragments of nucleus pulposus in the spinal canal, coagulation disorders, bacterial infections (such as discospondylitis), disc extrusion with observations of ruptured anulus fibrosus on MRI, free fragments of the nucleus pulposus, disc herniation in the lateral recess of the spinal canal, significant narrowing of the intervertebral disc space, lack of improvement after open disc surgery, severe circulatory and respiratory failure (MAKSYMOWICZ et al., 2004; HIRSCH et al., 2009). In veterinary surgery hemilaminectomy, mini-hemilaminectomy, pediculectomy are the gold standard for thoracolumbar disc disease. The proposed PLDD technique may be an option for a minimal invasive procedure in the therapy of a disc protrusion.

### Conclusion

PLDD is a minimally invasive surgical technique, which delivers effective treatment for disc protrusion. The described neurosurgical procedure is widely applied in human medicine, and this technique may be transposed to veterinary practice. PLDD may be performed throughout the entire spine, with the exception of the Th1-Th4 thoracic discs, which do not permit percutaneous access with a needle (CHOY et al., 2009). In this experiment, the positive outcomes of PLDD do not support the formulation of general conclusions regarding its efficacy (MENCHETTI et al., 2011). Due to the scant data related to the use of PLDD in the presented dog, further work is needed to determine the discussed technique's usefulness for the treatment of disc herniation in canines.

### References

- CHOY, D. S. J., G. P. TASSI, J. HELLINGER, S. HELLINGER, S. H. LEE (2009): Twenty-three years of percutaneous laser disc decompression (PLDD) - State of the art and future prospects. *Med. Laser Appl.* 24, 147-157.
- HIRSCH, J. A., V. SINGH, F. J. FALCO, R. M. BENYAMIN, L. MANCHIKANTI (2009): Automated percutaneous lumbar discectomy for contained herniated lumbar disc: a systematic assessment of evidence. *Pain Physician* 12, 601-629.
- LEW-KOJRYŚ, S., Z. ADAMIAK, A. POMIANOWSKI, W. MAKSYMOWICZ, M. BARCZEWSKA, A. MAJCHROWSKI (2013): Percutaneous laser disc decompression in the treatment of detrusor-urethral dyssynergia in a female German Shepherd: a case report. *Veterinarni Medicina* 58, 327-330.
- MAKSYMOWICZ, W., M. BARCZEWSKA, A. SOBIERAJ (2004): Percutaneous laser lumbar disc decompression - mechanism of activity, recommendation and contraindication. *Ortopedia Traumatologia Rehabilitacja* 6, 314-318. (in Polish)

MENCHETTI, P. P., G. CANERO, W. BINI (2011): Percutaneous laser discectomy: experience and long term follow-up. *Acta Neurochirurgica* 108, 117-121.

SATO, M., M. ISHIHARA, M. KIKUCHI, J. MOCHIDA (2011): The influence of Ho: YAG laser irradiation on intervertebral disc cells. *Laser Surg. Med.* 43, 921-926.

Received: 1 June 2014

Accepted: 25 November 2014

---

**BARCZEWSKA, M., Z. ADAMIAK, A. POMIANOWSKI, J. GŁODEK, P. PRZYBOROWSKA, Y. ZHALNIAROVICH, W. MAKSYMOWICZ: Perkutana laserska dekompresija diska u psa - prikaz slučaja. *Vet. arhiv* 85, 475-480, 2015.**

**SAŽETAK**

Perkutana laserska dekompresija diska (PLDD) minimalno je invazivna tehnika za liječenje hernije lumbalnog diska u humanoj medicine. Ima malo informacija o upotrebi PLDD u pasa. U članku je opisano liječenje protruzije diska perkutanom laserskom dekompresijom u psa. U ovom radu ta je tehnika prvi put opisana u psa s hernijacijom torakolumbalnog diska. Kirurški zahvat proveden je na psu s protruzijom Th13-L1 diska upotrebom aparata pomoću kojeg se laserska zraka optičkom niti uvede kroz tanku iglu u intervertebralni prostor pod rendgenskom kontrolom. Svrha je ovog izvješća procijeniti učinkovitost PLDD kod II. stupnja hernijacije po Hansenu u psa.

**Ključne riječi:** perkutana laserska dekompresija, protruzija, pas

---