

## Myocarditis associated with foot-and-mouth disease in suckling calves

Mustafa S. Aktas<sup>1\*</sup>, Yunusemre Ozkanlar<sup>1</sup>, Ertan Oruc<sup>2</sup>,  
Ibrahim Sozdutmaz<sup>3</sup>, and Akin Kirbas<sup>1</sup>

<sup>1</sup>Department of Internal Medicine, Faculty of Veterinary Medicine, Ataturk University, Erzurum, Turkey

<sup>2</sup>Department of Pathology, Faculty of Veterinary Medicine, Ataturk University, Erzurum, Turkey

<sup>3</sup>Department of Virology, Faculty of Veterinary Medicine, Erciyes University, Kayseri, Turkey

---

**AKTAS, M. S., Y. OZKANLAR, E. ORUC, I. SOZDUTMAZ, A. KIRBAS:**  
**Myocarditis associated with foot-and-mouth disease in suckling calves. Vet. arhiv**  
**85, 273-282, 2015.**

### ABSTRACT

Foot-and-mouth disease (FMD) can lead to myocarditis in young animals, but the age distributions of calves with myocarditis have not been described, nor the biochemical profile in these calves. In an area endemic with foot-and-mouth disease, calves less than 6 months of age in infected farms were examined for clinical lesions and abnormalities in respiratory rate, heart rate and heart rhythm. In total, 53 calves were identified to be suspected of having foot-and-mouth disease infection. In 6 calves myocarditis was suspected based on tachypnea, tachycardia and gallop rhythm. In these 6 calves, cardiac troponin-I (cTnI) and aspartate aminotransferase (AST) were significantly higher ( $P < 0.0001$ ), but the levels of Creatinine Kinase MB (CK-MB) and Lactate dehydrogenase (LDH) were not. These 6 calves died within 2 days and histopathology confirmed myocarditis. All calves with myocarditis were younger than 2-months old, suggesting that myocarditis caused by FMD is mainly found in very young suckling calves.

**Key words:** foot and mouth diseases, myocarditis, suckling calves

---

### Introduction

Foot and mouth disease (FMD) is a highly contagious vesicular disease affecting a number of domestic and wild cloven-hoofed mammals (SAMUEL and KNOWLES, 2001). FMD is an enzootic disease, seen in most large areas of the world (BARKER et al., 1993). The etiological agent, foot and mouth disease virus (FMDV) is classified within the *Aphthovirus* genus of the *Picornaviridae* family. Seven distinct serotypes (A, O, C,

---

\*Corresponding author:

Assoc. Prof. Dr. Mustafa Sinan Aktas (DVM, PhD), Department of Internal Medicine, Faculty of Veterinary Medicine, Ataturk University, 25240, Erzurum, Turkey, Phone: +90 442 231 55 30; Fax: +90 442 232 55 63; E-mail: sinanaktas@atauni.edu.tr

Asia 1, and South African Territories 1, 2, and 3) have been identified serologically, and multiple subtypes occur within each serotype (BACHRACH, 1968).

FMD is characterized by vesicular lesions on the tongue, feet, snout, and teats, including fever and lameness (DONALDSON and SELLERS, 2000). The disease is notorious for its high morbidity but is not notable for high mortality, except in suckling animals (BARKER et al., 1993). The mortality rate is about 5 % in adult ruminants but the rate can be boosted up to 50 % by myocardial damage in young animals (BARKER et al., 1993). In calves, myocarditis is considered a fatal form of FMD that occurs without developing the characteristic blister lesions noted in adult cattle (BARKER et al., 1993; ALEXANDERSEN et al., 2003). The acute myocarditis of young animals is distinguished by hyaline degeneration, necrosis of muscle fibers and an intense infiltration mainly of lymphocytes (ALEXANDERSEN et al., 2003).

Diagnosis of myocardial disease in cattle remains challenging and is based upon physical examination, cardiac auscultation, and the incidence of sudden death in the field. However, there are many biomarkers for myocardial injury, such as creatine kinase myocardial band (CK-MB), lactate dehydrogenase (LDH) and aspartate aminotransferase (AST) (JAFJE et al., 1996). Still, effective use of these enzymes is limited because of the lack of tissue specificity and sensitivity (O'BRIEN, 2008). The best cardiac biomarkers for myocardial damage are cardiac troponins, especially cardiac troponin-I (cTnI), because it has nearly absolute myocardial tissue specificity and higher sensitivity than CK-MB, LDH, and AST (WEBER et al., 2005). Furthermore, cTnI is the only troponin uniquely expressed in the myocardium (HASTINGS, 1997).

A higher occurrence risk of myocarditis induced by FMD is currently known in young animals than in older ones (ALEXANDERSEN et al., 2003; GUNES et al., 2005; GULBAHAR et al., 2007; KARAPINAR et al., 2010). However, no study has particularly evaluated the contributing factors of myocarditis and age for mortality risk. In this study, the aim was to determine the risk factors related to age for the development of myocarditis in FMD in the calves younger than 6 months old. Findings of clinical, histopathological and biochemical markers were also evaluated in calves with myocarditis.

### **Materials and methods**

*Animals and study design.* Fifty-three calves under 6 months of age and suspected clinically for FMD were included in this study. All FMD cases were reported to the veterinary office of animal health and control of the Erzurum province, in accordance with the regulations of the country. After recording anamnesis and clinical signs, the calves were divided into 3 groups, aging  $\leq 2$  months ( $n = 8$ ),  $>2-\leq 4$  months ( $n = 23$ ) and  $>4-\leq 6$  months old ( $n = 22$ ). The calves were alternatively divided into 2 groups, including those clinically suspect for myocarditis ( $n = 6$ ) and non-myocarditis ( $n = 47$ ). Twelve

healthy calves were also used as control groups, aging  $\leq 2$  months,  $>2$ - $\leq 4$  months and  $>4$ - $\leq 6$  months old, with four animals in each group.

Blood samples were collected from the diseased and control calves. 10 mL blood samples were collected by venepuncture of the v. jugularis, into collection tubes (BD Vacutainer System, Plymouth, UK). The samples of serum were obtained by centrifugation at 3,000 g for 15 min at 4 °C, and stored at -20 °C until analysis. All the animal samples were analyzed at the same time.

*Virus isolation and identification.* Blood samples collected from cases for disease confirmation and serotyping were analyzed using the reverse transcriptase polymerase chain reaction (RT-PCR) method. Total RNA was extracted from EDTA-mixed whole blood using TRIzol Reagent (Invitrogen), following the manufacturer's instructions. After RNA was extracted from the blood, RT-PCR was performed for serotype identification of FMDV, with specific primers described previously (SHIN et al., 2003).

*Serum biochemistry.* The concentrations of serum CK-MB, AST, and LDH were determined using an automatic biochemical analyzer as directed by the manufacturer's guides (Cobas 6000 analyzer, Roche). All cTnI values were measured following the manufacturer's guidelines, using the VIDAS Troponin I Ultrassay (Biomerix, Marcy L'Etoile, France).

*Histopathology.* The hearts obtained from dead calves were histopathologically examined in the pathology laboratory of the Faculty of Veterinary Medicine, Ataturk University, Turkey. Tissue samples were fixed in 10 % formalin solutions. Processing the histopathology through alcohol-xylol, 5- $\mu$  serial sections of paraffin blocks were prepared and stained with haematoxylin-eosin (H&E) for light microscopy.

*Statistical analyses.* Data from the serum concentrations of CK-MB, AST, LDH, and cTnI were analyzed by one-way analysis of variance (ANOVA) using the MINITAB statistical software program (Release 11.2; MINITAB Inc., Pennsylvania, USA). Values were represented as the mean  $\pm$  SEM. Differences between CK-MB, AST, LDH, and cTnI levels of groups were considered significant when  $P < 0.05$ .

## Results

All samples of the calves clinically suspect for FMD were identified as FMDV serotype O with RT-PCR. The clinical findings and ages of calves with non-myocarditis, myocarditis, and control groups are presented in Table 1.

Table 1. Clinical findings and ages of calves in groups.

Parameters	Control (n = 12)	With FMD	
		Myocarditis (n = 6)	Non-myocarditis (n = 47)
High temperature (>40.5 °C)	-	+ (n = 6)	+ (n = 32); - (n = 15)
Tachypnea (>50 breaths per min)	-	+ (n = 6)	-
Tachycardia (>100 beats per min)	-	+ (n = 6)	-
Gallop rhythm	-	+ (n = 6)	-
Lesions of FMD only on the mouth	-	+ (n = 1)	+ (n = 2)
Lesions of FMD only on the foot	-	-	+ (n = 1)
Lesions of FMD on both foot and mouth	-	-	+ (n = 44)
Age (month)	≤ 2	4	6
	>2-≤4	4	-
	>4-≤6	4	-

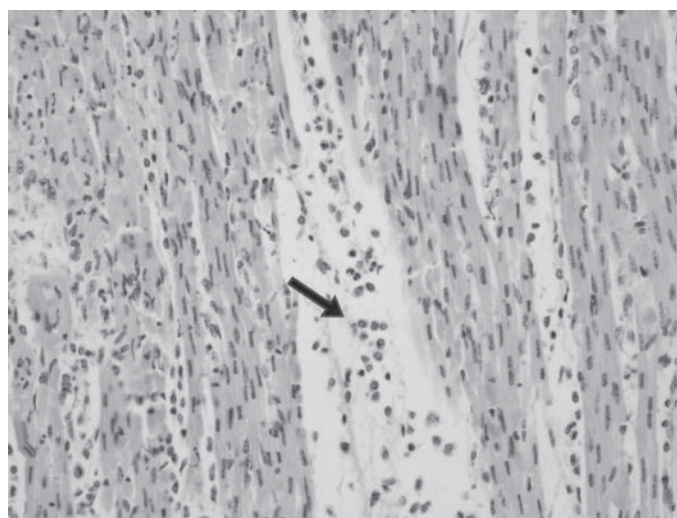


Fig. 1. Interstitial mononuclear cell infiltration composed of lymphocytes, histiocytes and plasma cells (arrow). H&E.

In the calves diagnosed with non-myocarditis with FMD, clinical symptoms of anorexia, apathia and fever (>40.5 °C) were determined in some, and vesicular lesions on the feet and/or mouths in all. In the calves diagnosed as myocarditis with FMD under 2 months old, the symptoms were fever, tachypnea (>50 breaths per min), tachycardia

(>100 beats per min) and arrhythmia. However, no clinical symptoms for FMD were observed, except in one animal in this group. In the anamnesis, there were adult animals showing clinical symptoms of FMD in the same barns with those calves. The animals suspected clinically of myocarditis were submitted to the clinic after they became ill in the previous 24 hours. Of the calves under 2 months old, two died on the day of referral and four died 1 day after referral. As a result of gross examination of the hearts of the dead animals, multifocal white foci were observed on the myocardium. Interstitial mononuclear cell infiltration, composed of lymphocytes, histiocytes, plasma cells and few neutrophil leucocytes, was detected in the histopathology examination of the heart tissue sections. There was hyaline degeneration and necrosis on the myocardiocytes.

On biochemical examination, comparisons were made between the data in the groups (non-myocarditis, myocarditis and control). It was determined that mean levels of serum cTnI and AST were significantly higher ( $P < 0.0001$ ) in the myocarditis group than the non-myocarditis and control groups. There was no statistical difference between the non-myocarditis and control groups for cTnI and AST. There was no statistical difference between the groups for CK-MB and LDH levels, either. Serum parameters of CK-MB, LDH, AST, and cTnI are presented in Table 2.

Table 2. Biochemical findings of calves in groups

Parameters	Control (n = 12)	With FMD		Significance
		Myocarditis (n = 6)	Non-myocarditis (n = 47)	
cTn-I ( $\mu\text{g/L}$ )	0.05 $\pm$ 0.10	11.48 $\pm$ 0.67	0.03 $\pm$ 0.06	$P < 0.0001$
AST (U/L)	68.25 $\pm$ 17.63	265.60 $\pm$ 11.26	84.87 $\pm$ 51.82	$P < 0.0001$
CK-MB (U/L)	222.50 $\pm$ 87.17	178.60 $\pm$ 8.82	232.16 $\pm$ 135.37	N.S.
LDH (U/L)	1036.33 $\pm$ 256.59	1411.40 $\pm$ 50.92	1072.93 $\pm$ 274.54	N.S

NS: not significant.

### Discussion

Myocarditis of ruminants is a myocardial inflammation caused by bacterial, viral or parasitic organisms (*Staphylococcus aureus*, *Clostridium chauvoei*, *Mycobacterium* species, foot and mouth disease, Toxoplasmosis and Cysticercosis or Sarcocystic infection) (SMITH, 2009). FMD does not result in high mortality in adult animals, but acute severe myocardial injury may result in death particularly in neonates (ALEXANDERSEN et al., 2003). The present study describes the clinical findings, the biochemistry markers of myocardial cell damage, and age-related myocarditis rates induced by FMD for calves under 6 months old.

Regarding clinical appearance, blistering lesions are characteristic for FMD in adult cattle and acute severe myocardial injury in neonates (ALEXANDERSEN et al., 2003). In agreement with previous reports (TUNCA et al., 2008; KARAPINAR et al., 2010), in this study, the characteristic lesions were not seen in any of the calves in the myocarditis group due to FMD, except for one animal. One possible reason may be the myocardial affinity to the developing heart muscle cells of the virus, causing fatal outcome before vesicular lesions occur on the feet, hooves or mouth. Additionally, ALEXANDERSEN et al. (2003) reported that the symptoms and severity of FMD vary between breeds of animal and sometimes within a breed, probably because of the serotype and strain of the virus, genetic or physiological factors. Clinical findings of fever, raised heart and respiratory rates and murmur have also been reported in cases of myocarditis due to FMD, as seen in this study (TUNCA et al., 2008; KARAPINAR et al., 2010). Therefore, these findings demonstrate the clinical characteristics of circulatory insufficiency caused by myocarditis.

In cattle recovered from FMD disease, although virus shedding ceases within two weeks, in some cases it may be prolonged up to 6-24 months and, presumably, these animals may act as source virus at the start of an epidemic outcome (VAN BEKKUM et al., 1959). According to our personal observations in the field, although no cases showing clinical symptoms for FMD were seen in any animal housed in the same barns with the calves, the sudden calf deaths due to myocarditis occurred due to FMD. Detailed histopathology revealed the myocardial form of FMD as well as a history of the occurrence of the disease almost 1 year before in the adult animals reared in those barns. Both the presence of FMD and myocarditis should be confirmed on the basis of virology, detection of some biochemical markers in the blood and histology. In the present study, all samples from the sick calves were found to be positive for FMDV by RT-PCR analysis. Histological findings in dead animals were hyaline degeneration, myocardial necrosis, and intense mononuclear cell infiltration, consistent with the results of other studies (GUNES et al., 2005; KARAPINAR et al., 2010).

Serum cardiac troponins may be determined during myocardial damage as the earliest appearing biochemical markers (BOCCARA et al., 2000). Of the cardiac troponin proteins, cTnI is very low or below the level of detectability in most assays and is released into the circulation because of leakage from the damaged myocardial cells (O'BRIEN et al., 1997). Detection of cTnI in humans and various animal species, including cats, dogs, horse and sheep, serves as an indicator of myocardial injury (KORFF et al., 2006; LEONARDI et al., 2008). Additionally, idiopathic pericarditis, traumatic reticuloperitonitis, experimentally induced endotoxemia in cattle, and foot and mouth disease in calves have been reported to cause increased concentrations of circulating cTnI (GUNES et al., 2008; PEEK et al., 2008; TUNCA et al., 2008). In the present study, serum cTnI concentrations in the calves with myocarditis were considerably higher than the values obtained from the non-myocarditis

and healthy calves. These results were supported by the degeneration, necrosis and dispersion of the myocardiocytes on the histopathologic section.

In humans, after the initiation of acute cardiac injury, serum CK-MB concentration peaks at the 24<sup>th</sup> hour and serum LDH at the 48<sup>th</sup>-72<sup>nd</sup> hours (VARLEY et al., 1984), while cardiac troponin starts to increase at the 3<sup>rd</sup>-4<sup>th</sup> hours and peaks at the 12<sup>th</sup> hour (ADAMS et al., 1994). Therefore, it is reported that CK-MB levels, as a marker of myocardial cell damage, are often within the normal range during the very early stage of myocarditis (SMITH et al., 1997). In calves, there has not been any report with regard to the stages of the disease. In this study, it can be suggested that the stage of the disease is very early because of the increased concentration of cTnI and normal levels of CK-MB and LDH in the myocarditis group compared to the other groups. This suggestion is supported by the anamnesis that the animals were referred within 24 hours after first clinical signs appeared. Serum AST concentration was higher in the animals with myocarditis than the non-myocarditis and control groups. The increases in AST level can be seen in several abnormalities, such as liver, muscle and heart diseases. It can be recognized that the increased level of AST is related to myocarditis with respect to the increased level of cTnI.

Regarding the pathogenesis of the disease, FMDV receptors, as well as other picornavirus receptors, may play a role in tissue and organ tropism (SCHNEIDER-SCHAULIES, 2000). FMDV entry into cells *in vivo* is believed to involve the attachment of the RGD loop of VP1 on the viral capsid to host integrins, such as  $\alpha v\beta 1$ ,  $\alpha v\beta 3$ ,  $\alpha v\beta 5$ , or  $\alpha v\beta 6$  on the surface of target cells (JACKSON et al., 2000; JACKSON et al., 2002). Age-associated changes occur in the cardiac matrix and integrins of the heart (BURGESS et al., 2001). Until now, many myocarditis cases due to FMD have been reported in calves and lambs one week to three months old (GULBAHAR et al., 2007; KARAPINAR et al., 2010; ASLANI et al., 2013; KAYA et al., 2013). In this study, all myocarditis cases of FMD were under 2 months old, suggesting age-associated changes in the cardiac matrix and integrins.

In conclusion, the results of this study suggest that vesicular lesions, characteristic clinical findings of FMD, could not be observed in many cases of myocarditis induced by FMDV in calves. The detection of cTnI is a very sensitive method of determining myocardial cell damage in the earlier stages of the disease. The risk of myocarditis to FMDV is directly related to the age and is higher in calves under 2 months old.

### References

- ADAMS, J. E., K. B. SCHECHTMAN, Y. LANDT, J. H. LADENSON, A. S. JAFFE (1994): Comparable detection of acute myocardial infarction by creatine kinase MB isoenzyme and cardiac troponin I. *Clin Chem.* 40, 1291-1295.



- ALEXANDERSEN, S., Z. ZHANG, A. I. DONALDSON, A. J. M. GARLAND (2003): The pathogenesis and diagnosis of foot-and-mouth disease. *J. Comp. Pathol.* 129, 1-36.
- ASLANI, M. R., M. MOHRİ, A. R. MOVASSAGHI (2013): Serum troponin I as an indicator of myocarditis in lambs affected with foot and mouth disease. *Vet. Res. Forum* 4, 59-62.
- BACHRACH, H. L. (1968): Foot-and-mouth disease. *Ann. Rev. Microbiol.* 22, 201-244.
- BARKER, I. K., A. A. VAN DREUMEL, N. PALMER (1993): The alimentary system. In: *Pathology of Domestic Animals*, 4<sup>th</sup> ed. (Jubb, K. V. F., P. C. Kennedy, N. Palmer, Eds.). Academic Press, San Diego, CA. pp.141-144.
- BOCCARA, G., Y. POUZERATTE, R. TRONCIN, A. BONARDET, A. M. BOULARAN, P. COLSON, C. MANN (2000): The risk of cardiac injury during laparoscopic fundoplication, cardiac troponin I and ECG study. *Acta Anaesthesiol. Scand.* 44, 398-402.
- BURGESS, M. L., J. C. McCREA, H. L. HEDRICK (2001): Age-associated changes in cardiac matrix and integrins. *Mech. Ageing. Dev.* 122, 1739-1756.
- DONALDSON, A. I., R. F. SELLERS (2000): Foot-and-mouth disease. In: *Diseases of Sheep*. (Martin, W. N., I. D. Aitken, Eds). Blackwell Science, Oxford, United Kingdom. pp. 254-258.
- GULBAHAR, M. Y., W. C. DAVIS, T. GUVENC, M. YARIM, U. PARLAK, Y. B. KABAK (2007): Myocarditis associated with foot-and-mouth disease virus type o in lambs. *Vet. Pathol.* 44, 589-599.
- GUNES, V., H. M. ERDOGAN, M. CITIL, K. OZCAN (2005): Assay of cardiac troponins in the diagnosis of myocardial degeneration due to foot-and-mouth disease in a calf. *Vet. Rec.* 156, 714-715.
- GUNES, V., G. ATALAN, M. CITIL, H. M. ERDOGAN (2008): Use of cardiac troponin kits for the qualitative determination of myocardial cell damage due to traumatic reticuloperitonitis in cattle. *Vet. Rec.* 162, 514-517.
- HASTINGS, K. E. (1997): Molecular evolution of the vertebrate troponin I gene family. *Cell Struct. Funct.* 22, 205-211.
- JACKSON, T., A. P. MOULD, D. SHEPPARD, A. M. KING (2002): Integrin avb1 is a receptor for foot-and-mouth disease virus. *J. Virol.* 76, 935-941.
- JACKSON, T., D. SHEPPARD, M. DENYER, W. BLAKEMORE, A. M. KING (2000): The epithelial integrin avb6 is a receptor for foot-and-mouth disease virus. *J. Virol.* 74, 4949-4956.
- JAFFE, A. S., Y. LANDT, C. A. PARVIN, D. R. ABENDSCHEIN, E. M. GELTMAN, J. H. LADENSON (1996): Comparative sensitivity of cardiac troponin I and lactate dehydrogenase isoenzymes for diagnosing acute myocardial infarction. *Clin. Chem.* 42, 1770-1776.
- KARAPINAR, T., D. O. DABAK, T. KULOGLU, H. BULUT (2010): High cardiac troponin I plasma concentration in a calf with myocarditis. *Can. Vet. J.* 51, 397-399.
- KAYA, A., S. KOZAT, C. OZKAN, S. YILDIRIM, Y. AKGUL, O. AKGUL (2013): Serum homocysteine levels in calves with foot and mouth disease. *JAVA.* 12, 1357-1361.
- KORFF, S., H. A. KATUS, E. GIANNITSIS (2006): Differential diagnosis of elevated troponins. *Heart.* 92, 987-993.



- LEONARDI, F., B. PASSERI, A. FUSSARI, P. DE RAZZA, C. BEGHI, R. LORUSSO, A. CORRADI, P. BOTTI (2008): Cardiac troponin I (cTnI) concentration in an ovine model of myocardial ischemia. *Res. Vet. Sci.* 85, 141-144.
- O'BRIEN, P. J., Y. LANDT, J. H. LADENSON (1997): Differential reactivity of cardiac and skeletal muscle from various species in a cardiac troponin I immunoassay. *Clin. Chem.* 43, 2333-2338.
- O'BRIEN, P. J. (2008): Cardiac troponin is the most effective translational safety biomarker for myocardial injury in cardiotoxicity. *Toxicol.* 245, 206-218.
- PEEK, S. F, F. S. APPLE, M. A. MURAKAMI, P. M. CRUMP, S. D. SEMRAD (2008): Cardiac isoenzymes in healthy Holstein calves and calves with experimentally induced endotoxemia. *Can. J. Vet. Res.* 72, 356-361.
- SAMUEL, A. R., N. J. KNOWLES (2001): Foot-and-mouth disease virus: cause of the recent crisis for the UK livestock industry. *Trends. Genet.* 17, 421-424.
- SCHNEIDER-SCHAULIES, J. (2000): Cellular receptors for viruses: links to tropism and pathogenesis. *J. Gen. Virol.* 81, 1413-1429.
- SHIN, J. H., H. J. SOHN, K. S. CHOI, B. J. KWON, C. U. CHOI, J. H. KIM, E. K. HWANG, J. H. PARK, Y. J. KIM, S. H. CHOI, O. K. KIM (2003): Identification and isolation of foot-and-mouth disease virus from primary suspect cases in Korea in 2000. *J. Vet. Med. Sci.* 65, 1-7.
- SMITH, B. P. (2009): Foot and mouth diseases. In: *Large Animal Internal Medicine*. 4<sup>th</sup> ed. (Smith, B. P., Ed.). St. Louis, Missouri, Mosby. pp. 802-803.
- SMITH, S. C., J. H. LADENSON, J. W. MASON, A. S. JAFFE (1997): Elevations of cardiac troponin I associated with myocarditis. Experimental and clinical correlates. *Circulation* 95, 163-168.
- TUNCA, R., M. SOZMEN H. ERDOGAN, M. CITIL, E. UZLU, H. OZEN, E. GOKCE (2008): Determination of cardiac troponin I in the blood and heart of calves with foot-and-mouth disease. *J. Vet. Diagn. Invest.* 20, 598-605.
- WEBER, M., M. RAU, K. MADLENER, A. ELSAESSER, D. BANKOVIC, V. MITROVIC, C. HAMM (2005): Diagnostic utility of new immunoassays for the cardiac markers cTnI, myoglobin and CK-MB mass. *Clin. Biochem.* 38, 1027-1030.
- VAN BEKKUM, J. G., H. S. FRENKEL, H. H. J. FREDERIKS, S. FRENKEL (1959): Observations on the carrier state of cattle exposed to foot-and-mouth disease virus. *Tijdschr Diergeneeskd.* 84, 1159-1164.
- VARLEY, H., A. H. GOWENLOCK, M. BELL (1984): *Practical Clinical Biochemistry*. 5<sup>th</sup> ed. William Heinemann Medical Books Ltd. London. pp. 685-770.

Received: 21 March 2014

Accepted: 4 February 2015

---

**AKTAS, M. S., Y. OZKANLAR, E. ORUC, I. SOZDUTMAZ, A. KIRBAS:**  
**Miokarditis vezan uz slinavku i šap u sisajuće teladi. Vet. arhiv 85, 273-282, 2015.**

**SAŽETAK**

Slinavka i šap može dovesti do miokarditisa u mladim životinja. Dosada nije opisana dobna raspodjela miokarditisa ni biokemijski profil u teladi oboljele od slinavke i šapa. U jednom području gdje se slinavka i šap javlja endemijski, telad mlađa od šest mjeseci bila je na zaraženim farmama klinički pretražena posebice na poremećaje u frekvenciji bila, disanja i srčanog ritma. Ukupno su 53 teleta bila sumnjiva na slinavku i šap. Sumnja na miokarditis postavljena je u šest teladi i to na osnovi tahipneje, tahikardije i galopirajućeg ritma. U te su teladi razine srčanog troponina-I (cTnI) i aspartat-aminotransferaze (AST) bile značajno više ( $P < 0,0001$ ), dok razine kreatinin-kinaze MB (CK-MB) i laktat-dehidrogenaze (LDH) nisu. Tih šest teleta uginulo je unutar dva dana te je u njih miokarditis bio potvrđen patohistološki. Sva telad s miokarditisom bila je mlađa od dva mjeseca, što upućuje na zaključak da se miokarditis uzrokovan virusom slinavke i šapa pretežito javlja u sisajuće teladi najranije dobi.

**Ključne riječi:** slinavka i šap, miokarditis, sisajuća telad

---