

Evaluation of the healing potential of earthworm coelomic fluid in full thickness skin wounds in rabbits

Amarpal^{1*}, Ran V. Singh², Hari P. Aithal¹, Prakash Kinjavdekar¹,
Abhijit M. Pawde¹, Karam P. Singh³, and Mudasir B. Gugjoo¹

¹ Division of Surgery, Indian Veterinary Research Institute-Izatnagar, Bareilly, India

² Division of Animal Genetics, Indian Veterinary Research Institute-Izatnagar, Bareilly, India

³ Division of Pathology, Indian Veterinary Research Institute-Izatnagar, Bareilly, India

AMARPAL, R. V. SINGH, H. P. AITHAL, P. KINJAVDEKAR, A. M. PAWDE, K. P. SINGH, M. B. GUGJOO: Evaluation of the healing potential of earthworm coelomic fluid in full thickness skin wounds in rabbits. Vet. arhiv 85, 189-200, 2015.

ABSTRACT

The present study was conducted on 16 New Zealand White rabbits of 10-12 months of age, to evaluate the healing potential of earthworm coelomic fluid in full thickness skin wounds. Under xylazine-ketamine anaesthesia, four rectangular full thickness excisional skin wounds, measuring 2×2 cm² were created on the dorsum of each animal and designated as groups I, II, III and IV. Wounds were treated by topical coelomic fluid (I), 0.5 % povidone-iodine and coelomic fluid (II), 0.5 % povidone-iodine (III) and normal saline (IV). Healing was evaluated on the basis of gross and histomorphological parameters. The mean wound area was significantly lesser ($P<0.05$) in the wounds of groups I and II as compared to groups III and IV, up to 21 days. Out of 16 wounds, nine wounds in group I (56.25 %) and 11 wounds in group II (68.75 %) healed completely by day 21, but none in groups III and IV. Histomorphological studies showed more mature and densely placed collagen and better epithelialization in groups I and II as compared to groups III and IV. It was concluded that coelomic fluid of the earthworm *Eisenia foetida* can accelerate healing of full-thickness skin wounds in rabbits.

Key words: earthworm, coelomic fluid, skin, wounds, rabbits

Introduction

Open wounds heal through a process of well-orchestrated cellular and molecular response that may be divided into four overlapping phases, described as: inflammation, debridement, repair, and remodeling and maturation (FOSSUM et al., 2007). Extensive research has been carried out on the use of topical medications in healing, but none of the

*Corresponding author:

Dr. Amarpal, MVSc, PhD, Principal Scientist & Head, Division of Surgery, Indian Veterinary Research Institute, Izatnagar-243122, Bareilly (UP), India, Phone: +91 901 2339 489; Fax: +91 58123 03284; E-mail: dramarpal@gmail.com

products investigated in domestic animals benefits wound healing, rather many of them inhibit it (SWAIM and HENDERSON, 1990). However, antiseptics, such as povidone-iodine, are frequently used in the management of open wounds, healing by secondary intention, primarily to reduce bacterial load (LEAPER and DURRANI, 2008). Despite advances made in understanding the basic principles, problems in wound healing continue to cause significant morbidity and mortality (PEACOCK and COHEN, 1990; BORENA et al., 2010).

The use of earthworms for medical purposes was documented as early as in 1340 AD (REYNOLDS and REYNOLDS, 1972). Traditional Indian healers operating in North America and doctors in East Asia have used earthworms to treat various diseases (COOPER et al., 2004). Administration of earthworm paste to albino rats reduced inflammation and restored the levels of antioxidants, possibly due to the high polyphenolic content of earthworm tissue (BALAMURUGAN et al., 2007). Earthworm coelomic fluid has been reported to contain molecules that exhibit cytolytic, agglutinating, proteolytic, haemolytic, mitogenic, antipyretic, and antibacterial properties (LANGE et al., 1997). The present study was designed to evaluate the wound healing potential of earthworm coelomic fluid in experimental full thickness skin wounds in rabbits.

Materials and methods

The present study was conducted on 16 New Zealand White rabbits of both sexes, between 10 and 12 months of age and between 1.50 and 2.0 kg body weight. The study was approved by the Institute Animal Ethics committee. The animals were acclimatized to approaching and handling for a period of 15-20 days before the start of the experiment. The animals were anaesthetized using 6 mg/kg xylazine, followed, 10 min later, by 60 mg/kg ketamine intramuscularly (AMARPAL et al., 2010). The dorsum of each animal was shaved and scrubbed for aseptic surgery using 0.1 % chlorhexidine solution three times. The site was painted with 5 % povidone-iodine before surgery. Two rectangular, full thickness excisional skin wounds measuring 2×2 cm² were created on the left side and two on the right side of the dorsum, about 2 cm away from the midline in each animal, using a sharp surgical knife. The bleeding, if any, was controlled by digital pressure. A gap of 2 cm was maintained between the two wounds on each side. Thus, a total of 4 wounds were created in each animal. The four wounds in each animal were designated as groups I, II, III and IV for assessment of four treatments (Fig. 1a). Wounds in group I were treated by topical application of coelomic fluid once daily until healing. Wounds in group II were cleaned daily with 0.5 % povidone-iodine, followed by application of coelomic fluid as in group I. Wounds of group III were cleaned with 0.5 % povidone-iodine once daily and wounds of group IV were cleaned with normal saline once daily. All the topical agents were applied to the wounds of their respective groups using sterile gauze pieces from day 0 until complete wound healing. The animals were kept in fly

proof cages individually, and standard feed and water were supplied to the animals ad libitum. The wounds were left open to heal without bandaging. Earthworm coelomic fluid was collected non-invasively by exposing earthworms (*Eisenia foetida*) to bright sunlight in clean containers. Coelomic fluid was then filtered into a sterilized glass beaker using a qualitative grade 1 filter paper. It was then sterilized by ultra-violet light exposure for 12 hours and stored at -20 °C temperature in small aliquots. Each time one aliquot was thawed and used within three days. During this period it was stored in a refrigerator at 4 °C.

Postoperatively, in addition to the topical treatments mentioned above, antibiotic enrofloxacin 5 mg/kg (Baytril- Bayer, India) and anti-inflammatory drug meloxicam 0.2 mg/kg (Melonex- Neovet India) were administered daily for 5 days starting from day 0 before induction of the wounds, to all the animals, to minimize the chances of infection and pain. The following observations were made for the evaluation of healing:

Observations. Extent of inflammation. Swelling at the wound margins was recorded as a measure of inflammation. It was recorded as present or absent.

Wound contraction. Wound contraction was recorded as a reduction in the wound area (%). The wound area was measured on day 0, 3, 7, 14, 21 and 28 after surgery by tracing the wound margin on a transparent polyvinyl chloride sheet and the total area (cm²) was calculated using graph paper. The area recorded at each interval was divided by the total wound area of the wound on day 0 and multiplied by 100 to calculate per cent wound contraction at each interval (BIGBIE et al., 1991).

Gross and photographic evaluation. Wounds were examined for colouration, presence of exudate, and presence and type of scab over the wounds. Sequential photographs of the wounds were made on day 0 and then on 3rd, 7th, 14th and 28th days after wounding to compare the quality of healing between the groups.

Time of complete healing. The number of wounds healed completely in each group was recorded at each interval. Healing was considered to be complete when the epithelium covered the entire wound and the area of the remaining granulation tissue was zero i.e. wound contraction was 100 % (BIGBIE et al., 1991).

Histomorphological evaluation. Four representative samples of full-thickness skin tissue from healing wounds in each treatment group were collected on 21th and 28th days after surgery and fixed in 10 % buffered formalin. The tissues were processed by the paraffin-embedding technique and 4 to 5 µm thick paraffin sections were made. The sections were stained with haematoxylin and eosin (H&E), as described by LUNA (1968), and screened for evidence of healing under a light microscope.

Statistical analysis. Data for wound area were analysed using Analysis of Variance and Duncan's Multiple Range Test for comparison between the groups. The values at

different intervals were compared with the 0 day values in respective groups using the Paired “t” test by SPSS software. For each comparison, differences between groups were considered significant at P<0.05.

Results

All the wounds were created by measuring an area of 2×2 cm² over the dorsum of the rabbits. However, the wounds expanded to variable sizes in different animals. Thus the initial size of the wound varied, but it did not differ significantly between the groups (Table 1).

On day 3, all the wounds appeared red in colour with dried margins. The signs of inflammation and swelling were only minimal. The wound size had started to decrease in all the groups but it was grossly evident in the animals of treatment groups I and II only (Fig. 1b). The wound area was smallest in the wounds of group II followed by the wounds of group I and the wounds of groups IV and III (Table 1). Wound contraction was maximum in the animals of group II, followed by the wounds of group I, but it was minimal in groups III and IV (Table 2).

Table 1. Mean ± SE of wound area in the wounds treated with coelomic fluid (group I), 0.5 % povidone-iodine + coelomic fluid (group II), 0.5 % povidone-iodine (group III) and normal saline (group IV) at different intervals

Groups	Intervals (days)					
	0	3	7	14	21	28
I	6.98 ± 0.30	5.23 ± 0.42 ^{*a}	3.41 ± 0.25 ^{*a}	1.32 ± 0.13 ^{**a}	0.06 ± 0.07 ^{**a}	0.0 ± 0.0
II	6.75 ± 0.33	4.89 ± 0.33 ^{*a}	3.49 ± 0.15 ^{*a}	1.42 ± 0.23 ^{**a}	0.09 ± 0.03 ^{**a}	0.0 ± 0.0
III	7.0 ± 0.18	6.78 ± 0.45 ^b	4.85 ± 0.27 ^b	2.77 ± 0.35 ^{*b}	0.82 ± 0.03 ^{**b}	0.0 ± 0.0
IV	6.95 ± 0.23	6.34 ± 0.19 ^b	4.77 ± 0.30 ^b	2.48 ± 0.36 ^{*b}	0.82 ± 0.12 ^{**b}	0.0 ± 0.0

*Significantly different from 0 day value (P<0.05); ** Significantly different from 0 day value (P<0.01); Values with different superscripts (a, b) differ significantly (P<0.05) at the corresponding intervals.

Table 2. Wound contraction (%) in the wounds treated with coelomic fluid (group I), 0.5 % povidone-iodine + coelomic fluid (group II), 0.5 % povidone-iodine (group III) and normal saline (group IV) at different intervals

Groups	Intervals (days)				
	3	7	14	21	28
I	25.07	51.15	81.09	98.34	100
II	27.56	48.29	78.96	98.66	100
III	3.14	30.71	60.43	88.29	100

On day 7, the wounds in the different treatment groups appeared dried. A thick dry pale yellow scab was present over the wounds. There were no signs of swelling or exudation in any of the wounds. The wounds of the group I appeared smallest and their scab appeared thinner, as compared to the wounds in the other treatment groups (Fig. 1c). The mean wound area was significantly ($P<0.05$) smaller in the wounds of groups I and II as compared to that in groups III and IV (Table 1). The wound contraction was also greater in the wounds of group I followed by the wounds in group II, IV and III.

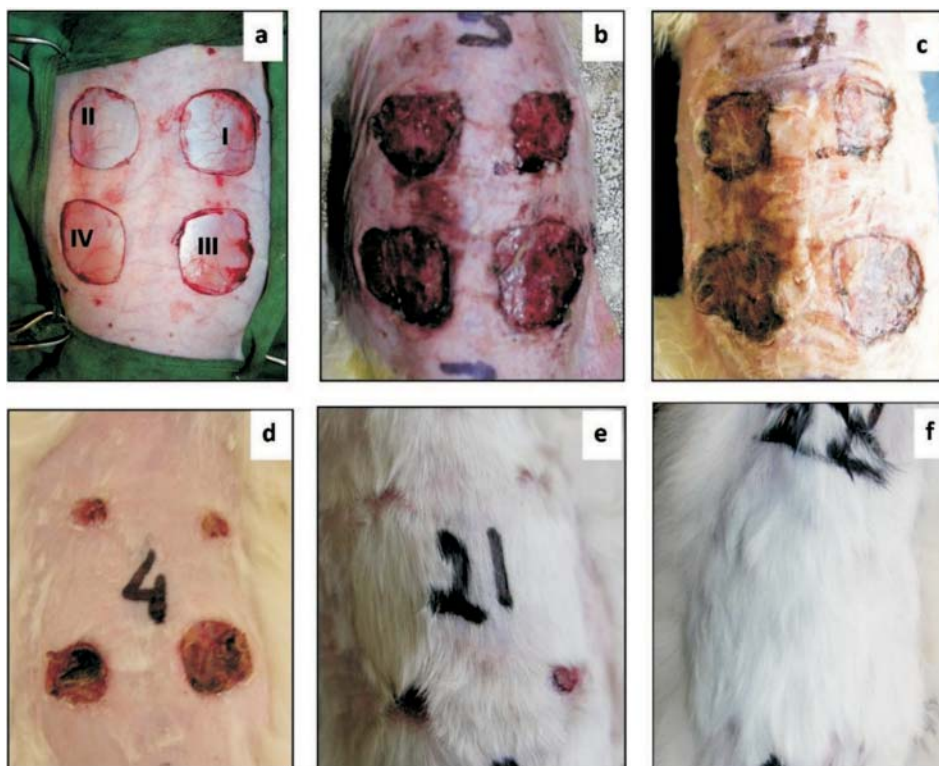


Fig. 1. Gross photographs showing extent of healing in the wounds treated with topical application of coelomic fluid (group I), 0.5 % povidone-iodine followed by coelomic fluid (group II), 0.5 % povidone-iodine (group III) and normal saline (group IV) on day 0 (a), 3 (b), 7 (c), 14 (d), 21 (e), and 28 (f).

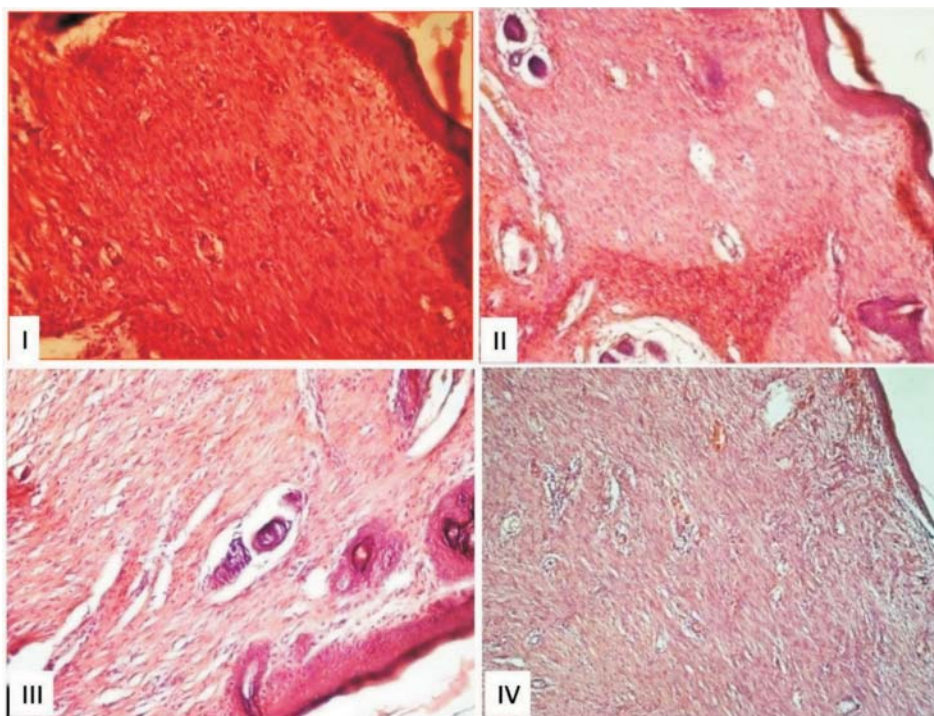


Fig. 2. Photomicrographs showing histomorphological details of healing tissues in wounds treated with topical application of coelomic fluid (group I), 0.5 % povidone-iodine followed by coelomic fluid (group II), 0.5 % povidone-iodine (group III) and normal saline (group IV) on 21st day after treatment. Note better granulation tissue formation and epithelialization in the wounds of group I and II (H&E, $\times 200$).

On day 14, the wound scab had peeled off completely in groups I and II. In the wounds of groups III and IV, areas of black scab were evident over the wound surface, but in a few places the scab had peeled off. The photographic evaluation revealed a bright red wound area in groups I and II, but a mosaic appearance of the scab in groups III and IV (Fig. 1d). The wound size had reduced further in all the groups. The mean wound area was significantly smaller ($P < 0.05$) in the wounds of groups I and II as compared to that in groups III and IV (Table 1). Out of 16 wounds, three wounds in group I and one wound in group II had healed completely. The other two wounds in group I and three wounds in group II had only a small unhealed area, suggesting almost complete wound healing. The wound contraction was maximal in the wounds of group I, followed by the wounds of group II and then by the wounds of groups IV and III (Table 2).

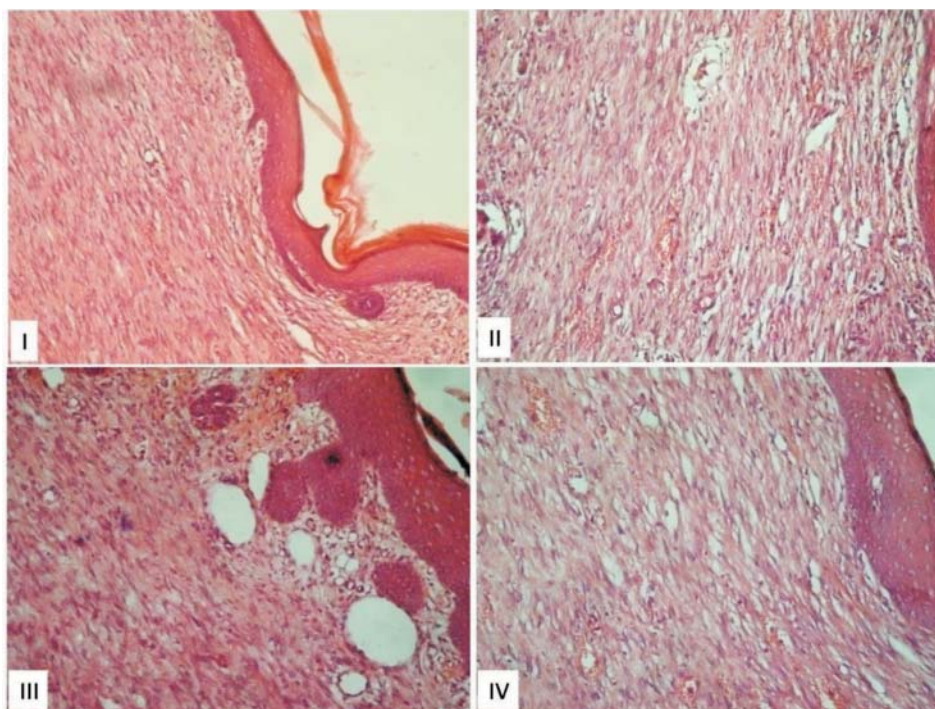


Fig. 3. Photomicrographs showing histomorphological details of healing tissues in wounds treated with topical application of coelomic fluid (group I), 0.5 % povidone-iodine followed by coelomic fluid (group II), 0.5 % povidone-iodine (group III) and normal saline (group IV) on 28th day after treatment. Note better collagen deposition in the wounds of group I and II (H&E, $\times 200$).

On day 21, the wound scab had peeled off completely in groups I and II. In the wounds of groups III and IV the scab was still present at a few places over the wound area. The photographic evaluation revealed either completely healed wounds or only a very small wound area in groups I and II, but mostly red wounds in groups III and IV (Fig. 1e). The mean wound area was significantly ($P < 0.05$) smaller in groups I and II than in groups III and IV (Table 1). Out of 16 wounds, nine wounds in group I (56.25 %) and 11 wounds in group II (68.75 %) had healed completely. None of the wounds in groups III and IV had healed completely (Table 1). The contraction was maximal in the wounds of group II, followed by the wounds of groups I, IV and III (Table 2). On day 28 all the wounds of the different treatment groups had healed completely (Fig. 1f).

Histomorphological observations. On 21st day post-treatment the healing tissues from wounds of group I consisted of immature fibroblasts, having an elongated nucleus and tapering ends with moderate collagen fibres. Young capillaries were present in the healing tissue. The epidermis covering was completely formed with keratin and a basal layer. In places an indication of adnexa formation was also seen in the healing tissue (Fig. 2I). The healing tissues from the wounds of group II consisted of immature fibroblasts, dense collagen fibres with complete regeneration of the epidermis, having keratin and a basal layer. An indication of adnexa formation was also noticed in the healing area (Fig. 2II). In the tissues of group III the healing reaction was poor, with less dense connective tissue and immature fibroblasts. The newly formed capillaries and skin adnexa were poor in the healing tissue. The epidermis formation was complete with a poor and thin keratin layer (Fig. 2III). In group IV, the healing tissue was loose, with less dense connective tissue and sparse fibroblasts. The epidermis formation was complete with a poor, thin keratin layer and poor skin adnexa (Fig. 2IV).

On 28th day post-treatment the healing tissue in group I showed densely placed mature fibroblasts with collagen fibres. The mononuclear cells were present around the blood vessels. Newly formed capillaries were found perpendicular to the healing tissue. Epidermis formation was complete with a thick keratin layer (Fig. 3I). In group II, the healing was complete and almost similar to the coelomic fluid treatment in group I (Fig. 3II). In group III, the healing tissue was not dense, fibroblasts and the collagen fibres were sparsely placed. Epidermis formation was complete, with the presence of rete ridges (Fig. 3III). In group IV, healing tissue consisted of mature but sparsely placed fibroblasts, collagen fibres and newly formed capillaries, with the presence of mononuclear cells around the congested blood vessels (Fig. 3IV).

Discussion

The wounds of different groups expanded to variable sizes, but the mean wound area did not differ significantly between the groups. Expansion of wounds on the dorsum is a common event in rabbits, and may be attributable to the loose attachment of rabbit skin (BALAMURUGAN et al., 2007; BORENA et al., 2009).

The wounds of all the groups were covered by a thick scab during the early part of the observation period. The wound exudates and clotted blood oozing from the cut wound edges might have been responsible for the formation of thick scabs over the wounds. Full-thickness skin wound healing occurs by granulation tissue formation, contraction and epithelialisation (FOSSUM et al., 2007). Epithelialisation occurs by migration of undamaged epidermal cells from the wound margins across the granulation bed. Once the epithelial bridge is complete, enzymes are released to dissolve the attachment at the base of the scab, resulting in its removal (DIEGELMANN and EVANS, 2004). The scab peeled

off completely in the wounds of group I and II by day 14, but it was still evident in the wounds of groups III and IV even on day 21. The early detachment of the scab observed in the wounds of groups I and II could be due to the early bridging of the gap and early epithelialization of the wounds in groups I and II.

Wound contraction plays a very important role in the healing of excisional skin wounds. The wound undergoes physical contraction throughout the entire wound healing process, which is believed to be mediated by contractile fibroblasts (myofibroblasts) that appear in the wound (GOSAIN and DIPIETRO, 2004; CAMPOS et al., 2008). Two theories of wound contraction have been proposed in the past. The 'picture frame' theory states that myofibroblasts located in the wound margins of an open wound are responsible for the centripetal forces that lead to wound contraction (WALDRON and ZIMMERMAN-POPE, 2003), while the 'pull' theory suggests that fibroblasts distributed throughout the granulation tissue generate the forces responsible for contraction (ABERCROMBIE et al., 1956). However, it is also suggested that wound contraction occurs through a combination of these two processes (SWAIM et al., 2001). The wound area reduced significantly ($P < 0.05$) from day 3 onward in the wounds of group I and II but only from day 14 onward in groups III and IV. The wound contraction was faster in the wounds of groups I and II as compared to that in the wounds of groups III and IV until day 21. The early onset and faster rate of wound contraction in the wounds of groups I and II could be responsible for early healing in those groups, as compared to the wounds of groups III and IV.

It has been suggested that histomorphological assessment of healing in open wounds allows more precision than clinical examination (ABRAMO et al., 2004). Histomorphological examination revealed better epithelialization with a thick keratin layer, mature fibroblasts, and more deposition and better arrangement of collagen fibres in the wounds of groups I and II, as compared to the wounds of groups III and IV. Collagen, the main component of the extracellular matrix, is responsible for the tensile strength of the wound bed. Collagen is initially deposited in an irregular way, after which the individual collagen fibrils are reorganized in bundles, regularly aligned and orientated along stress lines (SINGER and CLARK, 1999). The better arrangement of collagen in the wounds of groups I and II was indicative of better quality healing in those wounds, as compared to the wounds of groups III and IV.

The exact mechanism by which coelomic fluid might have accelerated wound healing was not studied in the present investigation. However, it is expected to benefit wound healing owing to its various properties. Earthworm coelomic fluid and earthworm extracts are reported to possess anti-inflammatory, antioxidant and antipyretic properties (BALAMURUGAN et al., 2009), and antibacterial properties (MATAUSIC-PISL et al., 2010). These properties might have helped induction of early and faster healing in the wounds treated with coelomic fluid, as compared to the wounds treated with povidone-iodine

or saline. Although inflammation is necessary for healing, by fighting infection and induction of the proliferation phase, healing proceeds only after inflammation has been controlled (MIDWOOD et al., 2004). The anti-inflammatory properties of coelomic fluid might have resulted in early onset of the proliferation phase in the wounds of groups I and II, as evident by the rapid contraction and presence of more mature fibroblasts as compared to the wounds of groups III and IV. Our findings were comparable to the observations of MATAUSIC-PISL et al. (2010), who reported that earthworm extract (glycoprotein G-90) may enhance wound healing in rats, possibly by influencing tissue regeneration, and acceleration of proliferation and synthesis of growth factors. It is interesting to note that in the present study non-invasively collected coelomic fluid was used, in contrast to the tissue extract used by MATAUSIC-PISL et al. (2010). Since there are no reports of the presence of glycoprotein (G 90) in the coelomic fluid of earthworms, the enhanced healing in the present study might be attributable mainly to the reported anti-inflammatory, antibacterial and mitogenic properties of earthworm coelomic fluid (LANGE et al., 1997; BALAMURUGAN et al., 2007).

It was concluded that non-invasively collected coelomic fluid of the earthworm *Eisenia foetida* can accelerate healing of full-thickness skin wounds in rabbits.

Acknowledgements

Authors are highly thankful to the Director of the Institute for providing the necessary facilities.

References

- ABERCROMBIE, M., M. H. FLINT, D. W. JAMES (1956): Wound contraction in relation to collagen formation in scorbutic guinea-pigs. *J. Embryol. Expt. Morphol.* 4, 167-175.
- ABRAMO, F., P. MANTIS, D. H. LLOYD, S. T. AUXILIA, C. NOLI, R. LEOTTA, D. PFEIFFER (2004): An evaluation of methods for the assessment of healing of open wounds in the dog. *Vet. Dermatol.* 15, 13.
- AMARPAL, P. KINJAVDEKAR, H. P. AITHAL, A. M. PAWDE, J. SINGH, R. UDEHIYA (2010): Evaluation of xylazine, acepromazine and medetomidine with ketamine for general anaesthesia in rabbits. *Scand. J. Lab. Anim. Sci.* 37, 223-229.
- BALAMURUGAN, M., K. PARTHASARATHI, E. L. COOPER, L. S. RANGANATHAN (2007): Earthworm paste (*Lampito mauritii*, Kinberg) alters inflammatory, oxidative, haematological and serum biochemical indices of inflamed rat. *Eur. Review Med. Pharmacol. Sci.* 11, 77-90.
- BALAMURUGAN, M., K. PARTHASARATHI, E. L. COOPER, L. S. RANGANATHAN (2009): Anti-inflammatory and anti-pyretic activities of earthworm extract-*Lampito mauritii* (Kinberg). *J. Ethnopharmacol.* 121, 330-332.
- BIGBIE, R. B., J. SCHUMACHER, S. F. SWAIM, R. C. PUROHIT, J. WRIGHT (1991): Effects of amnion and live yeast cell derivative on second-intention healing in horses. *Am. J. Vet. Res.* 52, 1376-1382.

- BORENA, B. M., A. M. PAWDE, AMARPAL, H. P. AITHAL, P. KINJAVDEKAR, R. SINGH, D. KUMAR (2010): Evaluation of autologous bone marrow-derived nucleated cells for healing of full-thickness skin wounds in rabbits. *Int. Wound J.* 7, 246-260.
- BORENA, B. M., A. M. PAWDE, AMARPAL, H. P. AITHAL, P. KINJAVDEKAR, R. SINGH, D. KUMAR (2009): Autologous bone marrow-derived cells for healing excisional dermal wounds of rabbits. *Vet. Rec.* 165, 563-568.
- CAMPOS, A. C., A. K. GROTH, A. B. BRANCO (2008): Assessment and nutritional aspects of wound healing. *Current Opinion Clinical Nutri. Metabolic Care* 11, 281-288.
- COOPER, E., T. HRZENJAK, M. GRDISA (2004): Alternative source of fibrinolytic, anticoagulative, antimicrobial and anticancer molecules. *Int. J. Immunopathol. Pharmacol.* 17, 237-244.
- DIEGELMANN, R. F., M. C. EVANS (2004): Wound healing: an overview of acute, fibrotic and delayed healing. *Frontiers Biosci.* 9, 283-289.
- FOSSUM, T. W., C. S. HEDLUND, A. L. JOHNSON, K. S. SCHULZ, H. B. SEIM, M. D. WILLARD, A. BAER, G. L. CARROLL (2007): Surgery of the integumentary system. In: *Manual of Small Animal Surgery*, Mosby, St Louis, pp. 159-175.
- GOSAIN, A., L. A. DIPIETRO (2004): Aging and wound healing. *World J. Surg.* 28, 321-326.
- LANGE, S., F. NÜSSLER, E. KAUSCHKE, G. LUTSCH, E. L. COOPER, A. HERRMANN (1997): Interaction of earthworm hemolysin with lipid membranes requires sphingolipids. *J. Biol. Chemistry* 272, 20884-20892.
- LEAPER, D. J., P. DURANI (2008): Topical antimicrobial therapy of chronic wounds healing by secondary intention using iodine products. *Int. Wound J.* 5, 361-368.
- LUNA L. (1968): *Manual of Histologic Staining Methods of the Armed Forces Institute of Pathology*, 3rd edn. McGraw-Hill, New York, pp. 55-96.
- MATAUSIC-PISL, M., H. CUPIC, V. KASUBA, A. M. MIKECIN, M. GRDISA (2010): Tissue extract from *Eisenia foetida* as a wound-healing agent. *Eur. Review Med. Pharmacol. Sci.* 14, 177-184.
- MIDWOOD, K. S., L. V. WILLIAMS, J. E. SCHWARZBAUER (2004): Tissue repair and the dynamics of the extracellular matrix. *Int. J. Biochemistry Cell Biol.* 36, 1031-1037.
- PEACOCK, E. E., I. K. COHEN (1990): Wound healing. In: *Plastic surgery*, McCarthy, J.G., J. W. May, J. W. Littler, Eds.), Vol. 1, (Philadelphia (PA): W.B. Saunders Company), pp. 161-185.
- REYNOLDS, J. W., W. M. REYNOLDS (1972): Earthworms in medicine. *Am. J. Nursing* 72, 1273.
- SINGER, A. J., R. A. CLARK (1999): Mechanisms of disease: cutaneous wound healing. *New England J. Med.* 341, 738-746.
- SWAIM, S. F., R. A. HENDERSON (1990): Wound management. In: *Small Animal Wound Management*, Lea and Febiger, pp. 9-33.
- SWAIM, S. F., S. H. HINKLE, D. M. BRADLEY (2001): Wound contraction: basic and clinical factors. *Compendium on Continuing Education for the Practicing Veterinarian* 23, 20-34.

Amarpal et al.: The healing potential of earthworm coelomic fluid in full thickness skin wounds

WALDRON, D. R., N. ZIMMERMAN-POPE (2003): Superficial skin wounds. In: Textbook of Small Animal Surgery. (Slatter, D., Ed.), WB Saunders, pp. 259-292.

Received: 21 January 2014

Accepted: 16 January 2015

AMARPAL, R. V. SINGH, H. P. AITHAL, P. KINJAVDEKAR, A. M. PAWDE, K. P. SINGH, M. B. GUGJOO: Prosudba učinkovitosti celomske tekućine kišne gujavice na cijeljenje rana u punoj debljini kože kunića. Vet. arhiv 85, 189-200, 2015.

SAŽETAK

Istraživanje je provedeno na 16 novozelandskih bijelih kunića u dobi od 10 do 12 mjeseci s ciljem da se prosudi mogući učinak celomske tekućine kišne gujavice na cijeljenje rana u punoj debljini kože u kunića. Kunići su bili podijeljeni u četiri skupine označene I, II, III i IV. Četiri pravokutne ekscizijske kožne rane u punoj debljini veličine 2x2 cm načinjene su na leđima svake životinje pod anestezijom ksilazin-ketaminom. Rane su bile obrađene celomskom tekućinom (skupina I), 0,5 %-tnim povidon-jodom i celomskom tekućinom (skupina II), 0,5 %-tnim povidon-jodom (skupina III) i fiziološkom otopinom (skupina IV). Cijeljenje rana bilo je prosuđivano na osnovi patoanatomskih i patohistoloških nalaza. Prosječna površina rana 21 dan nakon ekscizije bila je značajno manja ($P < 0,05$) u skupinama I i II u usporedbi s površinom skupina III i IV. Devet od 16 rana u skupini I (56,25 %) i 11 u skupini II (68,75 %) u potpunosti su zacijelile 21 dan nakon ekscizije, dok nijedna nije zacijelila u skupini III i IV. Patohistološki nalaz pokazao je više zrelog i gušće raspoređenog kolagena te bolju epitelizaciju u skupinama I i II u usporedbi sa skupinama III i IV. Može se zaključiti da celomska tekućina kišne gujavice *Eisenia foetida* može ubrzati cijeljenje rana u punoj debljini kože u kunića.

Ključne riječi: kišna gujavica, *Eisenia foetida*, celomska tekućina, koža, rane, kunić
