

Hematology parameters in dogs treated with subconjunctival application of limbal stem cells allografts

**Boris Pirkić^{1*}, Njetočka Gredelj Šimec², Lea Slunjski¹, Mirna Abbafy¹,
Dubravko Kezić³, Daniel Špoljarić³, Tomislav Babić¹, Katarina Špiranec⁴,
Gordan Mršić⁵, Damir Mihelić⁴, Dražen Matičić¹, and Maja Popović³**

¹*Clinic of Surgery, Orthopaedics and Ophthalmology, Faculty of Veterinary Medicine,
University of Zagreb, Croatia*

²*Clinical Hospital Merkur, Zagreb, Croatia*

³*Department of Biology, Faculty of Veterinary Medicine, University of Zagreb, Croatia*

⁴*Department of Anatomy, Histology and Embriology, Faculty of Veterinary Medicine,
University of Zagreb, Croatia*

⁵*Center for Forensic Investigations, Research and Expertise „Ivan Vučetić“, Zagreb, Croatia*

**PIRKIĆ, B., NJ. GREDELJ ŠIMEC, L. SLUNJSKI, M. ABBAFY, D. KEZIĆ,
D. ŠPOLJARIĆ, T. BABIĆ, K. ŠPIRANEC, G. MRŠIĆ, D. MIHELIC,
D. MATIČIĆ, M. POPOVIĆ: Hematology parameters in dogs treated with
subconjunctival application of limbal stem cells allografts. Vet. arhiv 85, 67-79, 2015.**

ABSTRACT

The cornea, as a source for obtaining stem cells, is a good medium for their use in veterinary ophthalmology. In this research, we used dogs which had been diagnosed with extensive, chronic thinning of the central cornea (vertex corneae) generated due to complicated mechanical damage to the corneae pannosa. The goal of this study was to test whether subconjunctival application of limbal stem cells allografts had any influence on haematology parameters in peripheral blood. The animals were divided into three experimental groups regardless of breed, sex and age, and each group comprised 7 dogs. Group A consisted of clinically healthy dogs (control), in group B there were dogs who had had injuries treated by a conventional ophthalmological approach in veterinary medicine, and group C in which corneal injuries were treated using subconjunctival cell allografts. Blood samples were taken four times during the experiment from all animals for haematological analysis. Transplantation of limbal stem cell allografts did not affect the physiological haematology parameters.

Key words: dog, stem cell, limbus, veterinary ophthalmology

*Corresponding author:

Assoc. Prof. Boris Pirkić, DVM, PhD, Clinic of Surgery, Orthopaedics and Ophthalmology, Faculty of Veterinary Medicine
University of Zagreb, Heinzelova 55, Zagreb 10000, Croatia, Phone: +385 1 2390 111, Fax: +385 1 2441 390; E-mail:
boris.pirkic@vef.hr

ISSN 0372-5480
Printed in Croatia

Introduction

In the past decades, stem cell biology has had a profound impact on our view of mammalian development, as well as opening new avenues in regenerative medicine (POPOVIĆ et al., 2009b). The potential of stem cells to differentiate into various cell types of the body is the principal reason why they are being explored in treatments for wound repair, tissue engineering and application in therapeutic fields, including regenerative surgery. Currently, veterinary scientists are investigating stem cell models, ranging from either blastocyst- or embryo-derived embryonic stem cells to somatic or adult stem cells, such as germline stem cells and those derived from bone marrow, epithelial and adipose tissues (MATOUSKOVA et al., 1997; HIPP and ATALA, 2008). It is not unexpected that novel stem cell based therapies have been applied to animal patients (horses, dogs and cats) long before they can be used in human patients, even without the ethical debate surrounding the use of human stem cells (HACKAM, 2007). An advantage of veterinarians is access to animal models of naturally occurring injuries/diseases (tendon and ligament damage, osteoarthritis, osteochondrosis, muscular dystrophy, myocardial infarction, corneal defects and stroke) that are targets for stem cells therapies (ELSINGHORST, 2004). Recently, in human medicine *in vitro* cultivation of limbal stem cells has been developed, isolated from very small samples of biopsates obtained from the limbal region of autologous and/or allogeneic donors. These isolated cells may be cultured on mouse fibroblasts (3T3) or other carriers, such as amniotic membrane, fibrin, collagen and contact lenses. PIRKIĆ et al. (2013) adapted techniques for culturing animal limbal stem cells, optimized the *in vitro* culturing of allografts, canine in particular, and applied them by subconjunctival application to patients with corneal injuries. Namely, the corneal epithelium has a key role in the homeostasis and integrity of the eye (CHUNG, 1999). To maintain integrity of the eye surface, epithelial cells of the cornea are supported by stem cells found in the limbus. The limbus is a 1mm wide transitory area between the cornea and the sclera, and together with the conjunctival epithelium has the important role of replenishing corneal epithelial cells after trauma (FERNANDES et al., 2007; TAYLOR, 2000).

There are numerous cases of corneal trauma in all pet species, from slight scratches to complete perforation. Such injuries are frequent in short muzzle (brachiocephalic) dogs, and occasional in cat and horses. The healing time of the cornea is long, and often complicated with secondary infections, because the eye is an exposed organ. Also, any loss in vision often leads to repeated injury so it is important to achieve corneal clarity as soon as possible. Often such injuries do not show a tendency to heal, and they are called corneal ulcers. The reasons for this may be multiple. One is a deficiency or complete lack of limbal stem cells (due to age, genetics or some other defect), but it also could be due to infections as well as to the aforementioned repeated trauma.

So, a fundamental goal in veterinary ophthalmology is the application of *in vitro* grown stem cells as allografts from animal species of interest for veterinary medicine (dogs, cats, horses and pigs) as a model for transplantation research in therapy of corneal defects and deficiencies. However, use of allogenic biological material as a substrate is associated with risks of transmission of certain diseases, so the goal of this study was to test if subconjunctival application of limbal stem cell allografts had any influence on haematology parameters in peripheral blood.

Materials and methods

Animals. Twenty-one dogs, which were patients of the Surgery, Orthopaedics and Ophthalmology Clinic of the Faculty of Veterinary Medicine, University of Zagreb were assigned to three experimental groups regardless of breed, sex and age. They were defined according to different therapeutic methods. Each experimental group contained seven animals (Tables 1-3). In group A (control group) were clinically healthy dogs, without any pathology of the cornea. In group B were dogs with pathologically altered central part of the cornea, caused by mechanical damage, which were treated by a classical ophthalmological approach. In group C were dogs with extensive, chronically thinning of the central part of the cornea, caused by mechanical damage, which were treated with limbal stem cell allografts. Blood samples were taken four times during the experiment from all animals for haematological analysis. Experimental animals were treated according to the Croatian legislation on animal protection and in accordance with the recommendations made by the European Community (86/609/EEC).

Biological material. Eye bulb samples (2-4 cm width) were collected from ten euthanized dogs (independent of sex, breed and age) at the Surgery, Orthopaedics and Ophthalmology Clinic of the Faculty of Veterinary Medicine, University of Zagreb, with the written consent of the dogs' owners. All donors of eye bulbs were clinically healthy, meaning that eyes were not subject to any illness. Nevertheless, euthanized animals were mostly fatally traumatized, and a few of them were suffering from a life threatening illness, and were euthanized at the request of the owner. Limbal 5 mm² samples were obtained using penetrating keratotomy, according to PIRKIĆ et al. (2010).

Procedure of dog limbal cell extraction from the eye. In sterile conditions (Forma Scientific sterile chamber), 1-2 mm² fragmented limbal tissue was placed into 6 well cultivation plates with 3 mL of medium without cell growing serum (Serum Free Media SFM, Invitrogen-Gibco). Cells were incubated (Forma Scientific incubator) in the atmosphere with 5 % CO₂, at +37 °C. Every three days, the medium was changed in sterile conditions. After cells have grown over 80 % of the plate bottom, they were treated with 1 mL of 0.25 % trypsin for 2-3 minutes, causing cell elevation from the cultivation plate bottom. In the cell suspension obtained, the number of cells was

determined in a Neubauer chamber using tripan methylene blue (Sigma, St. Louis, USA). The morphological characteristics of those samples were analysed using an electronic microscope XL30 ESEM, Philips, Netherlands (Forensic Science Centre „Ivan Vučetić“, Zagreb, Croatia) and the phenotype was determined by routine immunocytochemical methods using a fluorescent dye conjugate monoclonal mouse antibody against p63 cornea of the dog (antibodies-online.com Gmbh, Germany). 1×10^6 cells in 1 mL SFM medium was prepared in a sterile syringe, according to PIRKIĆ et al. (2013).

Application of the limbal stem cell suspension: 1×10^6 cells in 1 mL SFM medium, prepared in the syringe, were applied to the dogs under local anaesthesia (1 % tetracaine hydrochloride eye drops, three times within 5 minutes in the affected eye subconjunctivally) (Fig. 1). The dogs were treated 3 days before and 7 days after this procedure with local antibiotics (tobramycin drops, Alcon) and 2 days before and 5 days after the application of the cellular allograft with local corticosteroid preparations (dexametason drops three times daily in the eye).

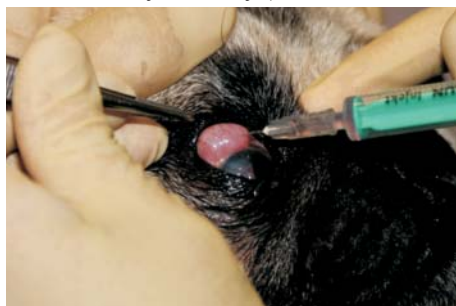

Fig. 1. Subconjunctival application of limbal stem cell in dog

Blood sampling. Blood samples (a total of 11.5 mL) were taken from a vein cephalic antebrachii in glass vacuum tubes (Beckton Dickinson, Plymouth, UK) with disodium salt of ethylenediaminetetraacetic acid (EDTA, Sigma) (1 mL) as an anticoagulant. Blood samples were taken four times during the experiment, before surgery and 3, 10, and 30 days after the procedure, due to expected time needed for the cornea to heal fully. Haematological parameters (red blood cell count and platelet count, haemoglobin and haematocrit) were determined by standard methods using automatic electronic counters, Serono Baker System 9120 (Pennsylvania, USA). Automatic electronic counters, Serono Baker System 9120 (Pennsylvania, USA), were used to determine the number of leukocytes and differential counts are made from the peripheral blood smears, stained with May-Grunwald Giemsa. The percentages of individual populations of leukocytes were determined by examination of blood smears using an Olympus BX 41 microscope with immersion increase.

Statistical analysis. All statistical analyses were performed using Statistica 7.0 (StatSoft Inc., 2005). The significance of differences between the experimental and control groups was determined using the Student's *t*-test and Mann-Whitney-U-test. Statistical differences were considered significant at $P \leq 0.05$.

Results

Dog limbal cells within “*in explant*” cultures, achieved 80 % confluence 5 days after ingrowing (Fig. 2). Using an electronic microscope, it could be seen that cells within the secondary cultures were of equal size, approximately $14.5 \mu\text{m} \times 13.4 \mu\text{m}$, five days after ingrowing (Fig. 3).

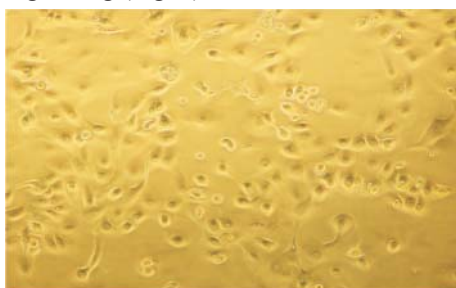

Fig. 2. *In explant* culture of dog limbal cells, 5 days after ingrowing, $\times 40$




Fig. 3. Electron micrograph of dog limbal cell, 5 days after ingrowing, visualized using electronic microscope XL30 ESEM, Philips, Netherlands (Centre for Forensic Investigations, Research and Expertise „Ivan Vučetić“, Zagreb, Croatia).

According to immunocytochemical analysis of dog limbal cells, using fluorescein dye conjugated mouse monoclonal antibody against p63 dog cornea, it was obvious that cells within the secondary culture, 5 days after ingrowing, had the characteristics of epithelial limbal cells, at the moment of their preparation for clinical use, that is they had positive p63 (Fig. 4-5).

Subconjunctival application of limbal cell allografts did not affected haemogram values. In other words, experimental group C showed physiological values of haematology indicators in the peripheral blood.

When looking at the tables, we can easily observe that in control group A (Table 1), and within groups B and C (Tables 2 and 3), there are no obvious discrepancies in blood test results. This assertion is further demonstrated by statistical analysis carried out within this study (Tables 4, 5 and 6). That is to say, no significant changes in blood values were found in any of the groups.

Statistical data were expressed as mean and standard deviation.

Table 1. Control group A contains clinical healthy dogs, without any pathology of the cornea

Group	N	Breed Number cards collection:	Age gender	Pathology of the cornea
A	1	A large Swiss mountain dog Can 229/10	1.5 year male	Without pathology
	2	Tibetan terrier Can 68/10	2 years male	Without pathology
	3	Border collie Can166/10	3 years male	Without pathology
	4	Golden retriever Can 601/08	4.5 years male	Without pathology
	5	Belgian Shepherd Can 1788/09	3 year female	Without pathology
	6	Dachshund Can 2595/09	5.5 years male	Without pathology
	7	Border collie Can 165/10	6.5 years male	Without pathology

Table 2. Experimental group B contains dogs with pathologically altered central part of the cornea caused by mechanical damage, which were treated by classic ophtalmological approach

Group	N	Breed Number cards collections:	Age gender	Pathology of cornea
B	1	French bulldog CAN 373/10	7 years male	Ulcus corneae chron. OD* Keratitis pannosa OD
	2	German boxer CAN 981/09	9 years male	Ulcus corneae chron. OS** Keratitis pannosa OD
	3	Pekingese CAN 2123/09	4 years male	Perforatio bulbi susp. Keratitis pannosa OD
	4	West highland terrier CAN 882/09	9 years female	Ulcus corneae OS Keratitis pannosa OS
	5	French bulldog CAN 747/09	1.5 years male	Ulcus corneae chron. OS Keratitis pannosa OS
	6	Shih-tzu CAN 971/09	1.5 years male	Contusio bulbi OS Ulcus corneae chron. OS
	7	Shih-tzu CAN 1143/10	7.5 years male	Ulcus corneae OD Keratitis pannosa OD

*OD - oculi dextri, **OS - oculi sinistri

Table 3. Experimental group C contains dogs with extensive, chronically thinning central part of the cornea caused by mechanical damage, which were treated with limbal stem cells allograft

Group	N	Breed Number cards collections:	Age gender	Pathology of cornea
C	1	Pug CAN 1159/09	1.5 year male	Ulcus corneae OS* Keratitis pannosa OS
	2	Alaskan malamute CAN 1311/09	7 years male	Perforatio corneae OS Keratitis OS
	3	Pekingese CAN 1163/09	6 months male	Ulcus corneae OS Keratitis pannosa OS
	4	Pekingese CAN 2010/09	4 years male	Ulcus et granulatio corneae OS, Keratitis pannosa et pigmentosa OS
	5	Pug CAN 1805/09	4 years female	Descemetocele OS Keratitis pannosa OS
	6	Shih-tzu CAN 1742/09	7 years male	Descemetocele OS, Keratitis et keratomalacia OS
	7	Shih-tzu CAN 2343/09	7 years male	Descemetocele OS Keratitis OS

*OS - oculi sinistri

Table 4. Values of hematology indicators in peripheral blood of clinical healthy dogs (Group A) during 30 days of experiment (1st sampling blood - shortly before therapy; 2nd sampling blood - three days after therapy; 3rd sampling blood - 10 days after therapy; 4th sampling blood - within 30 days after therapy).

An indicator	Baseline	1*	2*	3*	4*
Erythrocytes ($\times 10^{12}$)	5.5 - 8,5	6.2 \pm 2.0	5.8 \pm 2.6	6.4 \pm 1.7	5.9 \pm 3.7
Hemoglobin (g/L)	120 - 180	133 \pm 0.9	126 \pm 2.4	136 \pm 2.0	134 \pm 2.8
Hematocrit (%)	37 - 55	43 \pm 2.1	38 \pm 2.4	47 \pm 2.2	46 \pm 2.7
MCV (fL)	60 - 77	67 \pm 2.5	63 \pm 2.0	65 \pm 2.4	63 \pm 1.7
MCH (PG)	19 - 23	21 \pm 1.4	24 \pm 1.7	22 \pm 1.9	23 \pm 3.4
MCHC (g/L)	320 - 360	334 \pm 2.3	337 \pm 2.6	342 \pm 0.3	345 \pm 2.7
Leukocytes ($\times 10^9$)	6 - 17	9 \pm 2.6	8 \pm 2.4	7.5 \pm 2.6	8.3 \pm 1.9
Undivided (%)	0 - 1	0 \pm 2.3	1 \pm 2.2	0 \pm 2.5	0 \pm 2.0
Segmented (%)	60 - 77	63 \pm 2.7	61 \pm 2.1	67 \pm 2.4	64 \pm 0.9
Lymphocytes (%)	12 - 33	18 \pm 1.3	21 \pm 2.5	20 \pm 2.1	19 \pm 2.7
Eosinophils (%)	2 - 10	5 \pm 2.7	6 \pm 2.3	5.5 \pm 2.5	6.2 \pm 2.8
Monocytes (%)	3 - 10	4 \pm 2.0	4.6 \pm 2.1	5 \pm 2.4	5.4 \pm 2.6
Platelets ($\times 10^9$)	200 - 700	521 \pm 0.9	499 \pm 1.9	532 \pm 1.4	532 \pm 1.7

* mean \pm standard deviation

Table 5. Values of hematology indicators in peripheral blood of dogs treated by classic ophthalmological approach (Group B) during 30 days of experiment (1st sampling blood - shortly before therapy; 2nd sampling blood - three days after therapy; 3rd sampling blood - 10 days after therapy; 4th sampling blood - within 30 days after therapy).

An indicator	Baseline	1*	2*	3*	4*
Erythrocytes (x10 ¹²)	5.5 - 8,5	6.3 ± 2.7	6.0 ± 3.8	6.3 ± 2.7	6.1 ± 2.0
Hemoglobin (g/L)	120 - 180	141 ± 1.7	138 ± 2.3	140 ± 3.1	142 ± 0.9
Hematocrit (%)	37 - 55	45 ± 3.4	47 ± 2.7	41 ± 6.8	47 ± 2.1
MCV (fl)	60 - 77	61 ± 2.2	59 ± 1.3	64 ± 3,6	62 ± 2.5
MCH (PG)	19 - 23	22 ± 2.4	20 ± 2.7	21 ± 2.7	22 ± 1.4
MCHC (g/L)	320 - 360	356 ± 1.9	342 ± 2.0	357 ± 2.8	349 ± 2.0
Leukocytes (x10 ⁹)	6 - 17	10 ± 2.5	10.5 ± 3.4	11 ± 2.6	10.6 ± 2.3
Undivided (%)	0 - 1	0 ± 2.2	0 ± 2.7	1 ± 1.7	1 ± 2.7
Segmented (%)	60 - 77	67 ± 2.4	68 ± 1.7	62 ± 2.8	63 ± 1.3
Lymphocytes (%)	12 - 33	19.4 ± 4.6	21.3 ± 3.4	26 ± 2.7	23.4 ± 2.7
Eosinophils (%)	2 - 10	5.6 ± 2.9	5.9 ± 2.7	6.2 ± 1.7	5.9 ± 2.0
Monocytes (%)	3 - 10	3.2 ± 1.5	4.5 ± 2.0	3.0 ± 3.4	3.6 ± 2.3
Platelets (x10 ⁹)	200 - 700	456 ± 2.8	497 ± 0.9	523 ± 2.7	564 ± 2.7

* mean ± standard deviation

Table 6. Values of hematology indicators in peripheral blood of dogs treated with limbal stem cells allograft (Group C) during 30 days of experiment (1st sampling blood - shortly before therapy; 2nd sampling blood - three days after therapy; 3rd sampling blood - 10 days after therapy; 4th sampling blood - within 30 days after therapy).

An indicator	Baseline	1*	2*	3*	4*
Erythrocytes (x10 ¹²)	5.5 - 8,5	6.5 ± 1.9	6.2 ± 2.7	6.1 ± 4.2	5.9 ± 2.3
Hemoglobin (g/L)	120 - 180	139 ± 2.0	141 ± 2.0	142 ± 1.4	137 ± 2.7
Hematocrit (%)	37 - 55	35 ± 0.9	39 ± 0.9	40 ± 2.3	41 ± 1.3
MCV (fL)	60 - 77	64 ± 2.1	61 ± 2.1	63 ± 2.7	62 ± 2.7
MCH (PG)	19 - 23	21 ± 2.5	20 ± 2.7	19 ± 1.3	21 ± 2.2
MCHC (g/L)	320 - 360	336 ± 2.7	338 ± 1.7	337 ± 2.7	336 ± 2.4
Leukocytes (x10 ⁹)	6 - 17	11 ± 1.7	2 ± 3.4	11.5 ± 2.0	10 ± 1.9
Undivided (%)	0 - 1	1 ± 3.4	1 ± 2.7	1 ± 2.3	1 ± 2.5
Segmented (%)	60 - 77	64 ± 2.7	62 ± 2.7	60 ± 2.2	61 ± 2.2
Lymphocytes (%)	12 - 33	21 ± 1.7	19 ± 1.7	22 ± 3.7	21 ± 2.4
Eosinophils (%)	2 - 10	5 ± 2.7	5.1 ± 3.4	5.1 ± 3.8	5 ± 2.6
Monocytes (%)	3 - 10	3.7 ± 2.0	3.8 ± 4.8	4.0 ± 2.3	3.9 ± 2.4

* mean ± standard deviation

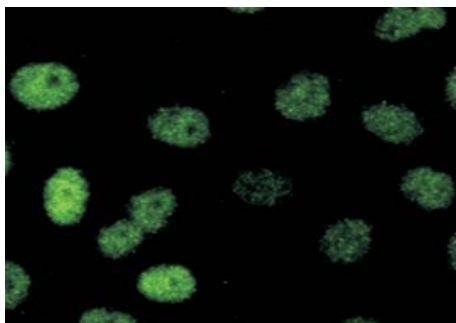


Fig. 4. Immunocytochemical analysis of dog corneal epithelial cells, 5 days after ingrowing, positive for p63 antibody. $\times 100$.

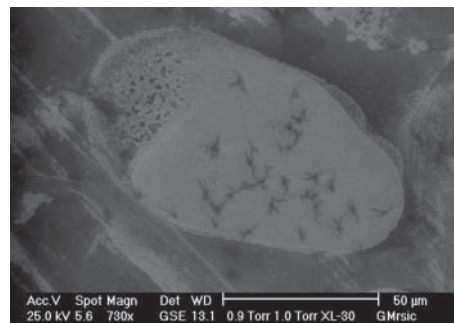

Fig. 5. Electron micrograph of dog limbal cell, 5 days after ingrowing, visualized using electronic microscope XL30 ESEM, Philips, Netherlands (Centre for Forensic Investigations, Research and Expertise „Ivan Vučetić“, Zagreb, Croatia) in which specific membrane receptors are tied fluorescein dye conjugated mouse monoclonal antibody against p63 dog cornea.

Discussion

The stem cells of the eye are located on Vogt's palisades and the limbal epithelial basal layer (TAYLOR, 2000) within the area of contact between the sclera and cornea, the so called limbal region (PELLEGRINI et al, 2014). The exact location of corneal stem cells has been demonstrated using monoclonal antibodies and by digital image analyses of cytology/histology specimens (FIGUEIRO et al., 2007). Recently p63 transcription factor has been identified as a keratinocyte stem cell marker (FERNANDES et al., 2007) which corresponds positively with the results obtained from our study (O'SULLIVAN and CLYNES, 2007). The latter cells migrate from the limbal region, simultaneously dividing/differentiating and homing in the basal epithelial layer of the cornea. Finally, they become terminally differentiated as corneal epithelial cells (BAYLIS et al., 2011). For most of their lifetime these cells divide slowly, but in the case of injury they become much more proliferative. However, limbal deficiency or loss of stem cells is characterized by reduced proliferative capacity, resulting in an abnormal corneal surface (AKPED and FOSTER, 1999). Non-treated limbal deficiency and corneal injuries may result in persistent epithelial defects, conjunctivalization of the cornea, destructive lesions of the basal membrane, and perforation of the cornea (AKPED and FOSTER, 1999). Consequently, surgical intervention is required, but its success has been rather limited. Hence, either a total or partial autograft transplantation is recommended in humans (SANGWAN, 2001) and dog (BRUNELLI et al., 2007) patients with limbal stem cell deficiency. When such transplantation is not possible,

limbal allograft transplants may be used as an alternative (DUA and AZUARA-BLANCO, 2000). More recently, there has been an intensive search for carriers of limbal stem cells (such as the amniotic membrane) which would fix grafted cells at the site of injury. POPOVIĆ et al. (2009a) demonstrated that porcine limbal stem cells can be grown onto carriers, such as contact lenses. Rabbit and human limbal stem cells can also be grown on such lenses, treated with plasma polymers or acrylic acid polymers (DESHPANDE et al., 2009).

Similarly, as DI GIROLAMO et al. (2011) showed with human limbal stem cell autografts, PIRKIĆ et al. (2013) successfully grew cultures of animal limbal stem cell allografts supplemented with autologous serum. By subconjunctival application of either auto- or allografts of limbal stem cells to dogs with corneal injuries, PIRKIĆ et al. (2013) obtained promising results in the healing of corneal defects and justified the introduction of cell-based therapy in veterinary ophthalmology. Namely, ten days following treatment the patients had decreased blepharospasm (by 80 %), reduced secretion (by 75 %) and conjunctival congestion (by 43 %) as well as diminished corneal oedema (by 31 %) and intensity of conjunctival irritation (by 55 %). These more than indicative clinical parameters show that severe lesions of the cornea in dogs may be restored by allograft transplantation of limbal stem cells within a much shorter period of time than by standard surgical procedures. Furthermore, as opposed to other transplantation procedures, corneal transplant does not need to pass the extensive tissue typization procedures to match the recipient. Tissue typization is not necessary for the following reasons: the corneal avascularity, and the exceptional corneal immune privilege.

Numerous scientific investigations describe how the cornea has poorly or completely un- developed molecules of its main histocompatibility complex (BAYLIS et al., 2011), that is it produces anti-inflammatory agents that inhibit inflammatory reaction, and comprise binding places on the surface of the cornea that prevent inflammatory cell action (FORRESTER et al., 2010). Accordingly, the results of our study largely correspond to those mentioned before. During the entire procedure, we did not find any obvious changes within the analysed haematological values, which is in correspondence with the results from NIEDERKORN (2007). Thus it may be assumed that the local use of cell allografts does not affect the overall blood count, nor does it influence the rest of the body. It should be pointed out that cells were obtained from cadavers, and later cultured and used as allotransplants (VLAHOVIĆ et al., 2010). Since the polymorphism of the main tissue system was not so developed, rejections were not noted. Therefore, it appeared that cadaveric allotransplantation is more practical than autotransplantation, because there were no accidental injuries or invasive procedures in the treated animals. The results described in this paper are additional stimulation for founding an Eye Bank at the Faculty of Veterinary Medicine, University of Zagreb. A potential benefit of the proposed study

is also the transfer of knowledge from veterinary ophthalmology to business subjects in the pharmaceutical industry and the broader biomedical aspects of cell-based therapy in domestic animals, particularly pets. The importance of this study for the scientific community is the fact that it is unique research in Croatia and the region in the area of veterinary ophthalmology. This fact could be of relevance for establishing a regional centre for animal stem cell therapy, to remain in step with similar centres in the EU and the World.

Acknowledgements

The current study was supported by the University of Zagreb (Short-term financial support for research 2013./2014; support No. 1.2.1.5, head of support prof. dr. sc. B. Pirkić). This paper is dedicated to assist. Prof. Branka Gršković, PhD, who passed away suddenly.

References

- AKPED, E. K., C. S. FOSTER (1999): Limbal cells transplantation. *Int. Ophthalmol. Clin.* 39, 71-81.
- BAYLIS, O., F. FIGUEIREDO, C. HENEIN, M. LAKO, S. AHMAD (2011): 13 years of cultured limbal epithelial cell therapy: a review of the outcomes. *J. Cell Biochem.* 112, 993-1002.
- BRUNELLI, A. T. J., F. A. M. VICENTE, F. CHAHUD, A. P. ORIÁ, A. A. BOLZAN, C. F. CAMPOS, F. A. DORIA NET, J. L. LAUS (2007): Sclerocorneal limbal cell autograft transplantation in dogs. *Zootec.* 59, 1194-1204.
- BAYLIS, O., F. FIGUEIREDO, C. HENEIN, M. LAKO, S. AHMAD (2011): 13 years of cultured limbal epithelial cell therapy: a review of the outcomes. *J. Cell Biochem.* 112, 993-1002.
- CHUNG, J. H. (1999): Healing of rabbit corneal alkali wounds *in vitro*. *Cornea* 9, 36-40.
- DUA, H. S., A. AZUARA-BLANCO (2000): Limbal cells of corneal epithelium. *Ophthalmol.* 44, 415-425.
- DESHPANDE, P., M. NOTARA, N. BULLETT, J. T. DANIELS, D. B. HADDOW, S. MacNEIL (2009): Development of a surface-modified contact lens for the transfer of cultured limbal epithelial cells to the cornea for ocular surface diseases. *Tissue Eng. Part 15*, 2889-2902.
- DI GIROLAMO, N. (2011): Stem cells of the human cornea. *Br. Med. Bull.* 100, 191-207.
- DUA, H. S., A. AZUARA-BLANCO (2000): Limbal stem cells of corneal epithelium *Surv. Ophthalmol.* 44, 415-425.
- ELSINGHORST, T. A. (2004): New findings on animal diseases published since 2003. *Dogs. Vet. Q.* 26, 18-24.
- FERNANDES, A. M., T. G. FERNANDES, M. M. DIOGO, C. L. Da SILVA, D. HENRIQUE, J. M. CABRAL (2007): Mouse embryonic stem cell expansion in a microcarrier-based stirred culture system. *J. Biotechnol.* 132, 227-236.

- FIGUEIRO, E. C., N. DI GIROLAMO, M. T. CORONEO, D. WAKEFIELD (2007): The phenotype of limbal epithelial stem cells. *Invest. Ophthalmol. Vis. Sci.* 48, 144-156.
- FORRESTER, J. V., H. XU, L. KUFFOVA, A. D. DICK, P. G. McMENAMIN (2010): Dendritic cell physiology and function in the eye. *Immunol. Rev.* 234, 282-304.
- HACKAM, D. G. (2007): Translating animal research into clinical benefit. *BMJ* 334, 163-164.
- HIPP, J., A. ATALA (2008): Sources of stem cells for regenerative medicine. *Stem Cell Rev.* 4, 3-11.
- MATOUSKOVA, E., S. BUCEK, D. VOGTOVA, P. VESELY, A. CHALOUPKOVA, L. BROZ, H. SINGERNOVA, R. PAVLIKOVA KONIGOVA (1997): Treatment of burns and donor sites with human allogeneic keratinocytes grown on acellular pig dermis. *Br. J. Dermatol.* 136, 901-907.
- NIEDERKORN, J. Y. (2007): Immune mechanisms of corneal allograft reject. *Curr. Eye Res.* 32, 1005-1016.
- O'SULLIVAN, F., M. CLYNES (2007): Limbal stem cells, a review of their identification and culture for clinical use. *Cytotech.* 53, 101-106.
- PELLEGRINI, G., P. RAMA, A. DI ROCCO, A. PANARAS, M. DE LUCA (2014): Concise review: hurdles in a successful example of limbal stem cell-based regenerative medicine. *Stem Cell* 32, 26-34.
- PIRKIĆ, B., K. VLAHOVIĆ, M. HOHŠTETER, M. TOMINAC, A. MULJAČIĆ, D. ŠPOLJARIĆ, NJ. GREDELJ ŠIMEC, M. KRESZINGER, M. STEJSKAL, M. POPOVIĆ (2010): *In vitro* cultivation of porcine limbal transplant. *Vet. arhiv* 4, 455-466.
- PIRKIĆ, B., K. VLAHOVIĆ, D. KEZIĆ, M. TOMINAC TRCIN, NJ. GREDELJ ŠIMEC, H. BOROŠAK, M. ABUFFY, L. SLUNJSKI, G. MRŠIĆ, D. ŠPOLJARIĆ, D. MIHELIC, M. POPOVIĆ (2013): Pregledni prikaz postignuća kliničkih ispitivanja stanične terapije u veterinarskoj oftalmologiji na Veterinarskom fakultetu Sveučilišta u Zagrebu. *Vet. st.* 44, 1-6.
- POPOVIĆ, M., M. TOMINAC, K. VLAHOVIĆ, D. KEZIĆ, M. ŠPERANDA, Ž. GRABAREVIĆ, I. POPOVIĆ, B. PIRKIĆ, B. ŠEOL, I. VALPOTIĆ (2009a): *In vitro* cultivation of porcine limbal stem cells *Italian J. Anim. Sci.* 3, 125-127.
- POPOVIĆ, I., M. TOMINAC, M. POPOVIĆ, A. MULJAČIĆ, H. VALPOTIĆ, M. ŠPERANDA, K. VLAHOVIĆ, D. KEZIĆ, D. ŠPOLJARIĆ, I. VALPOTIĆ (2009b): Zuchtung von schweinischer Haut für Transplantation. *Tierärztl. Umschau* 64, 29-35.
- SANGWAN, V. S. (2001): Limbal headquarters in health and disease. *Biosci. Rep.* 21, 385-405.
- TAYLOR, J. A. (2000): The ear and eye, manner: *Color Atlas of Cytology of the Dog and Cat*, ed. Baker, R., J. H. Lumsden, Mosby, Inc. paragraphs Louis, Missouri, USA, pp. 263-276.
- VLAHOVIĆ, K., B. PIRKIĆ, I. POPOVIĆ, H. BOROŠAK, M. HOHŠTETER, I. KIŠ, V. MATIJATKO, A. MULJAČIĆ, D. ŠPOLJARIĆ, M. POPOVIĆ (2010): *In vitro* cultivation of canine limbal transplant. *Acta veterinaria (Beograd)*, 60, 437-447.

Received: 6 February 2014

Accepted: 11 July 2014

PIRKIĆ, B., NJ. GREDELJ ŠIMEC, L. SLUNJSKI, M. ABBAFY, D. KEZIĆ, D. ŠPOLJARIĆ, T. BABIĆ, K. ŠPIRANEC, G. MRŠIĆ, D. MIHELIC, D. MATIČIĆ, M. POPOVIĆ: Vrijednosti hematoloških pokazatelja u pasa liječenih supkonjunktivalnom primjenom staničnog alografta. Vet. arhiv 85, 67-79, 2015.

SAŽETAK

Rožnica, kao izvor matičnih stanica, dobar je medij za njihovu uporabu u veterinarskoj oftalmologiji. U ovom istraživanju koristili smo pse kojima su dijagnosticirana opsežna, kronična stanjivanja središnjeg dijela rožnice, posljedica mehaničkih oštećenja, dodatno komplicirana upalnim procesima. Cilj istraživanja bio je ispitati utjecaj supkonjunktivalne primjene limbalnog staničnog alografta na hematološke pokazatelje u perifernoj krvi pacijenata. Životinje su bile podijeljene u tri pokusne skupine, bez obzira na pasminu, spol i dob. U svakoj skupini bilo je sedam pasa. U skupini A bili su klinički zdravi psi (kontrolna skupina), u skupini B bili su psi kojima su ozljede obrađene konvencionalnim oftalmološkim pristupom, a psima u skupini C oštećenja rožnice bila su liječena supkonjunktivalnom primjenom staničnog alografta. Četiri puta tijekom istraživanja svim su životinjama uzeti uzorci periferne venske krvi za hematološke pretrage. Supkonjunktivalna primjena staničnog alografta nije utjecala na promjenu vrijednosti hematoloških pokazatelja u obrađivanih pasa.

Ključne riječi: pas, matične stanice, limbus, veterinarska oftalmologija
