

The effects of intra-articular tramadol administration on histopathological indices in rat knee joints

Rahmat A. Fatahian Dehkordi^{1*}, Amin Bigham-Sadegh², and Naser Vajdi³

¹Department of Basic Sciences, Faculty of Veterinary Medicine, University of Shahrekord, Shahrekord, Iran

²Department of Clinical Sciences, Faculty of Veterinary Medicine, University of Shahrekord, Shahrekord, Iran

³Postgraduate of University of Shahrekord, Shahrekord, Iran

FATAHIAN DEHKORDI, R. A., A. BIGHAM-SADEGH, N. VAJDI: The effects of intra-articular tramadol administration on histopathological indices in rat knee joints. Vet. arhiv 84, 667-676, 2014.

ABSTRACT

The aim of this study was to investigate the effect of intra-articular injections of saline and tramadol on the articular cartilage in rat knee joints. Twenty-five adult Wistar rats were used in this experiment. They were randomly assigned to two groups, control (n = 5) and experimental (n = 20) and the latter was subdivided into four groups (each group n = 5). Saline was administered intra-articularly into the knee joints in the controls (group 1) and tramadol with different doses was injected into the knee joints of the experimental groups. In groups 2, 3, 4 and 5 different concentrations, 0.1, 0.25, 1.0 and 2.5 mg/mL respectively, of available tramadol were administered intra-articularly into the knee joints. The results showed that there were no pathological changes in the saline-treated control joints ($P > 0.05$). Joints treated with tramadol displayed significantly more pathological changes than the saline joints ($P < 0.05$). Group 5 (2.5 mg/mL) showed maximum pathological changes as compared to the other treatment groups and saline injection. Histological results in all parameters showed that there was no significant difference between joints that received tramadol in group 2, compared to saline-treated joints ($P > 0.05$). Joints that received tramadol in group 3 (0.25 mg/mL) showed no significant difference as compared with control joints in all histological indices, except for cell count. Joints treated with tramadol in groups 4 and 5 revealed significant histological changes compared to control joints in all histological indices. We conclude that intra-articular tramadol in high dosages (especially 2.5 mg/mL) causes histopathological changes in rat knee joints.

Key words: histopathology, knee joint, rat, saline, tramadol

*Corresponding author:

Dr. Rahamt Allah Fatahian Dehkordi, Department of Anatomy, Faculty of Veterinary Medicine, University of Shahrekord, Shahrekord, Iran, Phone: +98 381 4424 427; E-mail: fatahian_1349@yahoo.com

Introduction

Pain control has always been one of the most important issues after arthroscopic surgery, and in outpatient surgery, its importance has doubly increased (KALSO et al., 1997). The effects of intra-articular injections of some drugs on articular cartilage of knee joints have been studied (ELSHARNOUBY et al., 2008; MARRET et al., 2005; MILLIGAN et al., 1988; MøINICHE et al., 1999; REUBEN and CONNELLY, 1995; RICHARDSON et al., 1997; YANG et al., 1998). Some drugs administered intra-articularly have different histopathological effects on articular cartilage and synovium (IRWIN et al., 1998). Neostigmine treatment caused more histopathological changes in the synovial membrane and articular cartilage of the rabbit knee joint when compared with intra-articular bupivacaine treatment (DOGAN et al., 2004).

The discovery of opioid receptors in synovial articulation makes it conceivable that intra-articular administration of opioid drugs may have analgesic and anti-inflammatory properties in some species (LINDEGAARD et al., 2010; SHEEHY et al., 2001). Tramadol is a very weak μ -opioid receptor agonist, that induces serotonin release and inhibits the reuptake of noradrenalin in the descending inhibitory pathways, like $\alpha 2$ adrenoceptor agonists. It has been shown that tramadol is an effective local anesthetic in minor surgery, especially in arthroscopy (ALTUNKAYA et al., 2004); however, histologically its effect on the articular cartilage has remained ambiguous until now.

IRWIN et al. (1998) showed that intra-articular ketorolac and morphine may cause inflammatory cell infiltration, hyperplasia and hypertrophy of the cells of the synovial membrane, or inflammation of the articular cartilage of the knee joint.

However, based on the perceived experiences of intra-articular injections, the objective of the present study was to investigate the effect of intra-articularly available tramadol administration and saline treatment of joints on the histopathological indices of the articular cartilage in rat knee joints.

Materials and methods

Animals. Twenty-five adult male Wistar rats, with 270 ± 10 g body mass, were used in this study. The rats were housed and maintained under standard conditions, and food and water were given ad libitum. The experimental protocol was approved by the Animal Care and Experiment Committee of the University, and the experiments were conducted in accordance with institutional guidelines.

Operative procedure. Animals were randomly divided into two groups: the control (n = 5) and the experimental (n = 20), the latter of which was subdivided into four groups of five animals each. Choice of animal groups was performed using the alternate selection method. The skin of the knee region in each rat was shaved with electric clippers and prepared with antiseptic solution of 70% alcohol. For sedation in rats, ketamine

hydrochloride was give at a dosage of 40 mg/kg and intra-muscular xylazine 1 mg/kg. The articular cavity was recognized by extension and flexion movements of the femur and tibia bones. A 22 gauge needle was then inserted into the articular space, and the first aspiration was performed, as well as aspiration of the synovial fluid, and the drugs were injected. The rats in group 1 (control group) received no drugs, but were given 1cc of Normal Saline solution (0.9% NaCl) in the knee joints intra-articularly. Groups 2, 3, 4 and 5 were injected intra-articularly with 1cc in concentrations of 0.1, 0.25, 1.0 and 2.5 mg/mL of tramadol respectively. The animals were immediately transferred to the laboratory animal house to normal conditions.

Histopathological assessment. After 10 days, the animals were euthanized with minimal pain. Knee joints were removed by osteotomy of the femoral and tibia neck about 1 cm from the joint, and samples were embedded in 10% buffered formalin solution and were then transferred to the de-calcified (5% nitric acid) solution. After de-calcification, tissue sections were prepared at a thickness of 5 µm. Finally, the sections were stained with haematoxylin and eosin. Histopathological changes in the articular cartilage were assessed, and all data recorded.

For easier calculation of histological indices, the entire length of the articular cartilage was divided into two equal parts (cranial and caudal regions) and then parameters were calculated.

Inflammation of the articular cartilage was graded by a pathologist blinded for the treatment groups, using the following scale: 1: no inflammation; 2: minor inflammation (mild congestion and swelling); 3: moderate inflammation (congestion and swelling, slight number of neutrophils); 4: moderate inflammation (neutrophils and macrophages, synoviocyte hyperplasia); and 5: severe inflammation (neutrophils, exude fibrin, synoviocyte hyperplasia). Using a scale modified by MANKIN et al. (1971) inflammatory cell infiltration, cell hyperplasia and cell hypertrophy in the synovial membrane were evaluated based on the following scale: 0, normal; 1, mild; 2, moderate; 3, severe.

Finally, data were statistically analyzed by SPSS software v15.5; We used the Mann-Whitney U-test to compare different treatments in each group and to compare the control and treatments at different concentrations. $P < 0.05$ was considered significant.

Results

There were no intra-operative and post-operative deaths due to drug injection. Table 1 shows the results of the pathological evaluation of the rat knee joints regarding pathological indices.

Histopathological assessment. The results obtained from pathological analysis of articular cartilage inflammation, inflammatory cell infiltration, cell hyperplasia and cell

hypertrophy of the synovial membrane revealed that there were no significant differences between drug treatments with tramadol at the four drug dosages.

Table 1. Indices of histopathological differences in rat knee joints after intra-articular treatment with saline (G1) and tramadol in different dosages (0.1, 0.25, 1.0 and 2.5 mg/mL), calculated by ordinary histology in groups G2 to G5 (n = 5 per group).

Treatment group		Synovial membrane changes																
		Articular cartilage inflammation					Inflammatory cell infiltration			Cell hyperplasia				Cell hypertrophy				
		1	2	3	4	5	0	1	2	3	0	1	2	3	0	1	2	3
Control	G1	5	-	-	-	-	5	-	-	-	4	1	-	-	5	-	-	-
Experimental	G2	4	1	-	-	-	5	-	-	-	4	1	-	-	5	-	-	-
	G3	3	2	-	-	-	4	1	-	-	3	2	-	-	4	1	-	-
	G4	-	4	1	-	-	2	3	-	-	-	5	-	-	-	4	1	-
	G5	-	2	3	-	-	-	3	2	-	-	2	3	-	-	2	3	-

In general, the joints that received tramadol exhibited significantly greater inflammation of the articular cartilage as compared with joints treated with saline ($P < 0.05$). Greater inflammation of the articular cartilage was observed in the joints of animals in groups 4 and 5 compared with groups 2 and 3 ($P < 0.05$). No inflammatory cell infiltration of the synovial membrane was seen in any of the joints in the control groups. The least inflammatory cell infiltration was observed in the joints of animals in the control group compared to treatment animals ($P < 0.05$).

All joints treated with tramadol showed mild alterations in synovial membrane cell hyperplasia ($P < 0.05$). The joints that received tramadol displayed significantly more cell hyperplasia than saline-treated joints ($P < 0.05$). All joints treated with tramadol showed moderate synovial membrane cell hypertrophy in groups 4 and 5 as compared with groups 2 and 3. All joints that received tramadol showed significantly more cell hypertrophy than the saline-treated joints ($P < 0.05$), except for group 2, which was similar to the controls.

Results obtained from histological examination of cranial and caudal parts of the articular cartilage (Table 2) revealed a slight increase in cartilage diameter between groups 2 and 3 as compared with the joints treated with saline (controls) and this was followed by a larger increase between groups 4 and 5 than those of the control group. However, the mean cartilage diameter demonstrated a significant difference between groups 4 and 5 in comparison with the control ($P < 0.05$). Also there was significant difference between the fourth and fifth groups ($P < 0.05$).

Table 2. Comparison of the mean morphometrical indices in saline and tramadol received.

Parameter	Region	Group				
		Control	Experimental (mg/mL)			
		1	2	3	4	5
Cartilage diameter (μm)	cranial	12.7 \pm 0.58 ^{ab}	12.8 \pm 0.24	13.1 \pm 0.35	14.45 \pm 0.62 ^{ac}	15.4 \pm 0.27 ^{bc}
	caudal	12.4 \pm 1.34 ^{de}	12.6 \pm 0.47	13.07 \pm 0.43	14.28 \pm 0.56 ^{df}	15.38 \pm 0.3 ^{ef}
Cell diameter (μm)	cranial	1.25 \pm 0.06 ^{gh}	1.15 \pm 0.07	1.09 \pm 0.05	1.05 \pm 0.12 ^g	1.01 \pm 0.1 ^h
	caudal	1.23 \pm 0.08 ^{ij}	1.12 \pm 0.1	1.1 \pm 0.07	1.06 \pm 0.09 ⁱ	1.0 \pm 0.08 ^j
Nuclear diameter (μm) _r	cranial	0.8 \pm 0.04 ^{kl}	0.81 \pm 0.02	0.73 \pm 0.03	0.7 \pm 0.02 ^k	0.68 \pm 0.03 ^l
	caudal	0.84 \pm 0.02 ^{mn}	0.82 \pm 0.03	0.71 \pm 0.03	0.68 \pm 0.03 ^m	0.66 \pm 0.02 ⁿ
Cell number ($\times 40$)	cranial	5.4 \pm 0.74 ^{opq}	6.2 \pm 1.8	7.6 \pm 1.43 ^o	7.7 \pm 1.2 ^p	7.8 \pm 1.5 ^q
	caudal	5.8 \pm 0.7 ^{stu}	6.1 \pm 1.2	7.4 \pm 1.03 ^s	7.6 \pm 1.1 ^t	7.9 \pm 1.35 ^u
Cell number ($\times 10$)	cranial	45.2 \pm 14.2 ^{vwx}	47.3 \pm 11.2	48.4 \pm 8.63 ^v	49.4 \pm 9.84 ^w	58.2 \pm 10.95 ^x
	caudal	43.2 \pm 14.2 ^{yz}	46.3 \pm 11.2	47.2 \pm 7.93 ^y	47.9 \pm 8.94 ^z	57.2 \pm 9.85 ^a

The total values are mean \pm SEM; Similar small letters in each row: significant at <0.05

Results obtained from histological analysis of the cranial and caudal parts of articular cartilage displayed a large decrease in cell and nuclear diameter in the joints that received tramadol (experimental group) as compared with the control group. A significantly greater decrease of cell and nuclear diameter occurred in groups 4 and 5 as compared with the control group ($P < 0.05$). Nevertheless, there was no significant difference between the fourth group in comparison with the fifth group ($P > 0.05$). According to the data obtained from micrometric analysis of the cranial and caudal parts of the articular cartilage, a larger increase in the cell count was detected on different magnifications in experimental groups than in the control. However, significant differences were only observed between groups 3, 4 and 5 as compared with the control group in cell count on different magnifications ($P < 0.05$), but there was no significant difference between the third, fourth and fifth groups when compared with each other.

The results obtained from the present study, their statistical significance and histological structure are shown respectively in Figs. 1 and 2.

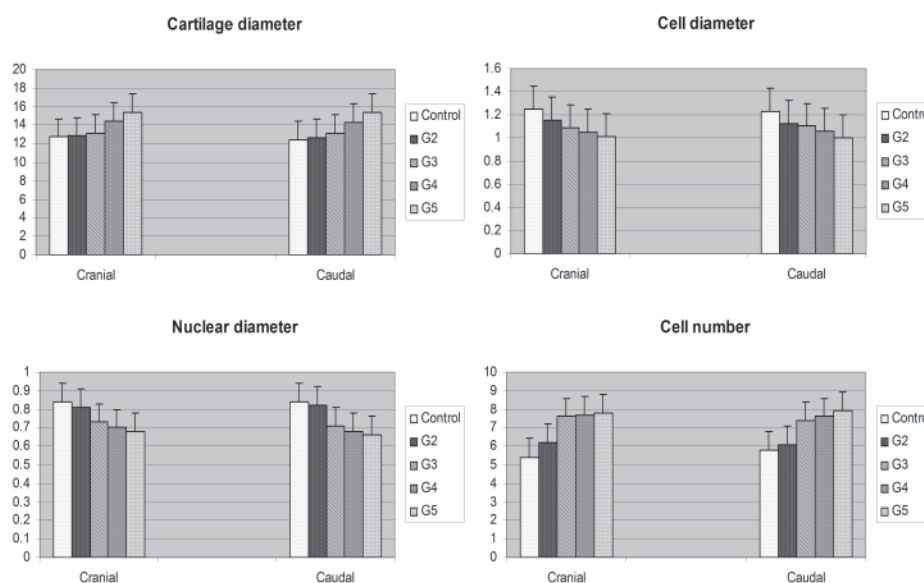


Fig. 1. Histograms showing changes in diameter of cartilage (μm), cells (μm) and nucleus and cells number among cranial and caudal parts of cartilage tissue in rat knee joint. Cranial and caudal parts had not significant difference.

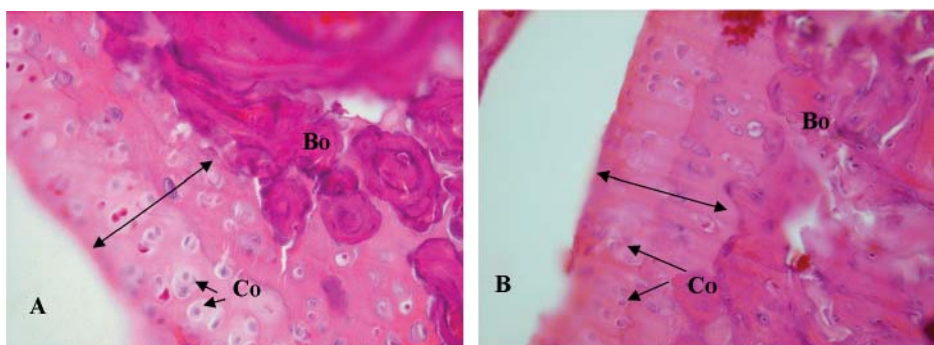


Fig. 2. Photomicrograph of articular cartilage structure and the underlying dense bone (Bo) treated with injection of saline (A) and tramadol (B); Thickness chondral (The bi-directional arrows), chondrocytes with lacuna (Co), (magnification $\times 40$, H&E staining).

Discussion

Efficient and sufficient postoperative analgesia is considered to be an essential requirement for day case surgery (EL-HAMAMSY and DORGHAM, 2009). After arthroscopy, postoperative analgesic has also been tested after the intra-articular administration of routine local anesthetics (KHOURY et al., 1992). A study of tramadol and its metabolite was performed by GIORGI et al. (2010) in donkeys and the efficiency of intra venous administration was concluded. Its local anesthetic effects were exhibited when administered as an epidural in horses (NATALINI and ROBINSON, 2000). However, there are no data on the effects of tramadol on the histomorphometrical properties of the articular cartilage after intra-articular administration in rats. Despite the fact that little is known about administration of intra-articular tramadol in rat, in the present study different concentrations of tramadol were used, administered intra-articularly, and histological indices were evaluated.

Pathological changes. In our study, intra-articular tramadol treatment (at high dosages) caused more inflammation in comparison with saline treatment. However, more inflammation in articular cartilage, and more inflammatory cell infiltration, hyperplasia and hypertrophy were obvious in the synovial membrane compared with intra-articular saline treatment. The histopathological changes were minimal in groups 2 and 3 following intra-articular administration, but these changes were slightly higher in groups 4 and 5 after treatment. In this study, intra-articular tramadol treatment at high dosages caused further histopathological changes in the synovial membrane and the articular cartilage of the rat knee joints, compared with intra-articular saline. Therefore, the results of the current study showed that tramadol in low concentrations is an agent which can be used safely for intra-articular administration.

Histological changes. In the present study, intra-articular tramadol treatment caused more histological changes in groups 4 and 5 in the articular cartilage of the rat knee joint when compared with groups 2 and 3 and intra-articular saline. However, these changes were significant between groups 4 and 5 rather than the other groups. Only the mean cell count in group 3 (0.25 mg/mL) displayed a significant difference as compared with the control group. Regardless of this group, it seems that the fourth and further fifth groups had the most histological changes in all measured parameters.

According to the results of morphometrical analyses at different doses of tramadol, it seems that the animal's health is secure at low doses of tramadol when injected intra-articularly. Different doses of various drugs have been used in humans in the intra-articular form. In humans, the intra-articular doses of bupivacaine are 0.25% in 40 mL and 0.5% in 30 mL (COOK et al., 1997; SMITH et al., 1992); in rabbits, a dose of 0.5%, 0.25 mL from bupivacaine showed histopathological changes in articular cartilage (DOGAN

et al., 2004). Also, the intra-articular dosage of neostigmine used in humans after knee surgery is 125 to 500 µg (YANG et al., 1998).

Although in humans the drugs are administered intra-articularly at almost 30-40 mL, nevertheless, in this study it was decided to use different doses (0.1, 0.25, 1.0 and 2.5 mg/mL) of tramadol for the knee joints of rats. In the present study, only the histopathological effects of various doses of this drug were investigated. It should be noted that it may not be possible to compare histopathological findings in rat knee joints directly with human joints, because they are difficult to study. However, rats are used as a comfortable animal model for histological investigations. The results of our study showed that more attention should be paid to intra-articular tramadol injection. Nevertheless, some authors have shown that tramadol may be a good choice for minor surgery using local anesthesia because of its sufficient local anesthetic and analgesic effects (ALTUNKAYA et al., 2004).

In some animals without intra-articular drug injection, defects in the posterior weight-bearing area of the medial femoral condyles also showed decreased cellularity, with a small number of round cells with the morphology of chondrocytes (ARGUN et al., 2010). KARVONEN et al. (1994) reported significant cartilage thinning with age in the weight-bearing aspect of the femoral condyles of subjects without drug administration. The results obtained from our experimental study provide support and incentive.

Histopathological changes of this drug usage were studied for the first time. It was concluded that intra-articular tramadol injection in high dosages, especially 2.5 mg/mL, may cause pathological changes and 1.0 mg/mL histological changes in the articular cartilage of the rat knee joint. Overall, a concentration of 2.5 mg/mL may be an unsafe dosage for intra-articular treatments.

Acknowledgements

This work was financially supported by the University of Shahrekord, Iran.

References

- ALTUNKAYA, H., Y. OZER, E. KARGI, I. OZKOCAK, M. HOSNUTER, C. B. DEMIREL, O. BABUCCU (2004): The postoperative analgesic effect of tramadol when used as subcutaneous local anesthetic. *Anesth. Analg.* 99, 1461-1464.
- ARGUN, M., M. ONER, A. GUNEY, M. HALICI, O. TEMIZYUREK, O. CANOZ (2010): The healing of full-thickness articular cartilage defects in rabbits: successful results with fibroblast growth factor. *Eklemler Hastalik Cerrahisi* 21, 147-152.
- COOK, T., J. TUCKEY, J. NOLAN (1997): Analgesia after day-case knee arthroscopy: double-blind study of intra-articular tenoxicam, intra-articular bupivacaine and placebo. *Br. J. Anaesth.* 78, 163-168.

- DOGAN, N., A. ERDEM, Z. ERMAN, M. KIZILKAYA (2004): The effects of bupivacaine and neostigmine on articular cartilage and synovium in the rabbit knee joint. *J. Int. Med. Res.* 32, 513-519.
- EL-HAMAMSY, M., D. DORGHAM (2009): Intra-articular adjuvant analgesics following knee arthroscopy: comparison between dexmedetomidine and fentanyl. *Res. J. Med. Sci.* 4, 355-360.
- ELSHARNOUBY, N. M., H. E. EID, N. F. A. ELEZZ, A. N. MOHARRAM (2008): Intraarticular injection of magnesium sulphate and/or bupivacaine for postoperative analgesia after arthroscopic knee surgery. *Anesth. Analg.* 106, 1548-1552.
- GIORGI, M., G. SACCOMANNI, V. ANDREONI (2010): Pharmacokinetics of tramadol after epidural administration in horses. *J. Equine Vet. Sci.* 30, 44-46.
- IRWIN, M., K. CHEUNG, J. NICHOLLS, N. THOMPSON (1998): Intra-articular injection of ketorolac in the rat knee joint: effect on articular cartilage and synovium. *Br. J. Anaesth.* 80, 837-839.
- KALSO, E., M. R. TRAMER, D. CARROLL, H. J. MCQUAY, R. A. MOORE (1997): Pain relief from intra-articular morphine after knee surgery: a qualitative systematic review. *Pain* 71, 127-134.
- KARVONEN, R., W. NEGENDANK, R. TEITGE, A. REED, P. MILLER, F. FERNANDEZ-MADRID (1994): Factors affecting articular cartilage thickness in osteoarthritis and aging. *J. Rheumatol.* 21, 1310-1318.
- KHOURY, G. F., A. C. CHEN, D. E. GARLAND, C. STEIN (1992): Intraarticular morphine, bupivacaine, and morphine/bupivacaine for pain control after knee videarthroscopy. *Anesthesiology* 77, 263-266.
- LINDEGAARD, C., M. H. THOMSEN, S. LARSEN, P. H. ANDERSEN (2010): Analgesic efficacy of intra-articular morphine in experimentally induced radiocarpal synovitis in horses. *Vet. Anaesth. Analg.* 37, 171-185.
- MANKIN, H. J., H. DORFMAN, L. LIPPIELLO, A. ZARINS, A. (1971): Biochemical and metabolic abnormalities in articular cartilage from osteo-arthritic human hips II. Correlation of morphology with biochemical and metabolic data. *J. Bone Joint Surgery* 53, 523-537.
- MARRET, E., M. GENTILI, M. P. BONNET, F. BONNET (2005): Intra-articular ropivacaine 0.75% and bupivacaine 0.50% for analgesia after arthroscopic knee surgery: a randomized prospective study. *Arthroscopy* 21, 313-316.
- MILLIGAN, K. A., M. J. MOWBRAY, L. MULROONEY, P. J. STANDEN (1988): Intra-articular bupivacaine for pain relief after arthroscopic surgery of the knee joint in daycase patients. *Anaesthesia* 43, 563-564.
- MØINICHE, S., S. MIKKELSEN, J. WETTERSLEV, J. B. DAHL (1999): A systematic review of intra-articular local anesthesia for postoperative pain relief after arthroscopic knee surgery. *Region. Anesth. Pain Med.* 24, 430-437.
- NATALINI, C. C., E. P. ROBINSON (2000): Evaluation of the analgesic effects of epidurally administered morphine, alfentanil, butorphanol, tramadol, and U50488H in horses. *Am. J. Vet. Res.* 61, 1579-1586.

- REUBEN, S. S., N. R. CONNELLY (1995): Postoperative analgesia for outpatient arthroscopic knee surgery with intraarticular bupivacaine and ketorolac. *Anesth. Analg.* 80, 1154-1157.
- RICHARDSON, M. D., A. R. BJORKSTEN, J. A. HART, K. MCCULLOUGH (1997): The efficacy of intra-articular morphine for postoperative knee arthroscopy analgesia. *Arthroscopy* 13, 584-589.
- SHEEHY, J. G., P. W. HELLYER, G. E. SAMMONDS, K. R. MAMA, B. E. POWERS, D. A. HENDRICKSON, K. R. MAGNUSSON (2001): Evaluation of opioid receptors in synovial membranes of horses. *Am. J. Vet. Res.* 62, 1408-1412.
- SMITH, I., R. A. SHIVELY, P. F. WHITE (1992): Effects of ketorolac and bupivacaine on recovery after outpatient arthroscopy. *Anesth. Analg.* 75, 208-212.
- YANG, L. C., L.-M. CHEN, C.-J. WANG, H. BUERKLE (1998): Postoperative Analgesia by Intra-articular Neostigmine in Patients Undergoing Knee Arthroscopy. *Anesthesiology* 88, 334-339.

Received: 9 October 2013

Accepted: 11 July 2014

FATAHIAN DEHKORDI, R. A., A. BIGHAM-SADEGH, N. VAJDI: Učinci intra-artikularno primijenjenog tramadola na histopatološki nalaz koljenog zgloba u štakora. *Vet. arhiv* 84, 667-676, 2014.

SAŽETAK

Cilj istraživanja bio je utvrditi učinak primjene fiziološke otopine soli i tramadola na hrskavicu koljenog zgloba štakora. U pokusu je korišteno 25 odraslih Wistar štakora koji su metodom slučajnog izbora bili podijeljeni u dvije skupine, kontrolnu (n = 5) i pokusnu (n = 20). Pokusna skupina je naknadno podijeljena u 4 podskupine po 5 štakora. Fiziološka otopina bila je unesena u koljeni zglob štakora kontrolne skupine (skupina 1), dok je tramadol bio primijenjen u različitim dozama u koljeni zglob štakora pokusnih skupina. Skupina 2 primila je 0,1 mg/mL, skupina 3 primila je 0,25 mg/mL, dok su skupine 4 i 5 primile 1,0 odnosno 2,5 mg/mL tramadola. Rezultati su pokazali da nije bilo patoloških promjena u zglobovima kontrolne skupine (P>0,05). Zglobovi u koje je bio primijenjen tramadol pokazali su značajno (P<0,05) više patoloških promjena u odnosu na kontrolnu skupinu. Skupina 5 (2,5 mg/mL) pokazala je najviše patoloških promjena u usporedbi s ostalim pokusnim i kontrolnom skupinom. Histološki nalazi pokazali su da nije bilo statistički značajnih razlika (P>0,05) između skupine 2 koja je primila tramadol i skupine kojoj je bila primijenjena fiziološka otopina kuhinjske soli. U štakora skupine 3, kojima je u zglobove bio primijenjen tramadol u količini od 0,25 mg/mL, također nisu utvrđene značajne razlike u odnosu na kontrolnu skupinu za sve histološke pokazatelje osim za broj stanica. Primjena tramadola u zglobove štakora u skupinama 4 i 5 dovela je u usporedbi s kontrolnom skupinom do značajnih promjena svih histoloških pokazatelja. Na temelju navedenih rezultata, zaključuje se da primjena većih doza tramadola (osobito 2,5 mg/mL) u koljeni zglob štakora dovodi do histopatoloških promjena.

Ključne riječi: histopatologija, koljeni zglob, štakor, fiziološka otopina, tramadol
