

## The effect of a misapplied progesterone-releasing intravaginal device on fertility in a Holstein-Friesian cow - case report

Duygu Kaya<sup>1</sup>, Serhan S. Ay<sup>2\*</sup>, and Selim Aslan<sup>3</sup>

<sup>1</sup>Kafkas University, Faculty of Veterinary Medicine, Department of Obstetrics and Gynaecology, Kars, Turkey

<sup>2</sup>Ondokuz Mayıs University, Faculty of Veterinary Medicine, Department of Obstetrics and Gynaecology, Samsun, Turkey

<sup>3</sup>Ankara University, Faculty of Veterinary Medicine, Department of Obstetrics and Gynaecology, Ankara, Turkey

---

**KAYA, D., S. S. AY, S. ASLAN: The effect of a misapplied progesterone-releasing intravaginal device on fertility in a Holstein-Friesian cow. Vet. arhiv 84, 189-197, 2014.**

### ABSTRACT

In this case report, the surgical removal of a progesterone-releasing intravaginal device (PRID<sup>®</sup>, 1.55 g of progesterone) found adhered to the uterus was performed, and its effect on fertility in a Holstein-Friesian cow evaluated. No data older than six months was available on the cow; however, during the preceding six-month period, the animal showed no signs of estrus. Interestingly, in the course of a reproductive examination, a PRID-like spiral mass was identified on the right uterine horn. Following diagnosis of the mass, surgical removal was considered. Right flank laparotomy was selected as the surgical entry site. Approximately one month after surgery, the cow showed signs of estrus, but no insemination was performed until the third cycle. After insemination, the cow became pregnant and completed the gestation period. Therefore, we concluded that the PRID may have caused anestrus, and that right flank laparotomy was a safe procedure for the removal of a PRID from the uterus, and particularly to recover fertility, in this case.

**Key words:** anestrus, cow, fertility, misapplied progesterone

---

### Introduction

Progesterone is naturally secreted from the corpus luteum during the luteal phase and gestation periods in cows (NISWENDER et al., 2000). The main reasons for administering exogenous progesterone in the cattle industry are sexual synchronization (ODDE, 1990), and as a form of therapy for certain reproductive disorders such as ovarian cysts (ZULU et

---

\*Corresponding author:

Serhan Serhat Ay, DVM, Ph.D, Assistant Professor, Ondokuz Mayıs University, Faculty of Veterinary Medicine, Department of Obstetrics and Gynaecology, 55139, Samsun, Turkey. Phone: +90 362 3121 919-1226; Fax: +90 362 4576 922; E-mail: serhan.ay@gmail.com or serhan.ay@omu.edu.tr

al., 2003). For these purposes, it is administered through any of the following routes: oral, intravaginal, implants or injections.

Intravaginal devices, such as a PRID (Progesterone-Releasing Intravaginal Device; 1.55 g of progesterone and 10 mg of estradiol benzoate in a capsule), CIDR (Controlled Internal Drug Release; 1.38 g of progesterone), or CIDR-B (1.9 g of progesterone), are designed to release progesterone for as long as they remain in the vagina. These devices are covered in silicone-mixed progesterone and are routinely used in cattle practice (MACMILLIAN and PETERSON, 1993; ALLOC and PETERS, 2004; BOOTHE and MAYA, 2011).

The PRID has an approximately 8-cm long silastic coil with an outer diameter of 4.5 cm. Before insertion, it is tightly coiled around the external part of the applicator and its diameter is reduced to 2.5 cm. However, once inserted into the vagina, a large area of the device comes into contact with the vaginal mucosa, where it releases the progesterone (WALSH et al., 2008).

To the best of our knowledge, this is the first description of the surgical removal of a PRID found adhered to the uterus in a Holstein-Friesian cow.

### **Case presentation**

During a routine examination on a commercial dairy farm, a lactating Holstein-Friesian cow was identified incidentally. The cow was one of 200 dairy cows purchased from another farm. Upon analysing the data of the animals examined, this cow was noted to have shown no signs of estrus, and had not been given any treatment for six months. However, no prior data was available on the cow, except for the preceding six months. Clinical examination of the cow was conducted with respect to its general health condition, milk quality, udder consistency and reproductive ability, just prior to treatment. The animal was certified to be clinically healthy, showing the normal range for the parameters checked during initial physical examination, such as skin turgor, capillary refill time, membrane colour, rectal temperature, heart and respiratory rate. The final body condition score was 3.25 on a 5-point scale. While examining the reproductive tract by transrectal palpation, a PRID-like spiral mass was identified on the right uterine horn. However, the diameters and consistency of the uterine horn could not be evaluated because of the mass, although the uterus was in the pelvic cavity. The ovaries were found to be small (approximately 15 mm wide and 25 mm length), lacking luteal and follicular structures, during both rectal palpation and ultrasonographic examination. During transrectal ultrasonography, the border enhancement between the endometrium and myometrium was markedly visible as hyperechoic areas. Approximately two-thirds of uterine lumen was shown to be non-homogenous. Although the general view of this image was hyperechoic, some hypoechoic areas were determined. Beside the hyperechoic areas around the uterine horn, there was a mass and its acoustic shadow in the ventral side

of uterine horn, as seen in the ultrasonographic images. Upon vaginoscopic examination, the uterine cervix was determined to be closed, small and clear. There were no sign of vaginal discharge, odour or scarring on the vaginal wall and the vaginal mucosa appeared to be normal in colour. The surgery was scheduled to be performed two weeks after the first examination and standing right flank laparotomy was selected as the procedure. Surgery was performed using the incisional line block anaesthesia technique. A 12 cm incision was made, 8 cm cranially to the tuber coxae and parallel to the last rib. The abdominal cavity was scanned and the mass was identified as a PRID, which was found twisted on the right uterine horn (Fig. 1). Thinning on the right dorsal side of the uterine body was noted. Widespread adhesions were found between the right uterine horn and dorsal part of the cecum. Secondary adhesions were identified between the uterine wall and the PRID cord; otherwise, the majority of the PRID cord was found to have dissolved. Both uterine horns were symmetrical and smooth. The examination of the ovaries during surgery revealed similar findings to transrectal palpation: they were almond-sized, with no functional structures evident, that is, the total absence of luteal or follicular structures.

Based on these findings, the surgery was performed in two steps. In the first step, the widespread adhesions were separated by blunt dissection. Thus, the PRID and its connection to the uterine wall became clearly visible. In the second step, the PRID and its remnant cord were removed. When the surgically removed PRID was examined, dissolved silastic material was seen at the point of removal (Fig. 2). No haemorrhaging occurred during these processes. After removal of the PRID, the uterus was flushed with warm (38 °C) saline solution. The peritoneum, abdominal muscles and subcutaneous tissues were sutured separately using absorbable sutures (Vicryl, braided material, Ethicon: USP 2 and 0). The skin was closed with non-absorbable material (Silk, Ethicon: USP 2). During the operation, a saline solution (5 mL/kg/hr) was administered.

Postoperatively, the cow was given ceftiofur hydrochloride (Excenel RTU, Pfizer) immediately after the surgery: 1.0 mg/kg intrauterinely only once, and 1.0 mg/kg intramuscularly on three subsequent days. In addition, 1 mg/kg flunixin meglumine (Finadyne, Intervet) was injected intravenously once, post surgery. The cow was fed with total mixed ration, just like the other animals in the herd, with no dietary modifications. Water intake was ad libitum. The cow's general condition, appetite, water intake, defecation and urination were normal after the surgery. No complications were observed at the incision line. The skin sutures were removed ten days after the surgery. The animal was monitored until parturition after surgery.

Although the cow started showing signs of regular estrus cycles approximately one month after the surgery, insemination was not carried out until the third estrus. During the third estrus cycle following surgery, the cow was inseminated and was found to be pregnant by an ultrasonographic examination (5 MHz linear probe, Agroscaan L, France), 30 days after insemination. The cow completed the gestation period without any problems.

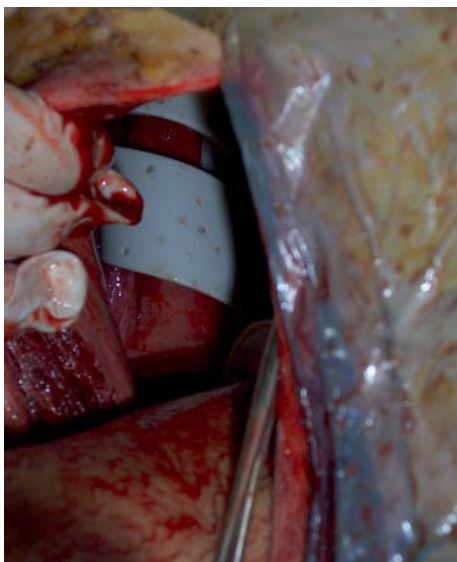

Fig. 1. View of the progesterone-releasing intravaginal device on the uterus during surgery

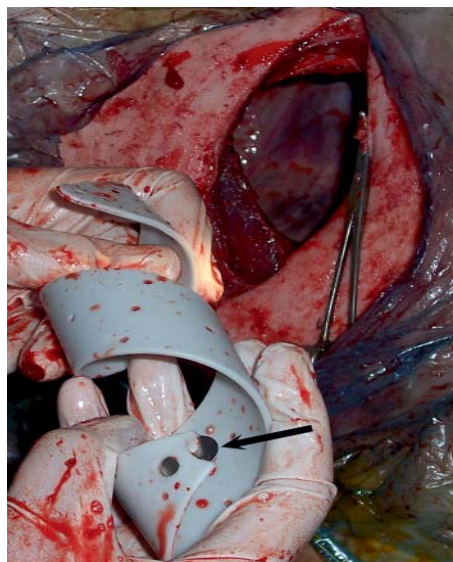


Fig. 2. View of the removed progesterone-releasing intravaginal device. The black arrow indicates the dissolving point.

### Discussion

The PRID is an intravaginal progesterone-releasing device frequently used in the cattle industry. The device is inserted into the vagina using a special applicator or speculum. The principle based on which this device is used is its ability to mimic the diestrus phase of the estrus cycle. Therefore, this device is used frequently in the synchronization of the estrus cycle (GARCIA-ISPIERTO et al., 2010), and less frequently in the treatment of ovarian cysts (KIM et al., 2004), inactive ovaries (KIM et al., 2004; ZULU et al., 2000) and the control of threatened abortion or early embryonic death (LOPEZ-GATIUS et al., 2004).

In this cow, no data was available on how the PRID had reached the uterus. We assumed there were two possibilities, both caused by application failure. The first possibility is that the applicator of the PRID may have perforated the vaginal fornix or another site in the vagina as the result of improper insertion. However, vaginoscopic examination revealed no scar tissue on the vaginal wall. Besides, during the surgery, thinning of the right dorsolateral wall of the uterine body was observed.

The second possibility is related to the relationship between the time when the cervix opens and the time of the PRID insertion. Usually, the normal cervical opening during the estrus stage does not allow the device to pass through into the uterine body. For the PRID

to be able to pass through the cervix it must be open much more than it normally is at the estrus stage. This is only possible when the animal is in the early postpartum period. Therefore, we concluded that the second possibility was the more probable explanation of how the PRID reached the uterus. Our assumption is supported by earlier researchers who reported that the diameter of the cervix was 30 cm immediately after parturition but reduced to 2 cm by the seventh postpartum day (WEHREND et al., 2003). In such a situation, the PRID in the uterine lumen could have perforated and come out through the uterine wall during involution of the genital tract.

The PRID has been reported safe for use in cattle (WALSH et al., 2008). The only known adverse effect in using the PRID is vaginitis, which improves spontaneously within a few days following removal of the device (HANDLER et al., 2006; WALSH et al., 2008). Also, it does not affect pregnancy rates (CHENAULT et al., 2003; PADULA and MACMILLAN, 2006; WALSH et al., 2007; FISCHER-TENHAGEN et al., 2012). The blood parameters, including hematocrit, white blood cells, serum glucose, blood urea nitrogen, aspartate aminotransferase and alanine aminotransferase are not affected in cows with an inserted PRID (WALSH et al., 2008). These reports suggest that the PRID does not affect the general health of the animal.

Normally, the PRID is inserted into the vagina and left for 7 to 14 days, depending on the intended use (CHENAULT et al., 2003; PADULA and MACMILLAN, 2006; FISCHER-TENHAGEN et al., 2012). In this case, no data was available regarding the purpose for which the device had been inserted and how long it had been left inside the animal. We believed that the device was left inside the cow for at least six months, because it had shown no signs of estrus throughout the entire six months since it had been bought from another farm. Besides, the state of dissolution of the device was evidence that it had been in the abdominal cavity for a long period of time.

Blood parameters were not evaluated in this case, although the general health status of the cow was good, in line with the available literature. The animal had been in anestrus or silent heat for at least six months; however, on rectal palpation as well as during surgery, performed two weeks after the first examination, no functional structure was observed on the ovaries. Therefore, we suggest that the animal was in true anestrus.

After removal of a PRID, most animals with anestrus or inactive ovaries showed signs of estrus within three days (KUROIWA et al., 2005; ÖZYURTLU et al., 2008). In this case, it took approximately one month after PRID removal for the animal to begin to show signs of estrus. Therefore, we suggest that anestrus, in this case, was due to the PRID coming into contact with the uterus. Our opinion is supported by an earlier study, which reported that intrauterine devices could lead to anestrus in cattle (TURIN et al., 1997). These devices are believed to cause mild endometritis by non-septic inflammation (NEWTON, 1989). This type of inflammation may become septic. However, the diagnosis of subclinical or mild endometritis is more difficult under field conditions and requires more

invasive techniques such as culture, cytology or biopsy of the endometrium (BARLUND et al., 2008). On the other hand, ultrasonography is a useful diagnostic method for the determination of endometritis in cows (ASLAN et al., 2002; KÄHN, 2004; KASIMANICKAM et al., 2004; KÜÇÜKASLAN, 2010). The hyperechoic and anechoic areas displayed in this case could be considered as due to endometritis. One well known, effective treatment for endometritis in cows is the intrauterine infusion of antibiotics. Therefore, we chose ceftiofur hydrochloride as the therapeutic agent and prophylactic antibacterial, because of its properties of dispersing well in the uterus, particularly if infected (WITTE et al., 2010), and not leaving a residue in milk (RISCO and HERNANDEZ, 2003).

To our knowledge, this is the first report of a PRID found on the uterus and this case is significant as it shows fertility loss caused by a series of simple mistakes. The lack of sufficient data on the animal, except for the preceding six months, enabled us to comment on this case. There are some suggestions which arise from this case, as follows. Firstly, veterinarians or farmers should be careful during the application of intravaginal devices. Secondly, when purchasing a cow, a routine reproductive examination should be carefully performed, in addition to a general examination. Also, all data for each cow, including treatments and synchronization methods, should be obtained from the owner. Further, before synchronization or a hormonal approach is attempted, the animal must be examined for reproductive ability. The specific data for each individual cow must be recorded carefully on the herd management system and should be checked at regular intervals. This will enable early detection of health problems in animals, and eliminate cases like this one.

Our goal, in this case, was to recover fertility in the cow. To achieve this, the device had to be removed and the only therapeutic option available was surgery. Colpotomy, which has been reported safe in cows (DROST et al., 1992), may be tried as an alternative to flank laparotomy; however, we preferred ipsilateral flank laparotomy because there was insufficient material available for colpotomy.

As a result of the surgery, the fertility of the cow has been recovered without complications. Therefore, we conclude that right flank laparotomy is a safe procedure for the removal of a PRID from the uterus, and particularly for the recovery of fertility, as in this case.

### References

- ALLOL, J. G., A. R. PETERS (2004): Pharmacological manipulation of reproduction. In: Bovine Medicine: Disease and Husbandry of Cattle 2<sup>nd</sup> ed. (Andrews, A. H., R. W. Blowey, H. Boyd, R. G. Eddy, Eds.), Blackwell, Oxford, pp. 678-688.
- ASLAN, S., J. HANDLER, G. WESENAUER, K. ARBEITER (2002): Eignung der sonographischen Beurteilung von Ovardynamik und Uterusinvolution zur Fertilitäts-prognose im Puerperium des Rindes. Dtsch. Tierärztl. Wschr. 109, 52-55.



- BARLUND, C. S., T. D. CARRUTHERS, C. L. WALDNER, C. W. PALMER (2008): A comparison of diagnostic techniques for postpartum endometritis in dairy cattle. *Theriogenology* 69, 714-723.
- BOOTHE, D. M., M. MAYA (2011): Parenteral dosage forms and delivery systems. In: Merck Veterinary Manual 9<sup>th</sup> ed, (Kahn, C. M. Ed.), Merck Sharp&Dohme Corp, Whitehouse Station, New Jersey.
- CHENAULT, J. R., J. F. BOUCHER, K. J. DAME, J. A. MEYER, S. L. WOOD-FOLLIS (2003): Intravaginal progesterone insert to synchronize return to estrus of previously inseminated dairy cows. *J. Dairy Sci.* 86, 2039-2049.
- DROST, M., J. D. SAVIO, C. M. BARROS, L. BADINGA, W. W. THATCHER (1992): Ovariectomy by colpotomy in cows. *J. Am. Vet. Med. Assoc.* 200, 337-339.
- FISCHER-TENHAGEN, C., X. VON KRUEGER, W. HEUWIESER (2012): Short communication: evaluation of vaginal discharge following treatment with a progesterone insert. *J. Dairy Sci.* 4447-4451.
- GARCIA-ISPIERTO, I., F. LÓPEZ-GATIUS, G. BECH-SÀBAT, J. L. YÁNIZ, E. ANGULO, C. MARIS, S. FLOCH, A. MARTINO (2010): Effects of a progesterone-based oestrous synchronization protocol in 51- to 57-day postpartum high-producing dairy cows. *Reprod. Domest. Anim.* 45, 168-173.
- HANDLER, J., S. SCHÖNLIEB, H-O. HOPPEN, C. AURICH (2006): Seasonal effects on attempts to synchronize estrus and ovulation by intravaginal application of progesterone-releasing device (PRID<sup>TM</sup>) in mares. *Theriogenology* 65, 1145-1158.
- KÄHN, W. (2004): Ultrasonography in the cow. In: *Veterinary Reproductive Ultrasonography* (Kahn, W. Ed.), Schluetersche Verlagsgesellschaft, Hannover, pp. 83-185.
- KASIMANICKAM, R., T. F. DUFFIELD, R. A. FOSTER, C. J. GARTLEY, K. E. LESLIE, J. S. WALTON, W. H. JOHNSON (2004): Endometrial cytology and ultrasonography for the detection of subclinical endometritis in postpartum dairy cows. *Theriogenology* 62, 9-23.
- KIM, S., K. KENGAKU, T. TANAKA, H. KAMOMAE (2004): The therapeutic effects of a progesterone releasing intravaginal device (PRID) with attached estradiol capsule on ovarian quiescence and cystic ovarian disease in postpartum dairy cows. *J. Reprod. Dev.* 50, 341-348.
- KÜÇÜKASLAN, I. (2010): Evaluation of endometrial echostructure following lotagen<sup>®</sup> administration in cows with chronic endometritis. PhD Thesis, Ankara University Graduate School of Health Sciences, Ankara, Turkey.
- KUROIWA, T., A. ISHIBASHI, M. FUKUDA, S. KIM, T. TANAKA, H. KAMOMAE (2005): Estrus synchronization and conception rate after a progesterone releasing intravaginal device (PRID) treatment from the early luteal phase in heifers. *J. Reprod. Dev.* 51, 669-673.
- LOPEZ-GATIUS, F., P. SANTOLARIA, J. L. YANIZ, R. H. F. HUNTER (2004): Progesterone supplementation during the early fetal period reduces pregnancy loss in high-yielding dairy cattle. *Theriogenology* 62, 1529-1535.
- MACMILLIAN, K. L., A. J. PETERSON (1993): A new intravaginal progesterone releasing device for cattle (CIDR-B) for oestrous synchronisation, increasing pregnancy rates and the treatment of post-partum anoestrus. *Anim. Reprod. Sci.* 33, 1-4

- NEWTON, J. (1989): Modern ICUDs, their safety and efficacy. *Curr. Therap.* 8, 117-133.
- NISWENDER, G. D, J. L. JUENGEL, P. J. SILVA, M. K. ROLLYSON, E. W. MCINTUSH (2000): Mechanisms controlling the function and life span of the corpus luteum. *Physiol. Rev.* 80, 1-29.
- ODDE, K. G (1990): A review of synchronization of estrus in postpartum cattle. *J. Anim. Sci.* 68, 817-830.
- ÖZYURLU, N., A. K. ZONTURLU, İ. KÜÇÜKASLAN (2008): İnaktif ve aktif ovaryumlu düvelerde PRID ve GnRH kombinasyonunun fertilité parametrelerine etkisi. *Ankara Üniv. Vet. Derg.* 55, 13-16.
- PADULA, A. M., K. L. MACMILLAN (2006): Effect of treatment with two intravaginal inserts on the uterine and vaginal microflora of early postpartum beef cows. *Aust. Vet. J.* 84, 204-208.
- RISCO, C. A., J. HERNANDEZ (2003): Comparison of ceftiofur hydrochloride and estradiol cypionate for metritis prevention and reproductive performance in dairy cows affected with retained fetal membranes. *Theriogenology* 60, 47-58.
- TURIN, E. M., C. A. NAGLE, M. LAHOZ, M. TORRES, M. TURIN, A. F. MENDIZABEL, M. B. ESCOFET (1997): Effects of a copper-bearing intrauterine device on the ovarian function, body weight gain and pregnancy rate of nulliparous heifers. *Theriogenology* 47, 1327-1336.
- WALSH, R. B., S. J. LEBLANC, E. VERNOOY, K. E. LESLIE (2008): Safety of a progesterone releasing intravaginal device as assessed from vaginal mucosal integrity and indicators of systemic inflammation in postpartum dairy cows. *Can. J. Vet. Res.* 72, 43-49.
- WALSH, R. B., S. J. LEBLANC, T. DUFFIELD, D. F. KELTON, J. S. WALTON, K. E. LESLIE (2007): The effect of a progesterone releasing intravaginal device (PRID) on pregnancy risk to fixed-time insemination following diagnosis of non-pregnancy in dairy cows. *Theriogenology* 67, 948-956.
- WEHREND, A., K. FAILING, H. BOSTEDT (2003): Cervimetry and ultrasonographic observations of the cervix regression in dairy cows during the first 10 days post partum. *J. Vet. Med.* 50, 470-473.
- WITTE, T. S., M. IWERSEN, T. KAUFMANN, P. SCHERPENISSE, A. A. BERGWERFF, W. HEUWIESER (2010): Determination of ceftiofur derivates in serum, endometrial tissue, and lochia in puerperal dairy cows after subcutaneous administration of ceftiofur crystalline free acid. *J. Dairy Sci.* 94, 284-290.
- ZULU, V. C., T. NAKAO, K. YAMADA, M. MORIYOSHI, K. NAKADA, Y. SAWAMUKAI (2000): Clinical response of inactive ovaries in dairy cattle after PRID treatment. *J. Reprod. Dev.* 46, 415-422.
- ZULU, V. C., T. NAKAO, K. YAMADA, M. MORIYOSHI, K. NAKADA, Y. SAWAMUKAI (2003). Clinical response of ovarian cysts in dairy cows after PRID treatment. *J. Vet. Med. Sci.* 65, 57-62.

Received: 22 January 2013

Accepted: 10 July 2013



---

**KAYA, D., S. S. AY, S. ASLAN: Učinak nepravilne primjene intravaginalnog umetka za otpuštanje progesterona na plodnost holštajnsko-frizijske krave: prikaz slučaja. Vet. arhiv 84, 189-197, 2014.**

**SAŽETAK**

U prikazu slučaja opisano je kirurško uklanjanje intravaginalnog umetka za otpuštanje progesterona (PRID<sup>®</sup>, 1,55 g progesterona). Umetak je bio pričvršćen za maternicu krave holštajnsko-frizijske pasmine u koje je obavljena kontrola plodnosti. U prethodnom šestomjesečnom razdoblju nije bilo podataka o kravi, a tijekom sljedećih šest mjeseci kontrole nije bilo znakova estrusa. Tijekom pregleda reproduksijskih organa, u desnom rogu maternice otkrivena je spiralna tvorevina, slična umetku. Nakon postavljene dijagnoze razmatrana je mogućnost kirurškog uklanjanja. Odabrana je laparotomija s pristupom na desnoj bočnoj strani. Približno mjesec dana nakon operacije kod krave su opaženi znakovi estrusa, no osjemenjivanje nije obavljeno prije trećeg ciklusa. Nakon osjemenjivanja, krava je postala bređa s normalnim trajanjem gravidnosti. Autori zaključuju da PRID može biti uzrokom izostanka estrusa kod krava. Laparoskopska operacija s desne bočne strane je sigurna metoda za uklanjanje PRID-a iz maternice, posebno s obzirom na uspostavljenu plodnost krave u ovom prikazu.

**Ključne riječi:** izostanak estrusa, krava, plodnost, nepravilno primijenjen progesteron

---

