

Renal nephroblastoma in an adult dog - a case report

Kurisinkal D. J. Martin¹, Sherin B. Sarangom^{1*}, Balakrishnan Nair D. Krishna², Narayanan D. Nair², Usha N. Pillai³, Susannah B. Philip¹, and Ashay P. Kankonkar¹

¹*Department of Veterinary Surgery and Radiology, College of Veterinary and Animal Sciences, Mannuthy, Thrissur, Kerala, India*

²*Department of Veterinary Pathology, College of Veterinary and Animal Sciences, Mannuthy, Thrissur, Kerala, India*

³*Department of Clinical Veterinary Medicine, College of Veterinary and Animal Sciences, Mannuthy, Thrissur, Kerala, India*

MARTIN, K. D. J., S. B. SARANGOM, B. D. KRISHNA, N. D. NAIR, U. N. PILLAI, S. B. PHILIP, A. P. KANKONKAR: Renal nephroblastoma in an adult dog. Vet. arhiv 84, 85-96, 2014.

ABSTRACT

A nine year old, intact female German shepherd dog was presented with the complaint of melena. The dog was anorectic, lethargic and cachectic. Physical examination and radiography revealed the presence of a large mid-dorsal intra-abdominal mass. Laboratory findings and diagnostic ultrasound marked the suspicious involvement of the right kidney. Renal neoplasm was suspected and an exploratory celiotomy was done. The mass was spread over the sublumbar region and was found to have originated from the right kidney. Excision of the tumor mass, along with unilateral nephrectomy, was done and the surgical recovery was uneventful. Histopathological examination led to the diagnosis of stage III renal nephroblastoma with unfavorable histology. The potential clinical and pathological manifestations of canine renal nephroblastoma in an adult dog have been documented.

Key words: renal nephroblastoma, Wilms' tumor, renal tumors

Introduction

Primary renal tumors are seldom diagnosed in dogs. Nephroblastoma, also known as embryonal nephroma, embryonal adenocarcinoma and Wilms' tumor, is a rare tumor of juvenile and adult dogs, but are more common in pigs and chicken (MOULTON, 1978;

*Corresponding author:

Sherin B. Sarangom, M.V.Sc. Scholar, Department of Veterinary Surgery and Radiology, College of Veterinary and Animal Sciences, Mannuthy, Thrissur - 680 651, Kerala, India, Phone: +91 9447310472, +91 900 8472 552; E-mail: sbs04vet@gmail.com

MAXIE and NEWMAN, 2007). Previously, they have been associated with hypertrophic osteopathy (KLEIN et al., 1988; SEAMAN and PATTON, 2003). In children, Wilms' tumor is the most common primary renal tumor and the fifth common pediatric malignancy (MINIATI et al., 2008). Among the dogs reported to have nephroblastoma, most were less than two years of age, although it is reported rarely in adult dogs (NAKAYAMA et al., 1984; CROW, 1985; KLEIN et al., 1988; SEAMAN and PATTON, 2003; BRYAN et al., 2006). The tumor usually remains unnoticed, until it becomes fatal or, at times, gets noticed accidentally. In dogs, the treatment protocols are adopted from the recommendations devised by the National Wilms' Tumor Study Group (NWTSG) for treatment in humans (D'ANGIO et al., 1989; KASTE et al., 2008). Treatment includes surgical resection of the tumor mass, complete or partial nephrectomy of the kidney involved, chemotherapy and radiotherapy, or a combination of the above, based on staging and histology. However, successful clinical outcomes have not been achieved in dogs. Also, the information regarding the clinical characteristics of canine renal nephroblastoma still remains limited. This report describes a case of stage III renal nephroblastoma with unfavorable histology in an adult dog, and its potential clinical and pathological manifestations.

Case description

A nine year old, intact female German shepherd dog weighing 25 kg was presented with the complaint of melena for the previous two days. On presentation, the dog was dull and depressed. The animal had been anorectic for the previous five days and was severely dehydrated, lethargic and dyspnoeic. The animal had showed a reduction in appetite and considerable weight loss (9%) over the previous one month. Vaccination and deworming history were irregular. The rectal temperature was normal (38.9 °C), but showed mild tachycardia (132 beats/min) and tachypnoea (54 breaths/min). The conjunctival mucous membrane was pink with rise in capillary refill time >2 sec. On fecal sample examination, no ova of any parasitic importance could be detected. The complete blood count (CBC) showed leukocytosis ($22.0 \times 10^3/\mu\text{L}$; reference range, $6.0\text{-}17.0 \times 10^3/\mu\text{L}$) with neutrophilia ($17.38 \times 10^3/\mu\text{L}$; reference range, $3.0\text{-}11.5 \times 10^3/\mu\text{L}$). The erythrogram revealed anemia ($4.4 \times 10^6/\mu\text{L}$; reference range, $5.5\text{-}8.5 \times 10^6/\mu\text{L}$) with a low hemoglobin level (9.4 g/dL; reference range, 12-18 g/dL), a decrease in the volume of packed red blood cells (29%; reference range, 37-55%) and an increase in erythrocyte sedimentation rate (100mm/hr; reference range, 0-6mm/hr). The platelet count was in the upper limit ($490 \times 10^3/\mu\text{L}$; reference range, $200\text{-}500 \times 10^3/\mu\text{L}$). Abnormalities in serum biochemistry profile included a mild rise in total bilirubin (0.8 mg/dL; reference range, 0.1-0.6 mg/dL) attributed to a rise in indirect bilirubin (0.6mg/dL; reference range, 0.1-0.3 mg/dL), a mild increase in alkaline phosphatase (90 IU/L; reference range, 12-72 IU/L) and hyperproteinemia (7.5 g/dL; reference range, 5.4-7.1 g/dL) attributed to hyperglobulinemia (4.9 g/dL; reference range, 2.7-4.4 g/dL). Urinalysis revealed proteinuria (1+) and microscopic haematuria

(5 to 10 red blood cells per high-power field). Alpha foeto-protein (AFP) in blood was estimated and found to be 0.89 ng/mL (reference range, <70 ng/mL). The reference data were obtained from KITAO et al. (2006), BRAUN and LEFEBVRE (2008), TENNANT and CENTER (2008) and RIZZI et al. (2010). On physical examination, a massive non-painful, firm, right sided, mid-dorsal intra-abdominal mass could be palpated. Radiography showed an irregular, soft tissue density, measuring 20 cm in diameter, that occupied the right side of the abdomen, displacing the intestinal loops. Chest radiographs were unremarkable. Diagnostic ultrasound revealed an extensive soft tissue mass of undetermined origin (Fig. 1). The mass was mixed in echogenicity, appeared partially cystic and occupied approximately 60% of the abdominal cavity filling the cranial abdomen, located between the right kidney and liver. The right kidney and adrenal gland were not visualized on diagnostic ultrasound. The gastro-intestinal tract was completely displaced by the mass. The liver, gall bladder, spleen, left kidney, urinary bladder, pancreas, ovaries, uterus, lymph nodes and gastro-intestinal tract appeared normal ultrasonographically. Renal neoplasia was suspected and an exploratory celiotomy was performed.

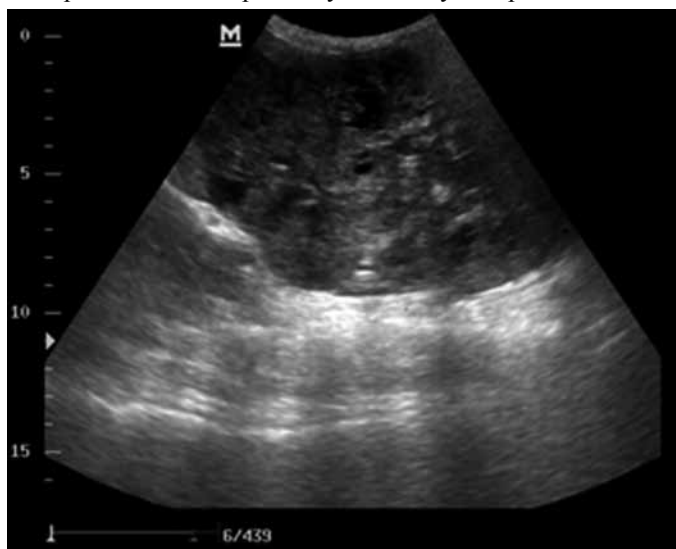


Fig. 1. Mixed echogenic soft tissue mass with cystic cavities in the diagnostic ultrasound

The animal was stabilized by intravenous (IV) administration of 0.9% normal saline (NS, Nirma limited, Gujarat, India) at the rate of 15 mL/kg body mass for the first two days, in addition to 3.5% gelatin polypeptides (Haemaccel, Nicholas Piramal India Ltd., Gujarat, India) at the rate of 5 mL/kg body mass, given on the second day pre-

operatively. Antibiotic therapy was started on the first day with ceftriaxone (Intacef, Intas pharmaceuticals, Ahmadabad, India) at the rate of 30 mg/kg body mass IV, twice daily along with pantoprazole (Pantocid, Sun pharmaceutical industries limited, Gujarat, India) at the rate of 1 mg/kg body mass, given once daily. Pre-operatively, tramadol (Tramazac, Cadila health care limited, Ahmadabad, India) was administered at the rate of 2 mg/kg body mass IV. A ventral midline celiotomy was performed under general anaesthesia using propofol (Neorof, Neon laboratories limited, Mumbai, India) at the rate of 5 mg/kg body mass IV for induction and 1.5% isoflurane (Forane, Aesica Queenborough Ltd., Kent, UK) in oxygen for maintenance. A 24 cm × 15 cm mass was identified that was found to have originated from the right kidney (Fig. 2). The mass was located on the retroperitoneal space in the sublumbar region. The right kidney and adrenal gland could not be positively identified as they were embedded in the mass. The cranial pole of the right kidney was noticed on the anterior aspect of the mass, without normal renal architecture. The mass was found to have involvement with the abdominal aorta and the caudal vena cava. The left kidney was found to be apparently normal. Involvement with any other abdominal organs was not noticed. The mass was separated by blunt dissection from its sublumbar attachments. The renal artery and the renal vein were double ligated separately, using chromic catgut No.1 (Chromic gut, Johnson and Johnson Ltd., Aurangabad, India), followed by the right ureter close to the bladder, which was ligated using polyglactin 910 No.0 (Vicryl, Johnson and Johnson Ltd., Aurangabad, India). A right nephrectomy was performed and the mass was removed. However, a portion of the mass surrounding the caudal vena cava and the abdominal aorta were left unresected. The *linea alba* was then apposed using polyglactin 910 No.0, followed by the subcutis. The skin was closed in a horizontal mattress pattern using polyamide No.2-0 (Trulon, Sutures India Pvt. Ltd., Bangalore, India).

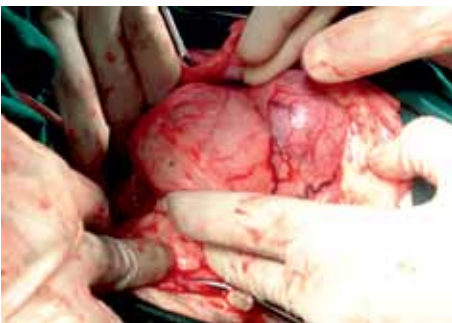

Fig. 2. Firm, pale, irregular, smooth surfaced and encapsulated mass viewed during celiotomy

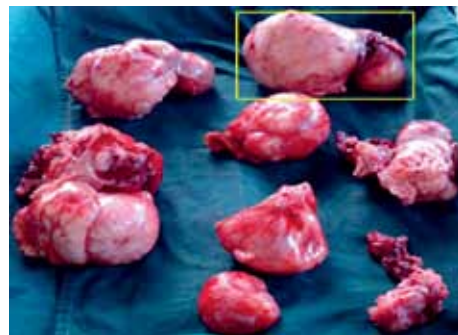


Fig. 3. The resected tumor mass after dissection. The inset shows the cranial pole of the right kidney embedded in the tumor mass

Post-operatively, meloxicam (Melonex, Intas pharmaceuticals, Ahmadabad, India) was administered at the rate of 0.2 mg/kg body mass intramuscularly. An emergency blood transfusion was administered immediately after surgery due to intra-operative bleeding. Whole blood was collected from a healthy donor, using a 350 mL blood bag containing 49 mL of citrate-phosphate-dextrose-adenine (CPDA-1) anticoagulant and 225 mL was transfused. Surgical recovery was uneventful. Post-operative antibiotic therapy (ceftriaxone) was continued for five more days, and analgesic (tramadol) was administered for two more days. CBC and serum biochemistry was repeated on the second post-operative day. Abnormalities in CBC included mild neutrophilia ($12.6 \times 10^3/\mu\text{L}$; reference range, $3.0\text{-}11.5 \times 10^3/\mu\text{L}$) and anemia ($2.6 \times 10^6/\mu\text{L}$; reference range, $5.5\text{-}8.5 \times 10^6/\mu\text{L}$) with a low hemoglobin level (8g/dL; reference range, 12-18 g/dL), decrease in volume of packed red blood cells (24%; reference range, 37-55%), increase in mean corpuscular volume (92 fL; reference range, 60-77fL), decrease in mean corpuscular hemoglobin (30 pg; reference range, 19-25 pg) and increased erythrocyte sedimentation rate (30 mm/hr; reference range, 0-6 mm/hr). Serum biochemical profile showed an elevated blood urea nitrogen (86.3 mg/dL; reference range, 10-25 mg/dL) and creatinine level (10.1 mg/dL; reference range, 1.0-2.2 mg/dL).

On gross evaluation, the excised mass was found to be firm, pale, irregular, smooth surfaced and encapsulated (Fig. 3). About 80% of the right kidney remained embedded in the mass. The mass measured about 24 cm \times 15 cm \times 10 cm and weighed 1.2 kg, including the right kidney. The cranial pole of the kidney contained a round, pale mass four centimeters in diameter, within the cortex and medulla (Fig. 4). On cut section, the mass appeared multilobulated with cystic cavities (Fig. 5) and the tumor was infiltrative in nature. Representative samples for histopathological evaluation were fixed in 10% neutral buffered formalin, paraffin-embedded and sections were cut and stained with haematoxylin and eosin (H&E).

On histopathological examination, the tumor consisted of both epithelial and mesenchymal components (Fig. 6). The epithelial components pre-dominated over the mesenchymal components. The tumor replaced a large part of the renal parenchyma and the mass was of the encapsulated, multilobulated and infiltrative type. The arrangement was both papillary and nest pattern. The epithelial cells resembled blastemal cells. Within the papillary pattern, there was a thin stroma of connective tissue components (Fig. 7). The blastemal cells were uniform, with centrally placed vesicular nuclei and sparse cytoplasm. The nucleoli were prominent and centrally located. The mitotic index was one per 10X high power field. There were multifocal areas of necrosis and hemorrhage.

The histological diagnosis was nephroblastoma. Based on the staging system for nephroblastoma (Wilms' tumor) in humans, developed by the NWTSG, the tumor was designated as stage III with unfavorable histology. A chemotherapeutic plan was devised,

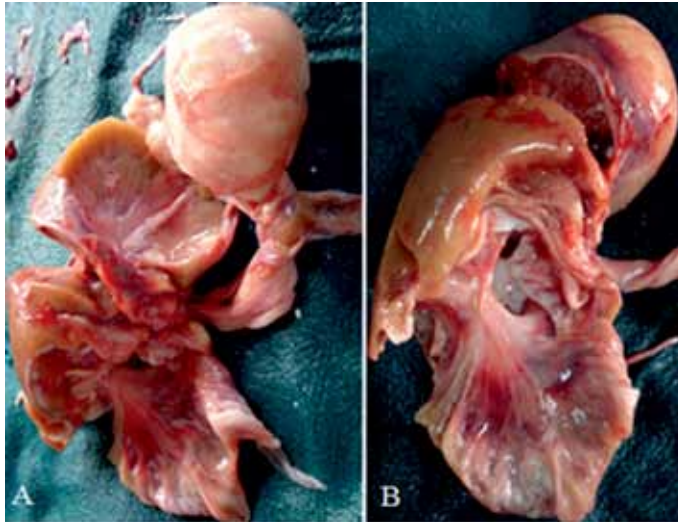


Fig. 4. A. The infiltrated tumor mass that involved both the cortex and medulla; B. The cortex and medulla after the removal of the infiltrated tumor mass.



Fig. 5. The cross section of the different lobes of the tumor mass showing cystic cavities

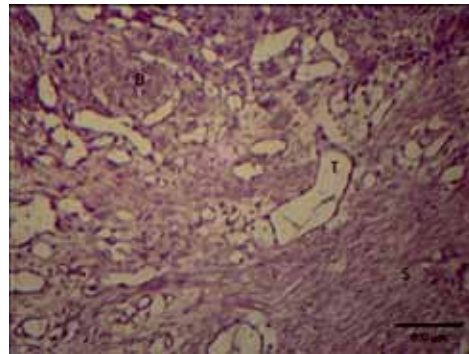


Fig. 6. Histopathology of the tumor mass. Photomicrograph showing tubular components (T), nest pattern of blastemal cells (B) and mesenchymal components (S) of the tumor mass, H&E; $\times 10$.

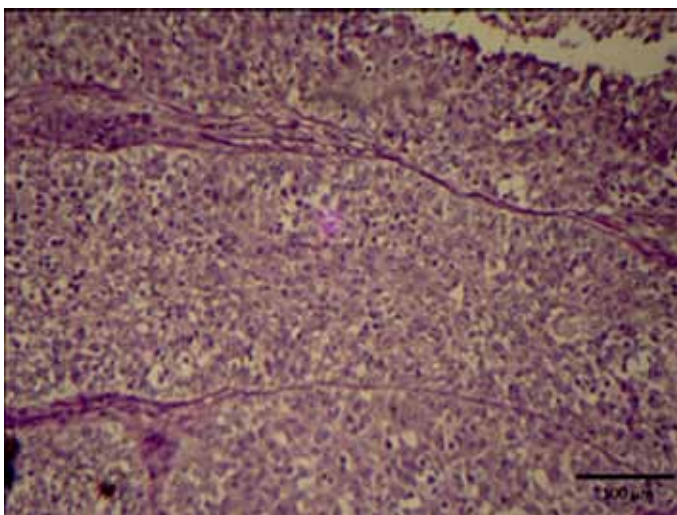


Fig. 7. Histopathology of the tumor mass. Photomicrograph showing uniformly arranged blastemal cells separated by thin stroma of connective tissue. Stained with haematoxylin and eosin; $\times 10$.

which consisted of a combination of vincristine sulphate (0.75 mg/m² of body surface area, IV, once a week for 12 weeks, followed by once in 3 weeks), actinomycin-D (1 mg/m², IV, once in 6 weeks) and doxorubicin (30 mg/m², IV, once in 6 weeks starting 3 weeks after initial administration of actinomycin-D) for a period of 24 weeks, based on the recommendations developed from the results of the NWTSG for treatment in humans. It was to start on the following week after patient stabilization. But the dog died on the 11th day after initial presentation as reported by the owner. Postmortem examination could not be performed because of the sentimental concerns of the owner.

Discussion

A nephroblastoma is a congenital neoplasm of the kidney and is associated with confirmed growth, but abnormal differentiation. The origin of this tumor is thought to be either a pluripotent primitive metanephrogenic blastema, which differentiates into the epithelial, stromal and connective tissue elements of the kidney, or from the persistent nephrogenic rest (MEUTEN, 2002). The neoplasms found commonly in the kidneys are metastatic, possibly because of the large blood volume this organ receives and the abundant supply of capillaries. Nephroblastomas may be benign, but are usually malignant. In dogs, nephroblastomas have been reported involving either a kidney or the spinal cord or both (NAKAYAMA et al., 1984; GASSER et al., 2003; BRYAN et al., 2006;

BREWER et al., 2011). However, both the renal and spinal variants of nephroblastoma appear similar histopathologically (GASSER et al., 2003). Renal nephroblastomas are usually unilateral, but bilateral involvement has been reported. There is no sex or breed predilection, although young intact dogs are commonly affected (KLEIN et al., 1988; FRIMBERGER et al., 1995).

The clinical signs in dogs with renal nephroblastoma may not be specific as in the case of other renal neoplasms. The most frequently reported signs include: abdominal distention with an associated palpable mass, lethargy, anorexia, emaciation, weight loss, vomiting and microscopic haematuria (KLEIN et al., 1988; SEAMAN and PATTON, 2003). The clinico-pathological findings are usually unremarkable. Abdominal radiographs and diagnostic ultrasound might help to localize the mass. A tumor, which penetrates the renal capsule, may locally invade onto the perinephric fat, posterior abdominal muscles, caudal vena cava, diaphragm and neighboring organs. Distal metastasis occurs via the lymphatics or by venous metastasis, mostly to the lungs and also the adrenals, liver, opposite kidney, ovaries, thymus, mesentery, lymph nodes, thyroid, spinal cord and bone (NAKAYAMA et al., 1984; KLEIN et al., 1988; GASSER et al., 2003; SEAMAN and PATTON, 2003; ŠOŠTARIĆ-ZUCKERMANN et al., 2013). The treatment plans were adopted from the therapeutic protocols devised for human patients recommended by the NWTSG based on the staging of tumor. The staging is done on the basis of gross and microscopic tumor distribution, as shown in Table 1 (D'ANGIO et al., 1989; KASTE et al., 2008). More pediatric patients are now cured successfully with better standardized treatment protocols devised by this group.

Table 1. Staging system for nephroblastoma (Wilms' tumor) in humans, developed by the National Wilms' Tumor Study Group

Stage I	Tumor limited to kidney and completely excised. Renal capsule is intact, tumor excised without rupture of capsule and no evidence of apparent residual tumor.
Stage II	Tumor extends beyond kidney, but completely removed. Regional extension of tumor, vascular infiltration by the tumor or tumor thrombi evident, local spillage of tumor contents during biopsy and no evidence of apparent residual tumor.
Stage III	Residual nonhematogenous tumor confined to abdomen. Evidence of tumor extension into the hilar or periaortic lymph nodes, diffuse spillage of tumor into the peritoneal cavity during excision and evidence of microscopic or gross extension of tumor beyond surgical margins. Incomplete resection of tumor due to local infiltration of vital structures.
Stage IV	Evidence of hematogenous metastases.
Stage V	Bilateral renal involvement at diagnosis.
Histopathological classification	Favorable histology (No evidence of anaplasia)
	Unfavorable histology (Focal or diffuse anaplasia or a sarcomatous component)

In this case report, the clinical and pathological manifestations of a renal nephroblastoma in a 9 year old female German shepherd dog are documented. The initial presenting signs were non-specific and did not show any involvement of the urinary system. The results of CBC, serum biochemistry and urinalysis were unremarkable. Similar laboratory findings associated with renal neoplasia were reported by BRYAN et al. (2006), and in particular with nephroblastoma by KLEIN et al. (1988), GASSER et al. (2003) and SEAMAN and PATTON (2003). However, the findings were non tumor specific. Radiograph and physical examination revealed an abdominal mass that had to be differential diagnosed from metastatic neoplasia, tumors originating from the liver or spleen, pyometra, endometritis, endometrial hyperplasia and an ovarian cyst. The normal AFP in the blood helped to eliminate the possibility of hepatic involvement. A huge rise in AFP has been noticed in hepatic tumors, especially hepatocellular carcinoma (KITAO et al., 2006). Ultrasound imaging helped to rule out the involvement of other abdominal organs, except the right kidney and adrenal, as they were entirely masked by the abdominal mass. Renal involvement was suspected when the presence of proteinuria and hematuria in urinalysis and the inability to visualize the right kidney on the diagnostic ultrasound were correlated. Needle biopsy of the mass was not attempted, to avoid the seeding of the metastatic tumor cells into the abdominal cavity if it was malignant. Hence, we resorted to exploratory celiotomy. Celiotomy revealed the involvement of the right kidney, which was encapsulated by the mass. The left kidney was found to be apparently normal and hence unilateral nephrectomy was performed. CBC, repeated on the second post-operative day, revealed macrocytic anaemia that might have been due to increased activity of the bone marrow to replace the blood lost in surgery. Also, the serum biochemistry showed increased BUN and creatinine values. The tumor was classified as Stage III with unfavorable histology (i.e., anaplastic or sarcomatous) based on the histopathological examination, as done for Wilms' tumor in human patients. The chemotherapeutic plan that was devised, adopted from the therapeutic protocols recommended by the NWTSG, was not started. A similar plan was proposed by FRIMBERGER et al. (1995) for the treatment of Stage III tumor. Although pre-operative chemotherapy and radiotherapy reduce the size of the tumor and decrease the risk of intra-operative tumor rupture, by formation of a fibrous capsule, as reported in the studies conducted by the International Society for Pediatric Oncology (SIOP) in Europe, the survival rates for people have been found to be similar to those who receive only post-operative treatment (LEMERLE et al., 1983; TOURNADE et al., 2001). However, the radiographic diagnostic basis followed by the SIOP might lead to diagnostic error. Also, for histological diagnosis, a per-cutaneous needle biopsy is needed, that might cause seeding of metastatic tumor cells. However, the primary line of treatment is surgical resection of the tumor mass and nephrectomy, as in the present case.

There are fewer reported cases of nephroblastoma compared to other renal neoplasms. Among the reported cases of nephroblastoma described in literatures, subsequent metastasis was noticed to have developed within a few weeks or months, even after the treatment, and most patients underwent humane euthanasia (COLEMAN et al., 1970; FRIMBERGER et al., 1995; GASSER et al., 2003; SEAMAN and PATTON, 2003). The present study has several limitations, such as the absence of an immunohistochemical diagnosis and also a necropsy, that might have provided better information on the pathophysiology of the disease. To the best of our knowledge, this was the first case of renal nephroblastoma reported of a stage III tumor with unfavorable histopathology in an adult dog.

Nephroblastoma remains a rarely diagnosed primary renal neoplasia in dogs. The clinical signs and clinico-pathologic findings are unremarkable. Hence, careful evaluation of patients with clinical signs referable to the renal system and immediate treatment should be devised to manage this neoplasm. However, knowledge on the natural behavior and clinical characteristics of this tumor is limited because of its rarity. A case of renal nephroblastoma in an adult German shepherd bitch, its potential clinical and pathological manifestations and surgical intervention is hence documented.

Acknowledgements

The authors are thankful to the Dean, College of Veterinary and Animal Sciences, Mannuthy, Thrissur, The Professor and Head, Veterinary and Animal Sciences University Hospital, Mannuthy, Thrissur and The Professor and Head, Veterinary and Animal Sciences University Hospital, Kakkalai, Thrissur for providing the necessary facilities for the study.

References

- BRAUN, J., H. P. LEFEBVRE (2008): Kidney function and damage. In: Clinical biochemistry of domestic animals. (Kaneko, J. J., J. W. Harvey, M. L. Bruss, Eds.). Elsevier, California. pp. 485-528.
- BREWER, D. M., S. CERDA-GONZALEZ, C. W. DEWEY, A. N. DIEP, K. V. HORNE, S. P. McDONOUGH (2011): Spinal cord nephroblastoma in dogs: 11 cases (1985-2007). *J. Am. Vet. Med. Assoc.* 238, 618-624.
- BRYAN, J. N., C. J. HENRY, S. E. TURNQUIST, J. W. TYLER, J. M. LIPTAK, S. A. RIZZO, G. SFILIGOI, S. J. STEINBERG, A. N. SMITH, T. JACKSON (2006): Primary renal neoplasia of dogs. *J. Vet. Intern. Med.* 20, 1155-1160.
- COLEMAN, G., E. GRALLA, A. KNIRSCH, R. B. STEBBINS (1970): Canine embryonal nephroma: a case report. *Am. J. Vet. Res.* 31, 115-1320.
- CROW, S. (1985): Urinary tract neoplasms in dogs and cats. *Comp. Cont. Educ. Pract. Vet.* 7, 607-618.
- D'ANGIO, G. J., N. BRESLOW, J. B. BECKWITH, A. EVANS, E. BAUM, A. DELORIMIER, D. FERNBACH, E. HRABOVSKY, B. JONES, P. KELALIS, H. B. OTHERSEN, M. TEFFT,

- P. R. M. THOMAS (1989): Treatment of Wilms' tumor: Results of the third national Wilms' tumor study. *Cancer* 64, 349-360.
- FRIMBERGER, A. E., A. S. MOORE, S. H. SCHELLING (1995): Treatment of nephroblastoma in a juvenile dog. *J. Am. Vet. Med. Assoc.* 207, 596-598.
- GASSER, A. M., W. W. BUSH, S. SMITH, R. WALTON (2003): Extradural spinal, bone marrow, and renal nephroblastoma. *J. Am. Anim. Hosp. Assoc.* 39, 80-85.
- KASTE, S. C., J. S. DOME, P. S. BABYN, N. M. GRAF, P. GRUNDY, J. GODZINSKI, G. A. LEVITT, H. JENKINSON (2008): Wilms' tumour: prognostic factors, staging, therapy and late effects. *Pediatr. Radiol.* 38, 2-17.
- KITAO, S., T. YAMADA, T. ISHIKAWA, H. MADARAME, M., FURUICHI, S. NEO, R. TSUCHIYA, K. KOBAYASHI (2006): Alpha-fetoprotein in serum and tumor tissues in dogs with hepatocellular carcinoma. *J. Vet. Diagnostic Invest.* 18, 291-295.
- KLEIN, M. K., G. L. COCKRELL, C. K. HARRIS, S. J. WITHROW, J. P. LULICH, G. K. OGILVIE, A. M. NORRIS, H. J. HARVEY, R. C. RICHARDSON, J. D. FOWLER, J. TOMLINSON, R. A. HENDERSON (1988): Canine primary renal neoplasms: a retrospective review of 54 cases. *J. Am. Anim. Hosp. Assoc.* 24, 443-452.
- LEMERLE, J., P. A. VOUTE, M. F. TOURNADE, C. RODARY, J. F. DELEMARRE, D. SARRAZIN, J. M. BURGERS, B. SANDSTEDT, H. MILDENBERGER, M. CARLI (1983): Effectiveness of preoperative chemotherapy in Wilms' tumor: results of an international society of pediatric oncology (SIOP) clinical trial. *J. Clin. Oncol.* 1, 604-609.
- MAXIE, M. G., S. J. NEWMAN (2007): Urinary system. In: Jubb, Kennedy and Palmer's pathology of domestic animals. (Maxie, M. G., Ed.). Elsevier Health Services, Philadelphia. pp. 425-522.
- MEUTEN, D. J. (2002): Tumors of the urinary system. In: Tumors of domestic animals. (Meuten, D. J., Ed.). Iowa Blackwell publishing, Ames. pp. 509-546.
- MINIATI, D., A. N. GAY, K. V. PARKS, B. J. NAIK-MATHURIA, J. HICKS, J. G. NUCHTERN, D. L. CASS, O. O. OLUTOYE (2008): Imaging accuracy and incidence of Wilms and non-Wilms renal tumors in children. *J. Pediatr. Surg.* 43, 1301-1307.
- MOULTON, J. E. (1978): Tumors of the urinary system. In: Tumors in domestic animals. (Moulton, J. E., Ed.). University of California Press, Berkeley and Los Angeles. pp. 288-308.
- NAKAYAMA, H., T. HAYASHI, R. TAKAHASHI, K. FUJIWARA (1984): Nephroblastoma with liver and lung metastases in an adult dog. *Jpn. J. Vet. Sci.* 46, 897-900.
- RIZZI, T. E., J. H. MEINKOTH, K. D. CLINKENBEARD (2010): Normal hematology of the dog. In: Schalm's Veterinary Hematology. (Weiss, D. J., K. J. Wardrop, Eds.). Wiley-Blackwell, Ames, Iowa. pp. 799-810.
- SEAMAN, R. L., C. S. PATTON (2003): Treatment of renal nephroblastoma in an adult dog. *J. Am. Anim. Hosp. Assoc.* 39, 76-79.
- ŠOŠTARIĆ-ZUCKERMANN, I.-C., K. SEVERIN, M. HOHŠTETER, B. ARTUKOVIĆ, A. BECK, A. GUDAN KURILJ, R. SABOČANEC, P. DŽAJA, Ž. GRABAREVIĆ (2013): Incidence and types of canine tumours in Croatia. *Vet. arhiv* 83, 31-45.

TENNANT, B. C., S. A. CENTER (2008): Hepatic function. In: Clinical biochemistry of domestic animals. (Kaneko, J. J., J. W. Harvey, M. L. Bruss, Eds.). Elsevier, California. pp. 379-412.

TOURNADE, M. F., C. COM-NOUGUÉ, J. DE KRAKER, R. LUDWIG, A. REY, J.M.B. BURGERS, B. SANDSTEDT, J. GODZINSKI, M. CARLI, R. POTTER, J.M. ZUCKER (2001): Optimal duration of preoperative therapy in unilateral and nonmetastatic Wilms' tumor in children older than 6 months: results of the ninth international society of pediatric oncology Wilms' tumor trial and study. J. Clin. Oncol. 19, 488-500.

Received: 23 December 2012

Accepted: 17 April 2013

MARTIN, K. D. J., S. B. SARANGOM, B. D. KRISHNA, N. D. NAIR, U. N. PILLAI, S. B. PHILIP, A. P. KANKONKAR: Nefroblastom u kuje - prikaz slučaja. Vet. arhiv 84, 85-96, 2014.

SAŽETAK

Opisan je nefroblastom devetogodišnje njemačke ovčarke s melenom. Kuja je bila anoreksična, letargična i kahektična. Fizikalnom pretragom i radiografijom u kuje je ustanovljena velika masa u srednjem dorzalnom dijelu trbuha. Laboratorijskom i ultrazvučnom pretragom ustanovljene su promjene na desnom bubregu. Postavljena je sumnja na pojavu novotvorine na bubregu te je učinjena dijagnostička celiotomija. Masa se proširila na podslabinsko područje, a potjecala je od desnog bubrega. Tumorska masa bila je uklonjena kirurški s unilateralmom nefrektomijom. Patohistološkom pretragom postavljena je dijagnoza nefroblastoma III. stupnja s nepovoljnim histološkim nalazom. U radu je opisano kliničko i patološko očitovanje nefroblastoma u odrasle kuje.

Ključne riječi: nefroblastom, Wilmsov tumor, bubrežni tumori
