

Anatomic variations of the neck muscles in dogs

Ivan Alić^{1*}, Tajana Trbojević Vukičević¹, Martina Đuras¹, Snježana Kužir¹,
Dražen Vnuk², Srebrenka Nejedli¹, Lazo Pendovski³,
and Vesna Gjurčević Kantura¹

¹Department of Anatomy, Histology and Embryology, Faculty of Veterinary Medicine, University of Zagreb, Zagreb, Croatia

²Clinic of Surgery, Orthopaedics and Ophthalmology, Faculty of Veterinary Medicine, University of Zagreb, Zagreb, Croatia

³Department of Functional Morphology, Faculty of Veterinary Medicine, University of Ss. "Cyril and Methodius", Skopje, Republic of Macedonia

ALIĆ, I., T. TRBOJEVIĆ VUKIČEVIĆ, M. ĐURAS, S. KUŽIR, D. VNUK, S. NEJEDLI, L. PENDOVSKI, V. GJURČEVIĆ KANTURA: Anatomic variations of the neck muscles in dogs. Vet. arhiv 84, 53-62, 2014.

ABSTRACT

Muscle variations are common in humans, as well as in both wild and domestic animals. They are defined as additional muscle bundles or bellies, unusual insertions or even complete absence of the muscle. In this manuscript, we have described different variations of neck muscles in dogs. Fifty-seven medium sized dogs of different breeds, sex and ages were dissected between 2005 and 2011, within gross anatomy course. These variations were observed in four (7.02%) dogs and have included the sternohyoideus, stylohyoideus, sternocephalicus and scalenus dorsalis muscle. One dog presented three muscle variations (left sternohyoideus muscle, left and right stylohyoideus muscle), another two dogs showed two muscle variations (left and right sternocephalicus muscle) and one dog had one muscle variation (left scalenus dorsalis muscle). Muscle variations were observed bilaterally three times and once involved the stylohyoideus muscle and in the other two cases, the sternocephalicus muscle. The close phylogenetic relationship explains the observed muscle variations. Our description of neck muscle variations in dogs is a contribution to phylogenetic research and, in the terms of veterinary medicine, their presence has to be taken in account during surgical procedures of the neck region.

Key words: dog, anatomic variations, m. sternohyoideus, m. stylohyoideus, m. sternocephalicus, m. scalenus dorsalis

*Corresponding author:

Ivan Alić, DVM, Research fellow-assistant, Department of Anatomy, Histology and Embryology, Faculty of Veterinary Medicine, University of Zagreb, Heinzelova 55, 10 000 Zagreb, Croatia, Phone: +385 1 2390 259; Fax: +385 1 2441 390; E-mail: ialic@vef.hr

ISSN 0372-5480
Printed in Croatia

Introduction

Muscle variations are common in humans (COSKUN et al., 2002; SOOKUR et al., 2008; THAKUR et al., 2011), as well as in both wild and domestic animals (EVANS, 1959; GINER et al., 2009; TERRADO et al., 2005; TERRADO and ORTEGA, 2002). The variations are defined as additional muscle bundles or bellies, unusual insertions, as well as complete absence of the muscle. In most cases, these muscle variations were asymptomatic, but may produce clinical symptoms. They influence invasive and non-invasive therapeutic procedures and, in rare cases, can represent a critical element for the health of the specimen. Beside their clinical importance, muscle variations are also studied to explain phylogenetic relationships.

Most publications published so far have analyzed muscle variations in humans, although they have also been described when noted in domestic animals. EVANS (1959) published the most comprehensive description of muscle variations in dogs. Variations of the pectoral girdle muscles were recorded in cross-breed dogs in a relatively high percentage by ALIĆ et al. (2014). Muscle variations were frequently presented as case reports and were found during anatomical dissections. Only a few publications have dealt with neck muscle variations in dogs and have described variations in the sternohyoideus muscle, stylohyoideus muscle, mylohyoideus muscle (EVANS, 1959), tyrohyoideus muscle (TERRADO and ORTEGA, 2002), splenius muscle (TERRADO et al., 2005) and sternothyroideus muscle (GINER et al., 2009).

Neck muscles (musculi colli) are primarily located in the neck region, dorsally and laterally from the cervical spine, with a significant role in head and neck movements. This group also includes some of the muscles associated with hyoid apparatus, which have a functionally close relationship to tongue and pharyngeal muscles. Muscles in the ventral part of the neck have considerable clinical importance, because of the numerous visceral, vascular and nervous structures that transverse it en route between the head and thorax (ANONYM., 2012; DYCE et al., 2010; EVANS and de LAHUNTA, 2010; KÖNIG and LIEBICH, 2007; MILLER et al., 1964; NICKEL et al., 1987; SCHALLER, 2007).

The clinical importance of involved muscles was described by PIERMATTEI and JOHNSON (2004) and SLATTER (2003). The sternocephalicus muscle is important during a ventral approach to the cervical vertebrae and intervertebral disks 2-7. Indications for this approach are fenestrations and curettage of intervertebral disks C2-C7, decompression of the cervical spinal cord by ventral slot of intervertebral disks C2-C7, distraction and fusion of intervertebral disks C5-C6 and C6-C7 for caudal cervical spondylomyelopathy and open reduction and ventral stabilization of fractures and luxations of C2-C7. The sternohyoideus muscle is important during a ventral approach to cervical vertebrae 1 and 2 for treatment of fractures of the ventral aspect of C1 and C2 and atlantoaxial instability. The sternothyroideus muscle is also important during a ventral midline cervical approach

to soft tissue cervical structures (thyroid gland, trachea, esophagus, larynx etc.). The stylohyoideus muscle is very close to the larynx and cervical salivary glands, and the anatomy of this muscle is important during an approach to those structures. The scalenus dorsalis muscle may be damaged during a bite wound to the dorsolateral cervical area and its reconstruction may be needed.

Our study describes variations of four neck muscles in dogs, and also studies their phylogenetic relationships and clinical importance.

Materials and methods

A total of 57 medium-sized dogs of different breeds, sex and ages were dissected between 2005 and 2011 within a gross anatomy course at the Department of Anatomy, Histology and Embryology, Faculty of Veterinary Medicine, University of Zagreb, Croatia. The animals were handled in accordance with the Croatian Animal Protection Act (2006), and the study protocol was approved by the Ethics Committee of the Faculty of Veterinary Medicine. Their owners donated dogs after they were euthanized with T-61 (Intervet International B.V., Boxmeer, The Netherlands) in different clinics, with no signs of neck muscle dysfunction in their anamnesis. After being delivered to the Department, they were routinely prepared for anatomical dissection through vascular perfusion of 4% formalin fixative solution. Skin and both superficial and deep fascia were removed. The structure and anatomical relationships of the neck muscles were studied by dissection. Macroscopic findings of muscle variations were recorded, described and photographed.

Results

Variations of neck muscles were found in four dogs. All dogs were adults of medium size (Table 1). Dog No. 1 presented three muscle variations, dogs No. 2 and No. 3 had two muscle variations and dog No. 4 one muscle variation.

Table 1. The breed, muscle involved and sex of the dissected dogs with muscle variations.

Dog No.	Breed	Muscle	Sex
1	Doberman	sternohyoideus and stylohyoideus	male
2	cross-breed	sternocephalicus	male
3	Hungarian Vizsla	sternocephalicus	female
4	German Shepherd Dog	scalenus dorsalis	male

In dog No. 1, we observed three muscle variations: one of the left sternohyoideus muscle and bilaterally of the stylohyoideus muscle. The left sternohyoideus muscle originated, as usual, from the manubrium sterni and the first rib cartilage. In the middle of the neck, a narrow muscle bundle separated out from the dorsal border of the muscle

(Fig. 1A). This muscle bundle was directed dorsolaterally, along the lateral surface of the sternothyroideus and thyrohyoideus muscles and covered by sternocephalicus muscle. Cranially, that muscle bundle spread in a fan shaped termination and connected to the central part of the left stylohyoideus muscle. The main belly of the left sternohyoideus terminated at the basihyoid, as it should.

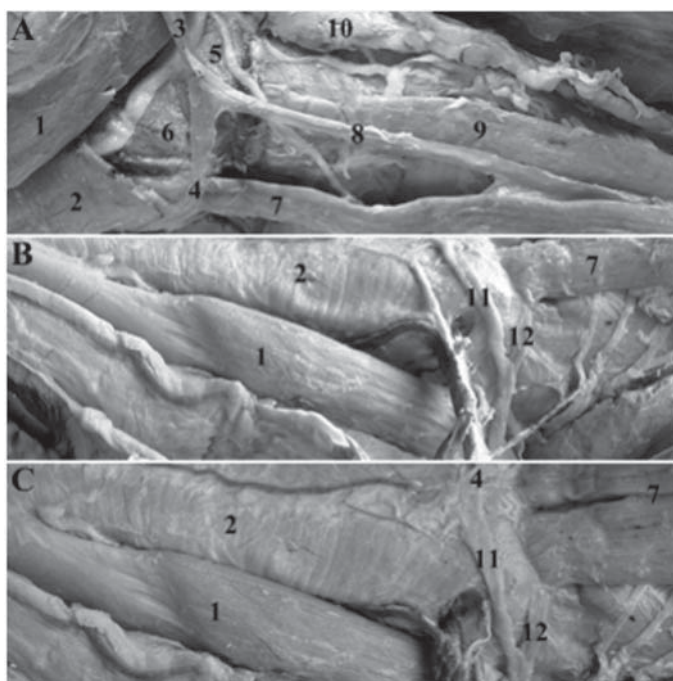


Fig. 1. Left view (A), right view (B) and ventral view (C) of the dog No. 1 neck: 1. digastricus muscle (m. digastricus), 2. mylohyoideus muscle (m. mylohyoideus), 3. stylohyoideus muscle (m. stylohyoideus), 4. small tendon termination of stylohyoideus muscle on the median fibrous raphe of the mylohyoideus muscle, 5. hyopharyngeus muscle (m. hyopharyngeus), 6. hyoglossus muscle (m. hyoglossus), 7. sternohyoideus muscle (m. sternohyoideus), 8. additional muscle bundle of sternohyoideus muscle, 9. sternothyroideus muscle (m. sternothyroideus), 10. medial retropharyngeal lymph node (lymphonodi retropharyngei mediales), 11. rostral bundle of the right stylohyoideus muscle, 12. caudal bundle of the right stylohyoideus muscle.

The left stylohyoid muscle of dog No. 1 originated dorsally from the tympanohyoid and the proximal end of the stylohyoid. Its central part associated with the previously described, narrow bundle of left sternohyoideus muscle. Further, it obliquely crossed the lateral surface of the digastricus muscle, ran superficially to the hyopharyngeus muscle

and terminated, with its largest part at the lateral end of the basihyoid. From here, a small tendon separated and ran rostroventrally, spread along the hyoglossus muscle and terminated at the caudal end of the median fibrous raphe of the mylohyoideus muscle (Fig. 1A, C).

The right stylohyoideus muscle of the same dog showed the usual origin and dorsal course. At the ventral third, it split into two gentle muscle bundles (Fig. 1B, C). The short caudal bundle ran ventrally, lying superficially on the hyopharyngeus muscle, and terminated at the lateral end of the basihyoid. The longer, rostral bundle ran ventrorostrally, crossed the hyoglossus muscle and terminated, like the opposite addition bundle of the left stylohyoideus muscle, at the caudal end of the median fibrous raphe of the mylohyoideus muscle.

In dog No. 2, we observed an additional muscle bundle in the left and right sternocephalicus muscles (Fig. 2). The additional bundle originated ventrally to the main belly of the left sternocephalicus muscle, as a wide, fan shaped tendinous aponeurosis at the manubrium sterni. Thereafter, it passed obliquely across the midline, to the right side of the neck and became fleshy and narrower. At the neck mid-level it fused with the ventral border of the right sternocephalicus muscle and together they terminated on the mastoid process of the temporal bone.

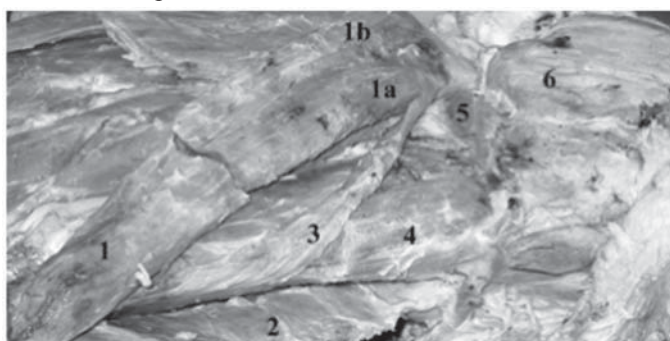


Fig. 2. Right and ventral view of the dog No. 2 neck: 1. right sternocephalicus muscle (m. sternocephalicus dexter), 1a. mastoid part of sternocephalicus (pars mastoidea m. sternocephalicus), 1b. occipital part of sternocephalicus (pars occipitalis m. sternocephalicus), 2. left sternocephalicus muscle (m. sternocephalicus sinister), 3. additional bundle of sternocephalicus muscle, 4. sternohyoideus muscle (m. sternohyoideus), 5. digastricus muscle (m. digastricus), 6. masseter muscle (m. masseter).

In dog No. 3, we observed several muscle fibres on the ventral side of the neck, connecting the left and right sternocephalicus muscles (Fig. 3). One additional muscle bundle separated from the ventral border of the left sternocephalicus muscle, followed

the course of the main muscle belly, and terminated cranially on the ventral border of the same muscle. From this additional muscle bundle, at the level of the middle of the neck, a few transverse additional fibres separated and connected to transverse fibres diverging from the ventral border of the right sternocephalicus muscle. Fat and connective tissue filled the space between these thin transverse additional fibres.



Fig. 3. Ventral view of the dog No. 3 neck: 1. right pectoralis descendens muscle (m. pectoralis descendens dexter), 2. left pectoralis descendens muscle (m. pectoralis descendens sinister), 3. right sternocephalicus muscle (m. sternocephalicus dexter), 4. left sternocephalicus muscle (m. sternocephalicus sinister), 5. additional muscle bundle and fibres, 6. right sternohyoideus muscle (m. sternohyoideus dexter), 7. left sternohyoideus muscle (m. sternohyoideus sinister), 8. mylohyoideus muscle (m. mylohyoideus), 9. digastricus muscle (m. digastricus), 10. masseter muscle (m. masseter).



Fig. 4. Lateral view of the dog No. 4 neck: 1. serratus dorsalis cranialis muscle (m. serratus dorsalis cranialis), 2. serratus ventralis cervicis muscle (m. serratus ventralis cervicis), 3. serratus ventralis thoracis muscle (m. serratus ventralis thoracis), 4. scalenus dorsalis muscle (m. scalenus dorsalis), 5. additional muscle bundle, 6. scalenus medius muscle (m. scalenus medius), 7. rectus thoracis muscle (m. rectus thoracis), 8. obliquus externus abdominis muscle (m. obliquus externus abdominis).

In dog No. 4, a small and thin additional muscle bundle separated from the ventral border of the left scalenus dorsalis muscle (Fig. 4). This additional muscle bundle originated from the ventral third of the fourth rib, coursed dorsocranially and fused with the rest of the muscle on the level of the second rib. This additional muscle bundle was situated caudodorsally to the rectus thoracic muscle.

Discussion

Neck muscle variations were observed in four (7.02%) dogs and included the sternohyoideus, stylohyoideus, sternocephalicus and scalenus dorsalis muscles. One dog presented three muscle variations (the left sternohyoideus, and the left and right stylohyoides muscles), another two dogs showed two muscle variations (the left and right sternocephalicus muscles) and one dog carried one muscle variation (the left scalenus dorsalis muscle). Muscle variation was twice noticed bilaterally, it once involved the stylohyoideus muscle and once the sternocephalicus muscle. The variations described in our manuscript were perceived as an accidental finding during anatomical dissections, and according to anamnesis data, these dogs did not have any changes in their locomotion or behaviour. Based on that fact, we think that the observed neck muscle variations did not influence the function of the involved muscles. The variations appeared in both sexes and, according to our personal observations, we presume that neck muscle variations are not sex dependent.

The frequency of the neck muscle variations in the dog population is unknown. EVANS (1959) studied a large group of dogs. He described variations of the muscles of the hyoid apparatus in seventy-eight beagles and seventy-eight cross-breed dogs. Other publications dealing with neck muscle variations are case reports and describe only one animal each (GINER et al., 2009; TERRADO and ORTEGA, 2002; TERRADO et al., 2005). Our work can be interpreted as the first research on the occurrence of neck muscle variation in dissected dogs in Croatia. According to our results, even 7.02% of the studied group has a neck muscle variation. Another study we conducted on the same group of dogs was devoted to muscle variations in the pectoral girdle (ALIĆ et al., 2014). The number of dogs with muscle variations in the pectoral girdle was seven (12.3%). Accordingly, if we summarize both neck and pectoral girdle muscle variations in the studied group of dogs, we have found and described muscle variations in eleven of fifty-seven dogs (19.3%). This is a relatively high percentage of variations, and therefore we state that during anatomical dissection considerable attention should be paid to their existence.

None of the muscle variations observed in our study has yet been described in the published literature. Concerning the stylohyoideus muscle, TERRADO and ORTEGA (2002) stated that variations in the musculature of the hyoid region mainly affect that muscle, which is frequently absent and also shows secondary slips or fusions with other muscles.

In addition, GINER et al. (2009) concluded that the muscles at the ventrolateral part of the dog's neck are particularly susceptible to undergoing variations in their attachments.

Neck muscle variations appear due to various causes. These causes may be grouped as close phylogenetic relationships or embryonic development disorders. A close phylogenetic relationship explains adjoining muscles, which exchange muscle bundles. For example, GINER et al. (2009) describe a dog's left sternothyroideus muscle with a group of fibres, which diverged cranially and ventrally from the caudal region of the muscle and terminated at the thyrohyoid bone, close to the termination site of the sternohyoideus muscle. The authors concluded that the presence of this muscle strip developed as a consequence of the close developmental relationship between the sternothyroideus muscle and the apparatus hyoideus. Besides, it can also be interpreted as a sign of the close phylogenetic relationship between the sternothyroideus and the sternohyoideus muscle. A similar explanation was given by EVANS (1959) for the variations observed in the sternohyoideus and stylohyoideus muscle of beagles and cross-breed dogs. He states that the described muscle variations developed as a consequence of the phylogenetic history of the muscles.

Embryonic developmental disorder explained the absence of the left thyrohyoideus muscle described by TERRADO and ORTEGA (2002). The authors presumed either that the myotomal cells of the left thyrohyoideus had not differentiated during embryonic development, or that they died for unknown reasons during the developmental stage. Another explanation given by the authors is that these cells might have differentiated but migrated to a near location, forming part of a neighbouring muscle.

The assumptions of EVANS (1959) and GINER et al. (2009) about the causes of the variations may be accepted in our case, although in our opinion, during the development of certain muscles, their terminations could be explained by the parallel development of bones and muscles in this area.

DIOGO et al. (2008) and DIOGO et al. (2009) specially emphasize that evolution is not directed 'towards' a goal, and surely not 'towards' humans. As a consequence of its unique evolutionary history, each species has its own mixture of primitive and advanced anatomical structures. This fact is very important in muscle description and it explains why some primitive species have their own characteristic muscles, which do not appear in species on higher evolutionary level.

EVANS already (1959) stated that it would be worthwhile to summarize all muscle variations encountered in various breeds of domestic animals and systematize data on occurrence frequency. He concluded that an attempt should be made to ascertain the significance of a variation in the light of its developmental history and comparative anatomy. Our description of neck muscle variations in dogs is a contribution to

phylogenetic research and, in the terms of veterinary medicine, their presence has to be taken into account during surgical procedures (e.g. a ventral approach to cervical vertebrae and intervertebral disks, ventral midline cervical approach to soft tissue cervical structures (thyroid gland, trachea, esophagus, larynx etc.) and approach to larynx and cervical salivary) on the neck region.

Acknowledgements

This manuscript was supported by a grant from the Ministry of Science, Education and Sports of the Republic of Croatia (Scientific project "Metabolic investigation of foetal membranes and animal organs", No. 053-0532400-2129).

The authors dedicate this manuscript to the deceased teacher and dear Professor Mladen Zobundžija.

References

- ALIĆ, I., T. TRBOJEVIĆ VUKIČEVIĆ, M. ĐURAS, S. KUŽIR, G. FAZARINC, V. GJURČEVIĆ KANTURA (2014): Variation in pectoral girdle muscles in dogs. *Anat. Histol. Embryol.* 43, 16-21.
- ANONYMOUS (2012): *Nomina Anatomica Veterinaria*, 5th ed. (revised version). International Committee on Veterinary Gross Anatomical Nomenclature, Editorial Committee Hannover, Columbia, Gent, Sapporo.
- COSKUN, N., F. B. YILDIRIM, O. OZKAN (2002): Multiple muscular variations in the neck region-case study. *Folia Morphol. (Warsz)* 61, 317-319.
- DIOGO, R., V. ABDALA, N. LONERGAN, B. A. WOOD (2008): From fish to modern humans - comparative anatomy, homologies and evolution of the head and neck muscles. *J. Anat.* 213, 391-424.
- DIOGO, R., V. ABDALA, M. A. AZIZ, N. LONERGAN, B. A. WOOD (2009): From fish to modern humans - comparative anatomy, homologies and evolution of the pectoral and forelimb musculature. *J. Anat.* 214, 694-716.
- DYCE, K. M., W. O. SACK, C. J. G. WENSING (2010): *Textbook of Veterinary Anatomy*. Saunders Elsevier, Philadelphia.
- EVANS, H. E. (1959): Hyoid muscle anomalies in the dog (*Canis familiaris*). *Anat. Rec.* 133, 145-162.
- EVANS, H. E., A. de LAHUNTA (2010): *Guide to the Dissection of the Dog*. Saunders Elsevier, Philadelphia.
- GINER, M. I., B. BALLESTER-LURBE, O. GOMEZ, J. TERRADO (2009): Anomaly of the sternothyroideus muscle insertion in a dog. *Open Anat. J.* 1, 11-12.
- KÖNIG, H. E., H.-G. LIEBICH (2007): *Veterinary Anatomy of Domestic Mammals, Textbook and Colour Atlas*. Schattauer, Stuttgart, New York.
- MILLER, M. E., G. C. CHRISTENSEN, H. E. EVANS (1964): *Anatomy of the Dog*. WB Saunders Company, Philadelphia, London.

- NICKEL, R., A. SCHUMMER, E. SEIFERLE (1987): Lehrbuch der Anatomie der Haustiere. Band II. 6. Auflage. Verlag Paul Parey, Berlin und Hamburg.
- PIERMATTEI, D. L., K. A. JOHNSON (2004): An Atlas of Surgical Approaches to the Bones and Joints of the Dog and Cat, 4th ed. Saunders, Philadelphia.
- SCHALLER, O. (2007): Illustrated Veterinary Anatomical Nomenclature. Ferdinand Enke Verlag, Stuttgart.
- SLATTER, D. (2003): Textbook of Small Animal Surgery, 3rd ed. Saunders, Philadelphia.
- SOOKUR, P. A., A. M. NARAGHI, R. R. BLEAKNEY, R. JALAN, O. CHAN, L. M. WHITE (2008): Accessory muscles: anatomy, symptoms, and radiologic evaluation. Radiographics 28, 481-499.
- TERRADO, J., J. ORTEGA (2002): Unilateral agenesis of the thyrohyoid muscle in a dog. Vet. J. 164, 156-158.
- TERRADO, J., M. GINER, O. GOMEZ (2005): Anomalous insertion of the splenius muscle in a dog. Vet. J. 170, 375-376.
- THAKUR, A., A. BERTHA, S. K. PARMAR (2011): Multiple variations in neck musculature and their surgical implications. IJAV 4, 171-173.

Received: 20 December 2012

Accepted: 10 October 2013

ALIĆ, I., T. TRBOJEVIĆ VUKIČEVIĆ, M. ĐURAS, S. KUŽIR, D. VNUK, S. NEJEDLI, L. PENDOVSKI, V. GJURČEVIĆ KANTURA: Anatomske varijacije vratnih mišića u pasa. Vet. arhiv 84, 53-62, 2014.

SAŽETAK

Varijacije mišića učestale su u ljudi, kao i u divljih i domaćih životinja. Varijacije mišića mogu se definirati kao pojava dodatnoga mišićnog traka ili trbuha, neuobičajeno mjesto početka ili završetka mišića kao i potpuni nedostatak mišića. U ovom radu opisali smo različite varijacije mišića u pasa. U razdoblju između 2005. i 2011. godine na nastavi anatomije secirano je 57 pasa srednje veličine, različite pasmine, spola i dobi. Varijacije mišića vrata uočili smo u 4 (7,02%) psa na mišićima: m. sternohyoideus, m. stylohyoideus, m. sternocephalicus i m. scalenus dorsalis. Na jednom psu pronašli smo tri varijacije (lijevi m. sternohyoideus te lijevi i desni m. stylohyoides), na druga dva psa dvije varijacije (lijevi i desni m. sternocephalicus) te na jednom psu jednu varijaciju (lijevi m. scalenus dorsalis). Bilateralne varijacije mišića uočene su triput i uključuju m. stylohyoideus u jednom i m. sternocephalicus u dva slučaja. Uočene varijacije mišića mogu se obrazložiti bliskim filogenetskim odnosom. Opis varijacija mišića u ovom radu naš je doprinos filogenetskim istraživanjima, a u okvirima veterinarske medicine, njihova se prisutnost mora uzeti u obzir tijekom kirurških zahvata u području vrata.

Ključne riječi: pas, anatomske varijacije, m. sternohyoideus, m. stylohyoideus, m. sternocephalicus, m. scalenus dorsalis
