

Assessment of predisposing effect of coccidiosis to necrotic enteritis in broiler chickens

Soundarapandian Sivaseelan*, Subramanian Vijayakumar**,
Shanmugasamy Malmarugan, Perumal Balachandran,
and Gurusamipalayam A. Balasubramaniam

Department of Veterinary Pathology, Veterinary College and Research Institute, Namakkal, Tamil Nadu, India

SIVASEELAN, S., S. VIJAYAKUMAR, S. MALMARUGAN, P. BALACHANDRAN, G. A. BALASUBRAMANIAM: Assessment of predisposing effect of coccidiosis to necrotic enteritis in experimentally induced broiler chicken. Vet. arhiv 83, 653-664, 2013.

ABSTRACT

In order to assess the predisposing effect of coccidiosis to Necrotic enteritis (NE), an experimental study was conducted in broiler chicken. In the first trial (NE alone), symptoms were noticed from the 4th to 7th days post inoculation (DPI), but no mortality was recorded. In the second trial (NE primed with coccidiosis), 23 % mortality was recorded. Grossly, a maximum intestine lesions score of 2 was recorded on the 6th DPI in the first trial. In the second trial, a maximum intestine lesions score of 3.67 was recorded on the 6th DPI. Microscopically, in the first trial, the birds' intestines from the 4th to the 7th DPI showed hyperplasia of the villi of the jejunal mucosa. In the second trial, the birds' intestines from 2nd to 4th DPI showed severe hyperplasia of the villi, and the presence of *E. necatrix* schizonts within and outside the enterocytes. In the second trial, intestines from 5th to 7th DPI revealed shortening of the villi, diphtheritic pseudomembrane formation and the presence of *C. perfringens* organisms among the necrotic epithelium. It was concluded that intestinal damage characterised by destruction of crypts cells, as well as villi enterocytes and rupture of blood vessels by schizonts and merozoites of *E. necatrix* predisposed the chicken to a clinical form of NE to increase the mortality percentage.

Key words: necrotic enteritis, coccidiosis, experimental study, chicken

Introduction

Necrotic enteritis occurs in clinical and non-clinical forms. The clinical form is characterised by extensive necrosis of the small intestine, with increased mortality rate

*Corresponding author:

Dr. Soundarapandian Sivaseelan, M.V.Sc., Ph.D Associate Professor, Department of Veterinary Pathology, Veterinary College and Research Institute, Namakkal - 637 002, Tamil Nadu, India, Phone: +91 94 4293 7227; E-mail: pathologysiva@yahoo.co.in

**Part of the M.V.Sc. Thesis

(FUKATA et al., 1988), whereas the sub-clinical form causes lesser mortality with milder intestinal lesions and hepatitis (SASAKI et al., 2003). The alpha and beta toxins produced by *C. perfringens* are responsible for the lesions noticed in NE (WAGES and OPENGART, 2003). The type A strains produce alpha toxin, while *C. perfringens* type C strains produce alpha toxin together with beta toxin. Alpha toxin, a phospholipase C, is considered to be a major contributing factor towards the development of intestinal necrosis.

DAHIYA et al. (2006) grouped predisposing factors for NE into the following categories: coccidial infection, environmental and management conditions, physiological stress, immunosuppression and nature of diet. In many outbreaks of NE, coccidial oocysts were also identified. Two trials were conducted, where the birds were only challenged with *C. perfringens* bacteria in the first trial. The second one was carried out in a similar manner, but the birds were primed with *E. necatrix* oocysts. This study has been carried out to ascertain the sequential pathological role of coccidial parasites for the corresponding severity of NE.

Materials and methods

Confirmation of necrotic enteritis

Polymerase chain reaction (PCR). Specimens such as intestinal contents and mucosal scrapings collected from the field birds suspected for NE were used for bacterial culture. Isolates of *C. perfringens* were grown on perfringens agar plates (dehydrated perfringens agar media from Hi-Media Laboratories, Mumbai, India) under anaerobic incubation for 48 hours. The DNA was extracted from *C. perfringens* cells by a method involving treatment with high salts (SAMBROOK and RUSSEL, 2001). The DNA extracted was subjected to PCR according to the protocol reported by BAUMS et al. (2004) with the following modifications.

Primers. The alpha toxin specific oligonucleotide primers (M/s. Genei, India) used in this study were

CP - F- AGT CTA CGC TTG GGA TGG AA and

CP - R- TTT CCT GGG TTG TCC ATT TC

which flanked 900 base pair DNA sequence (BAUMS et al., 2004).

The primer concentration used in this study was 50 pico moles.

Preparation of reaction mixture. The reaction mixture contained a total volume of 50 μ L (Template DNA 2 μ L, Primers CP - F 0.5 μ L and CP - R 0.5 μ L, Master Mix 21 μ L (Genei, Bangalore, India), Molecular biology grade water 26 μ L).

Amplification cycles and electrophoresis. PCR amplification reaction was conducted in an MJ thermal cycler with initial denaturation at 95 °C for 2 min 30 seconds, 35 repeated cycles of denaturation at 95 °C for 1 min, annealing at 55 °C for 1 min, extension at 72 °C

for 1 min and 20 seconds and final extension at 72 °C for 2 minutes. The PCR products were run in 1.5 per cent agarose gel in TAE buffer (Merck, India) with ethidium bromide 5 µg per mL.

Confirmation of coccidiosis. Mucosal scrapings from the guts of field birds suspected for coccidiosis were inoculated into a two per cent potassium dichromate solution in a shallow layer of 5 mm depth in a petri dish at room temperature. The petri dish was covered to minimize evaporation of dichromate solution. Periodical rotational agitation was given to the petri dish to facilitate aeration. A sufficient quantity of the same solution was added, as and when required.

A small quantity of a well mixed culture was transferred to a test tube and centrifuged at 2000 rpm for 2 min. The supernatant was discarded and the sediment was mixed with a small volume of Sheather's sugar solution (specific gravity, 1.2), which was slowly added up to the brim of the tube until a convex upper meniscus was obtained, and then the tube was allowed to stand undisturbed for about 10 min. The oocysts at the top of the tube were transferred on to a slide by a coverslip and examined under a microscope. The sporulated oocysts from two per cent potassium dichromate solution were stored at 4 °C until use in the trial. The oocysts were identified on the basis of various morphological parameters such as size, shape, colour and shape index (length/width), based on the procedure described by LEVINE (1985).

Experimental birds. Ninety day old broiler chicks (Cobb 400) were reared as per the standard management procedure. The birds were vaccinated on the 7th day for Newcastle disease and the 14th day for infectious bursal disease. The birds were fed with standard broiler feed.

Clostridium perfringens organisms. The *Clostridium perfringens* bacteria isolated from the field outbreaks of NE using the perfringens agar plates and confirmed by PCR technique were used at the dose of 10⁸ cfu per mL per chick to carry out the experimental study in chickens (AL-SHEIKHLY and TRUSCOTT, 1977).

Eimeria necatrix oocysts. *Eimeria necatrix* oocysts were isolated from natural cases of coccidiosis and preserved at 4 °C. The oocyst suspension was washed several times with tap water to remove potassium dichromate. After washing, the number of oocysts per mL of suspension was counted by the McMaster oocyst counting technique and diluted with water so as to contain 20,000 oocysts per mL.

Experimental trials. In the first trial, a total of forty-five one-day old chicks were divided into two groups of 30 and 15 that served as treatment and control groups respectively. The experimental birds were inoculated orally with *C. perfringens* bacteria at the dose rate of 10⁸ cfu per mL per chick on the 15th day. Feed was withdrawn for 8 h prior to inoculation of bacterial culture to minimize the occurrence of regurgitation. From

the 16th day (1st DPI) to the 30th day (15th DPI), the symptoms manifested by inoculated birds were recorded. Three inoculated birds and one or two control birds were sacrificed daily by the humane method of cervical dislocation for seven subsequent days from the 16th day (1st DPI) to the 22nd day (7th DPI) and on the 30th day (15th DPI), to ascertain the pathological changes to the intestines and liver. Tissue samples were collected for histopathological studies. Confirmation of bacteria was carried out by culture and isolation methods (BARROW and FELTHAM, 1993).

The second trial was conducted utilizing another 45 birds in a similar manner to the first one. However, additionally, the experimental birds were primed orally with 20000 *E. necatrix* coccidial oocysts per chick on the 15th day after withdrawal of feed for 8 h and challenging with clostridial organisms was carried out on the 18th day. A sequential pathological study was carried out from the 19th day (1st DPI) onwards for seven subsequent days and on the 15th DPI as mentioned in the first trial (three inoculated birds and one or two control birds were sacrificed).

Gross pathology. Detailed necropsy was conducted on randomly selected experimental birds from the treatment and control groups. Gross lesions of NE and coccidiosis complicated NE were recorded.

Lesion scoring. The intestines of both naturally affected as well as experimentally inoculated birds were incised longitudinally and examined for gross lesions of the NE. Lesion scoring of the NE was done following the methods of WILLIAMS et al. (2003) as follows

Table 1. Gross lesion score of the intestine in necrotic enteritis affected chickens

| Score | Observations |
|-------|---|
| 0 | No lesions |
| 1 | Thin walled and friable intestines |
| 2 | Focal necrosis or ulceration |
| 3 | Patches of necrosis 2-3 cm long |
| 4 | Diffuse necrosis typical of field cases |

Histopathology. A transverse section of tissue approximately 0.5 cm in thickness was taken from the duodenum, jejunum and ileum. Tissue pieces were fixed in 10 % buffered neutral formalin and trimmed to a thickness of about 3 mm.

The tissues were dehydrated, cleared and embedded in paraffin in routine manual processing. Tissues were cut at 5 µm thicknesses, mounted on glass slides, stained with haematoxylin and eosin, and covered with cover slips for histopathological examinations.

Results

Confirmation of necrotic enteritis and coccidiosis. All the bacterial isolates produced a PCR amplification band at 900 bp (Fig. 1). Coccidial oocysts were identified as *Eimeria* species under oil immersion microscopy on the basis of their morphology (Fig. 2).

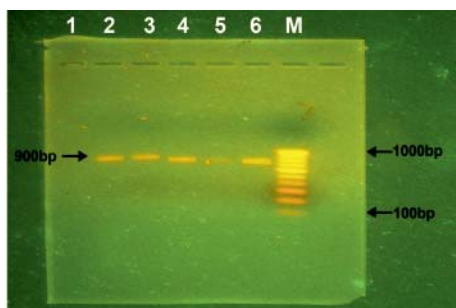


Fig. 1. A 900 bp size PCR amplification in agarose gel electrophoresis (lane 1-6. positive samples; M. known DNA ladder)

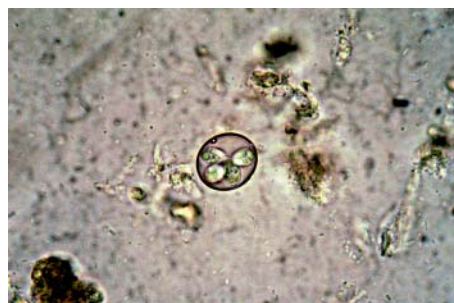

Fig. 2. An oval sporulated *Eimeria* species oocysts containing four sporozoites

Experimental trials - clinical signs.

Trial I. Clinical signs were not observed in the experimentally challenged birds up to the 3rd DPI. Dullness, anorexia, reluctance to move, diarrhoea (dark brown coloured), dehydration and ruffled feathers were observed from the 4th to 7th DPI. The intensity of symptoms decreased after the 8th DPI.

Trial II. Dullness and anorexia were noticed even on the 1st DPI and the severity of diarrhoea increased up to the 7th DPI. A mortality rate of twenty-three per cent was recorded in this trial.

Gross pathology

Trial I. Normal appearance of the intestines from the 1st to 3rd DPI, puffed up mucosa with catarrhal changes in the jejunal region on the 4th DPI and thickening of jejunal mucosa, with haemorrhagic foci (Fig. 3) from the 5th to 7th DPI were observed. Normal appearance of intestines was noticed on the 15th DPI.

Normal appearance of the liver from the 1st to 4th DPI, mild to moderate hepatomegaly with rounded borders, without any notable necrotic zones on the surface from the 5th to 7th DPI and normal appearance on the 15th DPI were recorded.

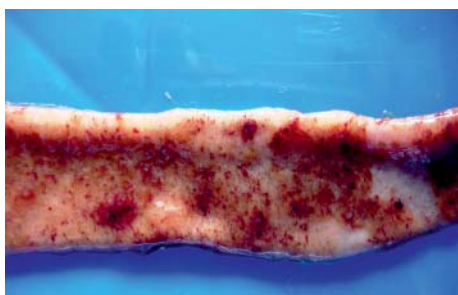


Fig. 3. Intestine from 4th DPI chicken (trial I) showing thickening of jejunal mucosa with haemorrhagic foci (red spots) .

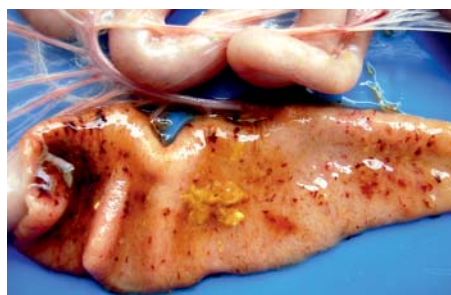

Fig. 4. Intestine from first DPI (trial II) showing edematous mucosa with diffuse red military haemorrhagic areas.

Lesion scoring. In coccidiosis non-primed birds, the maximum average intestine gross lesion score observed was two.

Trial II. Edematous mucosa with diffuse petechiae on the jejunal mucosa (Fig. 4) was observed even on the first day after inoculation. On 2nd DPI, a gas filled dilated jejunum and mucosal thickening with discrete foci of fur like tiny mucosal yellowish eruptions were noticed. Severe mucosal thickening, with yellowish brown eruptions resembling the ‘dirty Turkish towel’ appearance in the jejunal region and adjacent parts of the duodenum and ileum, with blood mixed with yellowish brown semisolid intestinal content, were observed from the 3rd to 4th DPI (Fig. 5). The jejunal mucosa from the 5th to 7th DPI showed a yellowish brown colored diphtheritic membrane, consisting of desquamated necrosed mucosal enterocytes, erythrocytes and fibrin.

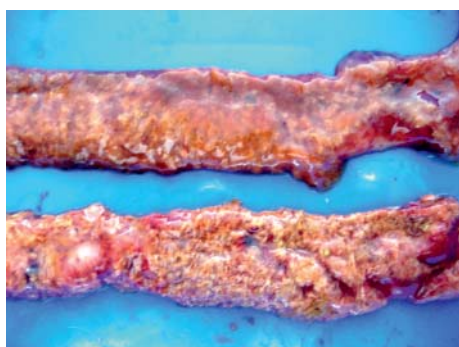

Fig. 5. Intestinal from 3rd DPI (trial II) revealing yellowish ‘dirty Turkish towel’ appearance throughout the mucosa.

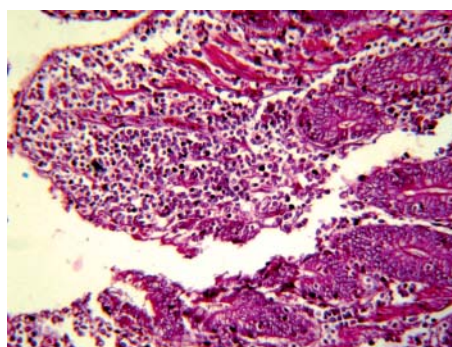


Fig. 6. Intestine from 5th DPI (trial I) depicting hyperplasia of villi of the jejunal mucosa, and infiltration of lymphocytes and macrophages (dark round cells). H&E; $\times 40$

On the first DPI, the liver appeared normal; it became pale in colour on the 2nd DPI and enlarged with rounded borders from the 3rd to 4th DPI. Moderate hepatomegaly with rounded borders and diffuse necrotic foci on the surface were observed from the 5th to 7th DPI. The liver appeared normal on 15th DPI.

Lesion scoring. The maximum average lesion score observed in coccidiosis primed birds was 3.67.

Histopathology

Trial I. Normal architecture of villi and crypts of Lieberkuhn was observed in the intestines from the birds on the 1st to 3rd DPI. Degeneration and necrosis of the upper one third of the villi in the intestines from the 4th DPI; hyperplasia of the villi of the jejunal mucosa, and infiltration of lymphocytes and macrophages into the lamina propria and within the villi (Fig. 6) from the 5th to 7th DPI were observed.

Normal architecture of hepatic cords and the central vein of the liver was observed from the 1st to 4th DPI. Disruption of the architecture of hepatic cords, mild sinusoidal congestion and liquefactive necrosis of group of hepatocytes were noticed from the 5th to 7th DPI.

Trial II. Intestines from the birds on the 1st DPI showed normal architecture of the villi and crypts of Lieberkuhn, but mild to moderate haemorrhages were observed in between the villi and the crypts. The presence of schizonts and merozoites of *E. necatrix* within the villi (Fig. 7) were observed. Shortening of the villi and diphtheritic pseudo membrane formations on the mucosa of the jejunal region of the small intestine were observed from the 5th to 7th DPI.

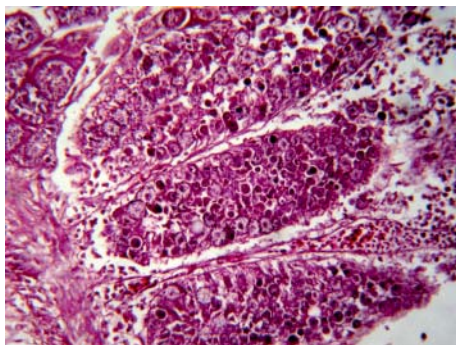


Fig. 7. Intestine from 4th DPI (trial II) revealing the presence of round to oval developing stages of *E. necatrix* within the villi. H&E; ×40

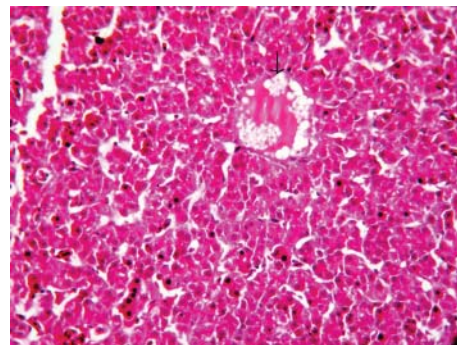


Fig. 8. Liver from 5th DPI (trial II) depicting derangement of hepatic cords and liquefactive necrosis (arrow). H&E; ×40

Normal architecture of the hepatic cords and the central vein of the liver on the first DPI; sinusoidal congestion, and occasional hepatic degeneration and necrosis on the 2nd DPI; focal coagulative necrosis of hepatocytes from the 3rd to 4th DPI; derangement of hepatic cords, diffuse coagulative necrosis and liquefactive necrosis (Fig. 8) were observed from the 5th to 7th DPI.

Discussion

Confirmation of necrotic enteritis and coccidiosis. Based on the PCR results, all the isolates were proved to be alpha toxin producing strains of *C. perfringens*. Morphological assessment confirmed the coccidial oocysts.

Clinical signs

Trial I. Experimentally challenged birds did not show any sign up to the 3rd DPI, which indicated the lesser severity of the disease in coccidia non-primed chicken. The lesions noticed from the 4th to 7th DPI are in agreement with the earlier reports of AL-SHEIKHLY and TRUSCOTT (1977) and AL-SHEIKHLY and AL-SAIEG (1980). The dark brown colored semisolid droppings noticed among the induced birds correlated well with the earlier observations of KALDHUSDAL and HOFSHAGEN (1992), who reported wood shaving coloured, dark and moist droppings in affected birds. The decrease in intensity of symptoms after the 8th DPI indicated that the action of this bacteria and its toxin is limited to 7 days.

Trial II. Dullness and anorexia were noticed even on the 1st DPI and the increased severity of diarrhoea up to the 7th DPI indicated the high virulence of NE in coccidia primed birds. This finding is supported by the report of PETIT et al. (1999), who observed that intestinal damage caused by coccidial pathogens is the prime predisposing factor for outbreaks of NE. The mortality rate of twenty-three per cent recorded in this study correlated well with the earlier report on mortality by LONG and TRUSCOTT (1976), who observed total mortality of 28 per cent, when the disease was induced in broiler chickens using a pure culture.

Gross pathology

Trial I. The lower degree of lesions observed in this trial indicated the lesser severity of the disease, due to slow proliferation and lesser numbers of *C. perfringens* organisms in coccidia non-primed birds. The normal appearance of the intestines on the 15th DPI indicated the complete recovery of birds.

Clostridium perfringens organisms are normal inhabitants of chicken intestines and their number is minimal (about 10⁴ cfu/g of digesta). The disease occurs when high numbers of bacteria coincide with damaged intestinal mucosa (AL-SHEIKHLY

and TRUSCOTT, 1977). Disturbances in normal intestinal microflora may cause rapid proliferation of *C. perfringens*, increasing their numbers, which range from 10^7 to 10^9 cfu/g of digesta, resulting in toxin production (KONDO, 1988).

Formation of a pseudo membrane on the jejunal mucosa, which is commonly observed in the clinical type of necrotic enteritis (WAGES and OPENGART, 2003), was not noticed in this trial, which indicated the lesser severity of the disease in coccidia non-primed chicken.

The lesions observed in the liver in this trial indicated the lesser severity of the disease in coccidiosis non-primed chicken.

Lesion scoring. In coccidia non-primed birds, the recorded maximum average intestine gross lesion score of two suggested that development of NE is subclinical.

Trial II. The edematous mucosa with diffuse petechiae on the jejunal mucosa, even on the first day after inoculation, indicated the higher severity of the disease. The high degree of lesions observed in this trial indicated the increased severity of NE. These findings are in agreement with the earlier report of BROUSSARD et al. (1986), and WAGES and OPENGART (2003).

Liver lesions observed in this study correlated well with the earlier report of ELEAZER and HARRELL (1976), who observed hepatomegaly with greenish discoloration and miliary necrotic foci on the surface.

Lesion scoring. The maximum average lesion score observed in coccidiosis primed birds was 3.67, as against the score of 2 recorded in the coccidiosis non-primed birds, indicating the higher severity of the disease. This was well supported by the 23 per cent mortality recorded in trial II, as against no mortality in trial I. This clearly indicates that predisposition by coccidial parasites creates a congenial environment for the proliferation of *C. perfringens* bacteria and their toxin production. This finding has been supported by VAN IMMERSEEL et al. (2004), who reported that intestinal damage caused by coccidial pathogens is the prime predisposing factor for outbreaks of NE. JACKSON et al. (2003) reported that *Eimeria* species, such as *E. maxima* and *E. acervulina*, were known to predispose to NE. AL-SHEIKLY and AL-SAIEG (1980) observed that *Eimeria* infection alone, or feeding *C. perfringens* contaminated feed without *Eimeria* infection, did not result in NE.

Histopathology

Trial I. Histopathological changes observed in this study correlated well with the gross lesions noticed and depicted the lesser severity of the disease in coccidia non-primed birds. These findings are in accordance with those of BROUSSARD et al. (1986), GAZDINSKI and JULIAN (1992), and OLKOWSKI et al. (2006). The liver microscopical lesions observed in this trial also correlated well with the gross lesions noticed and demonstrate the lesser severity of the disease in coccidia non-primed birds.

Trial II. The microscopic lesions observed in the intestine from the birds of the 1st DPI are in contrast to the report of AL-SHEIKHLY and TRUSCOTT (1977), who reported the histological changes in experimentally induced NE cases as massive necrosis of the villi with necrotic zones, reaching the crypts, and infiltration of the lamina propria with mononuclear cells. These lesions were observed only from the 2nd to 4th DPI in this study.

The presence of schizonts and merozoites of *E. necatrix* within the villi should have caused the destruction of crypt cells as well as villi enterocytes and the rupture of blood vessels, which might be the reason for the yellowish brown blood mixed intestinal content observed in this study (RAMAN et al., 2011). Intestinal destruction with rupture of blood vessels provides growth factors through plasma that are essential for the extensive proliferation of *C. perfringens* and production of its toxin to produce the clinical form of the disease (VAN IMMERSEEL et al., 2004).

The microscopic lesions of the liver observed in this study show that apart from intestinal damage, this disease also severely affects the liver.

It was concluded that severe intestinal damage and corresponding increased mortality is caused by the coccidiosis predisposing effect to NE. Destruction of crypt cells as well as villi enterocytes and rupture of blood vessels by schizonts and merozoites of *E. necatrix* provides a conducive environment for more proliferation of *Clostridium perfringens* bacteria to induce the clinical form of NE in chickens, with an increased percentage of mortality.

References

- AL-SHEIKHLY, F., R. B. TRUSCOTT (1977): The pathology of necrotic enteritis of chickens following infusion of broth culture of *Clostridium perfringens* into the duodenum. Avian Dis. 21, 230-240.
- AL-SHEIKHLY, F., A. AL-SAIEG (1980): Role of coccidia in the occurrence of necrotic enteritis of chickens. Avian Dis. 24, 324-333.
- BARROW, G. I., R. K. A. FELTHAM (1993): Cowan and Steel's Manual for the Identification of Medical Bacteria, 3rd ed., Cambridge University Press, Cambridge.
- BAUMS, C. G., U. SCHOTTE, G. AMTSBERG, R. GOETHE (2004): Diagnostic multiplex PCR for toxin genotyping of *Clostridium perfringens* isolates. Vet. Microbiol. 100, 11-16.
- BROUSSARD, C. T., C. L. HOFACRE, R. K. PAGE, O. J. FLETCHER (1986): Necrotic enteritis in cage reared commercial layer pullets. Avian Dis. 30, 617-619.
- DAHIYA, J. P., D. C. WILKIE, A. G. VAN KESSEL, M. D. DREW (2006): Potential strategies for controlling necrotic enteritis in broiler chickens in post-antibiotic era. Animal Feed Sci. Technol. 129, 60-88.
- ELEAZER, T. S., J. S. HARRELL (1976): *Clostridium perfringens* infection in turkey poults. Avian Dis. 20, 774-776.
- FUKATA, T., Y. HADATE, E. BABA, T. UEMURA, A. ARAKAWA (1988): Influence of *Clostridium perfringens* and its toxins in germ free chickens. Res. Vet. Sci. 44, 68-70.

S. Sivaseelan et al.: Assessment of predisposing effect of coccidiosis to necrotic enteritis in broiler chickens

- GAZDINSKI, P., R. J. JULIAN (1992): Necrotic enteritis in turkeys. *Avian Dis.* 36, 792-798.
- JACKSON, M. E., D. M. ANDERSON, H. Y. HSIAO, G. F. MATHIS, D. W. FODGE (2003): Beneficial effect of beta-mannanase feed enzyme on performance of chicks challenged with *Eimeria* sp. and *Clostridium perfringens*. *Avian Dis.* 47, 759-763.
- KALDHUSDAL, M., M. HOFSHAGEN (1992): Barley inclusion and avoparcin supplementation in broiler diets. Clinical, pathological and bacteriological findings in a mild form of necrotic enteritis. *Poult. Sci.* 71, 1145-1153.
- KONDO, F. (1988): *In vitro* lecithinase activity and sensitivity to 22 antimicrobial agents of *Clostridium perfringens* isolated from necrotic enteritis of broiler chickens. *Res. Vet. Sci.* 45, 337-340.
- LEVINE, N. D. (1985): *Veterinary Protozoology*. 1st ed. Ames: Iowa State Press, pp. 781-785
- LONG, J. R., R. B. TRUSCOTT (1976): Necrotic enteritis in broiler chickens. III. Reproduction of the disease. *Can. J. Comp. Med.* 40, 53-59.
- OLKOWSKI, A. A., C. WOJNAROWICZ, M. CHIRINO-TREJO, M. D. DREW (2006): Responses of broiler chickens orally challenged with *Clostridium perfringens* isolated from field cases of necrotic enteritis. *Res. Vet. Sci.* 81, 99-108.
- PETIT, L., M. GIBERT, M. R. POPOFF (1999): *Clostridium perfringens*: toxinotype and genotype. *Tren. Microbiol.* 7, 104-110.
- RAMAN, M., S. S. BANU, S. GOMATHINAYAGAM, G. D. RAJ (2011): Lesion scoring technique for assessing the virulence and pathogenicity of Indian field isolates of avian *Eimeria* species. *Vet. arhiv* 81, 259-271.
- SAMBROOK, J., D. W. RUSSEL (2001): *Molecular cloning: A Laboratory Manual*. 3rd ed. New York: Cold Spring harbor Laboratory Press.
- SASAKI, J., M. GORYO, M. MAKARA, K. NAKAMURA, K. OKADA (2003): Necrotic hepatitis due to *Clostridium perfringens* infection in a newly hatched broiler chickens. *J. Vet. Med. Sci.* 65, 1249-1251.
- VAN IMMERSSEEL, F., J. De. BUCK, F. PASMANS, G. HUYGHEBAERT, F. HAESEBROUCK, R. DUCATELLE (2004): *Clostridium perfringens* in poultry: an emerging threat for animal and public health. *Avian Pathol.* 33, 537-549.
- WAGES, D. P., K. OPENGART (2003). Necrotic Enteritis. In: *Diseases of Poultry*. (Saif, Y. M., H. J. Barnes, J. R. Glisson, A. M. Adly, L. R. McDougald, D. E. Swayne, Eds.), 11th ed. Ames: Iowa State Press, pp. 781-785.
- WILLIAMS, R. B., R. N. MARSHALL, R. M. LA RAGIONE, C. CATCHPOLE (2003): A new method for the experimental production of necrotic enteritis and its use for studies on the relationships between necrotic enteritis, coccidiosis and anticoccidial accination of chickens. *Parasit. Res.* 90, 19-26.

Received: 17 October 2012

Accepted: 17 April 2013

SIVASEELAN, S., S. VIJAYAKUMAR, S. MALMARUGAN, P. BALACHANDRAN, G. A. BALASUBRAMANIAM: Procjena predispozicijskog učinka kokcidioze na pojavu nekrotičnog enteritisa u pokusnoj infekciji tovnih pilića. Vet. arhiv 83, 653-664, 2013.

SAŽETAK

Pokusno istraživanje u tovnih pilića poduzeto je radi procjene predispozicijskog učinka kokcidioze na pojavu nekrotičnog enteritisa (NE). U prvom pokusu (samo NE), simptomi su bili uočeni od 4. do 7. dana nakon zaražavanja, ali bez uginuća. U drugom pokusu (NE uz prethodnu kokcidiozu) ustanovljen je 23%-tni mortalitet. Najjače patoanatomske promjene (2. stupnja) na crijevima bile su u prvom pokusu opažene 6. dana nakon infekcije. I u drugom pokusu najjače promjene na crijevima (3,67) bile su ustanovljene 6. dana nakon infekcije. U prvom je pokusu mikroskopski bila dokazana hiperplazija crijevnih resica u sluznici jejunuma i to od 4. do 7. dana nakon infekcije. U drugom je pokusu teška hiperplazija crijevnih resica bila dokazana od 2. do 4. dana nakon infekcije. Dokazani su bili i šizonti vrste *E. necatrix* u enterocitima i izvan njih. U drugom je pokusu bilo zapaženo i skraćanje crijevnih resica od 5. do 7. dana nakon infekcije, zatim difterične pseudomembranozne naslage te prisutnost bakterije *C. perfringens* u nekrotičnom epitelu. Zaključuje se da oštećenje crijeva uzrokovano šizontima i merozoitima vrste *E. necatrix*, koje se očitovalo propadanjem stanica crijevnih kripti kao i propadanjem crijevnih resica te prsnućem krvnih žila, djeluje kao predispozicijski čimbenik na kliničku pojavu nekrotičnog enteritisa i povećani mortalitet.

Ključne riječi: nekrotični enteritis, kokcidioza, pokusna infekcija, pilići
