

Correlations between radiographic, magnetic resonance imaging and histopathologic findings in experimentally ruptured cranial cruciate ligament joints in rabbits

Behrooz Nikahval^{1*}, Seifollah N. Dehghani¹, Mohammad H. Bagheri², Sara Pakbaz³, Maryam Mansourian⁴, Nader Tanideh⁵, Davood Mehrabani⁵, and Masoud Alirezaei⁶

¹Department of Surgery and Radiology, School of Veterinary Medicine, Shiraz University, Shiraz, Iran

²Department of Radiology, Namazee Hospital, Shiraz University of Medical Sciences, Shiraz, Iran

³Department of Pathology, Chamran Hospital, Shiraz University of Medical Sciences, Shiraz, Iran

⁴Razi Vaccine and Serum Research Institute, Shiraz, Iran

⁵Stem cell and Transgenic Technology Research Center, Shiraz University of Medical Sciences, Shiraz, Iran

⁶School of Veterinary Medicine, University of Lorestan, Khorram Abad, Iran

NIKAHVAL, B., S. N. DEGHANI, M. H. BAGHERI, S. PAKBAZ, M. MANSOURIAN, N. TANIDEH, D. MEHRABANI, M. ALIREZAEI: Correlations between radiographic, magnetic resonance imaging and histopathologic findings in experimentally ruptured cranial cruciate ligament joints in rabbits. Vet. arhiv 83, 537-550, 2013.

ABSTRACT

Experimental osteoarthritis (OA) was induced in the knee joints of rabbits and the trend of changes were compared by radiography, Magnetic Resonance Imaging (MRI) and histopathology. Twenty rabbits were randomly divided into two equal groups based on short (30 days) and long-term (180 days) follow ups. In half of the animals in each group (n = 5) OA was induced by sectioning the cranial cruciate ligament and in the other half, only arthrotomy was performed as a sham operation. Radiography and MRI were carried out on days 0 and 30 in the group of short term studies, and on days 0, 90 and 180 in the other group. Histopathological examinations were performed on day 30 in the short-term group after the animals had been sacrificed and in the other group on day 180. The slope of changes over the course of the study between all 3 methods and the grade of changes, were both highest in histopathology, and then in MRI and radiology respectively. The slope of changes was 0.01 for histopathology, 0.009 for MRI and 0.004 for radiology. The ratios of slopes, when compare to each other, were as follows: His./MRI = 1.1, His./Rad. = 2.5, MRI/Rad. = 2.2. Comparison of MRI with radiology revealed that radiology would not show signs of OA when the MRI grade is less than a grade

*Corresponding author:

Dr. Behrooz Nikahval, Department of Surgery and Radiology, School of Veterinary Medicine, Shiraz University, P.O. Box 1731-71345, Shiraz, Iran, E-mail: nikahval@shirazu.ac.ir

of 0.27. Comparing both imaging techniques with histopathology showed that whenever the histopathological grade was below 0.22, radiology would not show signs of OA involvement, while MRI was capable of showing signs of OA involvement whenever it was more than 0.018 on histopathological grade.

Key words: radiography, magnetic resonance imaging, histopathology, ruptured cranial cruciate ligament, rabbit

Introduction

Osteoarthritis (OA) represents a degenerative pathological imbalance involving the whole joint and its component parts (SINUSAS, 2012). Animal models of OA have substantially contributed to the understanding its pathogenesis (ADAMS and BILLINGHAM, 1982). In the Pond-Nuki model, a mechanically instable knee is produced by transection of the cranial cruciate ligament (CCL), leading to progressive degenerative changes of articular cartilage (POND and NUKI, 1973). Conventional radiography is the method most frequently used for monitoring the progression of osteoarthritis, however, it may not show osteoarthritic changes of the knee until late in the disease process, and mostly may show involvement of only one or two compartments (WIRTH et al., 2013). Magnetic resonance imaging (MRI) has emerged as an important modality in the noninvasive evaluation of osseous and soft-tissue structures in and around the knee. The most accurate way of diagnosis of OA is histopathological evaluation, which requires invasive sampling of the suspected joints, which may induce more joint tissue damages (MARTIG et al., 2006).

Although both imaging techniques are highly practical, to date, there is no published information evaluating these methods on the same scales and the same conditions, and with histopathology as the gold method for OA detection. Therefore, the present study was conducted in order to induce experimental OA in the rabbit's knee joint (stifle), as an animal model, and to follow the term of changes by radiography, MRI and histopathology in short and long term studies, and to find the correlations between these diagnostic modalities in similar situations, in order to find the relative power of each technique in detecting OA.

Materials and methods

Animals. Twenty adult (18 ± 3 months), Dutch, male rabbits, weighing 3.2 ± 0.4 kg were randomly divided into two equal groups. The CCL of the left knees of one group was sectioned (Group T), and in the second group, only arthrotomy was performed using the same approach, leaving the CCL intact (Group A- Sham operation group). In both groups, the left knees before surgery were considered as control. Half of the animals in each group were designated for short-term studies of 30 days (which divided into two subgroups; CCL-transected Group = TS and Arthrotomized group = AS). The other half were used for long term studies, of 180 days (TL and AL). Skeletal maturity and absence

of natural OA were established by clinical and radiological examinations, to exclude any pre-existing abnormalities from the study. Animal selection, experiments, post operative care and the sacrifice procedure all adhered to the guidelines under supervision of the Animal Care Ethics Committee of the School of Veterinary Medicine (NIH publication NO. 86-23, revised 1985 were followed.). All experiments were carried out under aseptic conditions. The protocol of anesthesia, surgical procedures, post-operative care and sacrifice were identical for all animals. During the experiments, the animals were housed one per cage, maintained under controlled environmental conditions (ambient temperature of 21 ± 2 °C, relative humidity of 65-70%, and a balanced diet with free access to food and water).

Operative procedures. After the animals were anesthetized, the whole stifle region was aseptically prepared for surgery. The animals were placed in dorsal recumbency, and the CCL of the left knee of the T group was transected through a 4 mm parapatellar stab incision, as previously described for dogs (POND and NUKI, 1973). The joints of A group were approached in a similar manner, but the CCL was left intact. They were allowed to move freely for 2 hours a day in a 100 m² fenced area with no forced exercise.

Imaging techniques. On days 0, 30, 90 and 180 post-surgery, radiography and MR imaging were performed under general anesthesia.

Radiography. The animals were positioned in lateral recumbency for medio-lateral projections and then in dorsal recumbency to obtain antero-posterior radiographs. Image analysis consisted of evaluation of four diagnostic parameters that were subchondral sclerosis, osteophytes, and subchondral cysts and overall OA assessment (GUPTA et al., 2004). An overall OA grade was assigned to each case by giving the highest grade diagnosed in other criteria, which was considered as the most diagnostic radiographic sign. Joint space narrowing was excluded from the studied criteria, since weight bearing radiography was not possible in rabbits. The severity of osteoarthritic changes of the knee was graded from 0 = normal; 1 = mild OA; 2 = moderate OA and 3 = severe OA. Subchondral sclerosis was noted as 0 = absent; 1 = mild, or localized eburnation; 2 = moderate increase in density and 3 = severe, widespread sclerosis (BUCKLAND-WRIGHT, 1999). Osteophytes were graded as 0 = absent; 1 = small beaklike osteophyte; 2 = intermediate-size osteophyte, between those of grades 1 and 3 and 3 = proliferative or mushroomlike osteophyte (KINDYNIS et al., 1990). Subchondral cysts were evaluated as 0 = absent; 1 = one to two small cysts; 2 = single large or multiple small cysts; or 3 = many large cysts (GUPTA et al., 2004). In the case of non-uniform involvement of a single compartment, the most severe degree of changes was noted for grading.

MR Imaging. The rabbits were positioned in dorsal recumbency with the hind limbs extended. A 1.5-T scanner (Philips Interna Gyroscan: Philips Medical System, Netherlands) with a small extremity coil was used. Coronal and sagittal gradient echo

T2*- weighted (Repetition time (TR): 1000 msec, echo time (TE):30 msec and Flip angle (FA): 20°), proton density (TR: 1800 msec, TE: 30 msec and FA: 90°), T1-weighted (TR: 500 msec, TE: 20 msec and FA: 90°), T2-weighted (TR: 2700, TE: 110 msec and FA: 90°) and *short tau inversion recovery* (STIR) sequences (TR: 2200, TE: 70 and FA: 90) were obtained. The slice thickness was 1 mm. Spin-echo and gradient-echo images were acquired with two excitations. MRIs were interpreted by a skilled radiologist with high experience in MRI interpretation in a blind manner. Post-surgical meniscal degeneration or tears were graded following a system described for humans that was previously modified slightly for animal purposes (MARTIG et al., 2006). Joint effusions were also graded by MRI as 0 = normal; 1 = mild; 2 = moderate and 3 = severe. An overall grade of 0-3 was given to whole changes in MR images based on the meniscal degenerations, articular cartilage alterations and joint effusion (D'ANJOU et al., 2008). In the event of non-uniform involvement of a single compartment, the most severe degree of changes other than joint effusion was used for grading.

Histopathology. The rabbits underwent euthanasia by administration of sodium pentobarbital (50 mg/kg) after MRI examinations (on days 30 and 180 post-operation) and the stifle joints were examined grossly with the aid of a magnification loupe. Five normal joints were also examined (grossly and histologically) as controls. The knee joints were then sent to the pathology laboratory in 10 % buffered formalin solution. All joint parts that were noted during gross examinations were studied histologically. Coronal sections of the midportion of both medial and lateral tibial plateau and femoral condyles were sectioned, followed by decalcification and embedded in paraffin. Microscopic cuts were done using microtome into 5 µm thick sections. Sections were stained using hematoxylin and eosin (H&E) to assess the cellularity and any structural abnormality and safranin O to evaluate the proteoglycan content in cartilage ground substance (CHANG et al., 2008).

The weight-bearing area was selected as it was shown to be the zone where the earliest abnormalities can be detected pathologically and by MRI (CALVO et al., 2001; CALVO et al., 2004). Sections were evaluated by one pathologist, blinded with radiology and MRI findings, and the samples were presented in random order. Grading scores were applied to each single case according to Table 1, which is a modification of a previously described work, so it become comparable to other diagnostic techniques on a 0-3 scale (COLOMBO et al., 1983).

The meniscal changes were also graded according to the previously described scoring system (MARTIG et al., 2006), graded as 0 = normal; 1 = mucoïd degeneration; 2 = widespread mucoïd degeneration and 3 = tear. The safranin O stained sections were graded as 0: Normal (compared with control), 1: slightly reduced, 2: markedly reduced and 3: No staining. An overall OA grade through 0-3 was assigned to each single case on histopathology, using the most evident change's grade.

Table 1. Scoring system for histopathological evaluation of the tibial and femoral articular cartilage lesions.

Articular cartilage abnormalities	Scores			
	0	+1	+2	+3
Loss of superficial layer	No superficial loss	Slight	Moderate	Extensively severe
Ulceration or erosion	Not-Detectable	Detectable	Moderate	Extensively severe
Fibrillation (surface fragmentation)	Normal	Noticeable	Marked	Extensive
Fissures (“V”-shaped clefts)	Normal	1 very small to small	2 small or 1 medium	3 small, 2 medium or 1 large
Cysts	Normal	1 very small to small	2 small or 1 large	3 small or 2 large
Osteophytes/ chondrophytes	Normal	Very small to Small	Medium	Large
Loss of proteoglycan staining by Safranin O	No loss (Stained like control)	Slight loss of safranin o staining	Moderate loss of safranin O staining	Marked loss of safranin O staining
Disorganization of chondrocytes	Normal	Slight with some loss of columns	Moderate to marked loss of columns	No recognizable organization
Clones*	No clone	3-4 small or 1-2 medium	3-6 small, 3-4 medium, or 1-2 large	7 or more small, 5-6 medium, or 3-4 large
Loss of chondrocytes	No loss	Noticeable decrease in cells	Moderate decrease in cell	Marked to very extensive decrease in cells
Exposure of subchondral bone	No exposure	Focal exposure of bone	Moderate exposure of bone	Very extensive exposure of bone

* small = 2-4 cells; medium = 5-8 cells; large = 9 or more cells.

Statistical analysis. In order to compare radiographic, MRI and histopathological criteria, two independent non-parametric samples tests were used to compare the differences between groups T and A on the same days, using the Mann Whitney U test. Each specific criterion was compared on different days using the Friedman test for non-parametric data, and the LSD test was used as post-hoc, where significant differences existed. Spearman’s correlation coefficient was used for determination of the relationship between radiography, MRI and histopathology. Where correlation existed between

the methods, linear regression was drawn to determine the slope of changes between methods, using MS Excel 2007 software for windows. $P < 0.05$ was considered as the level of significance. All data were analyzed using computer software SPSS (version 11.5, Chicago, IL., USA).

Results

Radiography. There was no sign of OA in any of the joints prior to surgery. Therefore, all grades were 0 for all the studied criteria, and all the joints were normal. The statistical analysis revealed that there was no significant difference between groups T and A on days 30, 90 and 180 post-operation. The differences in subchondral sclerosis and overall OA were borderline ($P = 0.053$) on day 180 post-operation. The radiographic findings of T group showed no significant difference between different days of the study (Fig. 1).

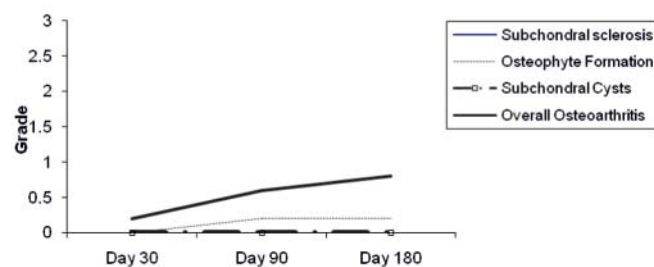


Fig. 1. The changes in radiographic findings over the six month period following OA induction.

There was no significant difference in radiographic signs, despite a mild increase, up to six months post CCL transection ($P > 0.05$). The subchondral bone sclerosis and overall osteoarthritis curves were the same and both lies on the x-axis (days).

MR imaging. The results obtained from the control joints (day 0) revealed that all ten joint menisci and ligamentous structures were normal on MRI imaging. As described in Fig. 2, the MRI findings of the T group showed significant differences in joint effusion between different days, and the differences were significant between day 30 and days 90 and 180. The differences in meniscal degeneration were also significant between days 30 and 180. The overall OA changes on different days showed significant differences between day 30 and days 90 and 180. Differences in subchondral sclerosis, osteophyte formation and subchondral cyst formation of the T group between different days were not significant.

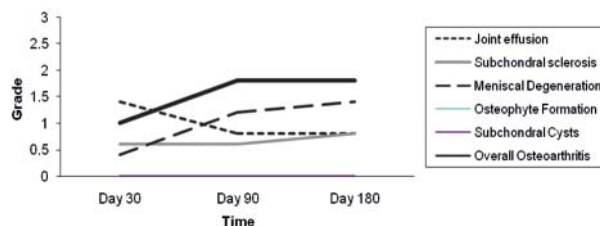


Fig. 2. The changes in MRI criteria over a six month period following CCL-transection. The subchondral bone sclerosis and overall OA were similar and showed one line on the curve and there was no subchondral cyst throughout the study, which lies on the x-axis.

Joint effusion and overall OA (which overlapped) showed a significant increase between day 30 and days 90 and 180. The increase in meniscal degeneration was significant between days 30 and 180.

Histopathology. The statistical analysis of the results of the TS and AS groups revealed that the differences in the lesions of the femoral articular cartilage were significant in loss of superficial layer, ulceration/erosion, fibrillation, disorganization of chondrocytes and clones, while the differences in fissures, cysts, osteophyte/ chondrophytes formation, loss of chondrocytes and exposure of subchondral bones were not significant. The results showed that the differences in all the above mentioned criteria measured on the tibial articular cartilage were not significant between the groups. The difference between all groups in relation to the OA grade on day 30 was significant post-operation.

The statistical analysis of the results on day 180 of femoral articular cartilage in both groups revealed that the differences in loss of superficial layer, ulceration, erosion, fibrillation, disorganization of chondrocytes, and exposure of subchondral bone were significant and the differences in fissures, osteophyte/ chondrophyte, clones, loss of chondrocytes were not significant, but all were borderline. Comparing the results of tibial articular changes between both groups, a significant difference was noticed ($P < 0.05$) considering all the studied criteria, except for fissures and cyst formation, while osteophyte/chondrophyte was borderline ($P = 0.053$). The overall OA status showed significant differences between all groups on day 180 post-operation.

When comparing femoral articular cartilage changes on days 30 and 180, most of the criteria increased by day 180. The findings of tibial articular cartilage changes between days 30 and 180 showed significant differences in superficial layer loss, ulceration/ erosion and fibrillation. Comparison of the overall OA grade in histopathology showed a significant difference between days 30 and 180 (Fig. 3).

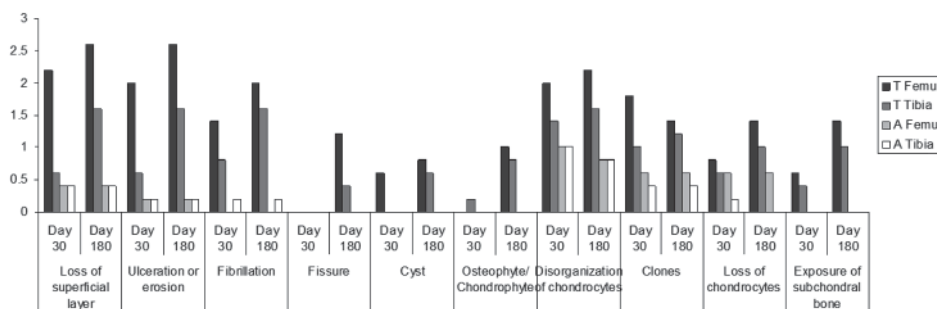


Fig. 3. Mean \pm SD of histopathological findings of the studied criteria on days 30 and 180 post-operation. Almost all of the studied criteria in femur and tibial cartilage increased between days 30 and 180.

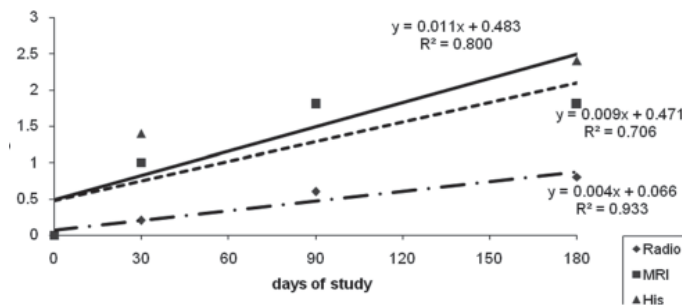


Fig. 4. Changes in different techniques of study during 180 post-operative days. Histopathological results showed the highest term of changes. MRI showed slight decrease in the observable changes as compared to histopathology, but higher when compared with radiography. The ratios of slopes of changes are His./MRI = 1.1, His./Rad. = 2.5, MRI/Rad. = 2.2.

Correlations between different techniques. The statistical analysis revealed that the correlations between different diagnostic techniques (radiography, MRI and histopathology) were positive at similar times, however, the trends of changes over the whole length of the study was significantly associated between different techniques (Fig. 4). The parameters of linear regression for histopathological changes were as slope = 0.0112, Intercept = 0.48 grade and correlation coefficient (r^2) = 0.80. For MRI changes were as, slope = 0.009, Intercept = 0.47 grade and correlation coefficient (r^2) = 0.70. For Radiographic findings, slope = 0.004, Intercept = 0.06 grade and correlation coefficient (r^2) = 0.93. The correlation coefficient (r^2) = 0.88 was recorded between radiography and

MRI with slope = 2.20 and Intercept = 0.27 (Fig. 5). Radiography and MRI results were compared with histopathology (as the gold standard), as shown in Figures 6 and 7. MRI findings were significantly associated with histopathology ($P < 0.05$), but, radiographical findings were not significantly correlated with histopathology ($P > 0.05$). Radiography and histopathology were compared to each other in Fig. 6 and MRI was compared to histopathology in Fig. 7

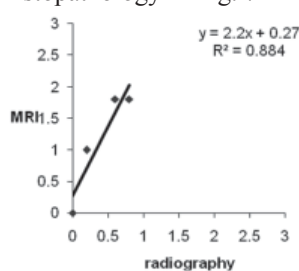


Fig. 5. The relationship between mean \pm SD of radiography and MRI results during the whole length of the study. The maximum of mean \pm SD of grades were 0.8 for radiography and 1.8 for MRI on the same scale (0-3).

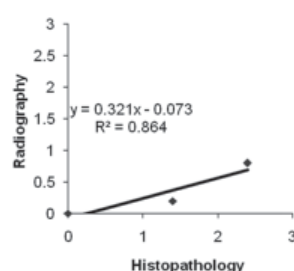


Fig. 6. Association between radiography and histopathology over 180 days of the study period. When histopathological grade reaches 0.27, radiography starts showing lesions.

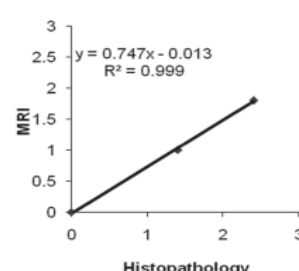


Fig. 7. The association between MRI and histopathological findings over the whole length of study. When histopathological grade reaches 0.018, MRI starts showing lesions.

Discussion

The radiographic findings of this study showed that, after the induction of OA, radiography would not significantly show OA up to six months. However, the term of changes in the findings of various criteria were different, so that we had no case of subchondral cyst in the whole 180 days of the study period, while we observed a case of subchondral sclerosis 30 days post-operation, which increased in number during the study period, and a case of osteophyte formation 90 days post-operation (data not shown). Although the changes in radiography were not different from those of the control group at the beginning of the study, the follow ups revealed that some radiographic parameters changed over time. Keeping the joints suspected for OA under close observation by radiography would show changes in the long term, even over more than six months.

Joint space narrowing was not used for grading of OA because of the non-weight bearing nature of radiography in anesthetized rabbits. In humans, measurement of joint space narrowing on radiography of weight-bearing hips and knees is most commonly used

to assess OA progression (ABADIE et al., 2004). In the present study, an overall OA grade was assigned to each case based on the other observed criteria. Giving an overall grade to radiography is practically possible by observing other diagnostic criteria. Basically, since the studied criteria are not separate from each other in general diagnosis and most of them are usually seen in one or two standard projections, the most evident parameter, on which diagnosis is usually made and considered are the radiographic findings and graded as overall OA.

Fig. 6 indicates that when histopathological grade is 0.22, the radiographical grade would be 0 (by dividing the intercept of 0.07 to 0.32 slope of curve). This shows that histological changes up to 0.22 in grade would not be detectable by radiography. MRI has been demonstrated to be a good technique to investigate OA, but most published studies evaluate morphological abnormalities, which can only be detected in well-established joint lesions (LOEUILLE et al., 1997; TURNER et al., 1994; GAHUNIA et al., 1995). However, the present study showed significant differences in some of the studied criteria (Fig. 2).

In some instances, meniscal changes were greater than those related to histopathology. This finding is well in accordance with some formerly published information. Cartilage substance remains basically intact with relatively little destruction or tissue loss in experimentally meniscectomized rabbits, and it is known that the collagen framework has to be severely damaged to find microscopic lesions in the matrix structure (CALVO et al., 2004).

The MRI curve is located between the histopathology and radiographic ones and much closer to histopathology than the radiography curve, which implies a little reduction in detection of the lesions in osteoarthritic joints when compared to histopathology, but closer to reality (histopathology) than radiography. When histological changes reach 0.018, MRI starts showing signs of involvement. This is about 0.018, which is much lower as compared to radiography (0.22), indicating the higher sensitivity of MRI to detect similar grades of lesions as compared to radiography (12 times greater than radiography).

The purpose of gross and histopathological evaluation was to define and quantify osteoarthritic changes, to independently score the abnormalities of cells, matrix, surface and calcified cartilage, and to give an overall OA score to each single studied articular cartilage, and to finally correlate each diagnostic method with histopathology as the gold standard method of diagnosis.

The alteration in articular cartilage surface was seen from the beginning of the study (day 30), and advanced to more progressed stages at the end of the study. Initially, OA progression involved focal involvement of the cartilage, usually adjacent to the surface affected most by a mechanical force. Other portions of the articular cartilage and other cartilages in the joint remain structurally intact. With progression, osteoarthritic changes were observed in contiguous portions of cartilage leading to advanced OA, in which

the entire joint surface was involved. The results of safranin O staining of the cartilages on day 30 revealed that although the grades of safranin O were higher in the T group the differences were insignificant, which implies the time consuming nature of OA, as compared to the findings of the same method on day 180.

In the present study, histopathological evaluations were performed as a baseline for comparing the other modalities of detecting changes within the osteoarthritic joints. As compared with other techniques, histopathology showed maximum changes. A linear regression curve was drawn for each technique, in order to determine the slope of changes in findings over time. As is shown in Fig. 4, the histopathology curve had the highest slope of changes over time, indicating that neither of the other techniques' findings showed what was really happening in the joint. Histopathology also showed the highest grades of changes in both days 30 and 180, implying the highest sensitivity, as compared to MRI and radiology. The ratio of the slope of histopathological changes to MRI was 1.1, which revealed the close relationship between changes in histopathology and MRI, and this ratio was 2.5 for histopathology and radiography, which shows the great difference between histology and radiography. This implies when a 1.1 grade of change occurs in histopathology, the MRI shows a 1 grade change, and in order to show 1 grade of changes in radiography, histopathology should change up to a 2.5 grade.

When a linear regression curve is drawn for the MRI and radiography relationship, the slope would be 2.2 when MRI is considered as the dependant factor (Y-axis). This shows that 1 unit (grade) change in radiography would result in a 2.2 grade change in MRI, implying that MRI is much more sensitive than radiography. The intercept of 0.27, shows that when radiography shows grade 0 change (normal radiography), 0.27 of grade of MRI changes would be expected.

Comparing both non-invasive modalities with histopathology, it reveals that the slope of linear regression curve is 0.74 for MRI and 0.32 for radiography. This shows that the slope of changes in MRI is more than twice that in radiography as histopathological changes progress one unit (grade). In other words, during the progression of OA, each single change in the histopathology grade of the affected joint would result in changes in MRI two times more than radiography.

This is the first correlative study to describe these relationships between these three diagnostic techniques in OA detection. Although our study offers new information, there were some limitations too. It was not possible to include other diagnostic techniques, which are available today, such as computed tomography or more powerful MRIs in our study. Our study was designed to assess the progression of soft tissue and osseous features of OA in vivo, using non-invasive techniques in a minimum number of rabbits, which did not allow macroscopic and microscopic measurements of changes at all time periods. In

the present study, a 1.5 T scanner was used for MRI, however, more recent studies have used more powerful magnets.

Conclusion

We concluded that a few features of OA are evident from day 30, on radiography, MRI and histopathology. Histopathology is the most sensitive method in detecting the abnormalities in osteoarthritic joints, despite some evidences that is seen in MRI before histopathology. Comparison of other diagnostic modalities with histopathology, revealed that MRI was much closer to the microscopic evaluations in detecting the lesions than radiography. Radiographic data analysis showed that only sclerosis would be detectable in early OA and osteophytes appears in radiography from day 90 on. Comparing radiography with other modalities indicated that radiography had the lowest detection power. Comparing the three methods revealed that the highest slope of changes over time was for histopathology, then for MRI and radiography. The relationship between MRI and radiography was such that when the overall OA grade was 0.27 for MRI it was 0 for radiography. When the histopathological grade was higher than 0.22, radiography started showing signs of OA, whereas the minimum level of detection was 0.018 for MRI, which was 12 times greater than radiography.

Acknowledgements

All the authors wish to thank Dr. S. Dehghani for the financial support of this study.

References

- ABADIE, E., D. ETHGEN, B. AVOUAC, G. BOUVENOT, J. BRANCO, O. BRUYERE, G. CALVO, J. P. DEVOGELAER, R. L. DREISER, G. HERRERO-BEAUMONT (2004): Recommendations for the use of new methods to assess the efficacy of disease-modifying drugs in the treatment of osteoarthritis. *Osteoarthr. Cartilage* 12, 263-268.
- ADAMS, M., M. BILLINGHAM (1982): Animal models of degenerative joint disease. *Curr. Topics Pathol.* 71, 265-297.
- BUCKLAND-WRIGHT, C. (1999): Radiographic assessment of osteoarthritis: comparison between existing methodologies. *Osteoarthr. Cartilage* 7, 430-433.
- CALVO, E., I. PALACIOS, E. DELGADO, J. RUIZ-CABELLO, P. HERNANDEZ, O. SANCHEZ-PERNAUTE, J. EGIDO, G. HERRERO-BEAUMONT (2001): High-resolution MRI detects cartilage swelling at the early stages of experimental osteoarthritis. *Osteoarthr. Cartilage* 9, 463-472.
- CALVO, E., I. PALACIOS, E. DELGADO, O. SANCHEZ-PERNAUTE, R. LARGO, J. EGIDO, G. HERRERO-BEAUMONT (2004): Histopathological correlation of cartilage swelling detected by magnetic resonance imaging in early experimental osteoarthritis. *Osteoarthr. Cartilage* 12, 878-886.

- CHANG, F., T. ISHII, T. YANAI, H. MISHIMA, H. AKAOGI, T. OGAWA, N. OCHIAI (2008): Repair of large full-thickness articular cartilage defects by transplantation of autologous uncultured bone-marrow-derived mononuclear cells. *J. Orthop. Res.* 26, 18-26.
- COLOMBO, C., M. BUTLER, E. O'BYRNE, L. HICKMAN, D. SWARTZENDRUBER, M. SELWYN, B. STEINETS (1983): A new model of osteoarthritis in rabbits. *Arthritis Rheum.* 26, 875-886.
- D'ANJOU, M. A., M. MOREAU, E. TRONCY, J. MARTEL-PELLETIER, F. ABRAM, J. P. RAYNAULD, J. P. PELLETIER (2008): Osteophytosis, subchondral bone sclerosis, joint effusion and soft tissue thickening in canine experimental stifle osteoarthritis: comparison between 1.5 T magnetic resonance imaging and computed radiography. *Vet. Surg.* 37, 166-177.
- GAHUNIA, H. K., P. BABYN, C. LEMAIRE, M. J. KESSLER, K. P. H. PRITZKER (1995): Osteoarthritis staging: comparison between magnetic resonance imaging, gross pathology and histopathology in the rhesus macaque. *Osteoarthr. Cartilage* 3, 169-180.
- GUPTA, K., J. DURYEA, B. WEISSMAN (2004): Radiographic evaluation of osteoarthritis. *Radiol. Clin. N. Am.* 42, 11-41.
- KINDYNIS, P., J. HALLER, H. KANG, D. RESNICK, D. SARTORIS, D. TRUDELL, R. TYSON (1990): Osteophytosis of the knee: anatomic, radiologic, and pathologic investigation. *Radiology* 174, 841-846.
- LOEUILLE, D., P. GONORD, C. GUINGAMP, P. GILLET, A. BLUM, M. SAUZADE, P. NETTER (1997): In vitro magnetic resonance microimaging of experimental osteoarthritis in the rat knee joint. *J. Rheumatol.* 24, 133-139.
- MARTIG, S., M. KONAR, H. SCHMOKEL, U. RYTZ, D. SPRENG, J. SCHEIDEGGER, B. HOHL, P. KIRLCHER, J. BOISCLAIR, J. LANG (2006): Low-field MRI and arthroscopy of meniscal lesions in ten dogs with experimentally induced cranial cruciate ligament insufficiency. *Vet. Radiol. Ultrasoun.* 47, 515-522.
- POND, M., G. NUKI (1973): Experimentally-induced osteoarthritis in the dog. *Brit. Med. J.* 32, 387-388.
- SINUSAS, K. (2012): Osteoarthritis: diagnosis and treatment. *Am. Fam. Physician.* 85, 49-56.
- TURNER, D. R., J. D. BANCROFT, H. C. COOK. (1994) *Manual of Histological Techniques and their Diagnostic Application.* Churchill Livingstone, London.
- WIRTH, W., J. DURYEA, M. P. HELLIO LE GRAVERAND, M. R. JOHN, M. NEVITT, R. BUCK, F. ECKSTEIN (2013): Direct comparison of fixed flexion radiography and MRI in knee osteoarthritis: responsiveness data from the osteoarthritis initiative. *Osteoarthr. Cartilage* 21, 117-125.

Received: 21 October 2012

Accepted: 17 April 2013

NIKAHVAL, B., S. N. DEGHANI, M. H. BAGHERI, S. PAKBAZ, M. MANSOURIAN, N. TANIDEH, D. MEHRABANI, M. ALIREZAEI: Povezanost između radiografskih nalaza, magnetske rezonancije i histopatoloških nalaza kod pokusne rupture prednje križne sveze u kunića. Vet. arhiv 83, 537-550, 2013.

SAŽETAK

Nakon što je u kunića pokusno izazvan osteoarthritis koljenog zgloba, trend promjena promatran je pomoću radiografije, magnetske rezonancije (MRI) i patohistoloških nalaza. Dvadeset kunića bilo je metodom slučajnog odabira podijeljeno u dvije jednake skupine od kojih je jedna promatrana tijekom kratkotrajnog (30 dana), a druga tijekom dugotrajnog (180 dana) razdoblja. U polovice životinja iz svake skupine ($n = 5$) osteoartritoza je bila uzrokovana sekcijom prednje križne sveze, a kod druge polovice primijenjena je samo artrotomija kao lažna operacija. Radiografija i magnetska rezonancija obavljene su 0-ti i 30. dan tijekom kratkotrajnog promatranja te 0-ti, 90. i 180. dan kod dugotrajnog promatranja. Histopatološke pretrage obavljene su 30. dan kod kratkotrajnog praćenja nakon što su životinje bile usmrćene, a kod dugotrajnog 180. dan. Slabljenje promjena tijekom promatranja svima trima metodama kao i stupanj promjena pokazali su se najvećima kod histopatoloških nalaza, zatim kod magnetske rezonancije te nakon toga kod radioloških snimki. Slabljenje promjena bilo je 0,01 za histopatološke nalaze, 0,009 za magnetsku rezonanciju i 0,004 za radiološke snimke. Kad se uzmu u obzir međusobni odnosi slabljenja su bila sljedeća: His./MRI = 1,1, His./Rad. = 2,5, MRI/Rad. = 2,2. Usporedba magnetske rezonancije i radiologije potvrdila je da radiologija neće pokazati znakove osteoartritisa kada je stupanj magnetske rezonance niži od 0,27. Usporedbom obje tehnike snimanja s histopatološkim nalazima utvrđeno je da radiologija neće pokazati znakove osteoartritisa kad je stupanj histopatoloških nalaza ispod 0,22. Primjenom magnetske rezonancije moguće je utvrditi znakove osteoartritisa svaki put kada je njezin stupanj veći od 0,018 u odnosu na stupanj histopatoloških nalaza.

Ključne riječi: radiografija, magnetska rezonancija, histopatologija, puknuće prednje križne sveze, kunić
