

Demineralized calf foetal growth plate effects on experimental bone healing in rabbit model

**Amin Bigham-Sadegh^{1*}, Mohammad Shadkhast²,
and Mahmoud-Reza Khalegi¹**

¹ *Department of Veterinary Surgery and Radiology, Faculty of Veterinary Medicine, Shahrekord University, Shahrekord, Iran*

² *Department of Veterinary Anatomy and Embryology, Faculty of Veterinary Medicine, Shahrekord University, Shahrekord, Iran*

BIGHAM-SADEGH, A., M. SHADKHAJ, M-R. KHALEGI: Demineralized calf foetal growth plate effects on experimental bone healing in rabbit model. Vet. arhiv 83, 525-536, 2013.

ABSTRACT

The following study was designed to evaluate demineralized calf foetal growth plate (DCFGP) effects on bone healing process. A critical size defect (10 mm) was created in the radial diaphysis of 20 rabbits and then supplied with DCFGP (treatment group, n = 10) or the defect was left empty (control group, n = 10). Radiographs of each forelimb were taken postoperatively on the 1st day and at the 2nd, 4th, 6th and 8th weeks post injury to evaluate bone formation, union and remodeling of the defect. The operated radiuses were removed on the 56th postoperative day and were evaluated for histopathological criteria. This study demonstrated that DCFGP, as a xenogenic biomaterial, could promote bone regeneration in critical size defects with a high regenerative capacity, and could be an attractive alternative for reconstruction of the major diaphyseal defects of the long bones in animal models.

Key words: demineralized calf fetal growth plate, bone healing, rabbit

Introduction

Trauma, developmental anomalies, oncologic resections, infection, and pathology can lead to defects in the bony skeleton. Reconstructive surgeons perform more than 250,000 bone graft procedures each year to restore lost tissue (MOGHADAM et al., 2004). An ideal bone graft substitute should have osteoconductive, osteoinductive and osteogenic properties. Autogenous bone graft is the gold standard among the graft materials, because

*Corresponding author:

Dr. Amin Bigham-Sadegh, Department of Veterinary Surgery and Radiology, Faculty of Veterinary Medicine, Shahrekord University, Shahrekord, Iran. P. O. Box: 115, Phone: +983 814 424 427; E-mail: dr.bigham@gmail.com

it provides all of these properties (FINKEMEIER, 2002; GREENWALD et al., 2001; PARIKH, 2002). Autogenous bone graft has always been the implant of choice for most orthopaedic procedures. However, autogenous and allogenic bone grafts have several limitations, such as donor-site infection, pain, and disease transfer (BAUER and MUSCHLER, 2000; BURCHARDT, 1983; FLEMING et al., 2000). As a result of these limitations, various bone graft substitutes, including autografts, allografts, xenografts, biosynthetic bone graft substitute polymers, ceramics and some metals that have been employed to promote bone reunion, are being investigated (FRIEDLAENDER, 1987; INOUE et al., 1997). Previously, numerous studies have compared the biopotency of xenografts such as Coralline and bovine grafts with the available autograft (KARAISSMAILILOGLU et al., 2002; KUBOKI et al., 1998). Allogenic, demineralized bone matrix (DBM) has been used for several decades in human surgery for the treatment of nonunions, osteomyelitis, and large defects resulting from benign tumor removal (JIN, 1991). The process of demineralization with hydrochloric acid destroys, but also decreases antigenic stimulation and may enhance the release of bone morphogenic protein (BMP) (RILEY et al., 1996). BMPs stimulate local undifferentiated mesenchymal cells to transform into osteoblasts (osteinduction), and the collagenous framework of the DBM particles allows for migration of tissue into the site (osteochondduction). Beyond their role in osteinduction, certain BMPs and DBM have shown promise in aiding repair of osteochondral defects (LOREDO et al., 1995; TANAKA et al., 1995). Advantages of DBM over other substitutes include inherent osteoinductive capacity (unlike tricalcium phosphate and hydroxyapatite) and availability in large amounts. The presence of growth factor β (TGF- β) in growth plate (ROSIER et al., 1998) and bone morphogenetic proteins 2 & 7 in human and rat fetal growth plates have been identified previously (ANDERSON et al., 2000). These proteins promote the chondroblastic differentiation of mesenchymal cells, followed by new bone synthesis by endochondral osteogenesis (URIST et al., 1983; URIST et al., 1979). A previous study proved that segmental bovine growth plate grafting has potential osteoinductive properties (DEHGHANI et al., 2008). More recently another study showed the ectopic osteoinductive properties of calf fetal growth plate in a rat sub-muscular model (BIGHAM et al., 2011). This study has been designed to evaluate the bone healing properties of demineralized calf fetal growth plate in a critical size bone defect model in an experimental rabbit model.

Materials and methods

Animals. Twenty male New Zealand Albino rabbits, 2 years old and weighing 2.0 ± 0.5 kg, were used in this study. The research protocol for this experiment was approved by the University Research Committee.

Preparation of demineralized bovine fetal growth plate matrix. A 6-month old bovine fetus was collected from the local slaughter house. Metacarpal bones were dissected

aseptically from the fetal calf (Holstein) and all soft tissues were removed. Radiographs were taken to determine the growth plate's margins and limitations. With an oscillating osteotom, proximal and distal growth plates were cut and retrieved under aseptic conditions. Then the retrieved growth plate was sliced. The demineralization process was performed as described by Reddi and Huggins (REDDI and HUGGINS, 1972). The harvested growth plate was cleaned of soft tissue and marrow, washed in sterile distilled water with continuous stirring, then washed three times in 95% ethanol for 15 min, rinsed in ether for 15 min, and finally air dried overnight. The cleaned and dried growth plate was then milled (Universal Mill A-20; Tekmer Co, Cincinnati, OH) to obtain 400-700 μm granules and then demineralized in 0.6 N HCl three times for 1 h (50 mL HCl per g of bone). The growth plate powder was rinsed with several changes of sterile distilled water to adjust the pH, three times in 95% ethanol and once in ether. The growth plate powder was air dried and stored in sterile plastic containers at 4 °C until being used for implantation. This entire process was performed under sterile conditions (except for the milling) and a sample was cultured to demonstrate that specimens contained no bacterial or fungal contamination.

Surgical technique. All the rabbits were anesthetized by intramuscular administration of 40 mg/kg ketamine hydrochloride (Alfasan International, Woerden, the Netherlands) and 5mg/kg xylazine (Alfasan International, Woerden, the Netherlands). In all animals the right forelimb was prepared aseptically for surgery. A 5 cm skin incision was made over the forearm craniomedially and then the radius was exposed by dissecting the surrounding muscles. A 10 mm segmental defect was then created with an electrical bone cutting saw, under normal saline flushing on the middle portion of each radius as a critical size bone defect. A segment at least twice as long as the diameter of the diaphysis is a nonunion model in rabbits (BOLANDER and GALIAN, 1983). The defects were supplied with DCFGP (treatment group, n = 10) or left empty without using any materials (control group, n = 10) and then covered by muscles suturing over the created defect. Muscle was sutured with polyglactin 910 (Vicryl®, Number 2-0, Ethicon, Edinburgh, UK) with simple continuous pattern, and the skin was sutured with nylon (Ethilon, Number 0, Ethicon, Edinburgh, UK) with a simple interrupted pattern. The injured limb was bandaged for the first week for protection from wound contamination. Antibiotic therapy was performed for three days by penicillin 40000 IU/kg, IM (Tabriz Pharmaceutical Co. Tabriz, IRAN) and gentamicin 5 mg/kg, IM (Darou Pakhsh, Pharmaceutical Co. Tehran, IRAN).

Post operative analgesia and euthanasia protocol. Tramadol (5 mg/kg, SC, Tramadol, Darou Pakhsh. Pharma. Chem. Co. Tehran, Iran) was administered every 12 hours after surgery for 24 hours and as needed thereafter, to control pain and discomfort (FLECKNELL, 2009).

Eight weeks after the operation the rabbits should be euthanized for histopathological evaluation. For euthanasia an overdose of ketamin hydrochloride 100 mg/kg was used. This agent was injected intracardially and produced sudden smooth death (RIGALLI and ELINA DI LORETO, 2009).

Post operative evaluation. Radiological evaluation. Radiographs of each forelimb were taken postoperatively on the 1st day and at the 2nd, 4th, 6th and 8th weeks to evaluate bone formation, union and remodeling of the defect. Results were scored using a modified Lane and Sandhu scoring system (LANE and SANDHU, 1987) (Table 1).

Table 1. Modified Lane and Sandhu radiological scoring system

Bone formation	
No evidence of bone formation	0
Bone formation occupying 25% of defect	1
Bone formation occupying 50% of defect	2
Bone formation occupying 75% of defect	3
Bone formation occupying 100% of defect	4
Union (proximal and distal evaluated separately)	
Non union	0
Possible union	1
Radiographic union	2
Total point possible per category	
Bone formation	4
Proximal union	2
Distal union	2
Remodeling	2
Maximum Score	10

Histopathological evaluation. The histopathological evaluation was carried out on ten rabbits of each group. The right forelimb of each animal was harvested and dissected free of soft tissues. Sagittal sections, containing the defect, were cut with a slow speed saw. Each slice was then fixed in 10% neutral buffered formalin. The formalin-fixed bone samples were decalcified in 15% buffered formic acid solution and processed for routine histological examination. Two sections, 5 µm in thickness, were cut from the centers of each specimen and were stained with hematoxylin and eosin. The sections were blindly evaluated and scored by two pathologists according to the Lane and Sandhu modified scoring system by Hieple et al 1987 (HEIPLE et al., 1987) (Table 2).

Table 2. Lane and Sandhu histopathological scoring system modified by Heiple et al

Union (proximal and distal evaluated separately)	
No evidence of union	0
Fibrous union	1
Osteochondral union	2
Bone union	3
Complete organization of shaft	4
Cancellous bone	
No osseous cellular activity	0
Early apposition of new bone	1
Active apposition of new bone	2
Reorganizing cancellous bone	3
Completely reorganization cancellous bone	4
Cortical bone	
Non	0
Early appearance	1
Formation under way	2
Mostly reorganized	3
Completely formed	4
Marrow	
None is resected area	0
Beginning to appear	1
Present in more than half of the defect	2
Complete colonization by red marrow	3
Mature fatty marrow	4
Total points possible per category	
Proximal union	4
Distal union	4
Cancellous bone	4
Cortex	4
Marrow	4
Maximum score	20

Statistical analysis. The radiological and histopathological data were compared by pair wise group comparisons using the Mann-Whitney U test. When *P-values* were

found to be less than 0.05 they considered statistically significant (SPSS version 17 for windows, SPSS Inc, Chicago, USA).

Results

There was no intraoperative or postoperative death during the study. None of the rabbits sustained a fracture of the ulna.

Radiographic findings. On the 14th, 28th, 42nd and 56th postoperative days statistically significant differences ($P < 0.05$) were observed between the DCFGF group and control group, whereby the DCFGF group was superior to the control group in terms of radiological evaluation (Fig. 1, Table 3).

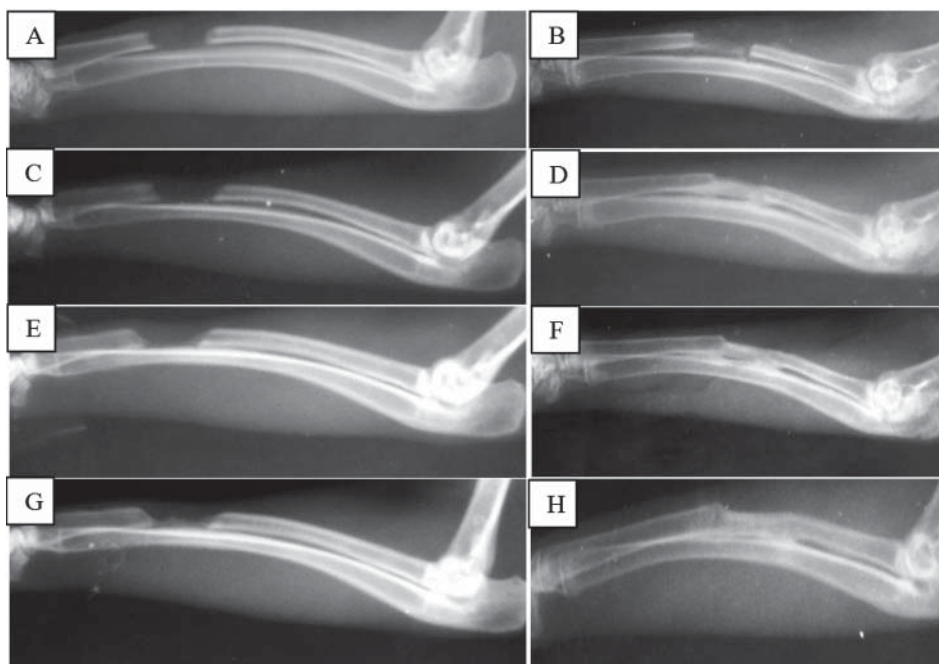


Fig. 1. The 14th postoperative day (A, control and B, DCFGF group); 28th postoperative day (C, control and D, DCFGF group); 42nd postoperative day (E, control and F, DCFGF group); 56th postoperative day (G, control and H, DCFGF group). Note to faster progress of bone healing in DCFGF group in comparison with control group.

Table 3. Radiograph findings for bone defect healing (sum of radiological scores) at various post-operative intervals

Postoperative days	Med (min-max)		P ^a
	DCFGF (n = 10)	Control (n = 10)	
14	2 (2-4) ^b	1 (0-1)	0.000
28	6 (3-8) ^b	2 (1-2)	0.000
42	7 (5-9) ^b	3 (3-5)	0.000
56	9 (8-10) ^b	5 (4-6)	0.000

Significant P-values are presented in bold face. ^a Mann-Whitney U test P values. ^b compared with control group on 14th, 28th, 42nd and 56th post-injury day that DCFGF group significantly was superior to control group in radiological bone formation criteria

Note that a P-value listed as 0.000 does not mean that the actual p-value is zero, instead it indicates that the P-value is less than 0.0005 (0.0004 being approximately the largest number which rounds to 0.000). Values less than 0.0005 are indeed very close to zero in many practical applications, but this is conceptually distinct from an actual value of zero.

Histopathological findings. There were significant differences between the DCFGF and control group on histopathological evaluation where the histopathological findings show superior bone union, cancellous bone, cortical bone and marrow formation in the DCFGF group in comparison to the control group. No significant inflammatory response was evident in the lesions of the animals of either group at 8 weeks post injury, although it may have been present earlier (Fig. 2, Table 4).

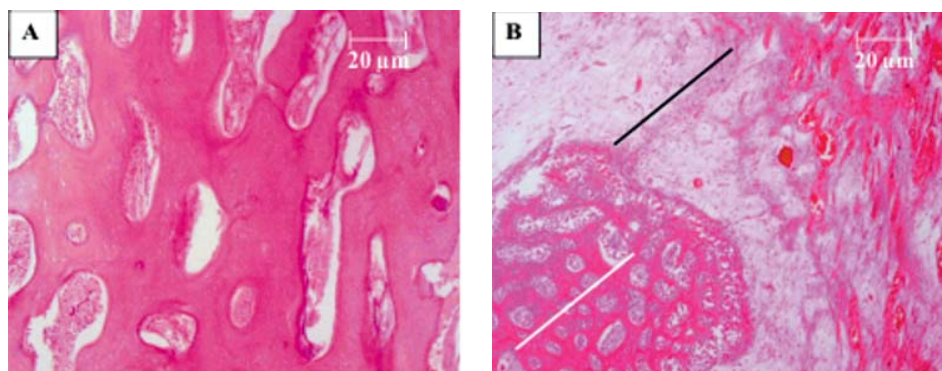


Fig. 2. At the end of 8 weeks post-surgery, histological examination demonstrated the regenerated bone with typical structure of trabecular bone in the defect at the experimental side of DCFGF group(A) (H&E, ×20). In contrast, weak osteogenesis activity could be found with at least woven bone formation (white line area), fibrous and fibrocartilage tissues (black line area) at the control defect (B) (H&E, ×10)

Table 4. Histopathological findings according to the Heiple scoring system

Histopathological criteria	Med (min-max)		P ^a
	DCFGP (n = 10)	Control (n = 10)	
Union	3 (2-4) ^b	2 (1-3)	0.001
Cancellous bone	2 (2-3) ^b	2 (1-2)	0.006
Cortical bone	3 (3-4) ^b	1 (0-1)	0.000
Marrow	3 (2-4) ^b	1 (1-2)	0.000

Significant P-values are presented in bold face. ^a Mann-Whitney U test P values; ^b compared with control group on union, cancellous bone, cortical bone and marrow formation that DCFGF group significantly was superior to control group in histopathological evaluation criteria.

Note that a P-value listed as 0.000 does not mean that the actual P-value is zero, instead it indicates that the P-value is less than 0.0005 (0.0004 being approximately the largest number which rounds to 0.000). Values less than 0.0005 are indeed very close to zero in many practical applications, but this is conceptually distinct from an actual value of zero.

Discussion

To the authors' knowledge this is one of the first studies, which presents new data on the bone regenerative properties of demineralized calf fetal growth plates on bone healing in a rabbit model. Such a defect in the radius has previously been reported to be suitable in the rabbit model because there is no need for internal or external fixation, which influences the healing process (AN and FRIEDMAN, 1999). The segmental defect was created on the middle portion of the radius, as long as 10 mm, to prevent spontaneous and rapid healing (BOLANDER and GALIAN, 1983).

In this study, the DCFGF group demonstrated superior osteogenic potential in the radial bone defect healing in the rabbit model. The radiological and histological findings of the present study indicate superior bone healing capability in the DCFGF group, by the end of 8 weeks post-surgery, in comparison to the control group.

Recently a study indicated that satisfactory ectopic bone formation occurred in a submuscular rat model, with a xenogeneic demineralized bovine fetal growth plate and complications were not identified (BIGHAM et al., 2011). Also, during two previous studies a segmental calf fetal growth plate was grafted into a radial bone defect and a positive bone healing process was observed by investigators (DEGHANI et al., 2008; BIGHAM et al., 2009).

The presence of transforming growth factor- β (TGF- β) in growth plates (ROSIER et al., 1998) and bone morphogenetic proteins (BMPs 2 & 7) have been identified in human and rat fetal growth plates (ANDERSON et al., 2000). These proteins promote the

chondroblastic differentiation of mesenchymal cells, followed by new bone synthesis by endochondral osteogenesis (URIST et al., 1979).

The primary osteoinductive component of the demineralized bone matrix (DBM) is a series of low-molecular-weight glycoproteins that includes the bone morphogenetic proteins (BMPs). The decalcification of cortical bone exposes these osteoinductive growth factors buried within the mineralized matrix, thereby enhancing the bone formation process. These proteins promote the chondroblastic differentiation of mesenchymal cells, followed with new bone synthesis by endochondral osteogenesis (URIST et al., 1979; OSHIN and STEWART, 2007). We proposed that in our study calf fetal growth plate demineralization leads to exposing the TGF- β and BMPs 2 & 7 into the injured site, and therefore bone healing process in DCFGP group was superior in comparison to control group.

In the present study, DCFGP did not elicit any inflammatory reaction in the grafted site. It has been reported that the demineralization process destroys the antigenic materials in bone, making DBM less immunogenic, and it does not induce immunological reaction by the host (BAUER and MUSCHLER, 2000), therefore we did not observe any inflammatory reaction throughout the histopathological evaluation.

Based on the radiological and histopathological findings of the present study, healing of the defects of the animals of the control group was not very efficient and the defect area was filled with fibrous connective tissues and rarely with cartilage instead of osseous tissue. Barnes et al. indicated that the chondrocytes derived from the mesenchymal progenitors proliferate and synthesize a cartilaginous matrix, until all the fibrous granulation tissue is replaced by cartilage. Where cartilage production is deficient, fibroblasts replace the region with generalized fibrous tissue. Discrete cartilaginous regions progressively grow and merge to produce a central fibrocartilaginous plug between the fractured fragments that splints the fracture (BARNES et al., 1999).

It was understood that the perfect bone healing process could be related to BMPs releasing from demineralized grafted bovine fetal growth plates, however we suggest for further studies in this subject, at least one growth and differentiated factor should be measured to help understand some of the real mechanisms of action of this product. Finally, we advise comparison of this new biomaterial with another existence commercial osteoinductive biomaterial, to determine of potential efficacy of DCFGP in contrast to other materials.

Conclusions

The results of this study indicate that satisfactory bone defect healing occurred in experimental radial bone defect healing in a rabbit model with a xenogenic demineralized bovine fetal growth plate, and complications were not identified. Further studies are

needed to evaluate the long-term effects of this new biomaterial on bone healing, to document the use of this graft substitute in various clinical situations. It is cost-effective and readily available from tissue banks.

Acknowledgements

The authors would like to thank the authorities of the Veterinary School, Shahrekord University for their financial support and cooperation.

Conflict of interest

All authors declare that there is no conflict of interests

References

- AN, Y. H., R. J. FRIEDMAN (1999): Animal models in orthopedic research. (1st ed). Florida, CRC Press Inc., Boca Raton.
- ANDERSON, H. C., P. T. HODGES, X. M. AGUILERA, L. MISSANA, P. E. MOYLAN (2000): Bone morphogenetic protein (BMP) localization in developing human and rat growth plate, metaphysis, epiphysis, and articular cartilage. *J. Histochem. Cytochem.* 48, 1493-502.
- BARNES, G. L., P. J. KOSTENUK, L. C. GERSTENFELD, T. A. EINHORN (1999): Growth factor regulation of fracture repair. *J. Bone Miner. Res.* 14, 1805-1815.
- BAUER, T. W., G. F. MUSCHLER (2000): Bone graft materials: An overview of basic science. *Clin. Orthop. Relat. Res.* 371, 10-27.
- BIGHAM, A. S., S. N. DEGHANI, Z. SHAFIEI, S. TORABI NEZHAD (2009): Experimental bone defect healing with xenogenic demineralized bone matrix and bovine fetal growth plate as a new xenograft: radiological, histopathological and biomechanical evaluation. *Cell Tissue Bank* 10, 33-41.
- BIGHAM, A. S., M. SHADKHAHAST, A. BIGHAM SADEGH, Z. SHAFIEI, A. LAKZIAN, M. R. KHALEGI (2011): Evaluation of osteoinduction properties of the demineralized bovine foetal growth plate powder as a new xenogenic biomaterial in rat. *Res. Vet. Sci.* 91, 306-310.
- BOLANDER, M. E., G. GALIAN (1983): The use of demineralize bone matrix in the repair of segmental defect. *J. Bone Joint Surg. Am.* 68A, 1264-1274.
- BURCHARDT, H. (1983): The biology of bone graft repair. *Clin. Orthop. Relat. Res.* 174, 28.
- DEGHANI, S. N., A. S. BIGHAM, S. TORABI NEZHAD, Z. SHAFIEI (2008): Effect of bovine fetal growth plate as a new xenograft in experimental bone defect healing: radiological, histopathological and biomechanical evaluation. *Cell Tissue Bank* 9, 91-99.
- FINKEMEIER, C. G. (2002): Bone-grafting and bone-graft substitutes. *J. Bone Joint Surg. Am.* 84, 454.
- FLECKNELL, P. (2009): Laboratory animal anaesthesia. UK, Elsevier.

- FLEMING, J. E., C. N. CORNELL, G. F. MUSCHLER (2000): Bone cells and matrices in orthopedic tissue engineering. *Orthop. Clin. North Am.* 31, 357-374.
- FRIEDLAENDER, G. E. (1987): Bone grafts: the basic science rationale for clinical applications. *J. Bone Joint Surg. Am.* 69, 786-790.
- GREENWALD, A. S., S. D. BODEN, V. M. GOLDBERG, Y. KHAN, C. T. LAURENCIN, R. N. ROSIER (2001): Bone-graft substitutes: facts, fictions, and applications. *J. Bone Joint Surg. Am.* 83, S98.
- HEIPLE, K. G., V. M. GOLDBERG, A. E. POWELL, G. D. BOS, J. M. ZIKA (1987): Biology of cancellous bone grafts. *Orthop. Clin. North Am.* 18, 179-185.
- INOUE, K., H. OHGUSHI, T. YOSHIKAWA, M. OKUMURA, T. SEMPUKU, S. TAMAI, Y. DOHI (1997): The effect of aging on bone formation in porous hydroxyapatite: Biochemical and histologic analysis. *J. Bone Miner. Res.* 12, 989-994.
- JIN, D. D. (1991): Bone matrix gelatin. Clinical application in 38 cases. *Chung-Hua Wai Ko Tsa Chih* 29, 312-314.
- KARAISSMAILIOGLU, T. N., Y. TOMAK, A. ANDAC, E. ERGUN (2002): Comparison of autograft, coralline graft and xenograft in promoting posterior spinal fusion. *Acta Orthop. Traumatol. Turc.* 36, 147-154.
- KUBOKI, Y., H. TAKITA, D. KOBAYASHI, E. TSURUGA, M. INOUE, M. MURATA, N. NAGAI, Y. DOHI, H. OHGUSHI (1998): BMP-induced osteogenesis on the surface of hydroxyapatite with geometrically feasible and non feasible structures: Topology of osteogenesis. *J. Biomed. Mater. Res.*, 39, 190-199.
- LANE, J. M., H. S. SANDHU (1987): Current approach to experimental bone grafting. *Orthop. Clin. North Am.* 18, 213-225.
- LOREDO, G. A., M. H. MACDONALD, H. P. BENTON (1995): Regulation of glycosaminoglycan metabolism by bone morphogenetic protein-2 in equine cartilage explant cultures. *Am. J. Vet. Res.* 57, 554-559.
- MOGHADAM, H. G., G. K. B. SANDOR, H. H. I. HOLMES, C. M. L. CLOKIE (2004): Histomorphometric evaluation of bone regeneration using allogeneic and alloplastic bone substitutes. *J Maxillofac Oral Surg.* 62, 202-213.
- OSHIN, A. O., M. C. STEWART (2007): The role of bone morphogenetic proteins in articular cartilage development, homeostasis and repair. *Vet. Comp. Orthop. Traumatol.* 20, 151.
- PARIKH, S. N. (2002): Bone graft substitutes in modern orthopedics. *Orthopedics* 25, 1301-1309.
- REDDI, A. H., C. HUGGINS (1972): Biochemical sequences in the transformation of normal fibroblasts in adolescent rats. *Proceedings of the National Academy of Sciences of the United States of America*, 1601-1605.
- RIGALLI, A., V. ELINA DI LORETO (2009): *Experimental surgical models in the laboratory rat*. New York, Taylor & Francis Group.
- RILEY, E. H., J. M. LANE, M. R. URIST, K. M. LYONS, J. R. LIEBERMAN (1996): Bone Morphogenetic Protein-2: Biology and Applications. *Clin. Orthop. Relat. Res.* 324, 39-46.

A. Bigham-Sadegh et al.: Demineralized fetal growth plate effects on bone healing

- ROSIER, R. N., R. J. O'KEEFE, D. G. HICKS (1998): The potential role of transforming growth factor beta in fracture healing. *Clin. Orthop. Relat. Res.* 355, S294-S300.
- TANAKA, T., K. FUJII, M. OHTA, S. SOSHI, A. KITAMURA, K. MUROTA (1995): Use of a guanidine extract of demineralized bone in the treatment of osteochondral defects of articular cartilage. *J. Orthop. Res.* 13, 464-469.
- URIST, M. F., K. SATO, A. G. BROWNELL (1983): Human bone morphogenetic protein. *Proceedings of the Society for Experimental Biology and Medicine. Society for Experimental Biology and Medicine (New York, N.Y.)*, 194-199.
- URIST, M. R., A. J. MIKULSKI, A. LIETZ (1979): Solubilized and insolubilized bone morphogenetic protein. *Proceedings of the National Academy of Sciences of the United States of America* 76, 1928-1932.

Received: 28 September 2012

Accepted: 17 April 2013

BIGHAM-SADEGH, A., M. SHADKHAST, M-R. KHALEGI: Učinci demineralizirane pločice rasta kostiju telećeg ploda na cijeljenje kostiju u kunića kao pokusnom modelu. *Vet. arhiv* 83, 525-536, 2013.

SAŽETAK

Istraživanje je poduzeto s ciljem da se procijene učinci demineralizirane pločice rasta kostiju telećeg ploda na proces cijeljenja kostiju. Kritični defekt (10 mm) učinjen je na dijafizi palčane kosti 20 kunića i tada nadomješten demineraliziranom pločicom rasta telećeg ploda (pokusna skupina n = 10) ili je defekt ostao nenadomješten (kontrolna skupina n = 10). Radiografske snimke svih prednjih nogu učinjene su 1. dana te 2., 4., 6., i 8. tjedna nakon operacije da bi se procijenila obnova kostiju, spajanje defekata i oblikovanje kostiju. Operirane palčane kosti bile su uzete 56. dana nakon operacije i procijenjene na osnovi histopatoloških kriterija. Istraživanje je pokazalo da demineralizirane pločice rasta kao ksenogeni biološki materijal mogu potaknuti regeneraciju kostiju u kritičnim defektima s visokom regenerativnom sposobnošću i mogu biti dobra zamjena za rekonstrukciju većih dijafiznih defekata dugih kostiju na životinjskom modelu.

Ključne riječi: demineralizirana pločica rasta, cijeljenje kostiju, kunić
