

## **Bovine tuberculosis in Bosnia and Herzegovina caused by *Mycobacterium caprae***

**Hajrudin Beširović<sup>1\*</sup>, Amer Alić<sup>1</sup>, Silvio Špičić<sup>2</sup>, Željko Cvetnić<sup>2</sup>,  
Senad Prašović<sup>1</sup>, and Lejla Velić<sup>3</sup>**

<sup>1</sup>University of Sarajevo, Veterinary Faculty, Department of Pathology, Sarajevo, Bosnia and Herzegovina

<sup>2</sup>Croatian Veterinary Institute, Department of Bacteriology and Parasitology, Laboratory for Bacterial Zoonosis and Molecular Diagnosis of Bacterial Diseases, Zagreb, Croatia

<sup>3</sup>University of Sarajevo, Veterinary Faculty, Department of Microbiology with Immunology and Infectious Diseases, Sarajevo, Bosnia and Herzegovina

---

**BEŠIROVIĆ, H., A. ALIĆ, S. ŠPIČIĆ, Ž. CVETNIĆ, S. PRAŠOVIĆ, L. VELIĆ:  
Bovine tuberculosis in Bosnia and Herzegovina caused by *Mycobacterium caprae*.  
Vet. arhiv 82, 341-349, 2012.**

### **ABSTRACT**

Bovine tuberculosis is a chronic disease of a zoonotic character that occurs in cattle and a wide range of domestic and wild animals. In this paper, bovine tuberculosis caused by *M. caprae* in six small household herds in Bosnia and Herzegovina was described. For the identification of the disease and determination of the causative agent comparative tuberculin skin test (TST), pathomorphology, microbiology and molecular methods were applied. Twenty-eight cows from five households from the Livno region (25/28 animals) and one household from the Vitez region (3/28 animals) were euthanized after being found positive by the comparative TST test. Eleven animals from five households from the Livno region (9/11 animals) and one household from the Vitez region (2/11 animals) were subject to field necropsy, and lesions consistent with tuberculosis were observed on the lymph nodes of the thoracic cavity and lungs in all carcasses. Histopathologic examination by hematoxylin and eosin staining confirmed the presence of specific granulomatous lesions, while Ziehl-Neelsen staining demonstrated the presence of very few acid fast bacteria. Mediastinal lymph nodes from seven necropsied animals (two animals from the Vitez region and five animals from five flocks from the Livno region) were submitted for bacteriology. Acid fast bacteria from five out of the seven submitted samples from one animal from the Vitez region and four animals from four households from the Livno region were isolated. All isolates were identified as *M. caprae*. By MIRU typing we found two different *M. caprae* genotypes, unique to Bosnia and Herzegovina. Our findings represent the first evidence of bovine tuberculosis caused by *M. caprae* in Bosnia and Herzegovina.

**Key words:** cattle, tuberculosis, *Mycobacterium caprae*, Bosnia and Herzegovina, epidemiology

---

\*Corresponding author:

Hajrudin Beširović DVM, MVSc, PhD, University of Sarajevo, Veterinary Faculty, Department of Pathology, Zmaja od Bosne 90, 71000 Sarajevo, Bosnia and Herzegovina, Phone: +387 33 65 59 22 ext. 231; Fax: +387 33 61 09 08; E-mail: hajrudin.besirovic@vfs.unsa.ba

ISSN 0372-5480  
Printed in Croatia

## Introduction

Bovine tuberculosis is a chronic disease of a zoonotic character that occurs mainly in cattle and also in a wide range of domestic and wild animals. It is caused by *Mycobacterium bovis* and other members of the *M. tuberculosis* complex (MTC), which includes *M. tuberculosis*, *M. caprae*, *M. microtii*, *M. canettii*, *M. africanum*, *M. pinnipedii*. *M. caprae* is a novel species within the *M. tuberculosis* complex (ARANAZ et al., 2003) and is by far the most dominant species in cattle in central European countries (ERLER et al., 2004; KUBICA et al., 2003; PAVLIK et al., 2002a; PRODINGER et al., 2005).

Little is known about cattle tuberculosis in Bosnia and Herzegovina. It was considered to be eradicated from the former Yugoslav Federation in 1973, with sporadic outbreaks recorded until 1990. No information is present from the war period (1992-1996), and only two outbreaks were documented between 1996 and 1999 (FEJZIĆ et al., 2000, PAVLIK et al., 2002a).

The aim of this paper was to describe bovine tuberculosis caused by *M. caprae* in six small household herds in the municipalities of Vitez in Central, and Livno in Southwestern Bosnia and Herzegovina. For identification of the disease and its causative agent, tuberculin skin tests, and histopathology, microbiology and molecular methods were applied.

## Materials and methods

Twenty-eight cows from six small dairy households in the municipalities of Vitez (one farm) and Livno (five farms) were euthanized with T-61 after having a positive tuberculin skin test (TST) in mandatory annual screening for tuberculosis, according to veterinary legislation in the Federation of Bosnia and Herzegovina. Most of the cows from the Livno municipality were of the Grey cattle breed and were kept on different farms in close proximity. These cows were on pasture together and also with cows from other uninfected farms. Cows from the Vitez municipality were also of the Grey cattle breed. The distance between these two municipalities is about 130 kilometers.

The monotest for TST was performed on the right side of the body, where the hair was clipped and skin fold measured before the 0.1 mL (2000 IU) of *M. bovis* PPD (Pliva, Zagreb, Croatia) was injected intracutaneously. The reaction was evaluated 72 hours later by comparing the thickness of the skin fold values. Thicknesses increased by <2 mm, 2-4 mm and >4 mm were interpreted as negative, suspicious and positive, respectively. Two months later, the animals with suspicious and positive reactions were subjected to comparative *M. bovis* and *M. avium* PPD testing. The same procedure was followed but 0.1 mL (2000 IU) of *M. bovis* PPD (Pliva, Zagreb, Croatia) was injected on the right side, 10 to 15 cm lower than the monotest, with 0.1 mL (2000 IU) of *M. avium* PPD (Genera-Veterina, Zagreb, Croatia) on the left side of the neck. The reaction was evaluated and

scored 72 hours later. The test was considered negative if the reaction to bovine PPD was equal or smaller than to avian PPD. If the fold was 1-4 mm, the reaction considered suspicious and if it was >4 mm, it was considered positive.

The carcasses of 11 of the 28 animals were subjected to field necropsy, while for 17 animals necropsy was not allowed by the authorities. The carcasses and viscera were examined and samples were collected for histopathology and bacteriology. Several slides for cytology were made by imprinting and scraping the material from observed lesions on the lymph nodes and lungs from each animal. These slides were stained by Diff-Quick and Ziehl-Neelsen.

Samples for histopathology were fixed in 10% buffered neutral formalin, routinely processed and embedded in paraffin blocks. Multiple semithin sections (4-5 microns) were cut, stained with hematoxylin and eosin and Ziehl-Neelsen for microscopic evaluation.

Mediastinal lymph nodes from seven necropsied animals (two animals from the Vitez region and five animals from five flocks from the Livno region) submitted for bacteriology were inoculated on six growth plates (two Löwenstein-Jensen, two Löwenstein-Jensen with glycerol and two Stonebrick). The cultured isolates from 5 samples (one isolate from Vitez region and 4 isolates from 4 flocks from Livno region) were identified as *Mycobacterium* spp. using TB1 (5'-GAG-ATC-GAG-CTG-GAG-GAT-CC-3') and TB2 (5'-AGC-TGC-AGC-CCA-AAG-GTG-TT-3') primers (Invitrogen Life Sciences, Invitrogen Ltd, Paisley, Scotland) (HANCE et al., 1989).

Clinically important mycobacteria: *M. avium* ssp., *M. chelonae*, *M. abscessus*, *M. fortuitum*, *M. gordonae*, *M. intracellulare*, *M. scrofulaceum*, *M. interjectum*, *M. kansasii*, *M. malmoense*, *M. peregrinum*, *M. marinum*/*M. ulcerans*, *M. tuberculosis* complex and *M. xenopi* were detected using "GenoType Mycobacterium CM" (Hain Lifescience, Germany), a test based on DNA-STRIP technology. Later, species in the *M. tuberculosis* complex were identified using "GenoType MTBC" test (Hain Lifescience, Germany) as previously described (CVETNIĆ et al., 2007).

The variable number tandem repeat (VNTR) profile analysis of twelve mycobacterial interspersed repetitive unit (MIRU) loci of isolated mycobacteria was performed as previously described (SUPPLY et al., 2000 and 2001; CVETNIĆ et al., 2007). Amplified PCR fragments were analyzed by agarose gel electrophoresis using 3% agarose gel and visualized using GelDoc 2000 (BioRad, Munich, Germany). The number of MIRU copies per locus was calculated on the basis of conventions (SUPPLY et al., 2001).

## Results

All twenty-eight TST positive animals were healthy and in good physical condition. No clinical signs of chronic illness were noted. No reactions were observed on auscultation and percussion of the chest cavity in any animal.

At necropsy of eleven animals, lesions consistent with tuberculosis were observed on the lymph nodes and lungs in all carcasses. The most striking pathomorphologic findings were very enlarged mediastinal (Fig. 1.) and bronchial lymph nodes. Lymph nodes were firm with a smooth surface and a few nodular elevations up to 1 cm in diameter. On cutting, the nodes were gritty due to mineralization, with diffuse loss and replacement of parenchyma with gray to yellow caseous material, intersected with thick bundles of grey to white fibrous connective tissue. In the lung parenchyma there were multiple caseous nodules ranging from small solitary to botryoid forms, which contained creamy to caseous, white to yellow material. In one animal about 50% of the lung parenchyma had been replaced by multiple, various size echinococcal cysts. In another, there were multifocal various sized (up to 20 cm) abscesses, filled with thick, creamy, yellow to grey odorous material (pus) in the pericardium and extending on to the left muscular part of the diaphragm. No tuberculous lesions were observed on other organs.

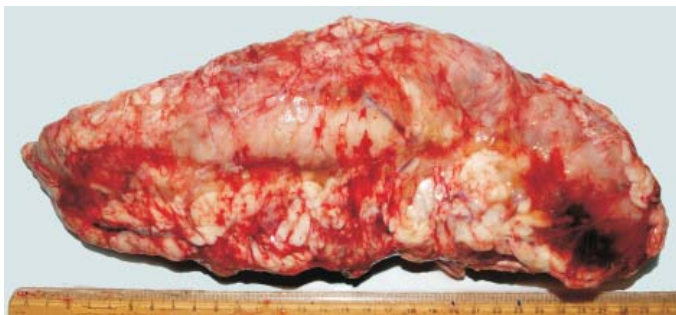

Fig. 1. The extremely enlarged mediastinal lymph node of a cow infected with *M. caprae*

Examination of the Diff-Quick stained slides revealed multiple large multinuclear cells consistent with Langhans type giant cells and many small lymphocytes accompanied by multiple macrophages with vacuolated cytoplasm.

Histologically, multifocal granulomatous lesions encircled by a thin fibrous capsule were present in the lymph nodes and lung lesions. The center of the granuloma consisted of copious eosinophilic, granular necrotic debris and degenerate leukocytes (caseous necrosis) accompanied by many dark blue to black foci of mineralization (dystrophic calcification). By the lining of the necrotic detritus there were many multinuclear giant cells, of both Langhans and foreign body type. Towards the fibrous capsule there was granulation tissue, infiltrated with many layers of leukocytes, admixed with macrophages and giant cells. Ziehl-Neelsen staining revealed a small number of single or groups of rod shaped, red stained bacteria, mostly present in the cytoplasm of giant cells (Fig. 2) with only a few bacteria visible in the necrotic debris.

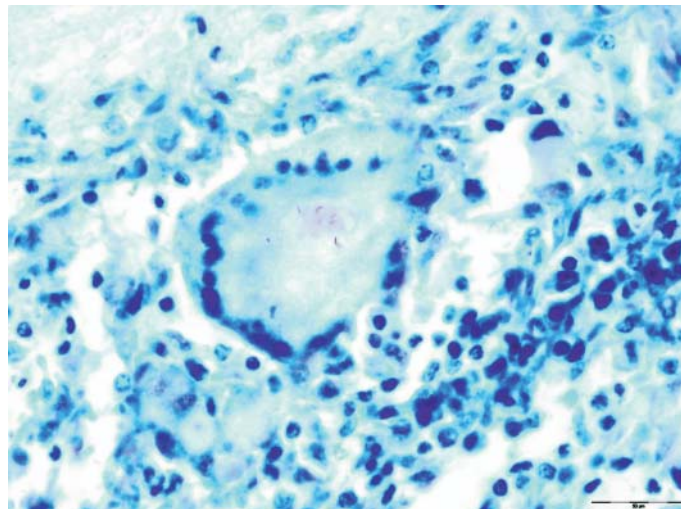


Fig. 2. The lung of a cow infected with *M. caprae*. A few straight and curved, bright red stained rods (*M. caprae*) in the cytoplasm of the giant multinucleate cell. Ziehl-Neelsen stain; scale bar = 50  $\mu$ m;  $\times$ 1000.

The acid fast bacteria isolated from 5 of the 7 submitted samples of cattle lymph nodes were identified as *M. caprae*. MIRU-VNTR profile of the isolated mycobacteria with twelve loci revealed the following code in one isolate from the Vitez region: 2 (2), 4 (3), 10 (4), 16 (4), 20 (2), 23 (4), 24 (2), 26 (6), 27 (3), 31 (5), 39 (2), 40 (2) and in 4 isolates from 4 flocks from the Livno region 2 (2), 4 (3), 10 (5), 16 (4), 20 (2), 23 (4), 24 (2), 26 (5), 27 (3), 31 (4), 39 (2), 40 (2).

### Discussion

Most countries in the European Union (EU) have achieved bovine tuberculosis free status, while in some EU countries and non EU members tuberculosis remains non eradicated, but with ongoing eradication programs (VARELLO et al., 2008). In developing countries tuberculosis still remains a public health concern. Most central European countries have a prevalence of reactor animals between 0.003% and 0.005%, including our neighbor, Croatia (CVETNIĆ et al., 2006 and 2007). In Bosnia and Herzegovina, the epidemiological status of bovine tuberculosis is still unknown in animals and humans. The number of human cases positive for tuberculosis is estimated at about 1800 nowadays, with no data about the percentage of cases of bovine tuberculosis. According to the WHO, the estimated prevalence of human tuberculosis in Bosnia and Herzegovina in 2007 was 2200 cases, and for 2015 the incidence has been estimated to be 80 new cases per 100,000

people (World Health Organization, Countries, Bosnia and Herzegovina. TB Country Profile, surveillance and epidemiology. [http://www.who.int/GlobalAtlas/predefinedReports/TB/PDF\\_Files/bih.pdf](http://www.who.int/GlobalAtlas/predefinedReports/TB/PDF_Files/bih.pdf) Accessed October 2010.).

*M. caprae* has been isolated from cattle in Spain (GUTIERREZ et al., 1995), France (HADDAD et al., 2001), Austria (PRODINGER et al., 2002), Germany (KUBICA et al., 2003), Czech Republic (PAVLIK et al., 2002b), Slovakia (PAVLIK et al., 2002c), Slovenia (ERLER et al., 2004), and Croatia (CVETNIĆ et al., 2006 and 2007). Our findings further support the dominance of *M. caprae* in bovine tuberculosis on the European Continent. Epidemiological investigation supported by MIRU typing results, suggested that the infections in the regions of Vitez and Livno are not connected.

Consumption of raw milk and milk products from infected cows poses a threat to human health. *M. caprae* is a common cause of bovine tuberculosis in humans (KUBICA et al., 2003; CVETNIĆ et al., 2007; RODRÍGUEZ et al., 2009); however, in our case the people living on the farms showed no signs of illness, probably because they were not consuming raw milk or the period of contact with infected animals was short. In Bosnia and Herzegovina, especially in central and south western parts, bovine and particularly sheep milk is used for traditional cheese production. Thus, it is important to boil the milk properly for consumption and cheese production to prevent the spread of bovine tuberculosis from animals to humans.

The exact source of the infection in the examined animals could not be established for various reasons (illegal trade, undocumented origin of infected cattle, uncontrolled movements of animals, unknown status of tuberculosis in wild animals). In comparison with previously described MIRU types in neighboring Croatia (ŠPIČIĆ, 2008) and most European countries (PRODINGER et al., 2005) our *M. caprae* type from Vitez region is unique. Regarding this result, our 4 isolates from Livno region are unique in relation to Croatian *M. caprae* types and were previously described in 2 German regions in 2002 and 2003. Despite the fact that Bosnia and Herzegovina had intensive cattle import from the EU, without additional genotype investigation it will be impossible to prove transmission of causing agents (FROTHINGHAM and MEEKER-O'CONNELL, 1998; SUPPLY et al., 2000 and 2006). Identical MIRU type results for 4 isolates from cattle infected in 4 herds may indicate the transmission of the same causing agents between herds in the Livno region. The incidence of bovine tuberculosis in wildlife in Bosnia and Herzegovina is unknown but wild animals, such as wild boar (MACHACKOVA et al., 2003) and red deer (PRODINGER et al., 2002) are documented reservoirs of mycobacteria and may be a source of infection for cattle, other animals and humans. The animals reported here were in pasture in meadows where wild deer were also grazing and wild boars rutting. Hence, in our case the infection could be transmitted from wild animals to the grazing cattle. Another source of infection could be from infected cows introduced into the herds through illegal trade.

As a result it is important to strengthen measures for eradication of tuberculosis. Although there are defined and prescribed measures for tuberculosis control and eradication at federal and state levels (Veterinary Office of the Bosnia and Herzegovina, 2010), they are not fully applied in the whole territory and in all veterinary practices. Tuberculin skin testing is mandatory for all cattle once every year, and all cattle carcasses are subjected to inspection at abattoirs. These actions are not fully and appropriately applied and from 1999 onwards only a few cases of suspected lesions found at abattoirs were submitted for histopathologic examination at the Department of Pathology of the Veterinary Faculty of Sarajevo. Also, animals that reacted positive to the tuberculin skin test were not submitted for necropsy, histopathology and microbiology for confirmation, but were immediately euthanized. For a better understanding of the epidemiology and better planning of control measures and eradication of bovine tuberculosis, all TST positive animals should be submitted for necropsy, histopathology and microbiology for cultivation, identification and typisation of precise mycobacterial species involved. These measures will give a better insight into the epidemiological situation of bovine tuberculosis in Bosnia and Herzegovina and hopefully prevent further spread of the disease to the human population.

### References

- ARANAZ, A., D. COUSINS, A. MATEOS, L. DOMÍNGUEZ (2003): Elevation of *Mycobacterium tuberculosis* subsp. *caprae* Aranaz et al. 1999 to species rank as *Mycobacterium caprae* comb. nov., sp. nov. *Int. J. Syst. Evol. Microbiol.* 53, 1785-1789.
- CVETNIĆ, Ž., V. KATALINIĆ-JANKOVIĆ, B. ŠOŠTARIĆ, S. ŠPIČIĆ, M. OBROAC, S. MARJANOVIĆ, M. BENIĆ, B. K. KIRIN, I. VICKOVIĆ (2007): *Mycobacterium caprae* in cattle and humans in Croatia. *Int. J. Tuberc. Lung. Dis.* 11, 652-658.
- CVETNIĆ, Ž., S. ŠPIČIĆ, V. KATALINIĆ-JANKOVIĆ, S. MARJANOVIĆ, M. OBROVAC, M. BENIĆ, M. MITAK, I. PAVLIK (2006): *Mycobacterium caprae* infection in cattle and pigs on one family farm in Croatia: a case report. *Veterinarni medicina* 51, 523-531.
- ERLER, W., G. MARTIN, K. SACHSE, L. NAUMANN, D. KAHLAU, J. BEER, M. BARTOS, G. NAGY, Ž. CVETNIĆ, M. ZOLNIR-DOVC, I. PAVLIK (2004): Molecular fingerprinting of *Mycobacterium bovis* subsp. *caprae* isolates from Central Europe. *J. Clin. Microbiol.* 42, 2234-2238.
- FEJZIĆ, N., J. FERIZBEGOVIĆ, S. CORNWELL (2000): Challenge in a transitional economy. *Proceedings of the sixth ISVEE*, 6-11 August. Breckenridge, Colorado, USA. pp. 69-71.
- FROTHINGHAM, R., W. A. MEEKER-O'CONNELL (1998): Genetic diversity in the *Mycobacterium tuberculosis* complex based on variable numbers of tandem repeats. *Microbiol.* 144, 1189-1196.
- GUTIERREZ, M., S. SAMPER, J. A. GAVIGAN, J. F. M. GARCIA, C. MARTIN (1995): Differentiation by molecular typing of *Mycobacterium bovis* strains causing tuberculosis in cattle and goats. *J. Clin. Microbiol.* 33, 2953-2956.

- HADDAD, N., A. OSTYN, C. KAROUI, M. MASSELOT, M. F. THOREL, S. L. HUGHES, J. INWALD, R. G. HEWINSON, B. DURAND (2001): Spoligotype diversity of *Mycobacterium bovis* strains isolated in France from 1979 to 2000. *J. Clin. Microbiol.* 39, 3523-3632.
- HANCE, A. J., B. GRANDCHAMP, V. LÉVY-FRÉBAULT, D. LECOSSIER, J. RAUZIER, D. BOCART, B. GICQUEL (1989): Detection and identification of mycobacteria by amplification of mycobacterial DNA. *Mol. Microbiol.* 3, 843-849.
- KUBICA, T., S. RÜSCH-GERDES, S. NIEMANN (2003): *Mycobacterium bovis* subsp. *caprae* caused one-third of human *M. bovis*-associated tuberculosis cases reported in Germany between 1999 and 2001. *J. Clin. Microbiol.* 41, 3070-3077.
- MACHACKOVA, M., L. MATLOVA, J. LAMKA, J. SMOLIK, I. MELICHAREK, M. HANZLIKOVA, J. DOCEKAL, Ž. CVETNIĆ, G. NAGY, M. LIPIEC, M. OČEPEK, I. PAVLIK (2003): Wild boar (*Sus scrofa*) as a possible vector of mycobacterial infections: review of literature and critical analysis of data from Central Europe between 1983 to 2001. *Veterinarny Medicina* 48, 51-65.
- PAVLIK, I., W. Y. AYELE, I. PARMOVA, I. MELICHAREK, M. HANZLIKOVA, B. KORMENDY, G. NAGY, Ž. CVETNIĆ, M. OČEPEK, N. FEJZIĆ, M. LIPIEC (2002a): Incidence of bovine tuberculosis in cattle in seven Central European countries during the years 1990-1999. *Veterinarny Medicina* 47, 45-51.
- PAVLIK, I., F. BURES, P. JANOVSKY, P. PECINKA, A. BARTOS, L. DVORSKA, L. MATLOVA, K. KREMER, D. VAN SOOLINGEN (2002b): The last outbreak of bovine tuberculosis in cattle in the Czech Republic in 1995 was caused by *Mycobacterium bovis* subspecies *caprae*. *Veterinarny Medicina* 47, 251-263.
- PAVLIK, I., L. DVORSKA, M. BARTOS, I. PARMOVA, I. MELICHAREK, A. JESENSKA, M. HAVELKOVA, M. SLOSAREK, I. PUTOVA, G. MARTIN, W. ERLER, K. KREMER, D. VAN SOOLINGEN (2002c): Molecular epidemiology of bovine tuberculosis in the Czech Republic and Slovakia in the period 1965-2001 studied by spoligotyping. *Veterinarny Medicina* 47, 181-194.
- PRODINGER, W. M., A. BRANDSTÄTTER, L. NAUMANN, M. PACCIARINI, T. KUBICA, M. L. BOSCHIROLI, A. ARANAZ, G. NAGY, Ž. CVETNIĆ, M. OČEPEK, A. SKRYPNYK, W. ERLER, S. NIEMANN, I. PAVLIK, I. MOSER (2005): Characterization of *Mycobacterium caprae* isolates from Europe by mycobacterial interspersed repetitive unit genotyping. *J. Clin. Microbiol.* 43, 4984-4992.
- PRODINGER, W. M., A. EIGENTLER, F. ALLERBERGER, M. SCHÖNBAUER, W. GLAWISCHNIG (2002): Infection of red deer, cattle, and humans with *Mycobacterium bovis* subsp. *caprae* in Western Austria. *J. Clin. Microbiol.* 40, 2270-2272.
- RODRÍGUEZ, E., L. P. SÁNCHEZ, S. PÉREZ, L. HERRERA, M. S. JIMÉNEZ, S. SAMPER, M. J. IGLESIAS (2009): Human tuberculosis due to *Mycobacterium bovis* and *M. caprae* in Spain, 2004-2007. *Int. J. Tuberc. Lung. Dis.* 13, 1536-1541.
- SUPPLY, P., E. MAZARS, S. LESJEAN, V. VINCENT, B. GICQUEL, C. LOCHT (2000): Variable human minisatellite-like regions in the *Mycobacterium tuberculosis* genome. *Mol. Microbiol.* 36, 762-771.



- SUPPLY, P., S. LESJEAN, E. SAVINE, K. KRAMER, D. van SOOLINGEN, C. LOCHT (2001): Automated high-throughput genotyping for study of global epidemiology of *Mycobacterium tuberculosis* based on mycobacterial interspersed repetitive units. *J. Clin. Microbiol.* 39, 3563-3571.
- SUPPLY, P., C. ALLIX, S. LESJEAN, M. CARDOSO-OELEMANN, S. RÜSCH-GERDES, E. WILLERY, E. SAVINE, P. de HAAS, H. van DEUTEKOM, S. RORING, P. BIFANI, N. KEREPINA, B. KREISWIRTH, C. SOLA, N. RASTOGI, V. VATIN, M. C. GUTIERREZ, M. FAUVILLE, S. NIEMANN, R. SKUCE, K. KREMER, C. LOCHT, D. van SOOLINGEN (2006): Proposal for standardization of optimized mycobacterial interspersed repetitive unit-variable-number tandem repeat typing of *Mycobacterium tuberculosis*. *J. Clin. Microbiol.* 44, 4498-4510.
- ŠPIČIĆ, S. (2008): Molecular epidemiology of *Mycobacterium tuberculosis* and *Mycobacterium avium* complex isolated from human, animals and environment (Molekularna epizootiologija vrsta *Mycobacterium tuberculosis* i *Mycobacterium avium* kompleksa izdvojenih iz ljudi, životinja i okoliša). PhD Thesis, University of Zagreb, Zagreb, Croatia.
- VARELLO, K., M. PEZZOLATO, D. MASCARINO, F. INGRAVALLE, M. CARAMELLI, E. BOZZETTA (2008): Comparison of histologic techniques for the diagnosis of bovine tuberculosis in the framework of eradication programs. *J. Vet. Diag. Invest.* 20, 164-169.

Received: 11 July 2011

Accepted: 17 April 2012

---

**BEŠIROVIĆ, H., A. ALIĆ, S. ŠPIČIĆ, Ž. CVETNIĆ, S. PRAŠOVIĆ, L. VELIĆ:**  
**Tuberkuloza goveda u Bosni i Hercegovini uzrokovano vrstom *Mycobacterium caprae*. *Vet. arhiv* 82, 341-349, 2012.**

**SAŽETAK**

Tuberkuloza goveda je kronična bolest zoonotskog karaktera koja se javlja u goveda i velikog broja domaćih i divljih životinja. U ovom je radu opisana tuberkuloza goveda izazvana vrstom *M. caprae* u šest malih domaćinstava u Bosni i Hercegovini. Za dokazivanje bolesti i determinaciju uzročnika rabljen je komparativni tuberkulinski kožni test (TKT), patomorfološki i mikrobiološki nalaz te molekularne metode. Dvadeset i osam krava iz pet domaćinstava na području Livna (25/28 životinja) i jednog domaćinstva na području Viteza (3/28 životinja) bilo je eutanazirano nakon što su bile pozitivne na komparativni TKT test. Jedanaest životinja iz pet domaćinstava na području Livna (9/11 životinja) i jednog domaćinstva na području Viteza (2/11 životinja) bilo je razučeno u terenskim uvjetima. Na svim truplima bile su uočene lezije osebujne za tuberkulozu na limfnim čvorovima torakalne šupljine i na plućima. Histopatološkom pretragom, bojenjem hematoksilin-eozinom bila je potvrđena prisutnost specifičnih granulomatoznih lezija dok je bojenje po Ziehl-Neelsenu pokazalo prisutnost veoma malog broja acidorezistentnih bakterija. Na bakteriološku pretragu dostavljeni su medijastinalni limfni čvorovi od sedam razučenih životinja (dvije životinje s područja Viteza i pet životinja iz pet domaćinstava s područja Livna). Acidorezistentne bakterije bile su izdvojene iz pet od sedam uzoraka dostavljenih na pretragu, i to od jedne životinje s područja Viteza i četiri životinje iz četiri domaćinstva s područja Livna. Svi su izolati identificirani kao *M. caprae*. MIRU tipizacijom ustanovili smo dva različita, za Bosnu i Hercegovinu jedinstvena genotipa *M. caprae*. Naši nalazi predstavljaju prvi dokaz tuberkuloze goveda uzrokovane vrstom *M. caprae* u Bosni i Hercegovini.

**Cljučne riječi:** govedo, tuberkuloza, *Mycobacterium caprae*, Bosna i Hercegovina, epidemiologija

---

