

Morphopathologic characteristics of myiasis caused by *Przhevalskiana silenus* larvae in goats

Azizollah Khodakaram-Tafti^{1*}, Seyed M. Razavi²,
and Sedigheh Gorgipour²

¹Department of Pathology, School of Veterinary Medicine, Shiraz University, Shiraz, Iran

²Department of Parasitology, School of Veterinary Medicine, Shiraz University, Shiraz, Iran

KHODAKARAM-TAFTI, A., S. M. RAZAVI, S. GORGIPOUR: Morphopathologic characteristics of myiasis caused by *Przhevalskiana silenus* larvae in goats. Vet. arhiv 82, 25-33, 2012.

ABSTRACT

Myiasis due to *Przhevalskiana silenus* infestation is an economic and health problem in most goat breeding countries. In the present study, the skin, subcutaneous tissues and internal organs of eighty-five local breed goats naturally infested by *Przhevalskiana silenus* larvae were examined grossly and histopathologically. Macroscopically, variable numbers of different larval stages (first, second and third) were observed in the subcutaneous tissues and the skin of the back and flanks. Abscess formation, perforated ulcers and also a number of holes due to migratory tracts and emerging mature larvae were observed in the affected skins. No larvae or any suspected lesions were found in other parts of the body. Microscopically, two main pathological lesions were diagnosed in the path of migration or around remnant fragments of alive or dead larvae in subcutaneous tissues, including purulent to non-purulent and granulomatous to pyogranulomatous dermatitis. The cross section of the larvae showed a thick eosinophilic cuticle associated with a number of outer short tiny spikes, various internal organs, such as the digestive system, were lined by tall simple columnar epithelium and full of digested inflammatory cells. Degenerated or dead larvae or fragments of the live larvae cuticle induced granulomatous or pyogranulomatous inflammatory reactions during molting.

Key words: morphopathology, *Przhevalskiana silenus*, myiasis, goat

Introduction

Myiasis due to *Przhevalskiana silenus* (Goat Warble Fly Infestation, GWFI) is an economic and health problem in most goat breeding countries. Due to geographical and meteorological variations and grazing pattern, the prevalence of the infestation differs considerably throughout the world (GIANGASPERO and LIA, 1997; FALIERO et al., 2001). The causative insect belongs to the Order Diptera, the Family Oestridae and Subfamily

*Corresponding author:

Dr. Azizollah Khodakaram-Tafti, DVM, PhD, Professor, Department of Pathology, School of Veterinary Medicine, PO Box 71345-1731, Shiraz University, Shiraz, Iran, Phone: + 98 711 2286 950; Fax: +98 711 2286 940; E-mail: tafti@shirazu.ac.ir

Hypoderminae (ZUMPT, 1965). The economic impacts are the loss of hides for the leather industry, loss in weight gain, milk production, and also decreasing carcass value due to inflammatory reactions and meat trimming at the slaughterhouse. In addition, *P. silenus* larvae rarely infest human beings, resulting in irritation and hypersensitivity responses (ABUL-HAB and AL-S'ADI, 1974).

Despite the high infestation rate in some parts of the world, little information is reported about morphopathological changes associated with this myiasis. Therefore, the present study was undertaken to investigate gross and histopathological lesions of GWFI in naturally infested goats.

Materials and methods

From November 2008 to February 2009, the skin, subcutaneous soft tissues, subcutaneous muscles and internal organs of eighty-five local breed goats of different ages and sexes, naturally infested by *Przhevalskiana silenus* larvae, were examined carefully at Fars slaughterhouse, Fars, Iran. Gross changes were observed, such as palpable larvae on the back, flanks and chest, congestion, hemorrhage, parasitic nodules or lumpy lesions, subcutaneous warbles, cysts, abscesses or suppurative lesions. Appropriate tissue samples from affected areas were fixed in 10% buffered formalin, embedded in paraffin, sectioned at about 5 µm, stained with haematoxylin and eosin and studied microscopically.

Results

Grossly, variable numbers of different larvae of different sizes and colors were observed in the subcutaneous tissues and the skin of the back and flanks. No larvae or any suspected lesions were found in other parts of the body.

The first larval stages were white in color, club-shaped, and sized about 2-7 mm in length. They were located in the deep parts of subcutaneous tissues (Fig. 1).

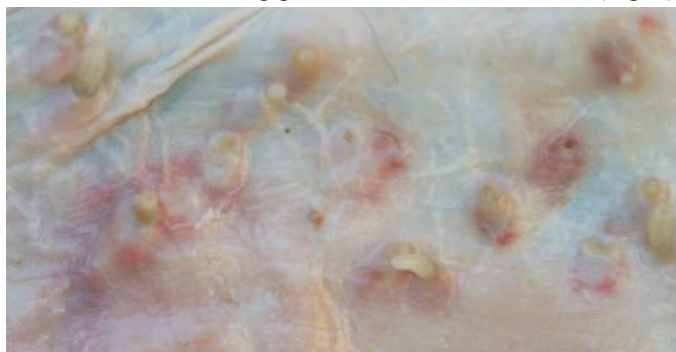

Fig. 1. Goat warble fly infestation. Subcutaneous tissue. First larval stages are seen as white in color, club-shaped, sized about 2-7 mm in length, located in the deep parts.

The second larval stages to some extent, in view of the color and location were similar to the first instar larvae but were larger, sized about 8-12 mm in length (Fig. 2).

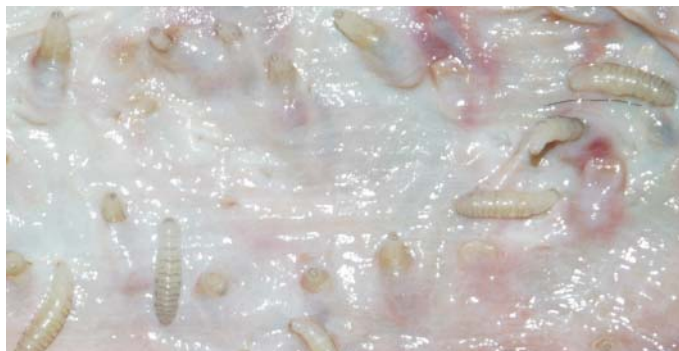

Fig. 2. Subcutaneous tissue. Second larval stages of *P. silenus* sized about 8-12 mm in length.

The third larval stages were completely different in comparison with the 1st and 2nd stages of larvae. They were dark brown to black in color, about 13-19 mm in length and were located in the superficial dermis, subepidermis and epidermis. A comparison of different larval stages is shown in Fig. 3.

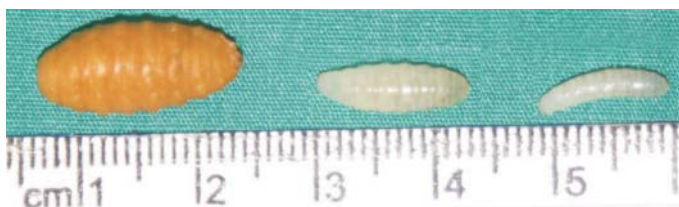

Fig. 3. The comparative different larval stages of *P. silenus* are shown. The third larval stages are dark brown to black in color and larger than 1st and 2nd larval stages.

Abscess formation, perforated ulcers and a number of holes due to migratory tracts and emerging mature larvae were observed in the affected skin.

The histopathological changes were variable from mild to severe. Compression atrophy in surrounding tissues and a mild inflammatory reaction accompanied with lymphocytes and eosinophils infiltration were the prominent changes around the 1st stage live larvae in the subcutaneous tissues. There were no degenerative or necrotic lesions in the upper dermis and the overlying epidermis was intact. In contrast, the tissue reaction around the 2nd and 3rd stage live larvae and also degenerated or dead larvae of all developmental stages was mostly granulomatous inflammation.

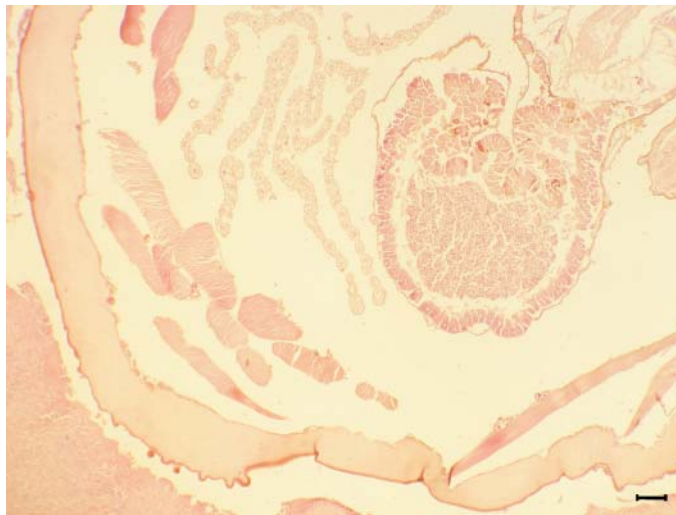


Fig. 4. A cross section of the larvae of *P. silenus* in the subcutaneous tissue, showing a thick eosinophilic cuticle associated with a number of outer short, tiny spikes and various internal organs, including the digestive system. H&E; $\times 60$, scale bar = 300 μm .

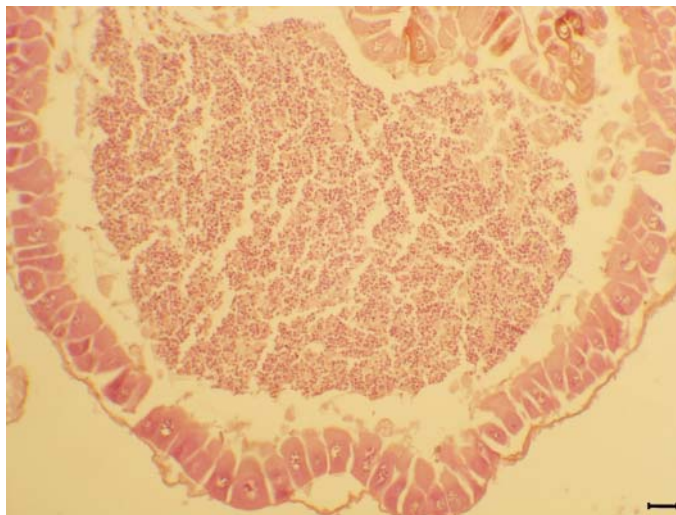


Fig. 5. Higher magnification of Fig. 4. A cross section of the intestine of the larvae, lined by tall, simple columnar epithelium. The lumen contains a large number of inflammatory cells. H&E; $\times 180$, scale bar = 100 μm .

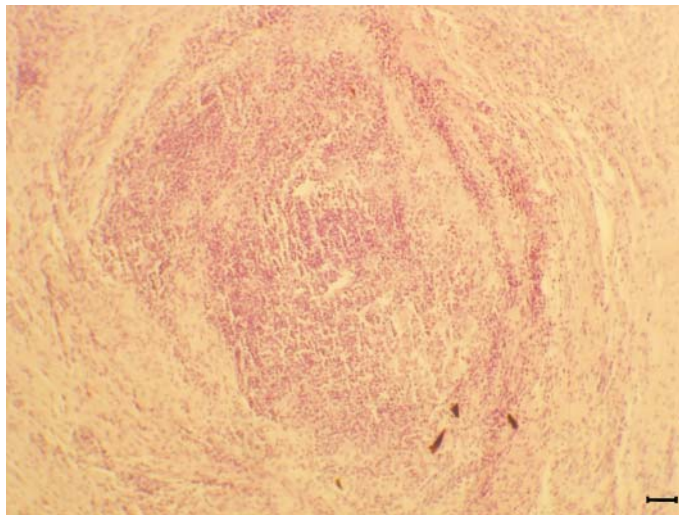


Fig. 6. Abscess formation and severe inflammatory reaction due to larvae migration. H&E; $\times 160$, scale bar = 112 μm .

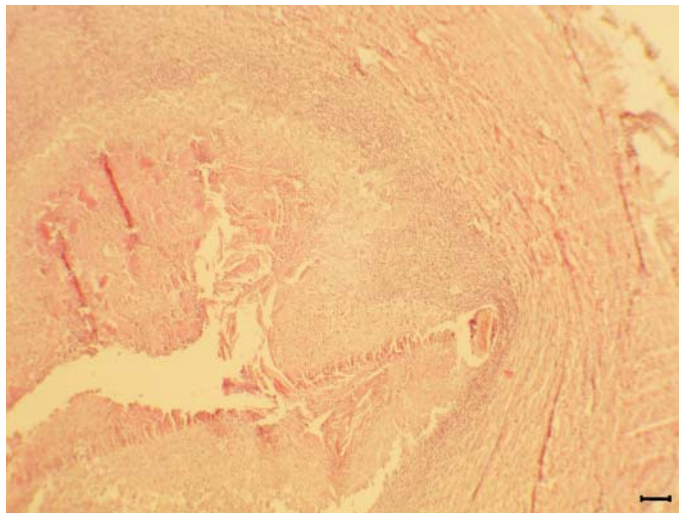


Fig. 7. Granulomatous inflammation in the subcutaneous tissue. A cavity in the center, eosinophilic necrotic tissue, inflammatory cells and a thick capsule of fibrous connective tissue are seen. H&E; $\times 160$, scale bar = 112 μm .

The cross section of the larvae in the tissues showed a thick eosinophilic cuticle associated with a number of outer, short tiny spikes, and various internal organs including bead-like structures formed by large oval cells, with central nuclei and numerous cytoplasmic vacuoles (Fig. 4). The digestive system of the larvae were lined with tall simple columnar epithelium and the lumen contained a large number of red blood cells, neutrophils and other inflammatory cells (Fig. 5).

The larvae migration induced necrosis in the surrounding tissues. associated with a severe inflammatory reaction (Fig. 6). In chronic lesions, these were replaced by a fibrous connective tissue, infiltrated by mononuclear inflammatory cells, including lymphocytes, macrophages and plasma cells.

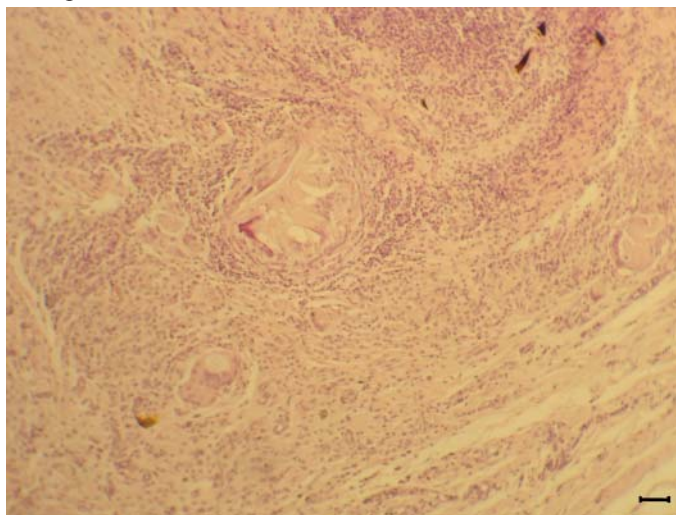


Fig. 8. Chronic inflammatory reaction including larva remnant fragments, aggregation of lymphocytes, plasma cells, macrophages and giant cells and also fibrosis. H&E; $\times 160$, scale bar = 112 μm .

The remnants of degenerated or dead larvae induced granulomatous or pyogranulomatous inflammatory reactions. These reactions were characterized by the presence of fragments of the remnant larvae or a cavity associated with eosinophilic necrotic tissue and infiltration of neutrophils, surrounded by lymphocytes, eosinophils, plasma cells, epithelioid macrophages and giant cells, and a thick capsule of fibrous connective tissue (Figs. 7 and 8).

Discussion

Goat warble fly infestation has been reported from many countries including: Pakistan, Saudi Arabia, Syria, India, Turkey, Iraq, Jordan, Egypt, Cyprus, Greece, Iran and Italy (HIMONAS et al., 1982; GIANGASPERO et al., 1996; ABU-SHEHADA et al., 2006; MORSY et al. 1998; OTRANTO and PUCCINI, 2000; AZIZI et al., 2007; ORYAN et al., 2009). The prevalence rate of infestation varies from 2 to 94% in these countries. The associated pathological lesions have not been adequately documented in the literature. The results of the present study showed two main pathological lesions around live or dead larva in subcutaneous tissue including non-purulent and granulomatous or pyogranulomatous dermatitis associated with variable infiltration of eosinophils, and also different degrees of peripheral fibrosis. There was no larval migration into the internal organs. In some cases, abscess formation in the subcutaneous tissues was evident. Our finding that the life cycle of the parasite takes place exclusively subcutaneously and mostly in the dorsal areas of the affected goats is in agreement with other reports (OTRANTO and PUCCINI, 2000).

The adult *P. silenus* lacks mouth parts and survives on resources accumulated during the larval period for about 3-8 days (ZUMPT, 1965). Based on the climate, the adult fly is active from April to June in different parts of Iran (JAFARI-SHOURIJEH and REZAZADEH, 1997; AZIZI et al., 2007). During these periods, the 1st stage larva emerges from the eggs laid directly on the hairs of the back and flank regions of the goats. By releasing large amounts of collagenolytic enzymes, it penetrates into the skin and localizes in deep parts of the subcutaneous tissue (MADEL and NAHIF, 1971; PUCCINI et al., 1988). Then the 1st stage larva develops into 2nd stage larva and finally into 3rd stage larva that emerge through the holes in the epidermis to pupate in the ground. Designing a prevention and control program requires more knowledge of the complete life cycle of the fly. In the present study, the presence of a large number of dead larvae and the granulomatous reaction around them in the subcutaneous tissue may indicate that the development of immunity plays a significant role in fighting larval migration and host resistance. It has been reported that repeated exposure to larval antigens results in the development of acquired resistance against bovine hypodermosis (GINGRICH, 1982). This resistance was dependent on previous exposure and the number of invaded larvae, and plays an important role in controlling the infestation. It is proposed that the lower prevalence rate of *P. silenus* infestation in older goats may be due to the fact that their skin is too hard and thick for larval penetration or due to the development of immunity due to previous infestation (OTRANTO and PUCCINI, 2000; ORYAN et al., 2009). However, with regard to the economic and health importance of the disease, as an important veterinary problem in goat rearing areas, it is necessary to investigate in more detail the pathogenesis and immunopathology of the infestation, particularly after repeated exposure in order to design proper control programs.

Acknowledgements

The authors are grateful to Mr. L. Shirvani and Mr. G. Yusefi for their technical assistance and also to the abattoir officials of Fars slaughterhouse for their valuable cooperation.

References

- ABU-SHEHADA, M., T. BATAINAH, N. ABU-HARFEIL, P. R. TORGERSON (2006): *Przhevalskiana silenus* myiasis among slaughtered goats in northern Jordan. *Vet. Parasitol.* 137, 345-350.
- ABUL-HAB, J., H. AL-S'ADI (1974): Seasonal occurrence of *Przhevalskiana silenus*, Brauer, 1858 (Diptera, Oestridae) warble flies of goats and sheep in the Baghdad. *Trop. Landwirtschaft Veterinaarmed* 12, 453-458.
- AZIZI, H., M. POURJAFAR, S. DARABI, F. ASSADIAN, F. A. KAHKESH (2007): Survey of seasonal infestation with *Przhevalskiana* larvae in slaughtered goats and sheep in south-western Iran. *Pakistan J. Biol. Sci.* 10, 3940-3943.
- FALIERO, D., D. OTRANTO, A. TRAVERSA, G. GIANGASPERO, R. SANTAGADA, R. LIA, V. PUCCINI (2001): Goat warble fly infestation by *Przhevalskiana silenus* (Diptera: Oestridae): immunoepidemiologic survey in the Basilicata region (southern Italy). *Parasitol.* 43, 131-134.
- GIANGASPERO, A., R. LIA (1997): Mapping goat warble fly distribution and related problems. *Parasitol.* 29, 423-426.
- GIANGASPERO, A., M. AMBROSI, E. ARRU, G. CRINGOLI, A. PUGLIESE, G. PRESTERA, P. SCARAMOZZINO (1996): Goat warble fly infestation in Italy: current situation. Proceedings of XIII European COST 811, Conf. Hypodermosis of Livestock, 5-6 September, Parma, Italy.
- GINGRICH, R. E. (1982): Acquired resistance to *Hypoderma lineatum*: comparative immune response of resistance and susceptible cattle. *Vet. Parasitol.* 9, 233-242.
- JAFARI-SHOORIJEH, S., H. REZAZADEH (1997): Study on hypodermosis of sheep and goats in the Fars industrial meat complex and assessment of economic losses to hide production. *J. Fac. Vet. Med. Univ. Tehran* 52, 61-71.
- HIMONAS, C. A., C. BOULARD, H. THOMBERRY (1982): The status of hypodermosis in cattle and goats in Greece, warble fly control in Europe. Symposium in EC Program Coordinate Research in Pathology, Bruxelles, Belgium.
- MADDEL, G., A. A. NAHIF (1971): Zur Entwicklung, Histologie und Sekretion der larvalen Speicheldrüsen der Ziegendasselfliege *Crivellia silenus* Brauer (Diptera, Hypodermatidae). *Z. Parasitkde* 37, 211-225.
- MORSY, T. A., A. SHUKRY, S. A. MAZYOD, M. M. ABOU-GAMRA (1998): The goat warble fly, *Przhevalskiana silenus* (Brauer) in north Sinai - Egypt. *J. Soc. Parasitol.* 28, 373-378.
- ORYAN, A., S. M. RAZAVI, S. BAHRAMI (2009): Occurrence and biology of goat warble fly infestation by *Przhevalskiana silenus* (Diptera, Oestridae) in Iran. *Vet. Parasitol.* 166, 178-181.

- OTRANTO, D., V. PUCCINI (2000): Further evidence on the internal life cycle of *Przhevalskiana silenus* (Diptera, Oestridae). *Vet. Parasitol.* 88, 321-328.
- PUCCINI, V., P. TASSI, A. GIANGASPERO (1988): Goat warble fly (*Przhevalskiana silenus* Brauer): etiology, epidemiology, biology and therapy. *Proceeding of Vet. European Multi Parasitol.*, Budapest, Hungary. P. 187.
- ZUMPT, F. (1965): Myiasis in man and animals of the old world. Butterworth, London, PP. 267-268.

Received: 7 December 2010

Accepted: 14 July 2011

KHODAKARAM-TAFTI, A., S. M. RAZAVI, S. GORGIPOUR: Patomorfološke značajke mijaze uzrokovane ličinkama štrka *Przhevalskiana silenus* u koza. *Vet. arhiv* 82, 25-33, 2012.

SAŽETAK

Mijaza uzrokovana štrkom *Przhevalskiana silenus* od velikoga je gospodarskoga i zdravstvenoga značenja u većini zemalja s razvijenim kozarstvom. U radu su patomorfološki i patohistološki bili pretraženi uzorci tkiva kože, potkožja i unutarnjih organa 85 koza lokalne pasmine prirodno infestiranih ličinkama štrka *Przhevalskiana silenus*. Makroskopski je ustanovljen različiti broj ličinaka prvoga, drugoga i trećega stupnja u koži i potkožnom tkivu u području slabina i leđa. Na zahvaćenom dijelu kože javili su se apscesi, perforirani čirevi i velik broj otvora zbog migracije i dozrijevanja ličinaka. Na ostalim dijelovima tijela nisu bile ustanovljene ni ličinke ni ikakve promjene. Mikroskopski su bile ustanovljene promjene na putovima migracije ili na mjestu ostataka uginulih ili živih ličinaka u potkožnom tkivu, koje su se očitovale u obliku gnojne ili negnojne granulomatozne upale kože. Ličinke su na presjeku pokazivale debelu eozinofilnu kutikulu povezanu s velikim brojem vanjskih kratkih, tankih izdanaka te različitim unutarnjim organima kao što su probavni organi s visokim stupčastim epitelom ispunjeni upalnim stanicama. Degenerativne ili uginule ličinke ili dijelovi odljuštene kutikule živih ličinaka uzrokovali su granulomatoznu ili piogranulomatoznu upalnu reakciju.

Ključne riječi: patomorfologija, *Przhevalskiana silenus*, mijaza, koza
