

## Unilateral segmental aplasia of the uterine horn in a gravid bitch - a case report

Silvijo Vince<sup>1\*</sup>, Branimira Ževrnja<sup>1</sup>, Ana Beck<sup>2</sup>, Ivan Folnožić<sup>1</sup>, Darko Gereš<sup>1</sup>,  
Marko Samardžija<sup>1</sup>, Juraj Grizelj<sup>1</sup>, and Tomislav Dobranić<sup>1</sup>

<sup>1</sup>*Clinic for Obstetric and Reproduction, Faculty of Veterinary Medicine, University of Zagreb, Zagreb, Croatia*

<sup>2</sup>*Department of General Pathology and Pathological Morphology, Faculty of Veterinary Medicine, University of Zagreb, Zagreb, Croatia*

---

VINCE, S., B. ŽEVRNJA, A. BECK, I. FOLNOŽIĆ, D. GERES, M. SAMARDŽIJA, J. GRIZELJ, T. DOBRANIĆ: Unilateral segmental aplasia of the uterine horn in a gravid bitch - a case report. *Vet. arhiv* 81, 691-698, 2011.

### ABSTRACT

A 1.5-year-old mongrel bitch was presented at the Clinic for obstetrics and reproduction at the Faculty of Veterinary Medicine in Zagreb for spaying. Since the animal had been found and kept in animal shelter, no anamnestic data about her reproductive status were known. A general examination did not reveal any preoperative problem. On ultrasonograph it was found that bitch was about four weeks pregnant. Finally, and with the owner's consent, ovariectomy was proposed and accepted as a radical alternative to medical abortion following an unwanted pregnancy, as it also involves definitive sterilization. The surgical procedure comprising ovariectomy was performed under general endotracheal anesthesia. The procedure revealed segmental aplasia of the left uterine horn with an intact left ovary and kidney.

**Key words:** segmental aplasia, uterine horn, ovariectomy, bitch

---

### Introduction

Agenesis is the failure in development of a structure or organ system because of the nonappearance of its primordium during embryonic development. Agenesis of any portion of the reproductive tract can be seen in all breeds of dogs and cats. In the reproductive tract of dogs and cats agenesis of the gonads, Müllerian or Wolffian ducts, urogenital sinus, genital tubercle or genital swelling can be seen (WYKES and OLSON, 1996). In females examples include ovarian agenesis and hypoplasia, segmental aplasia of oviducts, uterus and vagina (ROOT KUSTRITZ, 2003). The developmental failure of part of the uterus is

---

\*Corresponding author:

Silvijo Vince, PhD, DVM, Clinic for Obstetrics and Reproduction, Faculty of Veterinary Medicine, University of Zagreb, Heinzelova 55, 10000 Zagreb, Croatia, Phone: +385 1 2390 185; Fax: +385 1 23900 320; E-mail: svince@vef.hr

segmental aplasia, when a segment of the paramesonephric duct (Müllerian system) fails to develop. Segmental aplasia of the uterus may involve: both horns (aplasia uteri totalis), when there is no development of the ductus paramesonefricus or they collapse before even managing to merge partially; one horn (aplasia uteri partialis), when only one Müllerian duct fully evolves (resulting in a condition called uterus unicornis seu lateralis); or only part of one horn (which may result in cystic dilatation of the uterine horn cranial to the aplastic area). Histologically, there is usually a thin strip of smooth muscle, representing the external smooth muscle layer normally present in the mesometrium with connective tissue fibers. No distinct myometrium and endometrium are present (JONES et al., 1996).

Uterus unicornis is often associated with unilateral renal agenesis, because of the common embryonic origin of the uterus and kidneys (ductus paramesonefricus) (SENGER, 1995). Aplasia of the associated ovary may or may not be present, but in most cases the ovary is present due to its different embryologic development, since ovaries develop from the genital (gonadal) ridge (McENTEE, 1990). Congenital, bilateral, segmental aplasia of the uterine horns results in occlusion of the tubular female tract (FELDMAN and NELSON, 1996; JOHNSTON et al., 2001). Bitches with uterine tube and/or uterine horn agenesis and normal ovaries usually exhibit typical oestrous behavior but either fail to become pregnant (bilateral lesion) or, if becoming pregnant, have small numbers of offspring (unilateral lesion).

Diagnosis usually relies upon direct inspection of the reproductive tract via laparotomy or laparoscopy (ENGLAND, 2009).

This is the first described case of uterine unilateral segmental aplasia with the gravidity of the other horn at the same time. The goal of this paper is to contribute to a better understanding of segmental aplasia of female reproductive organs that sometimes can complicate gynecological procedures, such as ovariohysterectomy, cesarean section or any other obstetric intervention.

### **Materials and methods**

A 1.5-year-old mongrel bitch was presented at the Clinic for Obstetrics and Reproduction at Faculty of Veterinary Medicine in Zagreb for sterilization. Since the animal had been found and kept in an animal shelter for about two weeks, the anamnestic data about reproductive status were unknown. Sonographic examination was performed (Pie Medical, transabdominal probe 5 MHz) and the bitch was found to be gravid. The gestational length was determined by an ultrasound veterinary program and the fetal age was estimated to be four weeks by the gestational sac diameter. Ovariohysterectomy was proposed as a radical alternative to medical abortion following an unwanted pregnancy, which also involves definitive sterilization (CONCANNON and MEYERS-WALLEN, 1991). The owner agreed to the surgical procedure comprising ovariohysterectomy. Before

the sterilization the bitch was clinically examined. The operation was performed under general endotracheal anesthesia with controlled mechanical ventilation, maintaining  $\text{etCO}_2$  level between 35 and 45 mm Hg. For premedication methadon (Heptanon<sup>®</sup>, Pliva, Zagreb, Croatia) was used at a dosage of 1 mg/kg of body mass (b.m.) intramuscularly (i/m). Twenty minutes later the animal was induced into general anesthesia using diazepam (Apaurin<sup>®</sup>, Krka-farma d.o.o., Novo Mesto, Slovenia) at a dosage of 0.25 mg/kg b.m. intravenously (i/v), and ketamine (Narketan<sup>®</sup> 10 %, Vétquinol AG, Belp, Switzerland) at a dosage of 10 mg/kg b.m. i/v. For analgesia, after intubation, the bitch received an intravenous bolus of fentanyl (Fentanyl - Janssen<sup>®</sup>, Janssen pharmaceutica, Belgium) at a dosage of 0.003 mg/kg b.m., and anesthesia was maintained using a mixture of isoflurane (Forane<sup>®</sup>, Abbott Laboratories Ltd, Queenborough, Great Britain) 1.5-2 %, oxygen and nitrous oxide in 50 % concentration with respiratory volume of 10 to 20 mL/kg b.m. (PADDLEFORD, 1999). During the operation the bitch received intravenous saline (NaCl 0,9 %<sup>®</sup>, Pliva, Zagreb, Croatia) at a dosage of 10 mL/kg b.m. per hour. After preparation of the operation field, laparotomy was performed in linea alba starting from the umbilicus and ending a few centimeters in front of the pubis. After location of the gravid right uterine horn the related suspensory ligament was torn with the finger to improve visualization. The three- forceps technique, as described in SMITH (1974), was performed for ligation of the ovarian pedicle. After a vain search of the left uterine horn, it was established that it was missing and consisted of tiny fibers with intact broad ligament and arteria uterina media. (Fig. 1.) The left ovary was approximately the same size as the right one. After ligation of the ovarian vessels on both sides, the remaining broad ligament was severed or broken. Each pair of lateral uterine vessels was ligated separately using tight encircling ligature close to the main ligature on the junction of the uterine body and cervix. After removal of the reproductive tract, the abdomen was examined for any trace of hemorrhage and the abdomen incision was closed using a simple continuous suture. The subcutaneous layer and skin were closed using a simple interrupted pattern.

The right uterine horn, both ovaries and the tissue fiber found at the site of the left horn were fixed in neutral buffered 10 % formalin and embedded in paraffin. Paraffin sections 3-5  $\mu\text{m}$  thick were cut, and stained with hematoxylin and eosin (H & E) and Van Gieson methods.

### Results and discussion

Since the anamnestic data concerning the reproductive cycle of the examined bitch were unknown and sonographic examination did not reveal segmental aplasia, the final diagnosis was established during the surgical procedure. In this particular case a fibrous cord with mesometrium and a developed a. uterina media was found instead of the normal left uterine horn (Fig. 2.).

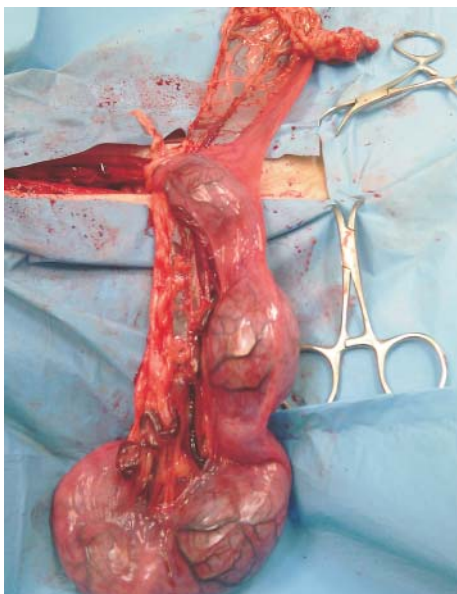


Fig. 1. The uterus with the right gravid horn and undeveloped left horn

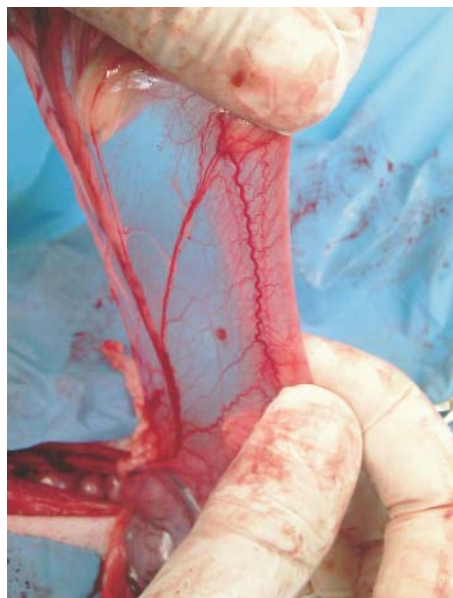

Fig. 2. Undeveloped left uterine horn

Even though some findings in literature describe segmental uterine aplasia with a dilated part of the reproductive system cranial to the place of agenesis (SCHULMAN and BOLTON, 1997; OH et al., 2005) this was not the case here. Histopathological examination revealed a normally developed uterus, except the undeveloped horn. The left ovary was normally developed and equal in size to the right one (Fig. 3.), and it was partially connected with the left kidney with a suspensory ligament. Since the ovary is present in most cases ipsilateral to the aplastic horn due to different embryologic origin (McENTEE, 1990) it is important to find it despite the difficulties. In this case the undeveloped left uterine horn with the presented ovary was found by following the gravid right horn up to the uterine bifurcation. We recommend visualization of the uterine bifurcation in order to see both horns, because it was difficult to find an undeveloped horn with a finger. The another way to locate the left ovary is by finding the left kidney, as in PINTO FILHO et al. (2001), but uterus unicornis is often associated with unilateral renal agenesis, because of the common embryonic origin (SENGER, 1995), so it is not possible in all cases.

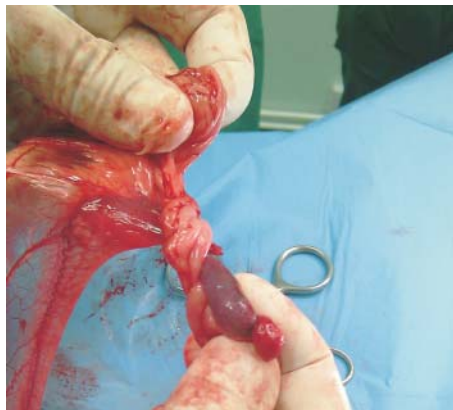

Fig. 3. Normally developed left ovary

Histopathology, particularly Van Gieson staining, confirmed that tissue fiber found at the site of the left horn was a flat structure consisting of smooth muscles and collagen fibers arranged in bundles, occasionally separated by fat tissue layers (Fig. 4.), which is the most usual histological finding (JONES et al., 1996; OH et al., 2005).

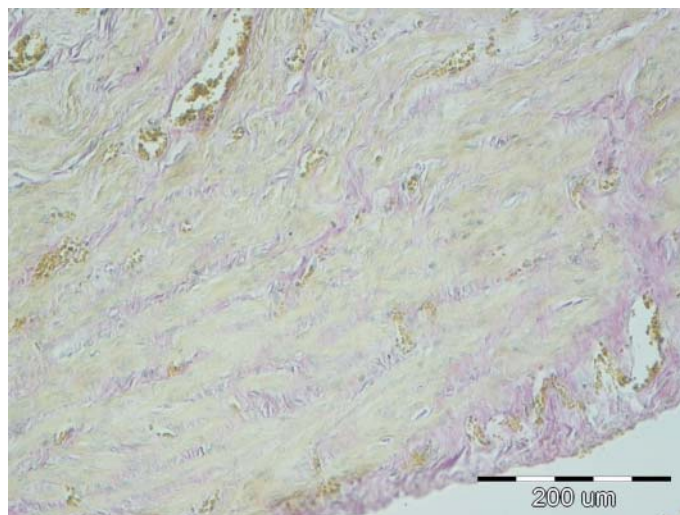


Fig. 4. Tissue found at the side of the left uterine horn. Irregular thick smooth muscle bundles stained yellow separated with a small amount of collagen fibers, stained red, and numerous blood vessels. Van Gieson,  $\times 20$ , scale bar = 200  $\mu\text{m}$ .

Although uterine horn agenesis can result in infertility (JONES et al., 1996), in this case samples collected from the right uterine horn revealed a normally developed gravid uterus with a placenta (Fig. 5). The right and left ovaries also had normal morphology, with corpora lutea present on both ovaries.

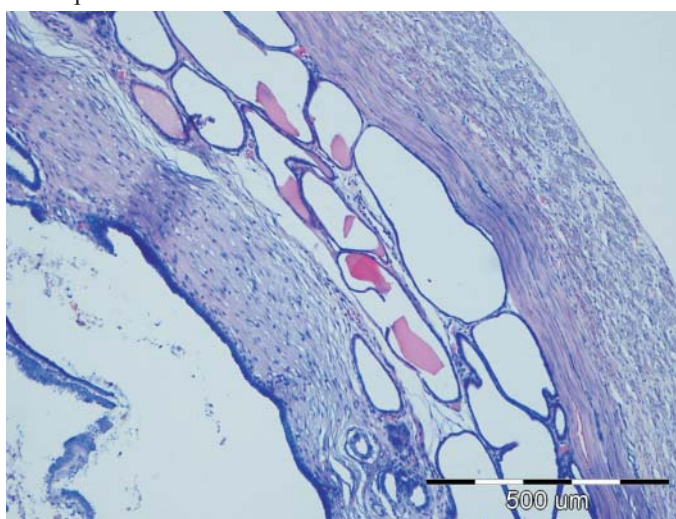


Fig. 5. Transversal section of the gravid uterine horn with placenta. Endometrium replaced with cavernous structures coated with trophoblasts; uterine glands dilated and invaginated in the inner muscular layer of the uterus. H&E,  $\times 10$ ; scale bar = 500  $\mu\text{m}$ .

### Conclusion

This is the first case described in which segmental aplasia of one and gravidity of the other uterine horn were found at the same time. Pathohistological examination confirmed the normal structure of the uterus, placentas and four fetuses in the expected stadium of development for the mid-pregnancy period. This proves that there is a real possibility for normal conception, development and delivery of the fetuses in a case of unilateral uterine horn agenesis. This is in accordance with SEYREK - INTAS et al. (2004), who showed that surgical removal of one uterine horn in bitches did not have any influence on subsequent fertility. Due to difficulties in finding the aplastic horn with a finger and its ovary we recommend visualization of the bifurcation. As the aplastic horn is smaller in diameter and much more difficult to find with a finger than in the usual procedure, in cases such as this, we recommend visualization of the uterine bifurcation.

### References

- CONCANNON, P. W., V. N. MEYERS-WALLEN (1991): Current and proposed methods for contraception and termination of pregnancy in dogs and cats. *J. Am. Vet. Med. Assoc.* 198, 1214-1225.
- ENGLAND, G. (2009): Infertility and subfertility in the bitch and queen. In: *Veterinary reproduction and obstetrics*. 9<sup>th</sup> ed. (Noakes, D. E., Parkinson, T. J., England, G. C. W., Eds.). Saunders Edinburg, London, New York, Oxford, Philadelphia, St Louis, Sydney, Toronto. pp. 647-648.
- FELDMAN, E. C., R. W. NELSON (1996): Infertility, associated breeding disorders and disorders of sexual development. In: *Canine and Feline Endocrinology and Reproduction*, 2<sup>nd</sup> ed. (Feldman, E. C., Nelson, R. W., Eds.). Philadelphia, WB Saunders. pp. 619-648.
- JOHNSTON, S. D., M. V. ROOT KUSTRITZ, P. N. S. OLSON (2001): *Canine and Feline Theriogenology*. W. B. Saunders Company. Philadelphia, London, New York, St. Louis, Sydney, Toronto. pp. 66-224.
- JONES, T. C., R. D. HUNT, N. W. KING (1996): *Veterinary Pathology*. 6<sup>th</sup> ed. Baltimore, Williams and Wilkins. pp. 1149-1221.
- McENTEE, K. (1990): The Uterus: Congenital anomalies. In: *Reproductive Pathology of Domestic Mammals*. Academic Press. San Diego, California. pp. 118-124.
- OH, K. S., C. H. SON, B. S. KIM, S. S. HWANG, Y. J. KIM, Y. J. PARK, J. H. JEONG, C. JEONG, S. H. PARK, K. O. CHO (2005): Segmental aplasia of uterine body in a adult mixed breed dog. *J. Vet. Diag. Invest.* 17, 490-492.
- PADDLEFORD, R. R. (1999): *Manual of Small Animal Anesthesia* 2<sup>nd</sup> edition. W.B. Saunders Company. pp. 12-76.
- PINTO FILHO, S. T. L., O. CUNHA, A. G. RAISER, G. S. BARBOSA, L. C. V. PORTELLA, L. F. IRIGOYEN (2001): Agenesia unilateral de corno uterino em cadela - Relato se caso. *Arq. Ciêvet. Zool. Unipar.* 4, 77-79.
- ROOT KUSTRITZ, M. V. (2003): Disorders of sexual development. In: *Small Animal Theriogenology*. Elsevier Sciences, USA. pp. 28-32.
- SCHULMAN, M. L., L. A. BOLTON (1997): Uterine horn aplasia with complications in two mixed-breed bitches. *J. S. Afr. Vet. Assoc.* 68, 150-153.
- SENGER, P. L. (1995): Embryogenesis of the pituitary gland and male or female reproductive system. In: *Pathways to Pregnancy and Parturition*. 2<sup>nd</sup> ed. Current Conceptions, Ephrata. pp. 80-87.
- SEYREK-INTAS, K., A. WEHREND, Y. NAK, H. B. TEK, G. YILMAZBAS, T. GOKHAN, H. BOSTEDT (2004): Unilateral hysterectomy (cornuectomy) in the bitch and its effect on subsequent fertility. *Theriogenology* 61, 1713-1717.
- SMITH, K. W. (1974): Female genital system. In: *Canine surgery* 2<sup>nd</sup> ed. (Archibald, J., Ed.). Santa Barbara, CA, American Veterinary Publications. pp. 751-782.
- WYKES, P. M., P. N. OLSON (1996): Moléstias do útero. In: *Mecanismo da moléstia na cirurgia de pequenos animais*. 2<sup>nd</sup> ed. (Bojrab, M. J., Ed.). São Paulo. Manole 83, 370-377.

Received: 13 October 2010

Accepted: 6 May 2011

---

**VINCE, S., B. ŽEVRNJA, A. BECK, I. FOLNOŽIĆ, D. GEREŠ, M. SAMARDŽIJA, J. GRIZELJ, T. DOBRANIĆ: Unilateral segmental aplazija materničnoga roga gravidne kuje - prikaz slučaja. Vet. arhiv 81, 691-698, 2011.**

**SAŽETAK**

Na Kliniku za porodništvo i reprodukciju Veterinarskog fakulteta Sveučilišta u Zagrebu dovedena je kuja miješane pasmine stara 1,5 godinu na kastraciju. Anamnestički podaci o reproduktivnom statusu nisu bili poznati s obzirom na to da je kuja došla iz prihvatilišta za napuštene životinje. Općim kliničkim pregledom nije utvrđen nikakav preoperativni problem. Ultrazvučnim pregledom ustanovljeno je da je kuja gravidna oko četiri tjedna. Vlasniku je predložena ovariohisterektomija kao radikalna alternativa pobačaju zbog neželjene gravidnosti. Operacija je uz pristanak vlasnika izvedena u općoj endotrahealnoj anesteziji. Prilikom izvođenja zahvata utvrđena je ageneza lijevoga materničnoga roga dok su lijevi jajnik i bubreg bili normalno razvijeni.

**Ključne riječi:** segmentalna aplazija, maternični rog, ovariohisterektomija, kuja

---