

**Histopathological changes in the stomachs of wild rodents in Croatia
and the first finding of the *Helicobacter* species
- short communication**

**Mirna Robić^{1*}, Branka Artuković², Ana Beck², Romana Turk¹,
Maja Belić¹, Ante Svetina¹, and Željko Grabarević²**

¹Department of Pathophysiology, Faculty of Veterinary Medicine, University of Zagreb, Croatia

²Department of Pathology, Faculty of Veterinary Medicine, University of Zagreb, Croatia

**ROBIĆ, M., B. ARTUKOVIĆ, A. BECK, R. TURK, M. BELIĆ, A. SVETINA,
Ž. GRABAREVIĆ: Histopathological changes in the stomachs of wild rodents in
Croatia and the first finding of the *Helicobacter* species. Vet. arhiv 81, 415-421, 2011.**

ABSTRACT

The aim of this study was to determine histopathological changes in the stomachs of wild rodents as well as the possible presence of *Helicobacter* species. Stomach samples of twenty two wild rodents of different species, captured in different regions of Croatia were examined. In all the samples examined inflammatory changes were observed, as well as bacterial and parasitic organisms. In one sample, those organisms were identified as the *Helicobacter* species since were positive when stained by the Warthin-Starry method. This is the first finding of *Helicobacter* species in wild rodents in Croatia.

Key words: *Helicobacter* spp., wild rodents, gastric histopathology

Introduction

Since WARREN and MARSHALL (1983) established the link between gastric helicobacter infection and gastritis in humans, *Helicobacter* species were intensively investigated not only in human but in veterinary medicine as well. Many species were identified in domestic and wild animals (WEBER et al., 1958; QUIEROZ et al., 1990; EATON et al., 1993; BARBOSA et al., 1995). Their role in gastric pathology is yet to be determined, since, although in most cases they cause visible histopathological changes, their clinical relevance is not yet clear.

*Corresponding author:

Dr. Mirna Robić, Department of Pathophysiology, Faculty of Veterinary Medicine, University of Zagreb, Heinzelova 55, 10000 Zagreb, Croatia, Phone: +385 1 2390 184; E-mail: mrobic@vef.hr

Literature data on the presence of *Helicobacter* species in wild rodents are scarce (GIUSTI et al., 1998; WON et al., 2002; GOTO et al., 2004; COMUNIAN et al., 2006) and histopathological changes are described only in the first of these studies.

The aim of this study was to establish histopathological changes and the presence of gastric spiral microorganisms in the stomachs of wild rodents.

Materials and methods

A total of 22 gastric samples taken from wild rodents were evaluated in this study. The species were as follows: *Mus musculus* (16), *Apodemus sylvaticus* (1), *Clethrionomys glareolus* (1), *Apodemus flavicollis* (2), *Microtus agrestis* (1), *Apodemus agrarius* (1). The samples were collected from animals captured in live traps and sacrificed, originating from different regions of Croatia (Moslavina, Turopolje, Popovača). Stomach samples were washed with saline and fixed in buffered formalin, embedded in paraffin, cut on microtome and stained with hematoxylin-eosine, toluidin blau, Giemsa and Warthin-Starry method (SHEENAN and HRAPCHAK, 1980). The number of *Helicobacter* species was determined after examination of ten high magnification fields (x40) as the mean number of bacteria.

Results

In all the stomachs examined inflammatory changes were observed in the gastric mucosa of the glandular stomach. The results are summarized in Table 1. The most frequent finding was oedema, noted in 21 samples examined. Epithelial desquamation was observed in 16 samples. Erosive gastritis was noted in five samples. Inflammatory cell infiltration was noted in all the samples examined, in four cases neutrophilic, in nine mixtocellular and in nine mononuclear infiltration was noted. In hematoxylin-eosine stained samples numerous microorganisms were seen in the gastric mucosa and lumina of the gastric glands (Fig. 2). Those microorganisms were histopathologically recognised as bacterial (13 stomachs) and parasitic (8 stomachs) organisms. In seven stomach samples bacterial and parasitic organisms were noted together. In one stomach sample *Helicobacter* species were observed on a slide stained by the Warthin-Starry method (Fig. 3). In that stomach sample, histopathological changes were consistent with chronic gastritis. *Helicobacter* species were numerous (up to 30 in a high magnification field), visible on the surface of the gastric mucosa, and in the lumina of the gastric glands. Their dimensions were from

Table 1. Histopathological changes in glandular gastric mucosa of wild rodents

Species	Desquamation	Congestion	Edema	Erosions	Infiltration	Microorganisms
1. <i>Mus musculus</i>	+	+	+	-	N	-
2. <i>Mus musculus</i>	+	+	+	+	M	-
3. <i>Mus musculus</i>	-	+	+	+	N	B
4. <i>Mus musculus</i>	-	+	+	-	MO	B,P
5. <i>Mus musculus</i>	+	-	+	-	N	B,P
6. <i>Mus musculus</i>	+	+	+	-	MO	B,P
7. <i>Mus musculus</i>	+	+	+	-	M	-
8. <i>Mus musculus</i>	+	+	+	-	M	B
9. <i>Mus musculus</i>	+	-	+	+	M	B
10. <i>Apodemus sylvaticus</i>	+	-	+	-	MO	B, P Warthin-Starry positive
11. <i>Mus musculus</i>	+	-	+	-	M	B,P
12. <i>Clethrionomys glareolus</i>	+	+	-	-	M	B
13. <i>Mus musculus</i>	-	+	+	-	MO	B,P
14. <i>Mus musculus</i>	+	+	+	-	MO	B,P
15. <i>Mus musculus</i>	-	-	+	-	M	-
16. <i>Mus musculus</i>	-	-	+	-	MO	-
17. <i>Mus musculus</i>	+	-	+	-	MO	-
18. <i>Mus musculus</i>	-	+	+	-	M	B
19. <i>Mus musculus</i>	+	-	+	-	MO	P
20. <i>Apodemus flavicollis</i>	+	-	+	-	N	B
21. <i>Microtus agrestis</i>	+	-	+	-	M	-
22. <i>Apodemus agrarius</i>	-	+	+	+	M	-

N – neutrophilic, M – mononuclear, Mo- mononuclear, B- bacteria, P – parasites

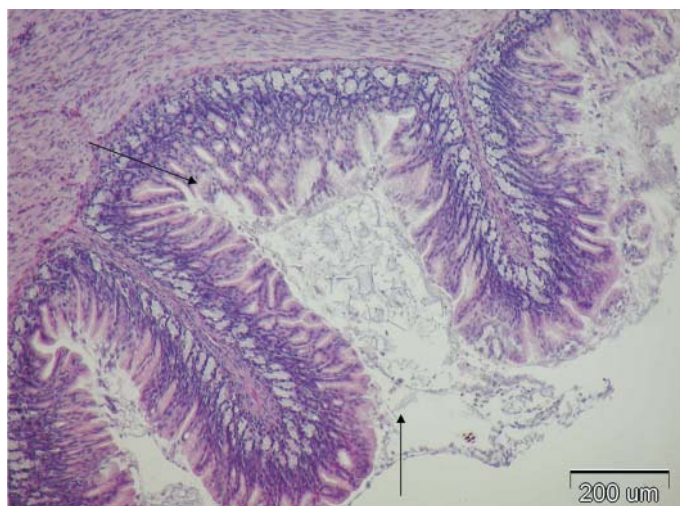


Fig. 1. Chronic inflammatory changes and abundant mucus production on the gastric surface. H&E; $\times 10$, scale bar = 200 μm

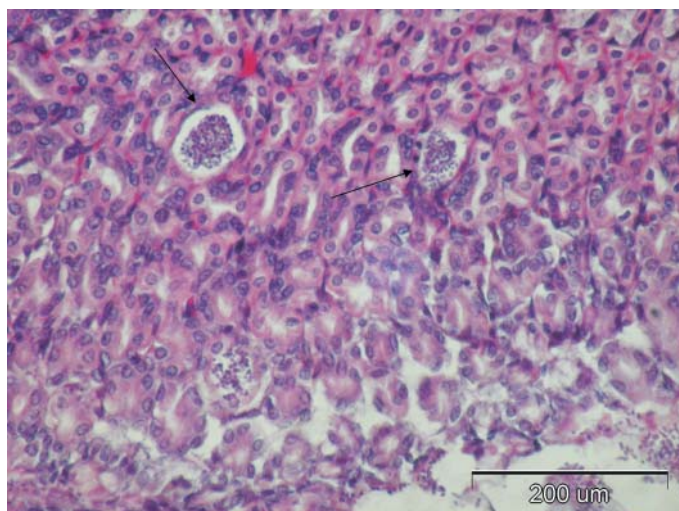


Fig. 2. Gastric glands luminal colonisation with parasitic organisms (protozoa organism). H&E, $\times 10$, scale bar = 200 μm .

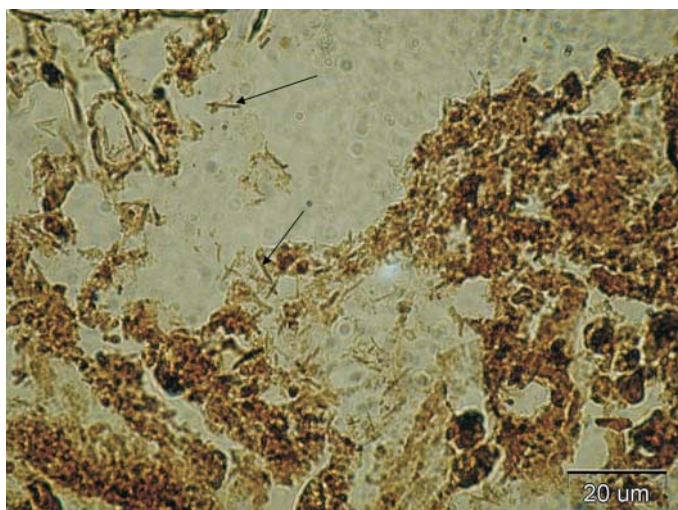


Fig. 4. Numerous *Helicobacter* organisms visible in the gastric mucosa. Warthin-Starry, $\times 100$, scale bar = 20 μm

2. 96-4.97 μm in length and 0.45-0.76 μm in width. Those *Helicobacter* species were not recognisable on slides stained with Toluidin blau nor Giemsa method.

Discussion

In all the gastric samples examined, histopathological changes were detected and described as inflammatory. In only one gastric sample were *Helicobacter* organisms seen on a Warthin-Starry stained slide. Histopathological changes in that sample were consistent with chronic gastritis, which is in accordance with the findings of GIUSTI et al. (1998) in wild rats in Italy. *Helicobacter* species have been found in wild rodents in Brazil, Korea and China, but in those studies histopathological changes in stomachs and the morphology of the *Helicobacter*s were not described since their presence was determined through PCR analysis of gastric and colon samples (COMUNIAN et al., 2006) or caeca and faeces (WON et al., 2002) and only faeces (GOTO et al., 2004). It is not possible to conclude whether the histopathological changes in the stomach sample of the rodent positive for *Helicobacter* organisms in our study were the consequence of that infection, since mixed bacterial infection and parasites were also found in that stomach sample. Also, in the stomach samples negative for *Helicobacter* species, inflammatory changes of similar morphology were noted, which may possibly be attributed to other microorganisms and gastric parasites. As for the staining methods used, it is important to note that the Warthin-Starry method is the only reliable method for *Helicobacter* species histopathological

detection in the stomachs of wild rodents, since there were numerous bacterial organisms visible in the stomach samples from our study, which did not stain positively by Warthin-Starry. Furthermore, the *Helicobacter* species recognized by Warthin-Starry were not recognisable when stained with Giemsa or Toluidin blau, which are methods used for detection of Helicobacter-like organisms in dogs (ROBIĆ et al., 2007). There is only one report of Helicobacter infection in wild rodents, but those rodents were of different species (*Brachiones przewalskii*, *Dipus sagitta*, *Euchoreutes naso*, *Meriones meridianus*, *Neskia indica*, *Rhodomys opimus*) and the investigation was performed in China. It is important to notice that this is the first report of the presence of *Helicobacter* species in wild rodents in Croatia and also that this is the first investigation of gastric histopathology of wild rodents in Croatia .

References

- BARBOSA, A. J. A., J. C. P. SILVA, A. M. M. F. NOUGEIRA, E. PAULINO Jr, C. R. MIRANDA (1995): Higher incidence of *Gastrospirillum* sp. in swine with gastric ulcer of the pars oesophagea. *Vet. Pathol.* 32, 134-139.
- COMMUNIAN, L. B., I. B. MOURA, A. P. PAGLIA, R. N. NICOLI, J. B. GUERRA, G. A. ROCHA, D. M. M. QUEIROZ (2006): Detection of *Helicobacter* species in the gastrointestinal tract of wild rodents from Brazil. *Curr. Microbiol.* 53, 370-373.
- EATON, K. A., M. J. RADIN, L. KRAMER, R. WACK, R. SHREDING, S. KRAKOWKA, J. G. FOX, D. R. MORGAN (1993): Epizootic gastritis associated with gastric spiral bacilli in cheetas (*Acinonyx jubatus*). *Vet. Pathol.* 30, 55-63.
- GIUSTI, A. M., L. CRIPPA, O. BELLINI, M. LUINI, E. SCANZIANI (1998): Gastric spiral bacteria in wild rats from Italy. *J. Wildl. Dis.* 34, 68-72.
- GOTO, K., W. JIANG, Q. ZHENG, Y. OKU, H. KAMIYA, T. ITOH, M. ITO (2004): Epidemiology of *Helicobacter* infection in wild rodents in the Xinjiang-Uyghur autonomous region of China. *Curr. Microbiol.* 49, 221-223.
- QUIEROZ, D. M., G. A. ROCHA, E. N. MENDES, A. P. LAGE, A. C. T. CARVALHO, A. J. A. BARBOSA (1990): A spiral microorganism in the stomach of pigs. *Vet. Microbiol.* 24, 199-204.
- ROBIĆ, M., B. ARTUKOVIĆ, A. BECK, A. GUDAN, A. SVETINA and Ž. GRABAREVIĆ (2007): Histopathological changes in stomach of dogs with naturally acquired *Helicobacter* infection. *Vet. arhiv* 77, 103-111.
- SHEENAN, D. C., B. B. HRAPCHAK (1980): *Theory and Practice of Histotechnology*. Batelle Press, Columbus, Richland.
- WARREN, J. R., B. MARSHALL (1983): Unidentified curved bacilli on gastric epithelium in active chronic gastritis. *Lancet* 1, 1273-1274.
- WEBER, A. F., O. HASA, J. H. SAUTTER (1958): Some observations concerning the presence of spirilla in the fundic glands of dogs and cats. *Am. J. Vet. Res.* 19, 677-680.

M. Robić et al.: Histopathological changes in the stomachs of wild rodents in Croatia and the first finding of the *Helicobacter* species

WON, Y. S., J. H. YOON, C. H. LEE, B. H. KIM, B.H. HYUN, Y. K. CHOI (2002): *Helicobacter muricola* sp. Nov., a novel *Helicobacter* species isolated from the ceca and feces of Korean wild mouse (*Mus musculus molossinus*). FEMS Microbiol. Lett. 209, 45-51.

Received: 2 April 2010

Accepted: 17 March 2011

ROBIĆ, M., B. ARTUKOVIĆ, A. BECK, R. TURK, M. BELIĆ, A. SVETINA, Ž. GRABAREVIĆ: Patohistološke promjene u želučanom tkivu divljih glodavaca iz Hrvatske i prvi nalaz vrsta roda *Helicobacter* - kratko priopćenje. Vet. arhiv 81, 415-421, 2011.

SAŽETAK

Cilj ovog istraživanja bio je odrediti patohistološke promjene u želucima divljih glodavaca i moguću prisutnost vrsta roda *Helicobacter*. Pregledani su uzorci želuca dvadeset i dva divlja glodavca različitih vrsta, koji su uhvaćeni u različitim dijelovima Hrvatske. U svim pregledanim uzorcima ustanovljene su upalne promjene, te bakterije i paraziti. U jednom uzorku želuca te su bakterije na temelju pozitivne reakcije pri bojenju metodom Warthin-Starry identificirane kao *Helicobacter* spp. Ovo je prvi nalaz vrsta roda *Helicobacter* u divljih glodavaca u Hrvatskoj.

Ključne riječi: *Helicobacter* spp., divlji glodavci, patohistološke promjene, želudac
