

## Lesion scoring technique for assessing the virulence and pathogenicity of Indian field isolates of avian *Eimeria* species

Muthusamy Raman<sup>1\*</sup>, Samsudeen S. Banu<sup>1</sup>, Sankaralingam Gomathinayagam<sup>1</sup>,  
and Gopal D. Raj<sup>2</sup>

<sup>1</sup>Department of Veterinary Parasitology, Madras Veterinary College, Tamil Nadu Veterinary and Animal Sciences University (TANUVAS), Chennai, India

<sup>2</sup>Department of Animal Biotechnology, Madras Veterinary College, Tamil Nadu, Veterinary and Animal Sciences University (TANUVAS), Chennai, India

---

**RAMAN, M., S. S. BANU, S. GOMATHINAYAGAM, G. D. RAJ: Lesion scoring technique for assessing the virulence and pathogenicity of Indian field isolates of avian *Eimeria* species. Vet. arhiv 81, 259-271, 2011.**

### ABSTRACT

Chicken coccidiosis caused by the genus *Eimeria* is a major health impediment causing high morbidity and mortality in commercial poultry. Assessment of the virulence and pathogenicity of *Eimeria* species are the vital factors for formulating effective control strategies. The gross lesion score was used in this study for assessing the virulence and pathogenicity of indigenous six *Eimeria* sp. in a controlled experimental trial using six groups of one hundred and twenty chicks of three weeks of age, inoculated with  $2 \times 10^2$  to  $2 \times 10^3$  numbers of oocysts of six species of *Eimeria*. While an extended prepatent period (2 - 6 hrs) was confirmed in the majority of the species, the gross lesion scores were mostly within the low score of 1-2 compared to the international reference strains such as Houghton, so indicating possible natural attenuation of the field isolates. The gross lesion scores (GLS) were assessed ranging from a scale of 0 (no gross lesion) to 4 (most severe lesion). This study seems to be the first such attempt to standardize a lesion scoring technique for assessing the virulence and pathogenicity of indigenous isolates of *Eimeria* in the Indian sub-continent.

**Key words:** chickens, *Eimeria*, assessment, virulence, prepatent period, gross lesion score

---

### Introduction

The poultry industry in India has grown in leaps and bounds from a mere backyard to a mammoth industry with a staggering 220 million layers and 80 million broilers (ANONYM., 2004). Of the infectious diseases, chicken coccidiosis caused by obligatory intracellular apicomplexan protozoa viz. *Eimeria*, is one of the economically important

---

\*Corresponding author:

Dr. Muthusamy Raman, M.V.Sc., Ph.D., Principal Investigator and Associate Professor, Department of Veterinary Parasitology, Madras Veterinary College, TANUVAS, Chennai 600 007, India, Phone: +91 44 2538 1506; Fax : +91 44 2536 2787; E-mail: ramapara@gmail.com

enteric-protozoan parasites affecting millions of commercial poultry. Assessment of the virulence and pathogenicity of various field isolates of *Eimeria* is an important component for control of chicken coccidiosis (LONG et al., 1976). As the authors as a team had been recently given the task of developing the first indigenous vaccine against chicken coccidiosis, it was felt that assessing of the virulence and pathogenicity of field isolates of *Eimeria* species collected from commercial broiler and layer birds would be a critical step before inclusion of the above isolates in the vaccinal strain (CHAPMAN, 2004).

As the biological features of the Eimerial parasite are highly specific, such as the prepatent period, development within the intestine, type of lesion (METTIELLO et al., 2000) and the morphological appearance of various endogenous stages in the mucosa of the intestine, the lesion scoring technique (LST) gained more significance in confirmation (SCHNITZLER et al., 1998) and accurate diagnosis of chicken coccidiosis (CONWAY and McKENZIE, 1991).

Based on the above, the LST is considered suitable for detecting the site specific relative gross lesions in various parts of intestines affected with the *Eimeria* species. The currently available lesion scoring technique, standardized for inbred or pure lines of chicken in European countries cannot be taken as a reference for Indian Eimerian isolates. This is due to the fact that chicken of different genetic makeup are reared under different selection pressures and management practices in India. Hence an attempt was made to standardize one such LST for Indian isolates of avian *Eimeria* to assess their virulence and pathogenicity. This work was carried out as part of the Department of Biotechnology, Govt. of India funded project to develop a multivalent oral vaccine against chicken coccidiosis, using local isolates.

### Materials and methods

**Maintenance of chicks.** One hundred and twenty day-old broiler chicks obtained from the Poultry Research Station, Tamil Nadu Veterinary and Animal Sciences University, Chennai, were maintained in coccidia free elevated cages. They were separated into six groups of 20 chicks in each group, representing the six species of *Eimeria* sp., and were maintained until 4-6 weeks of age. The chicks were fed with coccidiostat- free- broiler mash with all other ingredients and were given water *ad libitum* throughout the whole experiment.

**Inoculation of oocysts.** *Eimeria* oocysts collected from different locations of Southern India were sporulated and enumerated (Table 1). In each group, five chicks were inoculated with  $2 \times 10^2$  to  $2 \times 10^3$  oocysts, thus four different field isolates of a single *Eimeria* species were inoculated with six *Eimeria* species on days 18 and 36 (Table 2) as per ECKERT et al. (1995), and were examined for the prepatent period and gross post mortem lesions at regular intervals. Three chicks in each group were sacrificed randomly when the birds

started showing clinical signs, from 72 hours up to 120 hours in some species of *Eimeria*, to assess the status of infection and virulence by lesion scoring technique.

Table 1. Field isolates of avian *Eimeria* from Southern India used for the study

Sl. No.	Name of the species	Location	State
1	<i>E. acervulina</i>	Namakkal	Tamil Nadu
		Udumalpet	Tamil Nadu
		V. Kota	Andhra Pradesh
		Nellore	Andhra Pradesh
2	<i>E. brunetti</i>	Namakkal	Tamil Nadu
		Tirupur	Tamil Nadu
		Nellore	Andhra Pradesh
		Cuddalore	Tamil Nadu
3	<i>E. maxima</i>	Chittoor	Andhra Pradesh
		Bangalore	Karnataka
		Namakkal	Tamil Nadu
		V. Kota	Andhra Pradesh
4	<i>E. necatrix</i>	Madurai	Tamil Nadu
		Namakkal	Tamil Nadu
		Nellore	Andhra Pradesh
		Udumalpet	Tamil Nadu
5	<i>E. mitis</i>	Bangalore	Karnataka
		Namakkal	Tamil Nadu
		V. Kota	Andhra Pradesh
		Nellore	Andhra Pradesh
6	<i>E. tenella</i>	Coimbatore	Tamil Nadu
		Bangalore	Karnataka
		V. Kota	Andhra Pradesh
		Nellore	Andhra Pradesh

*Assessment of gross lesion score.* The prepatent period was assessed for various species of *Eimeria* sp. based on the day of excretion of the oocyst after inoculation. The gross lesion scores (GLS) were assessed using the criteria of JOHNSON and REID (1970) with the scores ranging from a scale of 0 (no gross lesion) to 4 (most severe gross lesion). Various portions of the intestines (anterior, middle, posterior, including caecal loop) were collected, slit open and preserved in 10% buffered formalin. The organ segments were routinely processed in paraffin, sectioned parallel to the cut edge and stained with haematoxylin and eosin stain for the histological examination (CONWAY and McKENZIE, 1991). The deep scrapings of the affected intestinal serosa and mucosa,

as well as the intestinal contents, were examined by light microscope (Leica research binocular microscope, Germany) at the sites of petechiae, plaques and some other lesions (LONG et al., 1976).

Table 2. Inoculum dose and prepatent period of various *Eimeria* species in experimental chicken

S. No.	Name of the species	Dose of oocysts per chick	Prepatent period (in hrs) (Present study)	Prepatent period (in hrs) (Eckert et al., 1995)	Site of development
1	<i>Eimeria acervulina</i>	$2.0 \times 10^3$	96	89	Small intestine (duodenum)
2	<i>Eimeria brunetti</i>	$2.0 \times 10^3$	122	120	Small intestine, caeca and rectum
3	<i>Eimeria maxima</i>	$2.5 \times 10^2$	120	120	Small intestine (middle part)
4	<i>Eimeria mitis</i>	$2.0 \times 10^3$	96	91	Small intestine (middle part)
5	<i>Eimeria necatrix</i>	$2.0 \times 10^3$	142	138	Small intestine
6	<i>Eimeria tenella</i>	$5.0 \times 10^3$	138	132	Caeca

In the current study, the lesion scoring of JOHNSON and REID (1970) was made as a baseline for assessing the gut lesions from the anterior, middle, posterior and caecal loops of chickens infected with various species of *Eimeria*. Thus, the following scoring system was standardized for a scale of 0 to 4 for chicks infected with *E. tenella* (DUFFY et al., 2005).

A score of "0" was given for intestines without any gross lesions;

- +1 Few petechiae in the cecal wall with the presence of normal contents
- +2 Mild ballooning with thickened cecal wall and bloody contents at the proximal end (Fig.1.1.)
- +3 Moderate ballooning of caecal loops with caecal core (Fig.1.2.)
- +4 Complete ballooning and distension of caecum packed with caseous cores (Fig.1.3.)

The following scoring system was standardized for chicks infected with *E. necatrix*.

- +1 Scattered petechiae and white spots observed on the serosa of intestine;
- +2 Ballooning of mid gut portion (Fig. 2.1.);
- +3 Pin point haemorrhages in the serosa with ballooning up to the lower part of the small intestine (Fig. 2.2.);
- +4 Massive haemorrhage with brownish mucus contents; complete ballooning of the mid intestine.

The scoring system for chicks infected with *E. acervulina* standardized for a scale of 0 to 4 was:

- +1 Scattered petechiae in the anterior intestine (duodenum) with lesions extending along the axis of the intestinal wall (Fig. 3.1.);
- +2 Vast lesions extending up to end of the mid intestine beyond duodenum (Fig. 3.2.);
- +3 Intestine has grayish coated appearance with thickened wall containing watery contents
- +4 the entire mucosa may be bright red with typical ladder like lesions in the mid intestine. The intestine is filled with creamy contents.

Similarly, the following scoring system for chicks infected with *E. maxima* was standardized as follows:

- +1 Small amount of orange slimy mucus present (Fig. 4.1.);
- +2 Intestine filled with orange mucus and the wall of the intestines thickened without ballooning (Fig. 4.2.);
- +3 Thickening of intestinal wall with mucus;
- +4 Ballooning of whole intestine with putrid odour of contents.

Likewise, the following scoring system was standardized for a scale of 0 to 4 for chicks infected with *E. brunetti*:

- +1 Stagnation of faecal contents with mild ballooning of intestine (Fig. 5.1.);
- +2 Slightly greyish intestinal wall, thickening of lower intestine with flecks of salmon colour material sloughed off the intestine;
- +3 Moderate thickening of intestinal wall with blood tinged catarrhal exudates; Transverse red. Streaks markedly visible in lower rectum (Fig. 5.2.);
- +4 Severe lesions extending up to the middle intestine.

## Results

The evaluation of the severity of gross lesions is usually the easiest method of assessment of the status of the infection in experimental chickens, because of the known factors, such as the oocyst dose etc. In the present study, it was obvious that the most species of *Eimeria* produced observable gross changes in the intestine with the confirmed presence of various developmental stages in the mucosa of the intestine.

In the present study, the birds exposed to  $2 \times 10^2$  *E. tenella* oocyst had gross lesions even when sacrificed on day 6, which provided a true representation of the severity of the infection as normally found in broiler flocks.

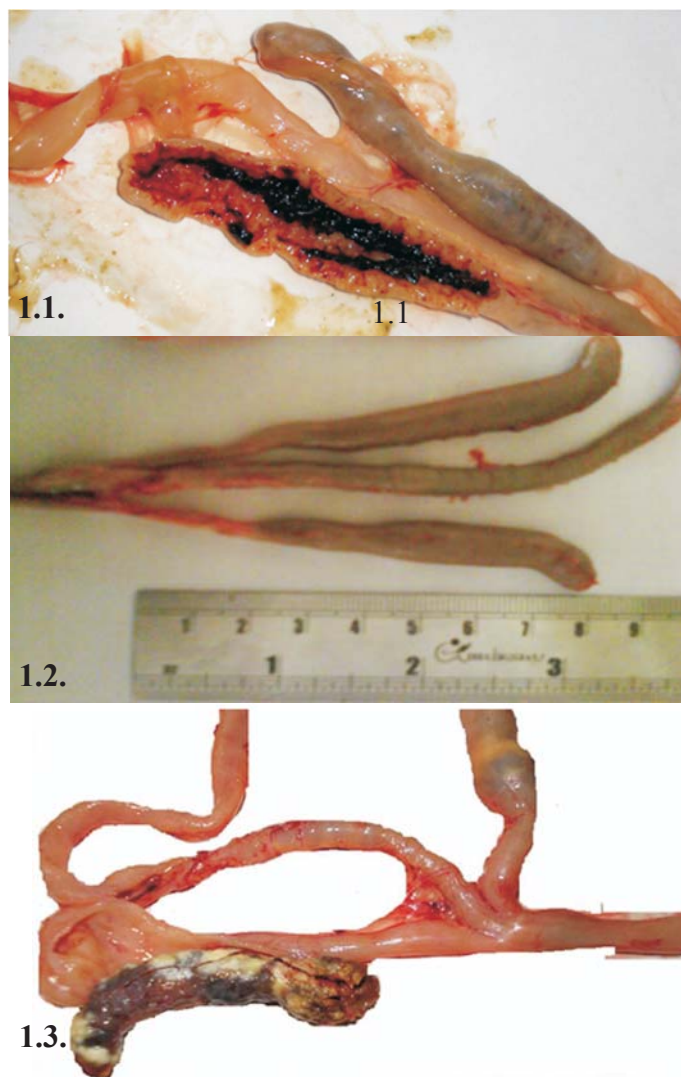


Fig. 1. Descriptive lesions in *Eimeria tenella*. Fig. 1.1. Mild ballooning with thickened cecal wall and bloody contents at the proximal end (+2); Fig.1.2. Moderate ballooning of caecal loops with caecal core (+3); Fig. 1.3. Complete ballooning and distension of caecum packed with caseous cores (+4).

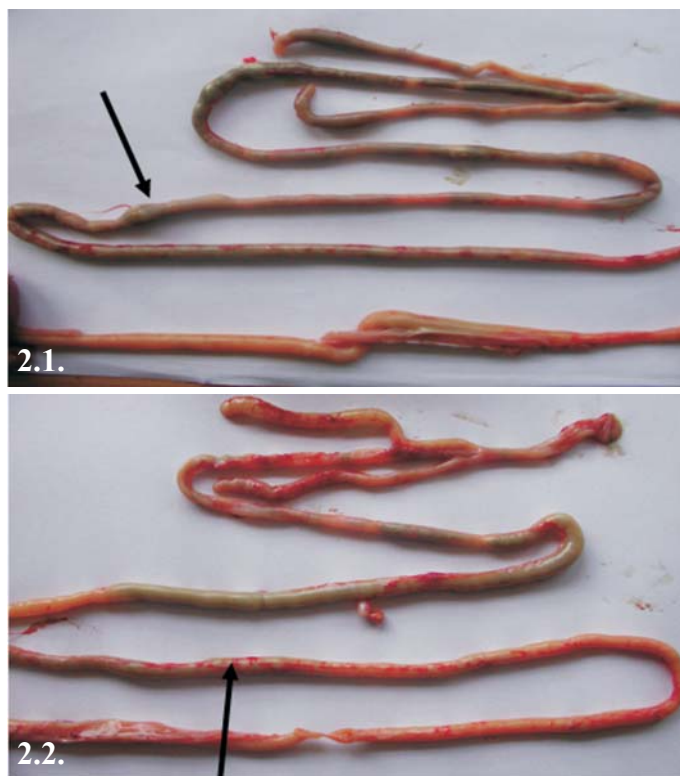

Fig. 2. Descriptive lesions in *Eimeria necatrix*. 2.1. Ballooning of mid intestine as seen through serosa, 2.2. Pin point haemorrhages in the serosa.

The lesions for *E. necatrix* were invariably found to be mild to moderate in spite of the varying number of oocysts in most birds sacrificed during the different phases of patency. This could be attributed to the possibility of the more natural attenuation of the species as it occurs in egg laying layers and backyard poultry (SHIRLEY and MILLARD, 1986).

It was observed in the investigation that *E. acervulina*, *E. maxima* and *E. brunetti* occupied a much greater area beyond the typical restricted sites of their development, which could be explained by the passive migration of merozoites due to the peristaltic waves of the intestine beyond the infected areas in heavy infection, as reported by WILLIAMS (2001).

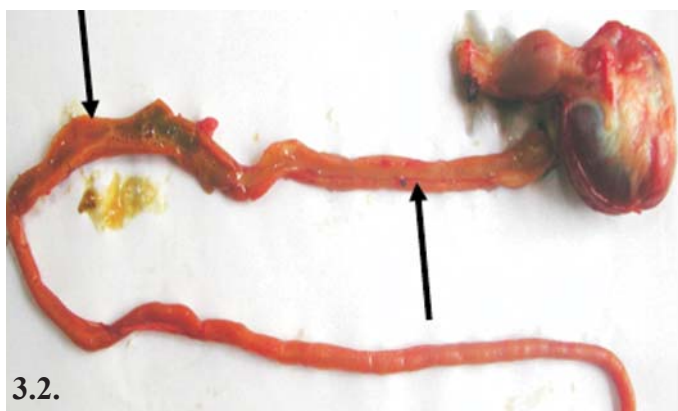
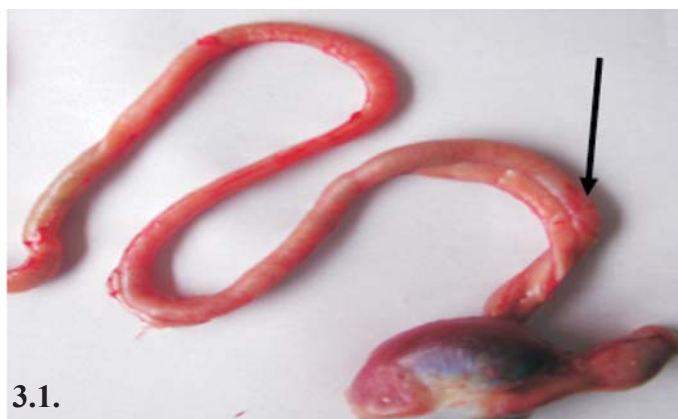
Fig. 3. Descriptive lesions in *Eimeria acervulina*. 3.1. Scattered petechiae and ballooning of the anterior intestine as seen through serosa; Lesions extending up to end of mid intestine beyond duodenum.



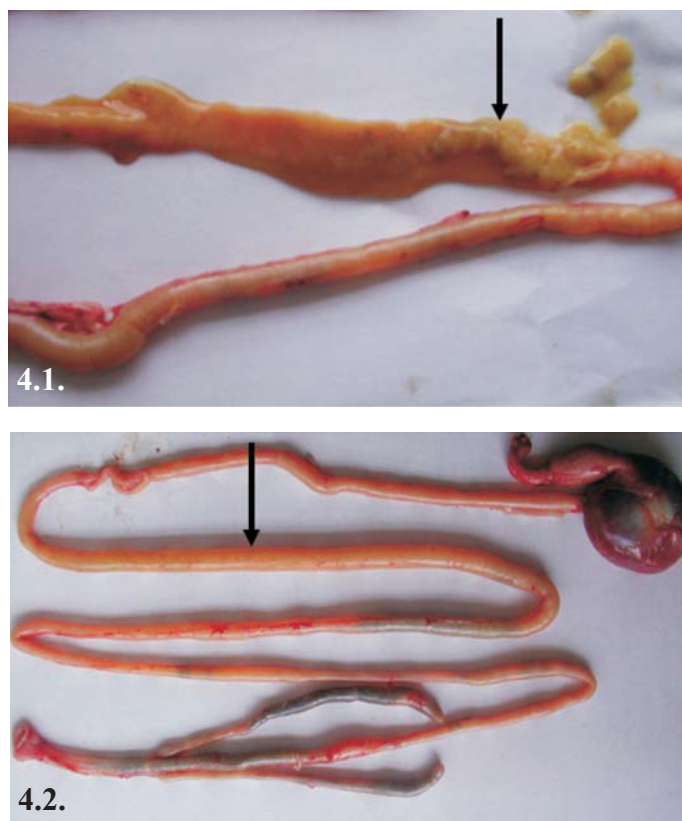


Fig. 4. Descriptive lesions in *Eimeria maxima*. 4.1. Intestine filled with orange mucous and thickening of wall; 4.2. Thickening of mid-intestine wall without ballooning.

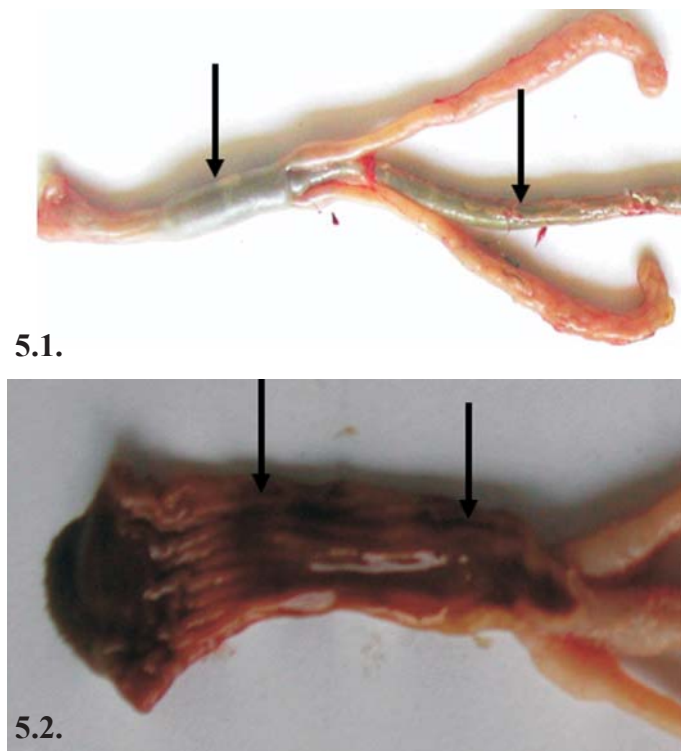


Fig. 5. Descriptive lesions in *Eimeria brunetti*. 5.1. Stagnation of faecal contents with mild ballooning of intestine; 5.2. Transverse red streaks markedly visible in lower rectum.

### Discussion

CONWAY et al. (1990) demonstrated that lesion scores provided a measure of parasite infection and associated gross lesions. They added that lesion scores did not measure nor could they possibly show the pathophysiological changes related to weight gain. However, the histopathological evaluation of the caecal segments done at 60 hrs after pi revealed 30% or more diffuse or moderate infections in spite of the lack of gross lesions. GOODWIN (1994) emphasized the need for the superior diagnostic testing in the absence of gross lesions in gastrointestinal tracts, outlining the different diagnostic protocols in pallor chicks, such as histopathology apart from culling, cultures and other laboratory investigations. In the present study, lesion scores observed in most of the local strains of chicken were usually low (+2) with overlapping lesions in the anterior, middle and posterior parts of the intestines. Hence, it was very difficult to assess virulence and

pathogenicity using standard lesion score parameters in the above groups of chicken (GARI et al., 2008).

McDOUGALD et al. (1987), during a study of the sensitivity of drugs to coccidia in Brazil, reported that even though most of the isolates of *E. acervulina*, *E. maxima*, *E. tenella*, *E. brunetti* and *E. mitis* produced gross lesions very close to the description by JOHNSON and REID (1970), some of the isolates of the different species caused indistinct lesions, for which speciation was confirmed by microscopic examination of the oocysts and other endogenous stages. The prepatent period of most *Eimeria* species, as assessed in the present study, was very similar to ECKERT et al. (1995) with minor deviations, which could be due to variations characteristic or typical to the local isolates (RAMAN et al., 2005). The extended prepatent period in most of the species could be attributed to the wild nature of the field isolates (McDOUGALD et al., 1987). This investigation further confirmed the significance of LST as an assessment tool to evaluate the virulence and pathogenicity of field isolates of the *Eimeria* species (CONWAY et al., 1990).

Definitive identification of the *Eimeria* species in chicken requires a combination of different methods (SHIRLEY and MILLARD, 1986). In this study, we used lesion scoring technique along with the prepatent period and other clinical signs. As the main scope of this study was to investigate the virulence and pathogenicity of the various field isolates in Tamil Nadu and the neighbouring south Indian states, to assess their potential as vaccinal strains, the LST was used as a tool. The scoring system standardized in the present study would be very useful for a comparative analysis of the local strains for their virulence and pathogenicity.

---

#### Acknowledgements

The senior author is grateful to Department of Biotechnology, Ministry of Science and Technology, Government of India, New Delhi (Scheme code No.BT/PR7275/AAQ/01/278/2006) for their financial assistance and the Dean, Madras Veterinary College, Chennai for the facilities provided.

#### References

- ANONYMOUS (2004): All India Poultry Business Directory (year book) 2003-04 special millennium issue, Sadana Publishers, pp. 59-388.
- CHAPMAN, H. D. (2004): Review article: Walter T. Johnson (1892 to 1937): pioneer of coccidiosis research in the fowl. *Avian Pathol.* 33, 107-116.
- CONWAY, D. P., M. E. McKENZIE (1991): Examination of lesions and lesion scoring. In: *Poultry Coccidiosis - Diagnostic and Testing Procedures*, 2<sup>nd</sup> ed. Pfizer Inc., New York. pp.17-36.
- CONWAY, D. P., E. M. McKENZIE, A. D. DAYTON (1990): Relationship of coccidial lesion scores and weight gain in infections of *Eimeria*. *Avian Pathol.* 19, 489-496.

M. Raman et al.: Lesion scoring technique for assessing the virulence and pathogenicity of avian *Eimeria* species

- DUFFY, C. F., G. F. MATHIS, R. F. POWER (2005): Effects of Natusat™ supplementation on performance, feed efficiency and intestinal lesion scores in broiler chickens challenged with *Eimeria acervulina*, *E. maxima* and *E. tenella*. *Vet. Parasitol.* 130, 185-190.
- ECKERT, J., R. BRAUN, M. W. SHIRLEY, P. COUDERT (1995): COST 89/820 Biotechnology: Guidelines on techniques in coccidiosis research, European commission, Agriculture Biotechnology, Luxemburg L 2920, pp. 1-190.
- GARI, G., G. TILAHUN, Ph. DORCHIES (2008): Study on poultry coccidiosis in Tiyo district, Arsi Zone, Ethiopia. *Int. J. Poult Sci.* 7, 251-256.
- GOODWIN, M. A. (1994): Differential diagnosis of gastrointestinal disease in broilers. *Poult. Digest.* 8-19.
- IDRIS, A. B., D. I. BOUNOUS, M. A. GOODWIN, J. BROWN, E. A. KRUSHINSKIE (1997): Lack of correlation between microscopic lesion scores and gross lesion scores in commercially grown broilers examined for small intestinal *Eimeria* sp. *Coccidiosis. Avian Dis.* 41, 388-391.
- JOHNSON, J., W. M. REID (1970): Anticoccidial Drugs: Lesion scoring techniques in battery and floor-pen experiments with chicken. *Exp. Parasitol.* 28, 30-36.
- LONG, P. L., B. J. MILLARD, L. P. JOYNER, C. C. NORTON (1976): A guide to the laboratory techniques used in the study and diagnosis of avian coccidiosis. *Folia Vet. Lat.* 6, 201-217.
- McDOUGALD, L. R., J. M. DA SILVA, S. J. BRAGA (1987): A survey of sensitivity to anticoccidial drugs in 60 isolates of coccidia from broiler chickens in Brazil and Argentina. *Avian Dis.* 31, 287-292.
- METTIELLO, R., J. D. BOVIEZ, L. R. McDOUGALD (2000): *Eimeria brunetti* and *E. necatrix* in chickens of Argentina and confirmation of seven species of *Eimeria*. *Avian Dis.* 44, 711-714.
- RAMAN, M., V. GOWTHAMAN, R. MAHAPRABHU, T. ANNA, T. J. HARIKRISHNAN (2005): Avian chorio-allantoic membrane-an *in-ovo* model for detection anticoccidial drug resistance. *Indian. J. Anim. Sci.* 75, 5-7.
- SCHNITZLER, B. E., P. L. THEBO, J. G. MATTSSON, F. M. TOMLEY, M. W. SHIRLEY, A. UGGLA (1998): Diagnosis of poultry *Eimeria*: from Lesion scoring to nucleotide sequences. *Parasitol. Int.* 47, 71-95.
- SHIRLEY, M. W., B. J. MILLARD (1986): Studies on the immunogenicity of seven attenuated lines of *Eimeria* given as a mixture to chickens. *Avian Pathol.* 15, 629-638.
- WILLIAMS, R. B. (2001): Quantification of the crowding effect during infections with the seven *Eimeria* species of the domesticated fowl: its importance for experimental designs and the production of oocyst stocks. *Int. J. Parasitol.* 31, 1056-1069.

Received: 16 September 2009

Accepted: 21 December 2010

---

**RAMAN, M., S. S. BANU, S. GOMATHINAYAGAM, G. D. RAJ: Bodovanje jačine patoanatomskih promjena za procjenu virulencije i patogenosti indijskih terenskih izolata ptičjih vrsta roda *Eimeria*. Vet. arhiv 81, 259-271, 2011.**

**SAŽETAK**

Kokcidioza uzrokovana vrstama roda *Eimeria* jedna je od glavnih prijetnji za zdravlje pilića, jer može uzrokovati njihov veliki pobol i pomor. Procjena virulencije i patogenosti vrsta roda *Eimeria* od velike je važnosti za donošenje učinkovitih kontrolnih mjera. Bodovanje jačine patoanatomskih promjena rabljeno je za procjenu virulencije i patogenosti šest udomaćenih vrsta roda *Eimeria* u kontroliranim pokusima na šest skupina pilića. U svakoj skupini bilo je 120 pokusnih pilića u dobi od tri tjedna. Pilići su bili zaraženi s  $2 \times 10^2$  do  $2 \times 10^3$  oocista šest vrsta *Eimeria*. Potvrđen je produženi prepatentni period (2 - 6 sati) za većinu vrsta, a patoanatomske promjene procijenjene su većinom s malim brojem bodova i to 1 - 2 u usporedbi s međunarodnim referentnim sojevima poput soja Houghton. To upozorava na moguću prirodnu oslabljenost terenskih izolata. Patoanatomske promjene bile su procijenjene na skali od 0 (bez promjena) do 4 (jako teške promjene). Ovo je istraživanje prvi pokušaj standardizacije bodovanja jačine patoanatomskih promjena za procjenu virulencije i patogenosti izvornih izolata vrsta roda *Eimeria* na Indijskom potkontinentu.

**Ključne riječi:** pilići, *Eimeria* spp., virulencija, prepatentni period, bodovanje, jačina patoanatomskih promjena

---

