

## Histopathological alterations induced after oral sub-acute thiacloprid toxicity in *Gallus domesticus*

Saloni Goyal<sup>1</sup>, Harpal S. Sandhu<sup>1\*</sup>, and Rajinder S. Brar<sup>2</sup>

<sup>1</sup>Department of Veterinary Pharmacology and Toxicology, Guru Angad Dev Veterinary and Animal Sciences University Ludhiana, Punjab, India

<sup>2</sup>Department of Veterinary Pathology, College of Veterinary Science, Guru Angad Dev Veterinary and Animal Sciences University Ludhiana, Punjab, India

---

**GOYAL, S., H. S. SANDHU, R. S. BRAR: Histopathological alterations induced after oral sub-acute thiacloprid toxicity in *Gallus domesticus*. Vet. arhiv 80, 673-682, 2010.**

### ABSTRACT

Repeated oral administration of 10 mg/kg/day thiacloprid, a neonicotinoid insecticide, for 28 consecutive days in *Gallus domesticus*, resulted in significant changes in the gross morphology of liver, lungs and intestine but no alterations in the kidneys, brain, heart and ovaries. Histopathologically significant alterations in the liver were observed, such as mild fatty changes, congestion and degeneration of hepatocytes. Alterations in the histoarchitecture of the kidneys included marked congestion, tubular cell degeneration and sloughing of epithelial cells. The cerebral hemisphere revealed changes comprising of mild neuronal degeneration with surrounding glial cells, satellitosis and vacuolation. Mild congestion and haemorrhage was observed in the lungs and myocardial tissues following oral administration of thiacloprid. No adverse effect on the ovarian histoarchitecture and thus the reproductive performance of *Gallus domesticus* was seen. The oral sub-acute toxicity study of thiacloprid revealed that this neonicotinoid insecticide is of moderate risk in *Gallus domesticus*.

**Key words:** *Gallus domesticus*, thiacloprid, neonicotinoid, histopathology

---

### Introduction

The use of insecticides in agriculture in recent years has increased tremendously and overshadowed all other control measures as means of crop protection. However, their use in agriculture and veterinary practices has also been associated with numerous health problems in man and animals (BENBROOK, 1991). Some of the major problems linked to excessive and indiscriminate insecticide use are the presence of residues in food and feed commodities, environmental pollution, insecticide resistance and insect resurgence

---

\*Corresponding author:

Dr. H. S. Sandhu BVSc & AH, MVSc, PhD, Professor, Department of Veterinary Pharmacology and Toxicology, College of Veterinary Science, Guru Angad Dev Veterinary and Animal Sciences University, Ludhiana- 141004, Punjab, India, Phone: +0161 2414 032; E-mail: harpal\_707@yahoo.co.in

(SANBORN et al., 2002). Among the various problems associated with pesticide use is the possibility of its biological accumulation in animal products such as milk, meat and egg, which are consumed by human beings (KUTCHES et al., 1970).

Thiacloprid is a new neonicotinoid insecticide that belongs to a new group of active ingredients, the cyanoamidines, and is effective on contact and via stomach action. It produces its action by binding agonistically to the nAChRs in the CNS of insects (LIU and CASIDA, 1993; ZHANG et al., 2000). It opens the ion pores of the receptor to induce a depolarization of nerve cell membrane that triggers an action potential and abnormal excitement in the insect by interrupting the normal synaptic transmission. This mode of action is unique to the neonicotinoids, so cross-resistance to conventional insecticides is non-existent. Exposure of poultry to pesticides often results in numerous health hazards and economic losses, in addition to posing a threat to public health, due to the presence of pesticide residues in poultry meat (HISASHI et al., 2006; ELLIS, 1989). The data on histopathological changes induced due to repeated exposure to thiacloprid are lacking and, as birds are more sensitive to xenobiotics as compared to mammals because of their relatively small liver and rapid food intake (ANAM and MAITRA, 1995), the present study was undertaken to investigate the effect of 28 days administration of sublethal doses of thiacloprid on histopathology of *Gallus domesticus*.

### **Materials and methods**

The present study was conducted on one and half year old layer *Gallus domesticus*. The birds were procured and housed in pens at the Layer House of the Poultry Farm, Guru Angad Dev Veterinary and Animal Sciences University, Ludhiana, India. The birds were provided with standard feed and clean water *ad libitum* and were acclimatized to the layer house for ten days prior to the commencement of the study. In addition to feed and water, the birds were provided with mineral mixture, Vimeral, coccidiostat amprolium hydrochloride and anti-stress vitamins before the start of experiment. The thiacloprid (Alanto 240 SC, Thiacloprid 21.7%), used in this study was commercially obtained from the authorized dealer of Bayer Cropscience Limited, Sabarkanta, Gujarat. Based on the recommended concentrations of thiacloprid used for crop protection, a suitable non-lethal dose of thiacloprid was selected for the administration by oral route.

The experimental trials were approved by the Institutional Animal Ethics Committee, India and conducted under its guidelines at the Poultry Farm of Guru Angad Dev Veterinary and Animal Science University, Ludhiana 141004. Thirty-six birds were randomly divided into seven groups. Group I, II and III, containing four birds each, served as control, in which no insecticide was administered, whereas the birds were stressed giving distilled water by using catheter with 2 mL glass syringe. Groups IV, V, VI and VII contained six birds each and were administered thiacloprid in repeated oral dose of 10 mg/kg/day

for 7, 14, 21 and 28 days or until the birds were sacrificed or died, respectively. The requisite amount of insecticide was suspended in water and administered directly into the proventriculus of the bird by using a catheter with a 2 mL glass syringe. Detailed post-mortem examinations of all the birds of groups I, II and III was performed on days 0, 14 and 28 of the experiment and for groups IV, V, VI and VII on day 7, 14, 21 and 28 of thiacloprid (10 mg/kg/day) treatment, respectively. For the birds which died during experiment, the post-mortem was performed immediately after death.

Post-mortem findings were made by systemic approach (i.e. gross changes in organ size, shape and any visible lesion) and detailed post-mortem lesions from all the birds were recorded. For histopathological examination, tissues from the liver, heart, kidney, brain, lung, intestine and ovaries were dissected out and cleaned with physiological saline solution (0.89%). The tissues were immediately put in 10% neutral formalin solution for subsequent processing and histopathological studies.

The formalin fixed tissues were thoroughly washed in running tap water, dehydrated in ascending grades of alcohol and acetone, cleared in benzene, and embedded in paraffin wax at 58 °C. Five microns thickness sections from paraffin embedded tissues were stained with haematoxyline and eosine (H&E) stain (BANCROFT and STEVENS, 1996). The H&E stained slides were examined by AHBT, the Research Photomicrographic Microscope system of Olympus Corporation, USA.

## Results

Thiacloprid (10 mg/kg/day), on repeated oral exposure, produced significant gross changes in the liver of the treated birds with enlargement, pallor or yellowish discolouration. Marked areas of haemorrhages, necrosis, congestion and fatty changes were also observed in the liver of all treated birds with severity depending on the number of treatment days. No apparent alteration in the gross morphology of the liver was observed in the birds of the control groups.

Repeated oral administration of thiacloprid at a dose rate of 10 mg/kg/day for 28 days did not produce any apparent morphological changes in the brain but produced congestion of the upper respiratory tract and myocardium along with mild haemorrhages in the heart. The kidneys were found to be congested and haemorrhagic in the birds kept in the treatment groups. There was mild enteritis in the small and large intestines in all insecticide treated birds.

Microscopically, the changes in the histopathological architecture of the liver after 14 days of thiacloprid administration comprised mild fatty changes, congestion and degeneration of the hepatocytes. The severity of the lesions progressed with the progression of the study period. On day 21 of the experiment marked degeneration of the hepatocytes was found and on day 28 marked degeneration of the hepatocytes, fatty

changes along with vacuolation and focal necrosis of hepatocytes (Figs. 1a and 1b) were evident. There were no significant changes in the livers of the control groups.

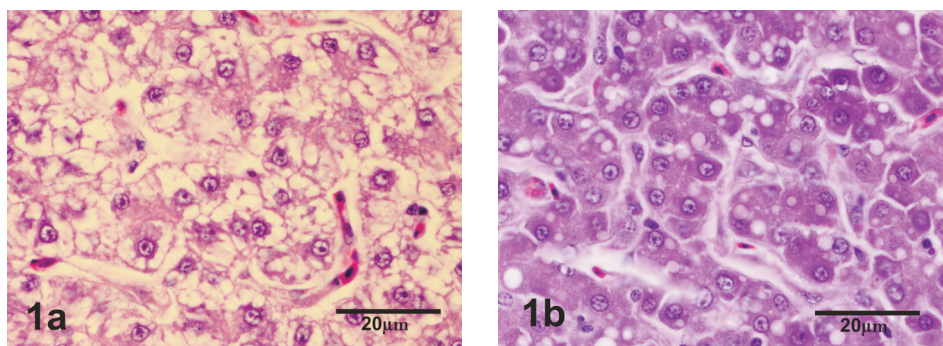


Fig. 1. Photomicrographs of a section of the liver of a *Gallus domesticus* after sub-acute administration of thiacloprid (10 mg/kg/day) showing: (a) fatty changes and vacuolation, (b) degeneration and focal necrosis of hepatocytes. H&E, scale bar = 20 µm.

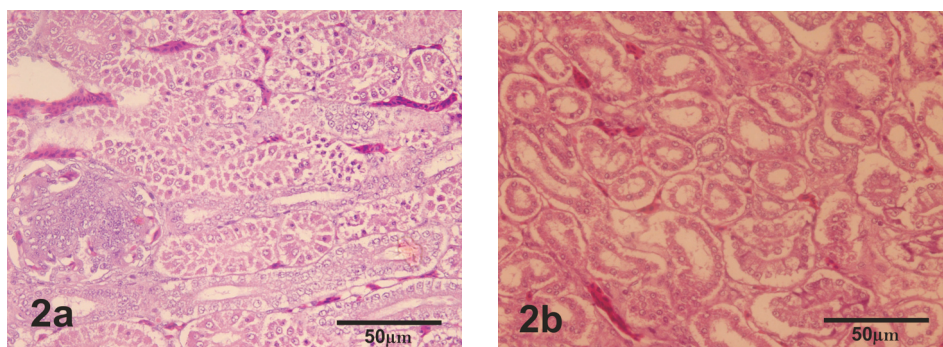


Fig. 2. Photomicrographs of a section of a kidney of a *Gallus domesticus* after sub-acute administration of thiacloprid (10 mg/kg/day) showing: (a) mild degeneration of tubular epithelial cells, (b) sloughed off tubular epithelial cells lying in the lumen of convoluted tubules. H&E, scale bar = 50 µm.

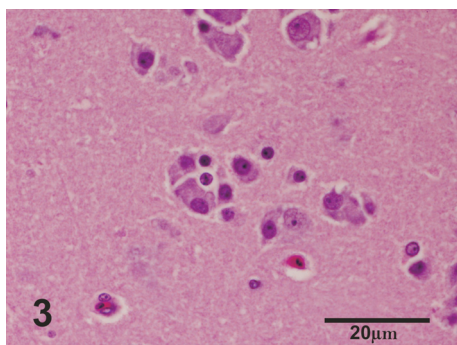


Fig. 3. Photomicrographs of a section of the cerebrum of a *Gallus domesticus* after sub-acute administration of thiacloprid (10 mg/kg/day) showing neuronal degeneration, vacuolization and gliosis in cerebral hemisphere. H&E, scale bar = 20 μm.

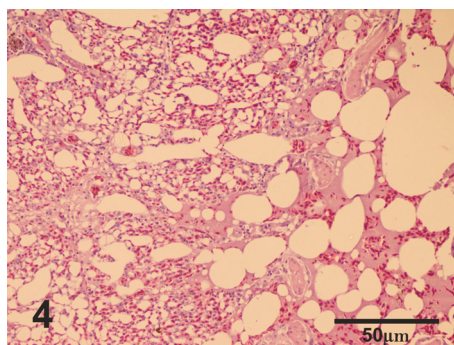


Fig. 4. Photomicrographs of a section of a lung of *Gallus domesticus* after sub-acute administration of thiacloprid (10 mg/kg/day) showing mild congestion. H&E, scale bar = 50 μm.

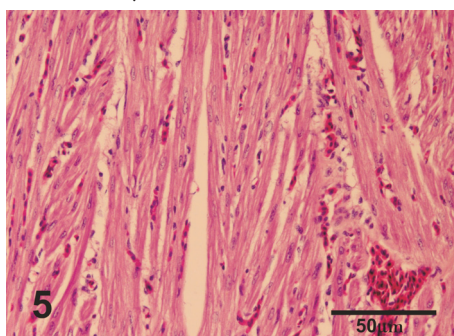


Fig. 5. Photomicrographs of a section of the heart of *Gallus domesticus* after sub-acute administration of thiacloprid (10 mg/kg/day) showing mild myocardial haemorrhages and congestion. H&E, scale bar = 50 μm.

There was a significant alteration in the histoarchitecture of the kidneys, especially in the second half of the experiment. Photomicrographs of a section of the kidneys after 14 days of insecticide exposure (Fig. 2a) showed mild tubular cell degeneration. The nephritic changes continued as the experiment progressed, with marked congestion, collecting duct degeneration and sloughing of epithelial cells becoming evident on day 28 of treatment (Fig. 2b). The section of the cerebral hemisphere showed small vacuoles within neurons in the early stages of experiment. The changes at the end of experiment to the cerebral hemisphere comprised of mild neuronal degeneration, with surrounding glial cells, satellitosis and vacuolation (Fig. 3).

The subacute oral toxicity of thiacloprid (10 mg/kg/day) produced mild congestion and haemorrhage in the lungs (Fig. 4) and mild myocardial haemorrhages and congestion in the heart (Fig. 5). There were no observable gross or histopathological changes in the ovaries of poultry birds.

### **Discussion**

The gross lesions observed in thiacloprid -fed birds were a pale, haemorrhagic, congested and enlarged liver. The gross lesions in the liver are in concurrence with the findings of KAUR et al. (1999) in goats and MEHTA et al. (2003), YADAV et al. (2003) and KRISHNAMOORTHY et al. (2007) in broiler chicks after administration of chlorpyrifos. The findings are also related to the results produced by ANONYM. (2001) after a four-week study done with thiacloprid in rats in which hypertrophy of the liver was observed. The enlargement of the liver in the present study was probably due to the functional hypertrophy of the smooth endoplasmic reticulum and increased drug metabolizing multi-enzyme complex, as suggested by ZIMMERMAN (1999). The observed changes in the digestive tract of the birds in the treatment group suggested that thiacloprid has some irritant action on the intestinal membrane.

Microscopic changes in the liver with large areas of vacuolation, fatty degeneration, large areas of necrosis and congested sinusoidal spaces after the 14<sup>th</sup> and 28<sup>th</sup> days of the trial are similar to imidacloprid administration in Japanese quail (ABO-EL-EZZ et al., 1986; EISSA, 2004). Hepatocellular hypertrophy and fatty changes in the liver were also observed in a three-week study conducted with thiacloprid by ANONYM. (2001) in mice. The study suggested that toxic responses occur relatively frequently in the liver compared with other organs, mainly because the liver is a predominant organ for the metabolism, and is also the first major organ to be exposed to ingested toxins, due to its portal blood supply (POPP and CATTLEY, 1991). A fatty liver is a common response noted with a variety of liver toxicants and represents a potentially reversible injury of the hepatocytes (TREINEN-MOSLEN, 2001). Loss of hepatic cell integrity and homeostasis generally cause energy production failure and cell membrane rupture, which allow leakage of cell contents and enzymes (ZIMMERMAN, 1999). The kidneys showed marked congestion, tubular cell degeneration and sloughing of epithelial cells in thiacloprid fed birds, which concurred with earlier reports by MAJUMDER et al. (1994), who reported glomerular and tubular necrosis in broiler chicks with repeated oral doses of fenvalerate. Kidneys are an important excretory organ, which, along with the liver, also accumulate toxicants. Chemically induced injury to the kidneys is reported to occur as a result of the direct effect of thiacloprid or a metabolite on renal cells, or occurs indirectly by alteration in renal haemodynamics, or by a combination of both (ALDEN and FRITH, 1991). The observed histopathological changes in the kidney in the present study clearly indicated

that repeated oral exposure to thiacloprid has a marked adverse effect on the functioning of kidneys in poultry birds.

Changes in the cerebral hemisphere comprised mild neuronal degeneration with the surrounding glial cells, satellitosis and vacuolation. These findings are in agreement with KRISHNAMOORTHY et al. (2007), MALIK et al. (2002) and YADAV et al. (2003) who reported perivascular and perineuronal oedema, gliosis and degeneration of a few neurons and Purkinje cells in broilers fed with chlorpyrifos. Histological examinations of the brains of poultry fed with different insecticides have revealed sporadic neurons containing double nuclei, suggesting enhancement in cell division by insecticides (LAKOMY et al., 1984). Proliferation of glial cells is a common response to loss of neurons. Thiacloprid exerts its effects possibly by acting both as an agonist and an antagonist on the nicotinic ACh receptors and these nicotinic cholinergic receptors are involved with neurotoxicosis, whose activation occurs at the neuromuscular junction (ANTHONY et al., 2001).

The lungs and heart showed mild congestion and haemorrhage, similar to the work of PUROHIT (2005) who observed congestion in the lungs and heart following oral administration of acephate in mice. GUPTA (1988) reported decline in the relative weight of the heart with histopathological alterations in cypermethrin intoxicated rats. Although the mechanism of pulmonary toxicity is poorly understood, it is reported that lung damaging processes depend on several endogenous factors, including lung cytokines (WITSCHI and LAST, 1991). The cause of the observed changes in cardiac tissue in the present study also cannot be cited with precision, but several factors including stress, metabolite toxicities and/ or endocrine disturbances are reported to lead to such myocardial alterations (ACOSTA, 1992).

No significant histopathological changes were seen in the ovaries of the poultry birds. Although several groups of insecticides, (such as endosulphan, which produces degeneration of the immature oocytes and rupture of the follicular epithelium in mice (AZARNIA et al., 2008), cypermethrin that induces connective tissue proliferation in ovaries of rabbits (ULLAH et al., 2006) and DDT which increases oocytes atresia in ovaries along with ovarian hypertrophy and decreased ovarian growth (SIBONANI et al., 2009) are known to affect the ovary and reproductive hormones of animals, but the present findings suggest that thiacloprid has no adverse effects on the ovarian histoarchitecture and thus on the reproductive performance of *Gallus domesticus*.

The oral sub-acute toxicity study on thiacloprid revealed that this neonicotinoid insecticide is moderately toxic to *Gallus domesticus*. The histopathological studies suggested that thiacloprid produced time dependent toxicosis in poultry birds.

## References

- ABO-EL-EZZ, Z. R., G. A. ABD-ALLAH, M. M. HASSIEB, G. A. HASSAN, M. H. SALEM (1986): Histopathological changes due to the effect of organophosphorous and pyrethroid insecticides in rabbits. *Alex J. Vet. Sci.* 2, 325-326.
- ACOSTA, Jr. D. (1992): *Cardiovascular Toxicology*. Raven Press, New York.
- ALDEN, C. L., C. H. FRITH (1991): Urinary system. In: *Handbook of Toxicologic Pathology*. (Haschetk, W. M., C. G. Rousseaux, Eds.). Academic Press Inc. San Diego. pp. 316-379.
- ANAM, K. K., S. K. MAITRA (1995): Impact of quinalphos on blood glucose and Ach esterase activity in brain and pancreas in a roseringed Parakeet (*Psittacula krameri borealis*: Newmann) *Archives Environ. Contam. Toxicol.* 29, 20-23.
- ANONYMOUS (2001): ISSN 1443-1335, Evaluation of the new active Thiacloprid in the new product Calypos 480 SC Insecticide.
- ANTHONY, D. C., T. J. MONTINE, W. M. VALENTINE, D. G. GRAHAM (2001): Toxic responses of the nervous system. In: *The Basic Science of Poisons*. 6<sup>th</sup> edn. Casarett and Doull's Toxicology (Klaassen, C. D., Ed.). McGraw Hill, New York. pp. 535-563.
- AZARNIA, M. H., M. KOCHESFAHARI, M. RAJABI, Y. TAHAMTANI, A. TAMADON (2008): Histological examination of endosulfan effects on follicular development of Balb/mice. *Bulgarian J. Vet. Med.* 12, 33-41.
- BANCROFT, J. D., A. STEVENS (1996): *Theory and Practice of Histological Techniques*. 4 ed., Churchill Livingstone, London.
- BENBROOK, C. M. (1991): *Sustainable Agriculture Research and Education in the Field*, National Academy Press. Washington, DC.
- EISSA, O. S. (2004): Protective effect of vitamin C and glutathione against the histopathological changes induced by imidacloprid in the liver and testis of Japanese quail. *Egypt. J. Hosp. Med.* 16, 39-54.
- ELLIS, R. L. (1989): Changing pesticide technology in meat and poultry products. *J. Assoc. Off. Anal. Chem.* 72, 521- 524.
- GUPTA, P. K. (1988): Cypermethrin - A pyrethroid insecticide. In: *Advances in Toxicology and Environment Health*. (Gupta, P. K., V. Raviprakash, Eds.). Jagminder Book Agency, New Delhi. pp. 81-130.
- HISASHI, M., K. KATSUYOSHI, M. YASUYUKI, M. HIROSHI (2006): Survey of pcb and organochlorine pesticide residues in meats and processed meat products collected in Osaka, Japan. *J. Food Hygienic Society of Japan.* 47, pp. 127-135.
- KAUR, H., A. K. SRIVASTAVA, S. K. GARG, D. PRAKASH (1999): Acute chlorpyrifos toxicity in goats - a pathomorphological study. *Indian J. Vet. Pathol.* 23, 41-43.
- KRISHNAMOORTHY, P., S. VAIRAMUTHU, C. BALCHANDRAN, B. MURALIMANO HAR (2007): Pathology of chlorpyrifos and T-2 toxin in broiler chicken. *Vet. Arhiv* 77, 47-57.
- KUTHES, A. J., D. C. CHURCH, F. L. DURYEE (1970): Toxicological effects of pesticides on rumen functions *in vitro*. *J. Agricul. Food Chem.* 18, 430-433.



- LAKOMY, M., S. FLIEGER, M. JASTRZEBSKI (1984): Binuclear neurons in brain of fowls after experimental poisoning with pesticides. *Polskie Archiwum Weterynaryjne* 24, 247-252.
- LIU, M. Y., J. E. CASIDA (1993): High affinity binding of [3H] imidacloprid in the insect acetylcholine receptor. *Pest Biochem. Physiol.* 46, 40-46.
- MAJUMDER, S., A. K. CHAKRABORTY, T. K. MANDAL, A. BHATTACHARYA, D. K. BASAK (1994). Subacute toxicity of fenvalerate in broiler chicks: concentration, cytotoxicity and biochemical profiles. *Indian J. Expt. Biol.* 32, 752-756.
- MALIK, G., J. P. DHAHIYA, G. SANDEEP, S. K. MISHRA (2002): Clinicopathological studies on chlorpyrifos intoxication in broiler chicken. *Proceedings of 19<sup>th</sup> Annual Conference of Indian Association of Veterinary Pathologists.* Palampur, India. p.124.
- MEHTA, G., S. P. SINGH, L. D. SHARMA, A. ZAFAR (2003): Immunotoxicity and cytotoxicity of chlorpyrifos and endosulfan in poultry. *Proceedings of 22<sup>nd</sup> Annual Conference of Society of Toxicology.* Chennai, India. pp. 113-114.
- POPP, J. A., R. C. CATTLEY (1991): Hepatobiliary system. In: *Handbook of Toxicologic Pathology.* (Haschek, W. M., C. G. Rousseaux, Eds.). Academic Press Inc. San Diego. pp. 279-315.
- PUROHIT, T. J. (2005): Subacute oral toxicity study of acephate in synthetic whiteleghorn birds. Thesis. Anand Agricultural University, Anand.
- SANBORN, M. D., C. D. OLE, A. ABELSOHN, E. WEIR (2002): Identifying and managing adverse environmental health effects of pesticides. *Can. Med. Assoc. J.* 166, 1431-1436.
- SIBONANI, S. M., H. J.V. JOHAN, E. J. B. IRINE, S. B. MARIA (2009): Histopathological changes in the reproductive system of *Oreochromis mssambicus* following exposure to DDT. *Environ. Toxicol. Pharmacol.* 28, 133-139.
- TREINEN-MOSLEN, M. (2001): Toxic responses of the liver. In: *The Basic Science of Poisons.* Cassarett and Doull's Toxicology. (Klassen, C. D., Ed.). McGraw Hill, New York. pp. 471-489.
- ULLAH, M. S., M. AHMAD, N. AHMAD, M. Z. KHAN, I. AHMAD (2006): Toxic effects of cypermethrin in female rabbits. *Pakistan Vet. J.* 26, 193-196.
- WITSCHI, H. P., J. O. LAST (1991): Toxic responses of the respiratory system. In: *The Basic Science of Poisons.* Cassarett and Doull's Toxicology. (Klassen, C. D., Ed.). McGraw Hill, New York. pp. 515-534.
- YADAV, S. S., S. K. MUKHOPADHAYAY, K. PUROHIT (2003): Experimentally induced chlorpyrifos toxicity in broilers: Haematobiochemical and pathomorphological studies. *Proceedings of 20<sup>th</sup> Annual Conference of Indian Association of Veterinary Pathologists,* 12-14 November. Jabalpur, India. pp.103.
- ZHANG, A. H., KAYSER, P. MAIENFISCH, J. E. CASIDA (2000): Insect nicotinic acetylcholinereceptor: conserved neonicotinoid specificity of [3H] imidacloprid binding site. *J. Neurochem.* 75, 1294-1303.
- ZIMMERMAN, H. J. (1999): Drug induced liver disease. In: *Schiff's Diseases of the Liver.* (Schiff, E. R, Sorrell, M. F. Maddrey, W. F. Eds.). Lippencott - Raven Publishers, Philadelphia. pp. 973-1064.

Received: 14 September 2009

Accepted: 22 December 2010

---

**GOYAL, S., H. S. SANDHU, R. S. BRAR: Patohistološke promjene kod subakutnoga otrovanja nakon oralne primjene tiakloprida u kokoši (*Gallus domesticus*). Vet. arhiv 80, 673-682, 2010.**

**SAŽETAK**

Ponovljena oralna primjena neonikotinoidnog insekticida tiakloprida u količini od 10 mg/kg/dan uzastopno tijekom 28 dana u kokoši je dovela do značajnih patomorfoloških promjena u jetrima, plućima i crijevima, ali neznatnih u bubrezima, mozgu, srcu i jajnicima. U jetrima su ustanovljene znatne patohistološke promjene poput blage masne degeneracije, kongestije i degeneracije hepatocita. Promjene u bubrezima uključivale su znatnu kongestiju, degeneraciju tubularnih stanica i ljuštenje epitelnih stanica. U mozgu su ustanovljene promjene u smislu blage degeneracije živčanih stanica okruženih glijalnim stanicama te satelitoza i vakuolacija. Blaga kongestija i krvarenje ustanovljeni su u plućima i u srčanom mišiću nakon oralne primjene tiakloprida. Nije ustanovljen štetan učinak na histološku građu jajnika i time na reproduktivnu sposobnost kokoši. Subakutno otrovanje kokoši tiaklopridom pokazalo je da je taj neonikotinoidni insekticid umjereno štetan za kokoš.

**Cljučne riječi:** *Gallus domesticus*, tiakloprid, neonikotinoid, patohistologija

---