

Patho-biochemical studies on hepatotoxicity and nephrotoxicity on exposure to chlorpyrifos and imidacloprid in layer chickens

Abdoalwahab M. Kammon^{1,2*}, Rajinder S. Brar¹, Harmanjit S. Banga¹,
and Sandeep Sodhi¹

¹Department of Veterinary Pathology, College of Veterinary Science Guru Angad Dev Veterinary and Animal Sciences University, Ludhiana, India

²Department of Poultry Diseases, Faculty of Veterinary Medicine, Al-Fateh University, Tripoli, Libya

KAMMON, A. M., R. S. BRAR, H. S. BANGA, S. SODHI: Patho-biochemical studies on hepatotoxicity and nephrotoxicity on exposure to chlorpyrifos and imidacloprid in layer chickens. Vet. arhiv 80, 663-672, 2010.

ABSTRACT

The hepatotoxicity and nephrotoxicity of chlorpyrifos (CPF) and imidacloprid (IMC) insecticides were experimentally studied in layer chickens, taking into account the patho-biochemical alterations. The LD₅₀ values estimated were 41 mg/kg bw and 104.1 mg/kg bw for CPF and IMC, respectively. The plasma cholineesterase enzyme was severely inhibited in chickens given a single dose of CPF at a rate of 55 mg/kg bw via oral gavage, while it remained unchanged in chickens given IMC at rate of 139 mg/kg bw via similar route. The activities of liver function enzymes viz. AKP, ALT and AST were significantly increased in chickens of CPF and IMC groups. Uric acid level was significantly increased and cholesterol level was only significantly reduced in the plasma of chickens administrated CPF. Plasma glucose values in chickens given CPF as well as in chickens given IMC were significantly increased at (P<0.01) and (P<0.05), respectively. Microscopically, liver tissue of CPF intoxicated chickens showed degeneration, coagulative necrosis and hemorrhages. The kidneys showed hemorrhages, vacuolar degeneration of tubular epithelial cells as well as focal coagulative necrosis. Microscopic lesions of a similar type were observed in chickens given IMC. The exposure to CPF and IMC produced histopathological changes that could be correlated with changes in the biochemical profile of layer chickens.

Key words: chickens, chlorpyrifos, hepatotoxicity, imidacloprid, nephrotoxicity, pathology

Introduction

Insecticides are being used extensively all over the world in the field of agriculture and veterinary practice. However, indiscriminate use of insecticide(s) has led to a widespread concern over the potential adverse effects of these chemicals on animal and human health

*Corresponding author:

A. M. Kammon, B.V.Sc., M.V. Sc., Department of Veterinary Pathology, College of Veterinary Science Guru Angad Dev Veterinary and Animal Sciences University, Ludhiana-141004 (PB), India, Phone: +919780382573; E-mail: abd_kammon@yahoo.com

(AL-SALEH, 1994) as these chemicals interfere with the defense mechanisms of the host, which normally ensures its survival against invading pathogens (CASALE et al., 1993; RODGERS and XIONG, 1996; SODHI et al., 2006; CABASSI, 2007).

Organophosphate insecticides are increasingly used as substitutes for organochlorine and carbamate insecticides because of their high efficacy and lower persistence in the environment. Chlorpyrifos (CPF) (O,O-diethyl O-3,5,6-trichloro-2-pyridyl phosphorothioate), an organophosphate is one of the most widely used insecticides in agriculture worldwide. It has also been used for the control of termites in chicken houses (LEIDY et al., 1991). Toxicological studies of CPF in chickens focused on the sub-acute effects on plasma or serum enzymes and other biochemical parameters (MALIK et al., 2004), examination of delayed neurotoxicity (RICHARDSON et al., 1993), food borne toxicity (MALIK et al., 2001), developmental effects (GELLER et al., 1998) and pathology of long-term exposure (KRISHNAMOORTHY et al., 2007).

Imidacloprid(IMC)(1-(6-chloro-3-pyridylmethyl)-N-nitroimidazolidin-2-ylideneamine) was the first representative of neonicotinoid insecticides to be registered for use and is presently the most important commercial product because of its high efficacy against insects. Besides its agricultural use, it is also used to control houseflies on poultry farms. There is paucity of information available concerning the effects of IMC on animal health, as the insecticide that is likely to be used in future pest control programs. The objective of this study was to investigate the hepatotoxic and nephrotoxic effect of acute exposure to chlorpyrifos and imidacloprid in layer chickens taking into account its correlation to alteration(s) of biochemical parameters and histopathology.

Materials and methods

Chemicals (Insecticides). Commercial products of chlorpyrifos (20%) imidacloprid (17.8%) used in this study were purchased from the local market in Ludhiana, India.

Experimental design. 50-day-old layer chickens were procured from the Department of Livestock Production and Management, GADVASU, Ludhiana. The acute oral (24 hours) LD₅₀ values of CPF and IMC were estimated by the up-and-down procedure (BRUCE, 1985). The calculations were carried out using a computer program (AOT425StatPgm), created by the United States Environmental Protection Agency (EPA). After estimation of LD₅₀, 45 chickens were randomly segregated into three groups of 15 each and fasted for 6 hours prior to dosing. Following the period of fasting, the birds were weighed and the doses were calculated according to the body weight. The insecticides were diluted in distilled water to obtain the desired concentrations. Fresh preparations were orally administered in single doses using oral gavage. The first group was given 55 mg/kg bw CPF, the second group was given 139 mg/kg bw IMC and the third group was given distilled water via the same route and served as a control for both groups. The birds were

closely watched for the presence of clinical signs, if any, until death. All the experiments were performed after obtaining permission from the University Animal Ethics Committee (IAEC). The regulations addressing animal use were followed and proper care and attention were given to the birds used in these experiments. Moribund birds and the birds at the end of the experiments were humanely sacrificed by cervical dislocation.

Biochemical analysis. Blood samples were collected from all birds of the control group (n = 15), from 8 birds of the CPF group and from 9 birds belong to the IMC group. Plasma was separated and immediately used for the analysis of acetylcholine esterase enzyme (CHE), aspartate aminotransferase (AST), alanine aminotransferase (ALT), alkaline phosphatase (AKP), uric acid, glucose, cholesterol, total protein and albumin. Biochemical tests were performed using commercial kits (Bayer Diagnostics India Ltd) on a Biotron BTR-830 analyzer.

Histopathological examination. Representative samples from the liver and kidneys were collected in 10% neutral formalin. After washing in running water and dehydration in alcohol, tissues were embedded and 5 µm paraffin sections cut and stained with haematoxylin and eosin as per the method of LUNA (1968).

Statistical analysis. All data were expressed as mean ± standard error. The statistical significance of the mean differences between control and treated groups was analyzed by ANOVA, with Tukey HSD post hoc test for multiple comparisons. Statistical calculations were performed with the SPSS 11.5 computer program (SPSS Inc. Chicago, Illions, USA). The values of (P<0.05) and (P<0.01) were taken as the cut-off value to consider differences statistically significant and highly significant, respectively.

Results

The acute (24h) oral LD₅₀ values of CPF and IMID were 41.5 mg/kg and 104.1 mg/kg, respectively (Table 1).

Table 1. Estimation of LD₅₀ of chlorpyrifos and imidacloprid in layer chickens by the up and down procedure

Variables	Result	
	Chlorpyrifos	Imidacloprid
LD ₅₀	41.5 mg/kg orally	104.1 mg/kg orally
Initial dose	22	35
Last dose	44	110
Dose sequence	22,28,35,44,35,44,35	35,44,55,70,88,110,88,110,88
Number of chickens used	7 (OOOXOXO)*	9 (OOOOOXOXO)*

*(X = death; O = survival)

CPF at the dose of 55 mg/kg orally produced signs of toxicity commencing two hours after administration, which included excitation followed by sluggishness, watery diarrhea, excessive salivation, changing to drooling and rigid stance with dropping of wings. The chickens were unable to stand and showed convulsions before death.

The gross lesions comprised of patches of generalized ecchymotic hemorrhages and congestions in the liver and kidneys. Pale areas were observed in the liver and kidneys.

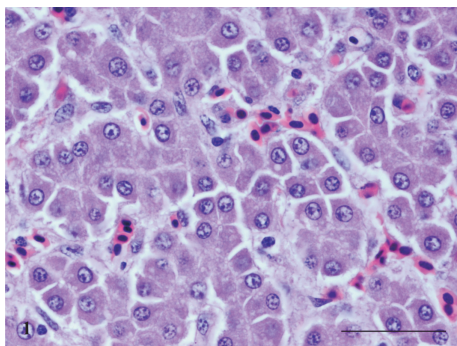


Fig. 1. Liver of chlorpyrifos intoxicated chicken revealing degeneration (with mild fatty changes) and coagulative necrosis along with hemorrhages. H&E, scale bar = 20µm.

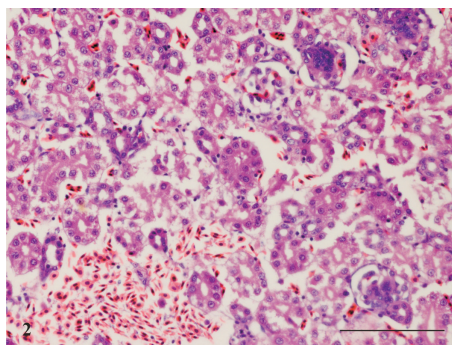


Fig. 2. Kidney of chlorpyrifos intoxicated chicken revealing hemorrhages, vacuolar degeneration of tubular epithelium and coagulative necrosis. H&E, scale bar = 50 µm.

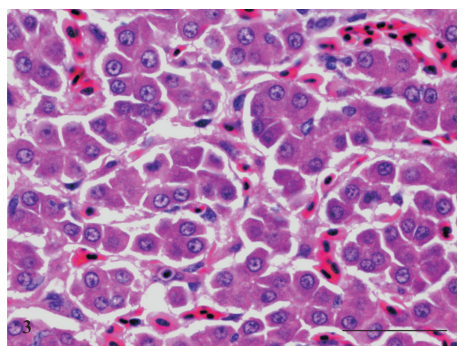


Fig. 3. Liver of imidacloprid intoxicated chicken exhibiting degeneration, congestion, and mild dilation of sinusoidal spaces. H&E, scale bar = 20 µm.

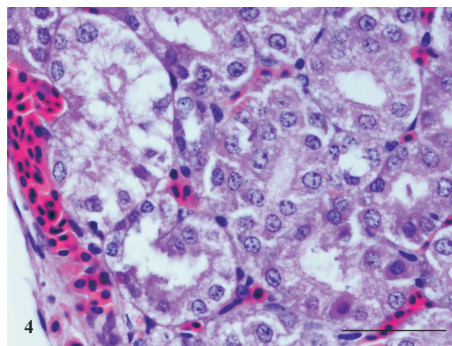


Fig. 4. Kidney of imidacloprid intoxicated chicken showing sub-capsular hemorrhages and coagulative necrosis of tubular epithelium. H&E, scale bar = 20 µm.

The histopathological examination of liver tissues showed degeneration (cloudy swelling with mild fatty changes), coagulative necrosis and hemorrhages (Fig. 1). The kidneys showed hemorrhages, vacuolar degeneration of tubular epithelial cells besides coagulative necrosis. (Fig. 2).

Administration of IMC at the dose of 139 mg/kg orally produced signs of toxicity within 15 minutes. These signs included sluggishness, closed eyes/dropped eyes, chickens sitting on hocks, open mouth breathing, muscular tremors, chickens lying on one side and walking when forced to do so but lying down again and some of chickens also revealed paralysis and watery diarrhea. Deaths occurred within 5-24 hours following insecticide administration. Grossly, some hemorrhages and paleness of the kidneys were seen. The histopathology of IMC intoxicated chickens revealed hemorrhages, degeneration of hepatocytes, congestion and mild dilation of hepatic sinusoids (Fig. 3). The kidneys showed sub-capsular hemorrhages and coagulative necrosis of the tubular epithelium (Fig. 4).

Data pertaining to the effect of CPF and IMC upon plasma biochemical parameters of layer chickens are presented in Table 2. The data shows significant inhibition of CHE enzyme ($P < 0.01$) in CPF intoxicated chickens compared to the control chickens. There was no inhibition of CHE enzyme in chickens of IMC group. The AST, AKP, ALT values were significantly elevated ($P < 0.01$) in both groups. Plasma glucose values in chickens given CPF, as well as in chickens given IMC, were significantly increased at ($P < 0.01$) and ($P < 0.05$), respectively. There was significant elevation of plasma uric acid in chickens given CPF ($P < 0.01$) only. The level of plasma cholesterol was significantly reduced ($P < 0.01$) in chickens given CPF. The plasma levels of total protein and albumin remained unaltered in both groups.

Table 2. Effect of exposure to chlorpyrifos and imidacloprid on plasma biochemical parameters (Mean \pm SE) in layer chickens

Biochemical parameters	Control (n = 15)	Chlorpyrifos (55 mg/kg bw) (n = 8)	Imidacloprid (139 mg/kg bw) (n = 9)
CHE (IU/L)	735 \pm 12	263 \pm 14**	733 \pm 28
AKP (IU/L)	992 \pm 3	1183 \pm 12**	1421 \pm 7**
AST (IU/L)	146 \pm 8	184 \pm 6**	235 \pm 10**
ALT (IU/L)	4 \pm 0.2	7 \pm 0.3**	5 \pm 0.2**
Uric acid (mg/dl)	3 \pm 0.1	9 \pm 0.2**	3.5 \pm 0.2
Glucose (mg/dl)	250 \pm 5	404 \pm 2**	269 \pm 4*
Cholesterol (mg/dl)	115 \pm 1.5	94 \pm 3**	109 \pm 2
Total protein (g/dl)	3 \pm 0.04	3 \pm 0.06	3 \pm 0.04
Albumin (g/dl)	1.5 \pm 0.1	1.6 \pm 0.1	1.6 \pm 0.1

* Significant difference ($P < 0.05$); ** highly significant difference from control ($P < 0.01$).

Discussion

The acute oral LD₅₀ for chlorpyrifos estimated in our study was 41.5 mg/kg bw in 50 days old layer chicken. Earlier, McCOLLISTER et al. (1974), AL-BADRANY and MOHAMMAD (2007) and MOHAMMAD et al. (2008) reported LD₅₀ values of >25.4 mg/kg bw, 18.14 mg/kg and 10.79 mg/kg bw, respectively. This variation could be due to many factors like age, environmental conditions and breed of the birds used for experimental studies.

Hepatotoxicity and nephrotoxicity were studied in layer chickens following single acute doses of 55 mg/kg bw and 139 mg/kg bw of CPF and IMC, respectively. The cholinergic signs in CPF intoxicated chickens were in agreement with those reported in chickens intoxicated with CPF and other organophosphate insecticides (LUMEIJ, 1997; AL-BADRANY and MOHAMMAD, 2007). The findings of a significant reduction of plasma CHE activity in CPF group is supported by earlier reports on CPF in broiler chicks (AL-BADRANY and MOHAMMAD, 2007) and in mice (COMETA et al., 2007).

The acute oral LD₅₀ of IMC determined in this study in layer chickens was 104.1 mg/kg bw, which has not previously been reported in chickens. However, the acute oral toxicity (LD₅₀) of IMC is 450 mg/kg body weight in rats (MEISTER, 1995), 131 mg/kg in mice (KIDD and JAMES, 1991), 152 mg/kg in bobwhite quail and 31 mg/kg in Japanese quail (MEISTER, 1995). The clinical signs seen in IMC intoxicated birds were similar to those reported in rats (SHEETS, 2001). Signs of toxicity were evident within 15 minutes following oral administration. This might be due to rapid absorption, distribution and metabolism profile. Imidacloprid mechanism of the action is found to derive from almost complete and virtually irreversible blockage of nicotinic acetylcholine receptors in the central nervous system of certain insects. Its insecticidal activity is attributed to actions (block of signals induced by acetylcholine) on post-synaptic nicotinic receptors which, in insects, are located exclusively in the central nervous system resulting in impairment of normal nerve function. It acts by exciting distinct nicotinic receptor proteins in a manner similar to acetylcholine, but unlike acetylcholine, which is quickly degraded, imidacloprid cannot be or is slowly inactivated by acetylcholinesterase. The lasting effect results in a disorder of the nervous system of the insect and as a consequence in killing the treated insects. In mammals, differences in binding properties to the various receptor subtypes contribute greatly to the much lower activity of neonicotinoids in vertebrate tissues, as compared to tissues from insects (SHEETS, 2001). However, there is less information about the mechanism of the action of imidacloprid in chickens. In our study, there was no alteration of plasma CHE level in IMC intoxicated chickens. This finding is in agreement with that IMC does not inhibit cholinesterase (SHEETS, 2001).

The gross lesions observed in chickens treated with CPF comprised of patches of ecchymotic hemorrhages and congestions in the liver. These findings agreed with

those reported in goats (KAUR et al., 1999). In the present study, the histopathological examination of liver tissues exposed to CPF showed degeneration (cloudy swelling with mild fatty changes), coagulative necrosis and hemorrhages. Some of these findings were similar to the changes reported by KRISHNAMOORTHY et al. (2007) in broiler chicks fed 45 ppm CPF for 28 days. GOEL et al. (2005) described marked alterations of hepatic pathology after 8 weeks of treatment in chlorpyrifos intoxicated rats. The hepatic cords were disrupted at most places. A few hepatocytes were vacuolated and had lost the usual polyhedral shape. Vacuolization along with hepatocytes ballooning was more severe near the portal tracts with a resultant widening of the sinusoidal spaces and some degree of hepatic hypertrophy. There was a significant increase in the cells undergoing necrosis.

Histopathological lesions observed in liver exposed to IMC, were similar to those reported in Japanese quail treated with IMC for 6 weeks (OMIAMA, 2004). The liver was the principal target organ in dogs treated chronically with IMC and rats treated subacutely (SHEETS, 2001). However, these changes were less severe as compared to those observed in the CPF intoxicated chickens in this study.

Generally, increased enzyme concentrations are a measure of recent organ damage rather than decreased organ function. The increase of plasma AST and ALT activity is the most specific indicators of muscle and liver cell damage (LUMEIJ, 1997). The increases of plasma AST activity and bile acid concentration were the most specific indicators of liver disease in the racing pigeons intoxicated by ethylene glycol (LUMEIJ, 1997). In our study plasma AST, AKP and ALT activities were significantly increased in CPF and IMC intoxicated chickens. These results suggest that administration of these insecticides causes necrotic changes in the liver thus causing leakage of the enzymes into the blood.

The susceptibility of the liver to toxic compounds is due to the central role it plays in the biotransformation and disposition of xenobiotics (MURRAY et al., 1999). The liver is known to be the target organ of IMC insecticide (SHEETS, 2001). The increase in level specific enzymes can be correlated well with gross and histopathological changes in livers in present study. However, the kidneys, the major detoxification organs for many xenobiotics, are frequently susceptible to the nephrotoxic effects. Although hisopathologic examination showed lesions in kidney tissues produced by IMC, the level of uric acid remain unchanged compared to a significant increase of uric acid level caused by CPF. Acute renal failure was reported, following exposure to organophosphates (OP). The transient renal injury was attributed in these studies to both a direct action of the OP, causing tubular cell necrosis, and to a secondary mechanism that followed the cholinergic crisis, causing hypovolemic shock and rhabdomyolysis (BETROSIAN et al., 1995; POND et al., 1995).

Thus, it is concluded that exposure to CPF and IMC produced hepatotoxic and nephrotoxic damage in layer chickens. There is an obvious correlation between the lesions

observed and plasma biochemical changes. However, the exact mechanism that leads to cellular damage, leading to hepatotoxicity and nephrotoxicity, needs to be elucidated.

Acknowledgements

This study is part of Ph.D thesis research work by Abdoalwahab Mohamed Kammon and was supported by the Department of Veterinary Pathology, College of Veterinary Science, Guru Angad Dev Veterinary and Animal Sciences University, Ludhiana, India.

References

- AL-BADRANY, Y. M. A., F. K. MOHAMMAD (2007): Effects of acute and repeated oral exposure to the organophosphate insecticide chlorpyrifos on open-field activity in chicks. *Toxicol. Lett.* 174, 110-116.
- AL-SALEH, I. A. (1994): Pesticides: A review article. *J. Environ. Pathol. Toxicol. Oncol.* 13, 151-161.
- BETROSIAN, A., M. BALLA, G. KAFIRI, G. KOFINAS, R. MAKRI, A. KAKOURI (1995): Multiple system organ failure from organophosphate poisoning. *Clin. Toxicol.* 33, 257-260.
- BRUCE, R. D. (1985): An up-and-down procedure for acute toxicity testing. *Fundam. Appl. Toxicol.* 5, 151-157.
- CABASSI, E. (2007): The immune system and exposure to xenobiotics in animals. *Vet. Res. Comm.* 31, 115-120.
- CASALE, G. P., J. L. VENNERSTROM, S. BAVARI, T. I. WANG (1993): Inhibition of interleukin 2 proliferation of mouse CTLL2 cells, by selected carbamate and organophosphate insecticides and congeners of carbaryl. *Immunopharm. Immunot.* 15, 199-215.
- COMETA, M. F., F. M. BURATTI, S. FORTUNA, P. LORENZINI, M. T. VOLPE, L. PARISI, E. TESTAI, A. MENEGUZ (2007): Cholinesterase inhibition and alterations of hepatic metabolism by oral acute and repeated chlorpyrifos administration to mice. *Toxicology* 234, 90-102.
- GELLER, A. M., A. A. ABDEL-RAHMAN, R. I. REIFFER, M. B. ABOU-DONIA, W. K. BOYES (1998). The organophosphate pesticide chlorpyrifos affects form deprivation myopia. *IOVS* 39, 1290-1294.
- GOEL, A., V. DANI, D. K. DHAWAN (2005): Protective effects of zinc on lipid peroxidation, antioxidant enzymes and hepatic histoarchitecture in chlorpyrifos-induced toxicity. *Chem. Biol. Interact.* 156, 131-140.
- KAUR, H., A. K. SRIVASTAVA, S. K. GARG, D. PRAKASH (1999): Acute chlorpyrifos toxicity in goats - a pathomorphological study. *Indian J. Vet. Pathol.* 23, 41-43.
- KIDD, H., D. JAMES (1991): *Agrochemicals Handbook*, 3rd ed., Cambridge, England, Royal Society of Chemistry. pp. 10-12.
- KRISHNAMOORTHY, P., S. VAIRAMUTHU, C. BALACHANDRAN, B. MURALIMANO HAR (2007): Pathology of chlorpyrifos and T-2 toxin on broiler chicken. *Vet. Arhiv.* 77, 47-57.

- LEIDY, R. B., C. G. WRIGHT, H. E. DUPREE (1991): Applicator exposure to airborne concentrations of a termiticide formulation of chlorpyrifos. *Bull. Environ. Contam. Toxicol.* 40, 177-183.
- LUMEIJ, J. T. (1997): Avian clinical biochemistry. In: *Clinical Biochemistry of Domestic Animals*, Kaneko, J. J., J. W. Harvey, M. L. Bruss, eds. 5th ed. Academic Press. pp. 857-883.
- LUNA, L. G. (1968): *Manual of histological staining methods of Armed Forces Institute of Pathology*. New York: Mc Graw Hill book Co.
- MALIK, G., V. K. AGARWAL, S. GERA, J. P. DAHIYA (2001): Studies on growth pattern and feed efficiency in broiler chickens following chlorpyrifos intoxication. *Haryana Vet.* 40, 38-40.
- MALIK, G., J. P. DAHIYA, S. GERA (2004). Biochemical studies on chlorpyrifos toxicity in broiler chickens. *Indian J. Anim. Sci.* 74, 473-476.
- McCOLLISTER, S. B., R. J. KOCIBA, C. G. HUMISTON, D. D. McCOLLISTER, P. J. GEHRING (1974): Studies of the acute and long-term oral toxicity of chlorpyrifos. *Food Chem. Toxicol.* 12, 45-61.
- MEISTER, R. T. (1995): *Farm Chemicals Handbook*. Meister Publishing Company. Willoughby, Ohio, USA.
- MOHAMMAD, F. K., Y. M. AL-BADRANY, M. M. AL-JOBORY (2008): Acute toxicity and cholinesterase inhibition in chicks dosed orally with organophosphate insecticides. *Arhiv Za higijenu rada i toksikologiju* 59, 145-151.
- MURRAY, R. K., D. K. GRANNER, P. A. MAYES, V. W. RODWELL (1999): *Harper's Biochemistry*, 22nd ed. USA, Prentice Hall.
- OMIAMA, S. E. (2004): Protective effect of vitamin C and glutathione against the histopathological changes induced by imidacloprid in the liver and testis of Japanese quail. *Egyptian J. Hosp. Med.* 16, 39-54.
- POND, A. L., H. W. CHAMBERS, J. E. CHAMBERS (1995): Organophosphate detoxication potential of various rat tissues via A-esterase and aliesterase activities. *Toxicol. Lett.* 78, 245-252.
- RICHARDSON, R. J., T. B. MOORE, U. S. KAYYALI, J. H. FOWKE, J. C. RANDALL (1993): Inhibition of hen brain acetylcholinesterase and neurotoxic esterase by chlorpyrifos *in vivo* and kinetics of inhibition by chlorpyrifos oxon *in vitro*: application to assessment of neuropathic risk. *Fundam. Appl. Toxicol.* 20, 273-279.
- RODGERS, K., S. XIONG (1996): Contribution of mast cell mediators to alterations macrophage function after malathion administration. *Fundam. Appl. Toxicol.* 33, 100-108.
- SHEETS, L. P. (2001): Imidacloprid: A Neonicotinoid Insecticide. In: *Handbook of Pesticide Toxicology*. Kreiger R, Ed. Academic Press. Vol. 2. pp. 1123-1130.
- SODHI, S., A. SHARMA, R. S. BRAR (2006): A protective effect of vitamin E and selenium in ameliorating the immunotoxicity of malathion in chicks. *Vet. Res. Comm.* 30, 935-942.

Received: 8 August 2009

Accepted: 29 January 2010

KAMMON, A. M., R. S. BRAR, H. S. BANGA, S. SODHI: Patološko-biokemijska istraživanja hepatotoksičnosti i nefrotoksičnosti nakon izlaganja pilenki klorpirifosu i imidaklopridu. Vet. arhiv 80, 663-672, 2010.

SAŽETAK

Hepatotoksičnost i nefrotoksičnost insekticida klorpirifosa (CPF) i imidakloprida (IMC) istraživana je u pokusima na pilenkama uzimajući u obzir patološko-biokemijske promjene. Vrijednosti LD50 iznosile su 41 mg/kg tjelesne mase za CPF i 104,1 mg/kg tjelesne mase za IMC. Aktivnost kolinesteraze u plazmi bila je zakočena u pilenki kojima je peroralno bila primijenjena jedna doza CPF u količini od 55 mg/kg, dok je ostala nepromijenjena u pilenki koje su dobile IMC također peroralno u količini od 139 mg/kg. Aktivnosti enzima koji pokazuju jetrenu funkciju, tj. AKP, ALT and AST, bile su značajno povećane u pilenki obiju skupina. Razina mokraćne kiseline bila je značajno povećana, a razina kolesterola značajno smanjena u plazmi pilenki kojima je primijenjen samo CPF. Vrijednosti glukoze u plazmi pilenki koje su dobivale CPF bile su značajno veće ($P<0,01$), a također i u pilenki koje su dobivale IMC ($P<0,05$). U jetrenom tkivu pilenki kojima je bio primijenjen CPF mikroskopski je ustanovljena degeneracija, koagulacijska nekroza i krvarenja. Povrh koagulacijske žarišne nekroze, u bubrezima su bila ustanovljena krvarenja i vakuolarna degeneracija tubularnih epitelnih stanica. Slična mikroskopska oštećenja bila su ustanovljena u pilenki kojima je primijenjen IMC. Izlaganje klorpirifosu i imidaklopridu dovelo je do patohistoloških promjena koje su usporedive s promjenama u biokemijskom nalazu pilenki.

Ključne riječi: pilenke, klorpirifos, imidakloprid, hepatotoksičnost, nefrotoksičnost, patologija
