

Hypertrophic cardiomyopathy in 12 dogs (2004-2008): first report in India

**Karlapudi S. Kumar*, Pothureddi Nagaraj, Vipparthi V. V. A. Kumar, and
Dronamraju S. T. Rao**

*Department of Clinical Veterinary Medicine, College of Veterinary Science, Rajendranagar, Hyderabad,
Andhra Pradesh, India*

KUMAR, K. S., P. NAGARAJ, V. V. V. A. KUMAR, D. S. T. RAO: Hypertrophic cardiomyopathy in 12 dogs (2004-2008): first report in India. Vet. arhiv 80, 491-498, 2010.

ABSTRACT

A total of 1276 dogs of various breeds and both sexes were presented to the Teaching Veterinary Clinical Complex, Bhoiguda, College of Veterinary Science, Hyderabad with a history and signs of cardio-pulmonary disorders, from 2004 to 2008. Based on physical, electrocardiographic, radiographic and echocardiographic examinations, 12 dogs were diagnosed with Hypertrophic Cardiomyopathy (HCM). No abnormalities were detected from the Complete Blood Count and blood biochemistry, except elevated levels of Creatine Kinase MB and Lactate Dehydrogenase. All the HCM dogs revealed common manifestations such as: exercise intolerance, poor appetite, lethargy, cough, seizures (8 dogs) and syncope (6 dogs) for more than a couple of weeks. The HCM dogs were under treatment for more than a month with diuretics and Angiotensin Converting Enzyme (ACE)-inhibitors but without any improvement. After supplementation of diltiazem along with ramipril and frusemide, improvement in clinical manifestations were noticed over 3-5 days and complete clinical recovery after 30-60 days. Hence, from the present findings it may be concluded that echocardiography is the most sensitive mode of diagnosis and the role of diltiazem in successful treatment of HCM in dogs is clear.

Key words: hypertrophic cardiomyopathy, dog, diltiazem

Introduction

Hypertrophic cardiomyopathy (HCM) is pragmatically defined as inappropriate myocardial hypertrophy of a non-dilated left ventricle, occurring in the absence of an identifiable stimulus for the hypertrophy (WYNNE and BRAUNWALD, 1997). HCM typically affects middle aged cats is relatively uncommon in dogs. Most are affected with murmurs or gallop and significantly with heart failure (MARKS, 1993). The majority of identified dogs have been males, of younger age (less than 5 yrs) and the condition was reported to be inherited in pointers (SISSON, 1990). Though some scattered information

*Corresponding author:

Dr. Satish Kumar, K., Assistant Professor, Department of Veterinary Clinical Medicine, College of Veterinary Science, Rajendranagar, Hyderabad-500 030, Andhra Pradesh, India, Phone: +91 98484 21375, E-mail: dr_petlover@yahoo.co.in

is available in literature published abroad on HCM dogs, there is a dearth in India. The present paper is the first of its kind in India to record retrospectively the manifestations, diagnosis and therapeutic management of hypertrophic cardiomyopathy in dogs.

Materials and methods

The present investigation was carried out at the Teaching Veterinary Clinical Complex (TVCC), Bhoiguda, College of Veterinary Science, Hyderabad, Andhra Pradesh, India over a period of 4 years (2004-2008). Out of a total of 1276 dogs of various breeds, ages and both sexes presented to the Cardiology ward with symptoms suggestive of cardio-pulmonary disease, on the basis of echocardiographic findings 12 dogs were diagnosed for HCM. At the time of presentation all the HCM dogs had been clinically evaluated at various hospitals and had been under conventional therapy for heart failure (enalapril and frusemide) for a couple of weeks but with no improvement. All the twelve dogs were subjected to physical examination. Electrocardiography was performed in right lateral recumbancy using a BPL Cardiart 1608 and whereas radiographic evaluation was done on left lateral and ventro-dorsal exposures using a Siemens X-ray unit. Further, blood was collected for complete blood count, serum biochemical profile and thyroid profile. The presence of canine heart worm was also tested by heartworm antigen test using Agen CHW® kit. Finally, Cardiac ultrasonography was performed using *Ixos* vet ultrasound / Doppler machine supplied by Esoate Pie Medicals, Netherlands. A micro convex Array C5-2 R13 cardiac probe was used for echocardiographic studies. All the twelve dogs confirmed for HCM were treated with oral diltiazem at the rate of 1.5 mg/kg, ramipril at the rate of 0.5 mg/kg, BID for 15 days followed by SID for 30-60 days and frusemide at the rate of 2 mg/kg, SID, PO for 10 days.

Results

All twelve dogs were presented with similar manifestations such as: exercise intolerance, poor appetite, lethargy and cough for more than two weeks. Further, seizures (8 dogs), syncope (6 dogs) and both (3 dogs) were also reported when excited. The twelve dogs (11 male and 1 female) diagnosed for HCM were aged between 10-13 years and 9 were Boxers and 3, Doberman pinchers. Physical examination revealed lethargy, ascites (3 dogs) with normal temperature, pulse and respiratory rates. Mild systolic murmurs were detected on auscultation of the cardiac area on the left side of the thorax between the 3rd to 5th intercostal spaces, and mild crackles over lung area.

The mean haematological parameters viz: total erythrocyte count, haemoglobin, total leukocyte count and differential count, were well within the normal range. The mean creatine kinase MB (89.6 ± 0.72 U/L) and lactate dehydrogenase (144.68 ± 1.24 U/L) levels were elevated when compared to the mean levels of healthy dogs (22.26 ± 0.14 U/L).

and 80.45 ± 0.58 U/L). However, the other serum biochemical parameters (total serum proteins, albumin, aspartate amino transferase and cholesterol) were within the normal range. No abnormality was detected in the values of T3, T4 and TSH. Further, the test for heartworm antigen was also negative.

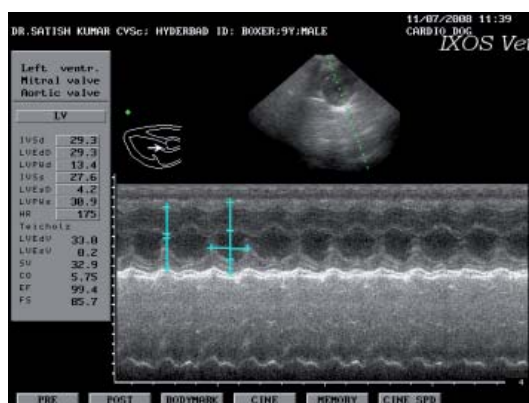


Fig. 1. Hypertrophied interventricular septum and left ventricle free wall. Also note increased fractions (EF & FS).

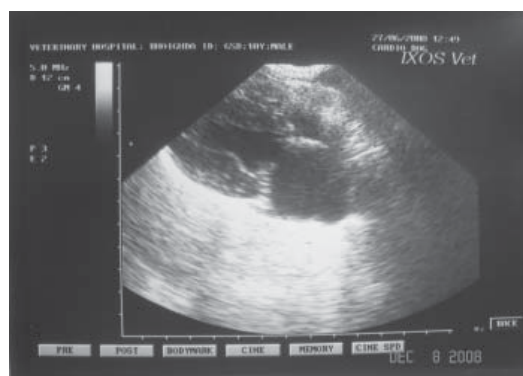


Fig. 2. Thickened left ventricle free wall and interventricular septum. Also note enlarged left atrium.

Electrocardiographic abnormalities include increased R wave amplitude, deep Q wave and ST coving. Five of the twelve dogs also revealed wide and bizarre QRS complexes.

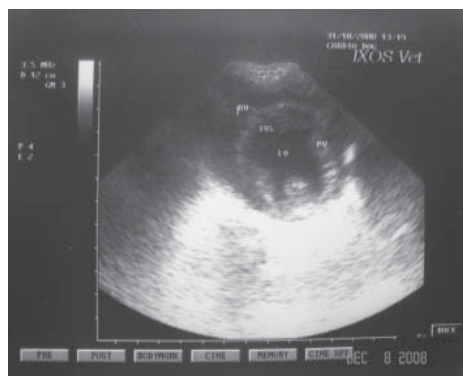


Fig. 3. Muscular ridge on short axis view-a third papillary muscle appearance

Thoracic radiography revealed cardiomegaly and moderate pulmonary edema suggestive of left side heart failure. However, abdominal radiograph in 2 ascitic dogs with pendulous abdomen, revealed a ground glass appearance and loss of overall visceral detail, consistent with ascites. Abdominal ultrasonography also revealed an anechoic region in the abdominal cavity, suggestive of fluid accumulation.

Two-dimensional echocardiography revealed a thickened left ventricular free wall and interventricular septum (Fig.1). The left ventricular chambers appeared smaller and the left atrial diameter larger than normal (Fig. 2). Functional obstruction to outflow was not observed during systole; however, pressure gradients across the outflow tract were not measured. M-mode echocardiography revealed a mean ejection fraction (92%) and fractional shortening (86%) that were greater than normal (Fig. 1). Further, a muscular ridge of the myocardium was also present in the left ventricle outflow tract on a short axis view (Fig. 3).

Based on the echocardiographic, radiographic and electrocardiographic findings, along with the history of seizures and/or syncope, the condition was diagnosed as hypertrophic cardiomyopathy. After the initiation of therapy with diltiazam, ramipril and frusemide, clinical improvement was noticed from day 3 (in 8 dogs) and 5 (in 4 dogs). The crackles and murmurs that had been auscultated diminished in intensity, coughing was less frequent and the amount of ascitic fluid decreased by day 5 (in 8 dogs) and 7 (in 4 dogs). Complete alleviation of clinical signs with absence of cough, ascites (2 dogs), improvement in physical activity and appetite was observed by day 30 in all the HCM dogs. However, the owners were advised to continue diltiazem (1.5 mg/kg, PO) and ramipril (0.5 mg/kg, PO). It was reported that all the dogs continued to improve and became much brighter and active over the next 30 days. After therapy, no appreciable changes in thoracic radiographs were noticed except the absence of pulmonary edema. Similarly

apart from the absence of arrhythmias, no differences in ECG and echocardiographic features were detected in all the HCM treated dogs, suggestive of clinical recovery.

Discussion

Primary HCM is characterized by hypertrophy of the left ventricle, a small left ventricular cavity and diastolic dysfunction associated with decreased left ventricular compliance and increased filling pressure. It results in pulmonary edema, dyspnoea, inadequate cardiac output, lethargy and sudden death (MARON and EPSTEIN, 1979). Although the disease is commonly diagnosed in cats and human beings, it is an infrequently identified cause of heart disease in dogs, and the majority of identified dogs are males (SISSON et al., 1999). The cause of primary HCM is not known. In dogs, HCM is commonly noticed in German Shepherds, Boxers, Rottweilers and Doberman Pinchers (SISSON and THOMAS, 1995).

Elevated R wave, ST coving, bizarre QRS complexes observed in the present dogs are the common ECG abnormalities associated with HCM in dogs (MARKS, 1993). These abnormalities were suggestive of left ventricle enlargement with ventricular conduction abnormalities.

When the left ventricle hypertrophies, the anterolateral free wall and the interventricular septum are affected; however, the septum is usually more severely affected than the left ventricular free wall. A septal-to-free wall thickness ratio >1 suggests the possibility of functional outflow obstruction (MARON and EPSTEIN, 1979). Septal-free wall thickness ratios in 10 dogs ranged from 1.1 to 1.5; in the majority (6 dogs) it was greater than or equal to 1.3 (LIU et al., 1979). In the dogs in our study, the septal-to-free wall thickness ratio was 1 and subjective assessment with two-dimensional echocardiography suggested that there was no obstruction. However, because pressure gradients across the outflow tract were not measured, non-obstructive HCM could not be confirmed.

A complete echo and Doppler examination is the best method to evaluate HCM and dynamic left ventricular outflow tract obstruction (DLVOTO). The most common echocardiographic feature of canine HCM is the presence of left ventricular concentric hypertrophy. A muscular ridge of myocardium is some times present in the LVOT, that can be most easily appreciated on a short axis view where it assumes the presence of an accessory papillary muscle (SISSON et al., 1999). Mitral flow showing a decreased E peak, increased A velocities and deceleration times, indicates impaired ventricular relaxation (MARON and EPSTEIN, 1980; MAJO et al., 2003). In the present study, no such mitral valve abnormalities were detected on echocardiography.

Thickening of the ventricular walls increases myocardial oxygen demand and the distance between capillaries. These multiple structural changes may predispose the myocardium to regional ischemia and subsequent scarring (KATA, 1990; LIU et al., 1979).

One aspect of diastolic dysfunction seen with HCM is incomplete, asynchronous relaxation of the heart. This impaired relaxation could be explained, in part, by abnormalities in myocardial calcium kinetics that cause an increase in the intracellular calcium concentration. An increase in the number of calcium channels, mediating abnormal calcium fluxes, helps by some unknown mechanism to produce hypertrophy and fibre disarray (WYNNE and BRAUNWALD, 1997). Two principle functional disturbances occur in patients with HCM: impaired diastolic filling and dynamic LVOT obstruction. Altered diastolic filling is the most pervasive hemodynamic change in human patients, as it is abnormal in patients with and without LVOT obstruction (WYNNE and BRAUNWALD, 1997). Diastolic dysfunction results from impaired relaxation in the early diastolic phase and from reduced ventricular compliance. The reduced rate and uniformity of ventricular relaxation in early diastole are thought to be caused by abnormal myocardial calcium kinetics, which results in increased concentration of intracellular calcium (MARON et al., 1987). The consequences of diastolic dysfunction include an impaired ability to increase cardiac output during stress or exercise, as well as a propensity to develop pulmonary congestion and edema due to increased left atrial and pulmonary venous pressures. Any increase in the heart rate exacerbates the severity of diastolic dysfunction.

Drugs that enhance ventricular relaxation and slow the heart rate, including the beta adrenergic and calcium channel blockers, are indicated in the treatment of the diastolic dysfunction of HCM. Beta blockers improve diastolic performance only indirectly, enhancing ventricular filling by reducing heart rate and improving myocardial perfusion. Traditionally, beta-blockers have been administered orally to reduce and prevent elevations in left ventricle end diastole pressure, to lower systolic pressure gradients and myocardial oxygen requirements, to prevent stress-induced tachycardia and reduce resting heart rate and for their anti-arrhythmic effects. When arrhythmias are present, this drug may be initiated earlier in the disease course. Calcium channel blocking agents have been effective in human HCM by reducing heart rate, myocardial oxygen consumption and diastolic dysfunction. In addition to directly enhancing myocardial relaxation, these drugs produce strong coronary vasodilatation and a mild peripheral one. Authors have demonstrated the utility of diltiazem in the treatment of feline HCM, including those cases refractory to the beta blockers (BRIGHT and GOLDEN, 1991). Calcium channel blockers have been shown to be effective in the management of HCM. They decrease intracellular calcium concentrations, thereby helping to promote relaxation and improve filling of the heart (BRIGHT et al., 1999). Administration of diltiazem, the calcium channel blocker used in the dogs in the present study resulted in a sustained improvement in clinical signs for several weeks.

A reduction in wall thickness was reported with the administration of enalapril to cats with HCM (TAUGNER, 2001). This suggests a potential role for ACE-inhibitors in

the treatment of HCM, while it is logical that the rennin-angiotensin-aldosterone system is not pathologically activated in asymptomatic patients, and hence ACE-inhibitors might not be useful in them. These drugs are generally safe and do play a role in symptomatic HCM dogs. Angiotensin converting the enzyme inhibitor, ramipril was also added for the present symptomatic HCM dogs as the Renin-Aldosterone activation system had been triggered and was responsible for the manifestations resulting in HCM. Frusemide, a loop diuretic, was also indicated to reduce fluid overload and resolve pulmonary edema in hypertrophic cardiomyopathy dogs (MARKS, 1993). Supplementation of diuretic in the present dogs was found effective in resolving abnormal fluid accumulations in body tissues.

Dogs exhibiting the clinical signs of heart failure did not always respond to conventional medical therapy for congestive heart failure. A complete cardiac evaluation, including echocardiography is essential in determining the exact cause and to initiate the correct treatment for heart failure patients. Addition of calcium channel blockers is more valuable in treating HCM dogs, as for the dogs in the present report it resulted in sustained improvement of clinical signs for several weeks.

References

- BRIGHT, J. M., A. L. GOLDEN (1991): Evidence for or against the efficacy of calcium channel blockers for management of hypertrophic cardiomyopathy in cats. *Vet. Clin. North. Am. Small. Anim. Pract.* 21, 1023-1034.
- BRIGHT, J. M., A. L. GOLDEN, R. E. GOMPF (1999): Evaluation of the calcium channel blocking agents diltiazem and verapamil for the treatment of feline hypertrophic cardiomyopathy. *J. Vet. Intern. Med.* 5, 272-282.
- KATA, A. M. (1990): Cardiomyopathy of overload-a major determinant of prognosis in CHF. *N. Engl. J. Med.* 322, 100-110
- LIU, S. K., B. J. MARON, L. P. TILLEY (1979): Hypertrophic cardiomyopathy in the dog. *Am. J. Pathol.* 94, 497-506.
- MAJO, M., D. DE BRITTI, M. MASUCCI, P. P. NIUTTA, V. PANTANO (2003): Hypertrophic obstructive cardiomyopathy associated to mitral valve dysplasia in the Dalmatian dogs; two cases. *Vet. Res. Com.* 27, 391-393.
- MARKS, C. A. (1993): Hypertrophic cardiomyopathy in a dog. *J. Am. Vet. Med. Assoc.* 203, 1020-1022.
- MARON, B. J., R. O. BONOW, R. O. CANNON (1987): Hypertrophic cardiomyopathy: interrelations of clinical manifestations, pathophysiology and therapy. II. *N. Engl. J. Med.* 316, 844-852.
- MARON, B. J., S. E. EPSTEIN (1979): Hypertrophic cardiomyopathy: a discussion of nomenclature. *Am. J. Cardiol.* 43, 1242-1244.

- MARON, B. J., S. E. EPSTEIN (1980): Hypertrophic cardiomyopathy: recent observations regarding the specificity of 3 hall marks of the disease: asymmetric septal hypertrophy, septal disorganisation and systolic anterior motion of the anterior mitral leaflet. *Am. J. Cardiol.* 45, 141-154.
- SISSON, D. D. (1990): Heritability of idiopathic myocardial hypertrophy and dynamic subaortic stenosis in pointer dogs. *J. Vet. Intern. Med.* 4, 118-124.
- SISSON, D. D., W. P. THOMAS (1995): Myocardial diseases. In: *Textbook of Veterinary Internal Medicine.* (Ettinger, S. J., E. C. Feldman, Eds.) 4th ed., W. B. Saunders, Philadelphia. pp. 995-119.
- SISSON, D., R. MICHEL, O'GRADY, A. C. CLAY (1999): Myocardial diseases of dogs. In: *Textbook of Canine and Feline Cardiology.* (Fox, P. R., D. Sisson, N. Sydney Moise, Eds.): 2nd ed., WB Saunders Co., Philadelphia, pp. 601-611.
- TAUGNER F. M. (2001): Stimulation of rennin-angiotensin aldosterone system in cats with hypertrophic cardiomyopathy. *J. Comp. Pathol.* 125, 122-129.
- WYNNE, J., E. BRAUNWALD (1997): The cardiomyopathies and myocarditides. In: *Heart Disease: A Textbook of Cardiovascular Medicine.* (Braunwald, E., Ed.). 5th ed., WB Saunders Co. Philadelphia, pp. 1404-1492.

Received: 5 August 2009

Accepted: 22 December 2009

KUMAR, K. S., P. NAGARAJ, V. V. V. A. KUMAR, D. S. T. RAO: Hipertrofična kardiomiopatija u 12 pasa (2004. - 2008.): prvi opis u Indiji. *Vet. arhiv* 80, 491-498, 2010.

SAŽETAK

Od 2004. do 2008. godine 1276 pasa različitih pasmina i spola s anamnezom i znakovima kardiopulmonalnih poremećaja bilo je pretraženo na Klinici Bhoiguda Kolidža veterinarske znanosti Hyderabad u Indiji. Na osnovi fizikalne, elektrokardiografske, radiografske i ehokardiografske pretrage u 12 je pasa bila dijagnosticirana hipertrofična kardiomiopatija. Pretragom kompletne krvne slike i biokemijskih pokazatelja u njih nisu bili ustanovljeni drugi poremećaji osim povišene razine kreatin kinaze MB i laktat dehidrogenaze. Svi psi s hipertrofičnom kardiomiopatijom pokazivali su uobičajene znakove kao što su nevoljko kretanje, slab apetit, pospanost, napadaje kašlja (osam pasa) i nesvjestice (6 pasa) tijekom nekoliko tjedana. Psi su bili liječeni više od mjesec dana diureticima i inhibitorima enzima konverzije angiotenzina, ali bez ikakva poboljšanja. Nakon primjene diltiazema istodobno s ramiprilom i furosemidom zabilježeno je kliničko poboljšanje za tri do pet dana, a potpun klinički oporavak za 30 do 60 dana. Iz postignutih rezultata može se zaključiti da je ehokardiografija najosjetljivija metoda za dijagnosticiranje, a da je diltiazem važan za uspješno liječenje hipertrofične kardiomiopatije u pasa.

Ključne riječi: hipertrofična kardiomiopatija, pas, diltiazem
