

Endocrine profile and testicular histomorphometry in neonatal rats of diabetic mothers

Gholamali Jelodar^{1*}, Zabiholah Khaksar², and Mohammad Pourahmadi³

¹ Department of Physiology, School of Veterinary Medicine, Shiraz University, Shiraz, Iran

² Department of Histology, School of Veterinary Medicine, Shiraz University, Shiraz, Iran

³ Department of Anatomy and Histology Jahrom, University of Medical Sciences, Iran

JELODAR, G., Z. KHAKSAR, M. POURAHMADI: Endocrine profile and testicular histomorphometry in neonatal rats of diabetic mothers. Vet. arhiv 80, 421-430, 2010.

ABSTRACT

This study was conducted to evaluate the effects of maternal diabetes on foetal testicular structure and function, and reproductive hormone level. Sixteen adult female rats were divided into two groups. Diabetes was induced in one group by alloxan. Both groups became pregnant by natural mating. Blood was collected from 30-day old male offspring and the level of testosterone, FSH and LH measured in their serum. The weight and volume of the testes and various histological parameters of the testes were determined. The results showed a significant decrease in LH, FSH and testosterone in the sera of offspring from diabetic mothers (ODM) compared with the control group. Weight and volume of testes were approximately 30% and 27.5% respectively less than those of the control group ($P < 0.05$). In histological sections the number of seminiferous tubules (ST) increased significantly (28.9%) ($P < 0.05$), whilst thickness of the testicular capsule (-17%), the number of Leydig cells (-28%), Sertoli cells (-11%), spermatogonia (-11%) and the diameter of ST (-21.8%) showed significantly reduced values in the ODM compared to controls ($P < 0.05$). In conclusion maternal hyperglycemia has a deleterious effect on testicular parameters during fetal life, which will affect reproductive endocrinology in the postnatal period and may impact on fertility.

Key words: maternal diabetes, testis, rat, histomorphometry, endocrine

Introduction

In diabetic mothers during pregnancy placental transport of glucose and other nutrients increases due to the increased availability at the maternal site, resulting in foetal and neonatal macrosomia (PEDERSEN, 1977; PERSSON and HANSON, 1998). The elevated glucose concentration in the mother accompanying hyperglycaemia in the foetus leads to degranulation of the foetal β -cells, resulting in foetal hypoinsulinaemia (VAN ASSCHE

*Corresponding author:

Dr. Gholamali Jelodar, Department of Physiology, School of Veterinary Medicine, Shiraz University, Shiraz, P.O Box 71345-1731, Iran, Phone: +98 71 1613 8757; Fax: +98 71 1228 6940; E-mail: jelodar@shirazu.ac.ir

et al., 1983). The pancreas of a foetus born to a mother whose diabetes is inadequately controlled (blood glucose $>16.7 \text{ mmol.L}^{-1}$) shows degranulation of the majority of β -cells (VAN ASSCHE et al., 1983).

The consequences of diabetes during pregnancy are not confined to foetal and neonatal life. Several epidemiological studies show that consequences extend to adult life and even to the next generation through the maternal line. KNOWLER et al. (1985) showed that the risk for diabetes is significantly higher in the offspring of mothers who have non-insulin-dependent diabetes.

Data indicate that pre-gestational maternal diabetes is associated with strong teratogenic effects on the kidney, urinary tract and heart and is strongly associated with multiple congenital abnormalities (CHUNG and MYRIANTHOPOULOS, 1975). The malformations often involve the heart and central nervous system and are potentially lethal. Major congenital anomalies are 2-4 times more common in diabetic pregnancies than in normal pregnancies (DRAZANCIC et al., 1993).

One of the mammalian systems that is clearly impaired in diabetes is the male reproductive function. Diabetes induced alterations of Leydig cell functions include a decrease in androgen synthesis and in the total number of these cells. Together, these effects cause impairment in male libido (FOGLIA et al., 1969). Disturbances in sexual function, including a decrease in libido, impotence and infertility have been reported to be due to testicular dysfunction associated with sustained hyperglycaemia in diabetic rats (CAMERON et al., 1990). Spontaneously diabetic BB rats also show a decrease in testicular testosterone production, indicating that this process is inherent to this disease. Moreover, this alteration is responsible for the diabetes-related effects on libido (HASSAN et al., 1993). The diabetic bio-breeding (BB) rat also shows altered spermatogenesis (MURRAY et al., 1983). Lower pregnancy rates have been associated with basic fertility potential in diabetic men and variations in semen quality have been reported in these patients (FAIRBURN et al., 1982; VIGNON et al., 1991). Diabetes-related effects on testicular function have been attributed to the lack of insulin. The regulatory action of this hormone is known and observations of a direct effect on both Leydig cells (KHAN et al., 1992; HURTADO et al., 1998) and Sertoli cells (BORLAND et al., 1984; MITA et al., 1985) have been reported. Testicular function is primarily controlled by pituitary hormones. The follicle-stimulating hormone (FSH) regulates spermatogenesis, whereas the luteinizing hormone (LH) controls Leydig cell function. Decreases in the serum level of FSH, LH, prolactin and growth hormone have been reported in diabetes (HUTSON et al., 1983; BENÍTEZ and PÉREZ DÍAZ, 1985).

The foetus of a diabetic mother also experiences hyperglycaemia and hypoinsulinaemia, which may have an adverse effect on their reproductive system (endocrine and testicular structure) during foetal development. The aim of this investigation was to evaluate the

effect of maternal diabetes on foetal testicular structure and function and reproductive hormone level (gonadotropins and testosterone) which may contribute to further complications and infertility

Materials and methods

Animals. Sixteen adult female Sprague Dawley rats (weighing 200-230 g and 4-5 months old) were housed in an air conditioned room (22 ± 2 °C) and supplied with standard pellet food with tap water *ad libitum*. The animals were divided into two groups: diabetic and normal (control). The animals were cared for and treated in accordance with the guidelines for laboratory animals established by the National Institute of Health as well as by the local ethical committee.

Induction of diabetes mellitus. Diabetes was induced in 8 rats by a single intraperitoneal injection of Alloxan tetrahydrate (Sigma, St. Louis, MO, USA) (150 mg/kg) according to previous experience. The animals fasted 12h before and after the injection. Rats with blood glucose level above 200 mg/dL, as well as polydipsia, polyuria and polyphagia for at least one week were considered as diabetic and selected for the study.

Experimental design. Female animals from both groups at the oestrus stage of the reproductive cycle were caged with male rats for mating. Mating was confirmed by the observation of a vaginal plug. Male offspring from both groups were reared in equivalent conditions in an animal-house for 30 days. At the end of the experiment, animals were anesthetized with diethyl ether and killed by whole blood collection through a heart puncture. Blood serum was isolated and used for endocrine analysis. The volume of the fresh isolated testes was obtained, using the Archimedes principle, by immersion in distilled water (ELIAS and HYDE, 1980), followed by fixation in 10% buffered formalin solution.

Histomorphometric study. Formaldehyde-fixed samples were embedded in paraffin and then sliced (section thickness, 4-5 μm). They were deparaffinised with xylol and histological observations were performed after staining with haematoxylin-eosin and Green Masson's Trichrome method (LUNA, 1968).

For histomorphological and histomorphometric study, the sections were observed under a light microscope, and the following factors were evaluated in the testes of both control and test groups: (1) thickness of the testicular capsule, (2) the number of seminiferous tubules/ mm^2 , (3) the number of Leydig cells/ mm^2 , (4) the average number of Sertoli and spermatogonia cells in seminiferous tubules and (5) the diameter of the seminiferous tubules.

Testicular capsule thickness. Thickness of the testicular capsule was measured at $\times 100$ magnification using Olysia software (Olysia soft imaging system provided by

Olympus 2000) and an Olympus BX51 light microscope. At least six points of capsule sections were chosen randomly and measured for each test.

Counting of seminiferous tubules. Seminiferous tubules were counted at $\times 40$ magnification, using a 441- intersection grid placed in the ocular of the light microscope (Olympus BX51). Ten sections were chosen at random, from each testis, and the number of round or nearly round seminiferous tubuli in a square millimeter (mm^2) was obtained.

Leydig cells. The number of Leydig cells per unit (mm^2) was determined at $\times 1000$ magnification, using a 441- intersection grid placed in the ocular of a light microscope (Olympus BX51). Ten sections were randomly chosen for each testis, the total of Leydig cell nuclei was counted, and the mean of Leydig cells per unit was scored.

Spermatogonia and Sertoli cells. All spermatogonia and Sertoli cells were counted at $\times 1000$ magnification, at least ten round or nearly round seminiferous tubule cross-sections, chosen randomly for each testis. The total number of spermatogonia and Sertoli cells per seminiferous tubule were determined from the corrected counts of spermatogonia cell nuclei and Sertoli cell nucleoli per seminiferous tubule cross section (FRANCA et al., 2005).

Analytic procedures in serum samples. Serum testosterone, FSH and LH levels were measured by the radioimmunoassay (RIA) technique and commercial kit (Immunotech-Radiova, Prague, Czech Republic). The intra-assay and inter-assay coefficient for FSH was below or equal to 2.6% and 6.3% respectively. The intra-assay and inter-assay for LH was below or equal to 3.5% and 8.8% respectively. For testosterone the intra-assay and inter-assay was below or equal to 14.8% and 15% respectively.

Statistical analysis. Morphometric data are presented as the mean \pm SD, and to analyze these data, the Student's *t* test was performed using the Statistical Package for Social Sciences (SPSS) program. Significant differences were considered when $P < 0.05$.

Results

Comparison of body weights. The changes in body weights of newborns at birth and day 30 are presented in Table 1. Significant ($P < 0.05$) changes in body weight were noticed on day 1 (33%) and 30 (42%).

Table 1. Comparison of body weight (mean \pm SD) between two groups (n = 10)

Age (day)	Weight of control (gr)	Weight of ODM (gr)	Percent of changes
1	4.5 \pm 0.5	6.0 \pm 0.5	33
30	49.6 \pm 12.8	70.8 \pm 7.3	42

Significant difference observed between two groups ($P < 0.05$). ODM: Offspring of diabetic mother.

Hormone level. Levels of serum testosterone in offspring from diabetic mothers (ODM) were significantly lower than in the control group (2.7 ± 0.64 vs. 4.81 ± 0.81 ng/mL). As shown in Fig. 1, serum gonadotropins; FSH (2.76 ± 0.92 vs. 7.5 ± 0.35 IU/mL) and LH (0.23 ± 0.08 vs. 0.44 ± 0.09 IU/mL) also showed a significant decrease in the ODM when compared with control values ($P < 0.05$).

Table 2. Comparison of testicular parameter (mean \pm SD) between two groups (n = 10)

Parameter*	Control	Offspring of diabetic mother	Percent of changes
Testicular volume (mm ³)	361.01 \pm 41.2	260.03 \pm 53.6	27.5
Testicular weight (g)	0.37 \pm 0.05	0.26 \pm 0.05	30
Spermatogonia/ST	86.79 \pm 11.56	78.5 \pm 8.63	11
Sertoli cell/ST	29.72 \pm 6.96	25.02 \pm 3.51	11
ST/mm ²	18.7 \pm 2.52	23.33 \pm 2.51	28.9
Leydig cell/mm ²	740.12 \pm 185.41	575 \pm 171.30	28
ST diameter (μ m)	179.44 \pm 10.41	140.38 \pm 10.61	21.8
Thickness of capsule (μ m)	19.75 \pm 0.71	16.65 \pm 0.91	17

All measured testicular parameters showed a significant difference between two groups ($P < 0.05$). ST: Seminiferous tubule.

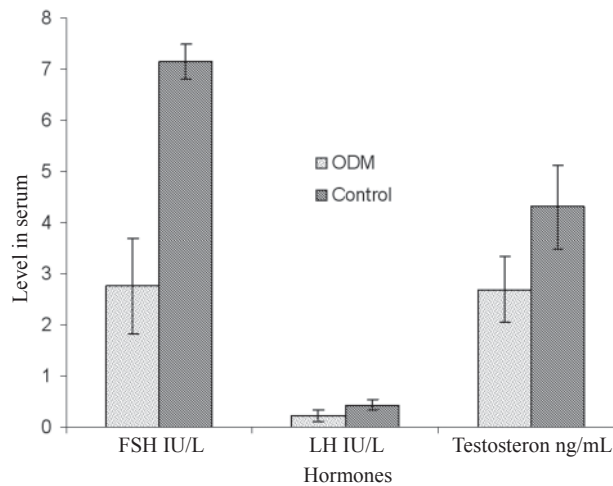


Fig. 1. Comparison of hormone levels in control and offspring of diabetic mothers (ODM). Significant difference observed for all measured hormones between two groups ($P < 0.05$)

Testicular histomorphology. The values obtained for various testicular parameters are presented in Table 2. In the ODM group, average weight and volume of testes were about 30% (0.37 ± 0.05 vs. 0.26 ± 0.05 gr) and 27.5% (361.01 ± 41.2 vs. 261.03 ± 53.6 mm³) respectively higher than those of the control group ($P < 0.05$). All histomorphologic testicular parameters, except the number of seminiferous tubules per square millimeter (+28.9%), showed significantly lower values in ODM compared to the control ($P < 0.05$), that is the thickness of the testicular capsule (-17%), the number of Leydig cells per square millimeter (-28%), the number of Sertoli cells in each seminiferous tubule (-11%), the number of spermatogonia in seminiferous tubule (-11%) and the diameter of seminiferous tubules (-21.8%).

Discussion

The body weight of newborns of diabetic mothers at birth and day 30 was significantly higher than the controls; this could be due to increased placental transport of glucose and nutrients (PERSSON and HANSON, 1998). Levels of FSH, LH and testosterone in ODM were significantly lower than that of the controls. A decrease in levels of FSH, LH, prolactin and growth hormone has been reported in diabetic rats (HUTSON et al., 1983; BENÍTEZ and PÉREZ DÍAZ, 1985). Diabetes induces a decrease in the serum level of LH, which is responsible for normal Leydig cell function (testosterone secretion) (BENÍTEZ and PÉREZ DÍAZ, 1985). The pituitary of diabetic rats has a blunted response, with diminished stimuli-induced secretion of FSH and LH (SEETHALAKSHMI et al., 1987). Moreover, a relationship between insulin/glucose and LH/FSH levels in serum has been proposed, although the mechanisms by which insulin, glucose, or both, controls these two hormones is unclear (BALLESTER et al., 2004). Decreases in testosterone levels may be related to decreases in LH, a decrease in the number of Leydig cells or both. This situation has been reported in male diabetic rats (BALLESTER et al., 2004).

Decreases in testicular weight and volume observed in the offspring of diabetic mothers may be related to important intracellular events, such as a decrease in the number of interstitial cells and Sertoli cells in the seminiferous tubule. Our histomorphometric results confirmed that in smaller testes (testes of ODM), the number of Leydig and Sertoli cells was reduced when compared to the control group. To our knowledge this is the first report about endocrine profiles and histomorphological study of gonads in offspring from diabetic mothers. Existing data suggest that the altered maternal glucose metabolism at the critical time during embryogenesis is a major determinant of the risk of anomalies in pregnancies complicated by diabetes (SCHAEFER-GRAF et al., 2000). Severe hyperglycemia in the maternal rat results in hyperglycemia and hypoinsulinemia of the fetuses and fetal growth retardation (AERTS and VAN ASSCHE, 1977; DEVASKAR et al., 1990). The decrease in the number of Leydig cells observed in the ODM group may

be due to hypoinsulinemia occurring during fetal life. Induced diabetes was reported to cause a decrease in total Leydig cell numbers and impairment in cell function due to hypoinsulinemia (BALLESTER et al., 2004). The remarkable decrease in the expression of interstitial tissue insulin receptors in diabetic rats, together with the virtual absence of serum insulin, is expected to lead to a total loss of insulin-mediated stimulation of androgen biosynthesis and cell proliferation, which is consistent with the morphologic alterations in the interstitial tissue observed.

Two parallel mechanisms were proposed to cause diabetes-related alterations in Leydig cells: (1) the effect of hypoinsulinaemia on serum LH level and (2) the combined effects of decreased level of LH and insulin on Leydig cells (BALLESTER et al., 2004). Moreover, diabetes mellitus has been reported to alter the activity of arginase (an enzyme important in cell proliferation) in the reproductive system, which may impair Leydig cell proliferation (JELODAR et al., 2007).

In the ODM group the number of seminiferous tubules per square millimetre increased, whilst the diameter of each tube decreased. This condition was accompanied by a decrease in FSH levels in the serum. A decrease in FSH in diabetic rats will decrease tubular FSH receptors, which in turn will diminish the response of the epithelium of seminiferous tubules to FSH stimulation significantly (BALLESTER et al., 2004). Additionally, a decrease in the expression of insulin receptors could lead to a loss of insulin-mediated cell proliferation in the seminiferous tubule (BALLESTER et al., 2004). Both conditions will decrease the number of spermatogonia in the seminiferous tubules, leading to a decrease in seminiferous tubule diameter. A decrease in seminiferous diameter was also reported in alloxan diabetic rats (HASSEN et al., 2007). The decrease in seminiferous tubules could be the cause of the increased number of seminiferous tubules per square millimetre.

In conclusion maternal hyperglycemia has a significant deleterious effect on reproductive endocrine and testicular structure and function. This detrimental change is likely to have occurred during foetal life, remains during postnatal life and shows a similar pattern of change as previously reported in adult male diabetic rats. Evaluation of postpubertal reproductive factors remains to be determined.

References

- AERTS, L., F. A. VAN ASSCHE (1977): Rat foetal endocrine pancreas in experimental diabetes. *J. Endocrinol.* 73, 339-346.
- BALLESTER, J., M. C. MUNOZ, J. DOMINGUEZ, T. RIGAU, J. J. GUINOVART, J. E. RODRIGUEZ-GIL (2004): Insulin-dependent diabetes affects testicular functions by FSH and LH-linked mechanisms. *J. Androl.* 25, 706-719.
- BENÍTEZ, A., J. PÉREZ DÍAZ (1985): Effect of streptozotocin-diabetes and insulin treatment on regulation of Leydig cell function in the rat. *Horm. Metab. Res.* 17, 5-7.

- BORLAND, K., M. MITA, C. L. OPPENHEIMER, L. A. BLINDERMAN, J. MASSAGUE, P. F. HALL, M. P. CZECH (1984): The actions of insulin-like growth factor-I and -II on cultured Sertoli cells. *Endocrinology* 114, 240-246.
- CAMERON, D. F., J. ROUNTREE, R. E. SCHULTZ, D. REPETTA, F. T. MURRAY (1990): Sustained hyperglycemia results in testicular dysfunction and reduced fertility potential in BBWOR diabetic rats. *Am. J. Physiol.* 259, 881-889.
- CHUNG, C. S., N. C. MYRIANTHOPOULOS (1975): Factors affecting risks of congenital malformations. II Effect of maternal diabetes on congenital malformations. *Birth Defects* 11, 23-38.
- DEVASKAR, S., K. MCMENAMY, L. HOLTZCLAW, F. SADIQ (1990): Long-term maternal-fetal exposure to high-low insulin concentrations alter liver but not brain insulin receptors. *Am. J. Obstet. Gynecol.* 163, 1350-1356.
- DRAZANCIC, A., J. BLAJIC, J. DJELMIS (1993): Early spontaneous abortions and congenital malformations in relation to diabetes regulation in very early pregnancy. 24th Annual Meeting of Diabetic Pregnancy. Silkeborg, Denmark, Abstract 3.
- ELIAS, H., D. M. HYDE (1980): An elementary introduction to stereology (quantitative microscopy). *Am. J. Anat.* 159, 411-417.
- FAIRBURN, C. G., D. K. MCCULLOCH, F. C. WU (1982): The effects of diabetes on male sexual function. *J. Clin. Endocrinol. Metab.* 11, 749-765.
- FOGLIA, V. G., J. M. ROSNER, M. RAMOS, B. E. LEMA (1969): Sexual disturbances in the male diabetic rat. *Horm. Metab. Res.* 1, 72-77.
- FRANCA, L. R., M. O. SUESCUN, J. R. MIRANDA, A. GIOVAMBATTISTA, M. PERELLO, E. SPINEDI, R. S. CALANDRA (2005): Testis structure and function in a non-genetic hyperadipose rat model at prepubertal and adult ages. *Endocrinol.* 147, 1556-1563.
- HASSAN, A. A., M. M. HASSOUNA, T. TAKETO, C. GAGNON, M. M. ELHILALI (1993): The effect of diabetes on sexual behaviour and reproductive tract function in male rats. *J. Urol.* 149, 148-154.
- HASSEN, N. S., N. M. EI ROUBI, E. A. OMARA (2007): Evaluation of the influence of each of melatonin and chromium against diabetes-induced alteration in the testis of Albino rats using light and electron microscopies. *Egyp. J. Hospital Med.* 27, 143-162.
- HURTADO DE CATALFO, G. E., I. DEGO´MEZ DUMM (1998): Lipid dismetabolism in Leydig and Sertoli cells isolated from streptozotocin-diabetic rats. *Int. J. Biochem. Cell Biol.* 30, 1001-1010.
- HUTSON, J. C., D. M. STOCCO, G. T. CAMPBELL, J. WAGONER (1983): Sertoli cell function in diabetic, insulin-treated diabetic and semi-starved rats. *Diabetes* 32, 112-116.
- JELODAR, G. A., N. RAZMI, V. GOLAMPOUR (2007): Arginase alteration in reproductive system of alloxan diabetic dogs. *J. Reprod. Dev.* 53, 317-321.
- KHAN, S., K. TEERDS, J. DORRINGTON (1992): Growth factor requirements for DNA synthesis by Leydig cells from the immature rat. *Biol. Reprod.* 46, 335-341.

- KNOWLER, W., D. J. PETTITT, C. L. KUNZELMAN, J. EVERHART (1985): Genetic and environment determinants of non-insulin dependent diabetes mellitus. *Diabetes Res. Clin. Practice*, Suppl. 1, S309.
- LUNA, L. G. (1968): Manual of histologic staining methods of the armed forces institute of pathology 3rd ed. *Am. Registry Pathol.* 34-35, 76-77.
- MITA, M., K. BORLAND, J. M. PRICE, P. F. HALL (1985): The influence of insulin and insulin-like growth factor-I on hexose transport by Sertoli cells. *Endocrinology* 116, 987-992.
- MURRAY, F. T., D. F. CAMERON, J. M. ORTH (1983): Gonadal dysfunction in the spontaneously diabetic BB rat. *Metabolism* 32, 141-147.
- PEDERSEN, J. (1977): The pregnant diabetic and her newborn: problems and management, 2nd ed. Baltimore, Md: Williams and Wilkins, pp. 211-220.
- PERSSON, B., U. HANSON (1998): Neonatal morbidities in gestational diabetes mellitus. *Diabetes Care* 21, 79-84.
- SCHAEFER-GRAF, U. M., T. A. BUCHANAN, A. XIANG, G. SONGSTER, M. MONTORO, S. L. KJOS (2000): Patterns of congenital anomalies and relationship to initial maternal fasting glucose level in pregnancies complicated by type 2 and gestational diabetes. *Am. J. Obstet. Gynecol.* 182, 313-320.
- SEETHALAKSHMI, L., M. MENON, D. DIAMOND (1987): The effect of streptozotocin induced diabetes on the neuroendocrine-male reproductive tract axis of the adult rat. *J. Urol.* 138, 190-194.
- VAN ASSCHE, F. A., L. AERTS, F. A. DE PRINS (1983): Degranulation of the insulin-producing B cells in an infant of a diabetic mother. Case report. *Brit. J. Obstet. Gynecol.* 90, 182-185.
- VIGNON, F., A. LEFAOU, D. MONTAGNON (1991): Comparative study of semen in diabetic and healthy men. *Diabetes Metab.* 17, 350-354.

Received: 6 May 2009

Accepted: 22 December 2009

JELODAR, G., Z. KHAKSAR, M. POURAHMADI: Endokrinski profil i histomorfometrijska obilježja sjemenika u netom okoćenih štakorčića podrijetlom od dijabetičnih majki. *Vet. arhiv* 80, 421-430, 2010.

SAŽETAK

Istraživanje je bilo poduzeto radi procjene učinka dijabetesa majki na građu i funkciju sjemenika te razinu spolnih hormona njihovih potomaka. Šesnaest odraslih štakorica bilo je podijeljeno u dvije skupine. Dijabetes je u jednoj skupini bio prouzročen aloksanom. Štakorice obje skupine postale su skotne prirodnim parenjem. Muškim potomcima u dobi od 30 dana bila je uzeta krv za određivanje serumske razine testosterona, folikulostimulirajućeg i luteinizirajućeg hormona. Mjerena je masa i obujam sjemenika te promatrani različiti histološki pokazatelji. Rezultati su pokazali značajno smanjenje razine luteinizirajućeg i folikulostimulirajućeg hormona te testosterona u uzorcima seruma potomaka dijabetičnih majki u usporedbi s kontrolnom skupinom. Masa sjemenika dijabetičnih potomaka bila je približno za 30%, a obujam za 27,5% manji od mase i obujma

potomaka kontrolne skupine ($P < 0,05$). Broj sjemenonosnih tubula u histološkim rezovima bio je značajno povećan (28,9%) ($P < 0,05$), dok su drugi pokazatelji: debljina ovojnice sjemenika (-17%), broj Leydigovih stanica (-28%), broj Sertolijevih stanica (-11%), broj spermatogonija (-11%) i promjer sjemenonosnih tubula (-21,8 %) imali značajno smanjene vrijednosti u dijabetičnih štakora u odnosu na kontrolnu skupinu ($P < 0,05$). Može se zaključiti da hiperglikemija majke ima razarajući učinak na sjemenike tijekom fetalne faze što utječe na reprodukciju endokrinologiju u postnatalnom razdoblju te može utjecati na plodnost.

Ključne riječi: materinski dijabetes, sjemenik, štakor, histomorfometrija, endokrini nalaz
