

Reaction of bone tissue to cemented total hip replacement in sheep

Daroslav Franka¹, Valent Ledecký^{2*}, Jozef Bodnár³, Marián Hluchý²,
Slavomír Horňák², Michael Ushmirsky², Katarína Ledecká⁴,
and Lenka Skurková²

¹Veterinary Clinic, Trnava, Slovak Republic

²Department of Surgery, Orthopedics and Radiology of Small Animal Clinic, University of Veterinary
Medicine, Košice, Slovak Republic

³Private Cytodiagnostic Laboratory, Košice, Slovak Republic

⁴Buzulucká 16, Košice, Slovak Republic

FRANKA, D., V. LEDECKÝ, J. BODNÁR, M. HLUCHÝ, S. HORŇÁK, M. USHMIRSKY, K. LEDECKÁ, L. SKURKOVÁ: Reaction of bone tissue to cemented total hip replacement in sheep. Vet. arhiv 80, 329-342, 2010.

ABSTRACT

Sheep were used as a model for the examination of radiological and histological changes in bone tissue following total hip replacement. A unilateral total hip replacement procedure was carried out in sheep with radiological examinations at 1, 3 and 6 months after surgery. After six months, the sheep were euthanized and the bone tissue was collected for histology. The histological examination was focused on superficial reactive changes, bone reactive changes and type and numbers of the cells present. Radiological examination showed no pathological changes. Histological examination revealed new bone formation and remodelling in all samples, three of them (12.5%) exhibiting changes in resorption and new bone formation at the osteoid level. Cellular reaction involving the presence of reactive cells was minimal in all samples (macrophages, fibroblasts). Changes characteristic of the development of completely mature bone with evident bone structures, including the Havers system, were observed in eleven samples (45.83%). Disturbances of intactness of the cement coat resulted in cellular activity and aseptic loosening. In our case, cellular activity was minimal and some samples allowed us to observe signs of mature bones which indicated strong fixation of endoprosthesis in the bone tissue and alterations at cellular level ongoing even at sixth months following the total hip replacement.

Key words: aseptic loosening, histology, total hip replacement, sheep

Introduction

Total hip replacement is an orthopaedic procedure replacing a painful or damaged joint with an artificial one, the so-called endoprosthesis. This eliminates the cause of

*Corresponding author:

Prof. MVDr. Valent Ledecký, CSc., Department of Surgery of Small Animal Clinic, University of Veterinary Medicine in Košice, Komenského 73, 040 01 Košice, Slovak Republic, Phone: +42 1903 606 016; E-mail: ledecky@uvm.sk

pain and dysarthrosis. The patient can resume most of the activities he was used to doing before the joint involvement.

Aseptic loosening of prosthesis is the greatest problem associated with long-term hip replacement. It has been assumed that bone necrosis and loosening of prosthesis are caused by an exothermic re-polymerisation reaction of polymethylmethacrylate (PMMA), its toxicity or the presence of PMMA particles (CHARNLEY, 1970). These particles can cause osteolysis, resulting in partial or total loosening of the implant due to phagocytosis and incipient activation of macrophages, histiocytes and giant cells with the release of factors leading to vascularisation, proliferation, fibrosis and necrosis or apoptosis (CATELAS et al., 1999). The particles phagocytosed by macrophages frequently cause osteoclastic resorption of bones and act as precursors of aseptic loosening of the implant (MALONEY and SMITH, 1997). The process of aseptic loosening is associated with formation of a synovial-like membrane between the internal bone surface and the cement. A characteristic feature of this membrane is the granulomatous reaction to foreign bodies (GOLDRING et al., 1983; JOHANSON et al., 1987; XU et al., 1996). Steel particles released from the head of the endoprosthesis also activate macrophages and giant cells which precedes aseptic loosening of endoprosthesis (HUO et al., 1992; LEE et al., 1992; BRIEN et al., 1992). Polyethylene particles released from steel - polyethylene endoprostheses are phagocytosed by macrophages and may also result in aseptic loosening of endoprosthesis (HOWIE et al., 1993).

The aim of our study was to observe bone tissue reaction and determine cell types and numbers at the contact site of the total hip prosthesis and to confirm successful mastering of the technique involving cemented hip replacement for its use in clinical practice.

Materials and methods

Experimental animals. Unilateral total hip replacement was performed either on the left or right limb of 8 Slovak merino sheep of mean weight 46.6 kg (41-54 kg), 2-4 years old. One day before the operation the selected limbs were sheared and shaved. The sheep fasted for 24 hours and were not offered drinking water for 2 hours before the operation. Prior to anaesthesia, the sheep were administered 1 mg.kg⁻¹ flunixin meglumine i.m., and the same dose was administered twice a day after surgery and once a day for the subsequent 5 days. In order to suppress post-operation pain more effectively, the sheep were administered xylazine at a dosage of 1 mg.kg⁻¹ i.v., in continuous infusion for 48 hours post-operation. This dose was tolerated well, as described in other studies (FIELD et al., 2001). Before the operation and for an additional 6 days afterwards the sheep were administered ceftiofour, 3rd generation cephalosporin, at a dosage of 22 mg.kg⁻¹ i.m.,

Prior to administering the anaesthetic, the animal was given atropine at a dosage of 0.04 mg.kg⁻¹, and was sedated i.m. with 0.4 mg.kg⁻¹ dose of xylazine. After sedation

an i.v. cannula was placed in *v. jugularis* and fixed with two stitches to the skin. Then ketamine was administered at a dosage of 5 mg.kg⁻¹ i.v. and the animal was intubated. Inhalation anaesthesia was induced using isofluran with 2-3% oxygen.

Surgical procedure. The animal underwent surgery in a lateral position using the standard procedure for preparation of the operation field. We used a cranio-lateral approach to the hip joint and the procedure according to OLMSTEAD et al. (1981).

The instruments and prostheses used were supplied by the company PROTETIM (Szeged, Hungary) which manufactures artificial acetabulae in 5 sizes, prosthesis heads in 3 sizes and prosthesis stems in 4 sizes. We used artificial acetabulae of sizes 24-28, SandN sizes of prosthesis head and 0-2 prosthesis stems.

After the operation the sheep were kept in a box 2×2 m, checked twice a day for the first three weeks and once a day thereafter.

Radiographic evaluation. The first radiographic examination was carried out immediately after the operation and subsequently 1, 3 and 6 months later. The sheep were examined in ventro-dorsal (VD) and latero-lateral (LL) projections focusing on the periosteal reaction, cemented coat around endoprosthesis and eventual osteolysis of bones in the place of contact with cement and on any potential displacement of the prosthesis.

In the radiograph, the femoral bone with endoprosthesis was divided into zones - „regions of interest“ (ROI) (De YOUNG and SCHILLER, 1992; JOHNSTON et al., 1990). In the VD projection ROI were numbered 1-5 and in LL projection marked with letters A-E. The acetabulum was divided into 3 parts, marked with numbers I-III in both VD and LL projection (Fig. 1).

Histological examination. Samples for histological examination were collected after euthanasia which was induced by administering an overdose of thiopental i.v. and MgSO₄ six months after the operation.

The acetabulum sample was collected from the cranio-dorsal margin, the region of most frequently observed luxation after total hip replacement - in the cranio-dorsal direction (DYCE et al., 2000).

Samples of the femur were collected from its caudal part, the end of the femoral stem of the endoprosthesis. This is the site of accumulation of biomechanical forces and the greatest remodelling of bones and the most probable region of aseptic loosening if the prosthesis is in direct contact with the endosteum (EDWARDS et al., 1997).

An additional sample was taken from the medial side of the proximal femur because this is the site of changes described by some authors in association with cemented hip replacement (BOBYN et al., 1987; TURNER et al., 1986) and the highest load is placed on the proximo-medial and outer distal parts of the cement coat (SHAHAR et al., 2003).

Samples sized 1×1 cm were stored for 1 week in 10% formaldehyde solution, decalcified with EDTA and embedded in paraffin. Sections were cut with a microtome, stained with toluidine blue for evaluation of bone reaction and with haematoxylin-eosine for observation of the type and number of cells. At least 3 sections were evaluated from each sample.

Semi-quantitative evaluation. Three samples from each area were decalcified. Microscopic examination allowed us to evaluate the following:

- surface reactive changes in the periosteum
- bone reactive changes: resorption of bone tissue, new bone formation and remodelling of bones with developed Havers system
- the bone-cement interface: vascularity, uniformity, cellularity and bone reaction
- proportion of cells: macrophages, fibroblasts, giant cells and mononuclear cells.

Semi-quantitative evaluation at the bone-cement interface included vascularity, uniformity, cellularity and bone reaction and was graded as follows: absence (0), very weak (+), medium (++) and strong (+++). The proportion of cells (macrophages, fibroblasts, giant cells and mononuclear cells) was also evaluated semi-quantitatively using the following gradation scale: absence (-), sporadic occurrence (0), low occurrence (+), medium occurrence (++) and great occurrence (+++) of respective cells.

Results

Surgical procedure and clinical evaluation. We observed no complications during surgery under total anaesthesia. Nor did we encounter complications during the post-operative follow-up period and the limping disappeared in all sheep during the second month after the operation. At the end of the first week 2nd degree limping was observed in the operated animals and increased slightly after withdrawal of the non-steroid antiinflammatory drugs. None of the sheep showed clinical, radiographic or histological symptoms of osteomyelitis.

Examination after euthanasia showed no loosening of the prosthesis and none of the prosthesis or cement could be removed by free hand. This was the reason why the samples had to be collected by means of an oscillatory saw.

Radiographic evaluation. None of the radiographs showed any damage to the cement coat around the prosthesis stem or artificial acetabulum. A slight periosteal reaction was recorded in two cases on the radiographs taken one month after the operation, namely in ROI regions 5 and 4, but 3 months after surgery the radiographic examination failed to detect any periosteal response even in the two mentioned cases.

The cement coat in the region of the distal end of the endoprosthesis stem was thinner than 2 mm in the ROI 3 region in four sheep and in the ROI C region in three sheep. No radiolucent zone was observed in these sheep even 6 months after the operation (Fig. 2).

Histological evaluation. All samples exhibited superficial bone reactive changes of minimal extent. New bone formation predominated in samples collected from the dorsal acetabular margin and in two cases (25%) the remodelled bone tissue acquired a structure of completely mature bone with evident bone structures including the Hawers system. The bone-cement interface tissue appeared uniform with small differences in five cases (62.5%) and three samples showing absence of cellularity (37.5%). Vascularity was observed in three samples (37.5%) and cellularity and bone reaction in two samples (25%). The numbers of fibroblasts associated with bone reaction were small. All samples contained sporadic macrophages, giant cells and mononuclear cells (Table 1).

Remodelling of bone tissue predominated in samples collected from the medial side of the proximal femur with the exception of one case in which resorption of bone tissue and new bone formation at the level of an osteoid was observed (12.5%). Weak vascularity of bone-cement interface tissue was detected in four cases (50%). Uniformity with small differences was observed in four sheep (50%), cellularity in three (37.5%) and bone reaction in two sheep (25%). No cellular reaction was observed in two sheep (25%). Macrophages, giant cells and mononuclear cells occurred only sporadically and a small number of fibroblasts were observed in five operated sheep (62.5%) (Table 2).

On the lateral side of the distal region at the end of the bone cement we detected two reactions of bone tissue and new bone formation at the level of the osteoid (25%). The remaining samples indicated new bone formation with remodelling of bone tissue in four sheep (50%). Weak vascularity of bone-cement interface tissue was observed in four cases (37.5%), cellularity in one (12.5%) and bone reaction in four (50%). Uniformity with small differences was detected in four sheep (50%). Macrophages, giant cells and mononuclear cells occurred sporadically as in the other samples. Fibroblasts were found in small numbers in five sheep (62.5%) (Table 3).

New bone formation was observed in all samples, although three of them (12.5%) also showed changes at the level of resorption. Remodelling of bones, in terms of practically mature bone with evident bone structures including the Hawers system, was observed in 11 samples (45.83%) (Fig. 3). Very weak vascularity was revealed in 10 samples (41.67%), cellularity in 6 (25%) and bone reaction in 8 samples (33.33%). Uniformity of samples was observed in 13 cases (54.17%).

Absence of cellularity was observed in 9 samples (37.5%). Of all cell types, the fibroblasts were most frequent, but their numbers were not high. In 14 samples (58.33%) the expected level of fibroblasts was exceeded only slightly.

Table 1. Semi-quantitative evaluation of the dorsal acetabular margin

Sample No.	Superficial reactive changes	Bone reactive changes	Bone-cement interface tissue	Cell types
351/05	present	new bone formation	vascularity uniformity cellularity bone reaction	absent
354/05	present	new bone formation	vascularity + uniformity cellularity + bone reaction	macrophages fibroblasts giant cells mononuclear cells
358/05	present	new bone formation bone remodelling (HS)	vascularity uniformity + cellularity bone reaction +	macrophages fibroblasts + giant cells mononuclear cells
360/05	present	new bone formation	vascularity + uniformity + cellularity bone reaction +	macrophages fibroblasts + giant cells mononuclear cells
365/05	present	new bone formation	vascularity uniformity + cellularity bone reaction	absent
366/05	present	new bone formation bone remodelling (HS)	vascularity uniformity + cellularity bone reaction	absent
369/05	present	new bone formation	vascularity + uniformity cellularity + bone reaction	macrophages fibroblasts + giant cells mononuclear cells
372/05	present	new bone formation	vascularity uniformity + cellularity bone reaction	absent

Table 2. Semi-quantitative evaluation on medial side of proximal femur

Sample No.	Superficial reactive changes	Bone reactive changes	Bone-cement interface tissue	Cell types
353/05	present	new bone formation	vascularity uniformity cellularity bone reaction	absent
356/05	present	new bone formation bone remodelling (HS)	vascularity + uniformity + cellularity bone reaction	macrophages fibroblasts + giant cells mononuclear cells
359/05	present	new bone formation bone remodelling (HS)	vascularity + uniformity + cellularity + bone reaction	macrophages fibroblasts + giant cells mononuclear cells
361/05	present	new bone formation bone remodelling (HS)	vascularity + uniformity cellularity + bone reaction	macrophages fibroblasts + giant cells mononuclear cells
363/05	present	new bone formation bone remodelling (HS)	vascularity uniformity + cellularity bone reaction	absent
368/05	present	new bone formation bone remodelling (HS)	vascularity uniformity + cellularity bone reaction +	macrophages fibroblasts + giant cells mononuclear cells
371/05	present	new bone formation bone remodelling (HS)	vascularity + uniformity + cellularity + bone reaction	macrophages fibroblasts + giant cells mononuclear cells
373/05	present	new bone formation	vascularity uniformity cellularity bone reaction +	macrophages fibroblasts + giant cells mononuclear cells

Table 3. Semi-quantitative evaluation of lateral side of femur at the end of bone cement

Sample No.	Superficial reactive changes	Bone reactive changes	Bone-cement interface tissue	Cell types
352/05	present	new bone formation bone remodelling (HS)	vascularity uniformity + cellularity bone reaction +	macrophages fibroblasts + giant cells mononuclear cells
355/05	present	new bone formation bone remodelling (HS)	vascularity uniformity + cellularity bone reaction	absent
357/05	present	new bone formation bone remodelling (HS)	vascularity uniformity + cellularity bone reaction +	macrophages fibroblasts + giant cells mononuclear cells
362/05	present	new bone formation bone remodelling (HS)	vascularity + uniformity cellularity bone reaction +	macrophages fibroblasts + giant cells mononuclear cells
364/05	present	new bone formation	vascularity + uniformity cellularity bone reaction	macrophages fibroblasts + giant cells mononuclear cells
367/05	present	new bone formation bone remodelling (HS)	vascularity uniformity cellularity bone reaction	absent
370/05	present	new bone formation	vascularity + uniformity cellularity + bone reaction +	macrophages fibroblasts + giant cells mononuclear cells
374/05	present	new bone formation bone remodelling (HS)	vascularity uniformity + cellularity bone reaction	absent

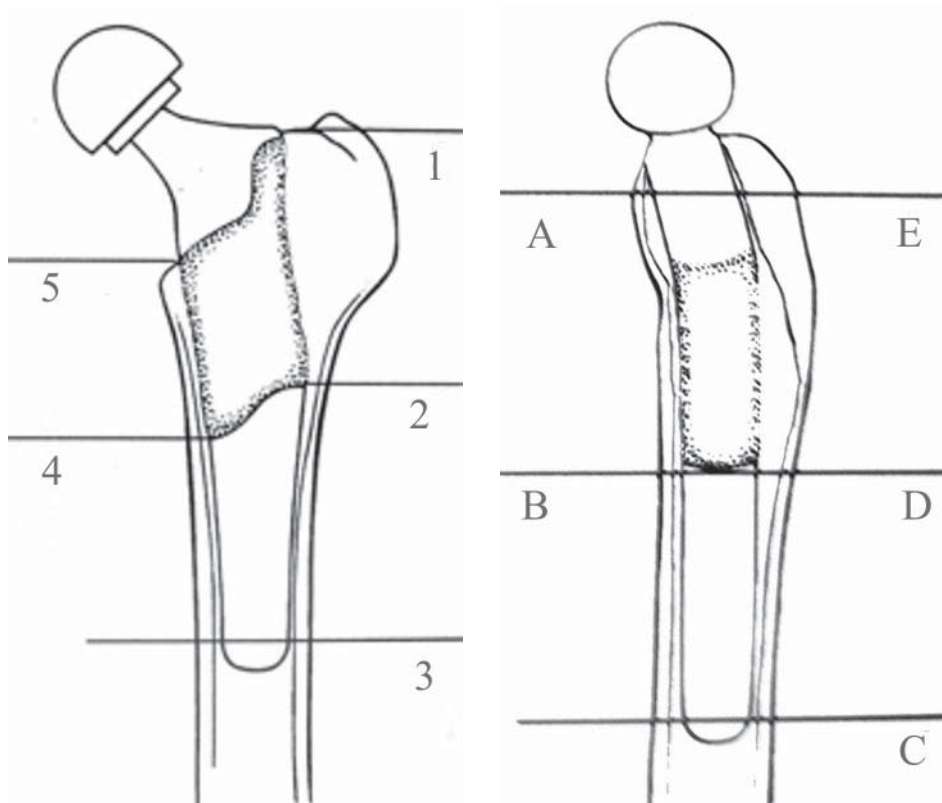


Fig. 1. Regions of interest (ROI), A. VD projection B. LL projection

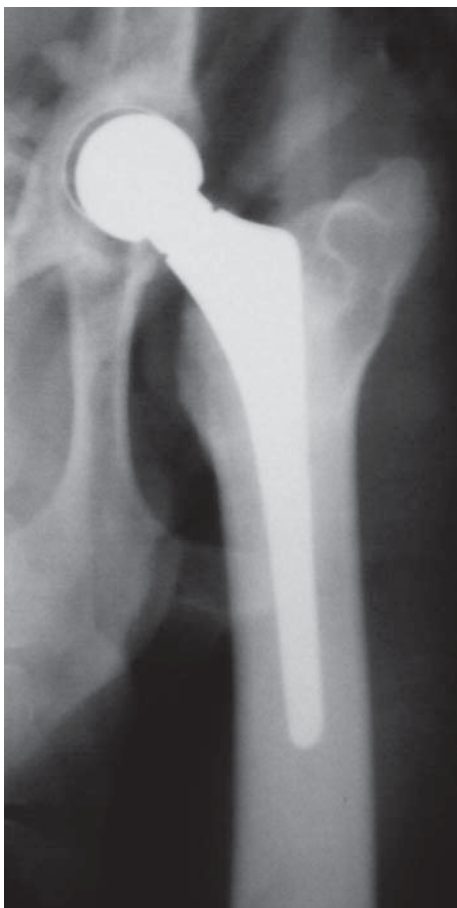

Fig. 2. Radiography of endoprosthesis: VD projection, 6 months after operation

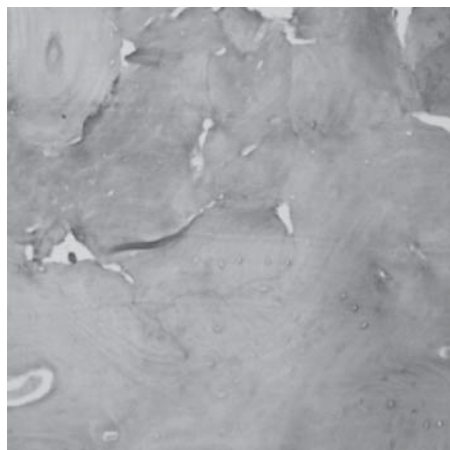


Fig. 3. Histological section of bone tissue - Havers system and osteoids

Discussion

The present experimental study focused on histological examination of bone tissue in cases in which aseptic loosening was not detected by radiographic examination at 6 months after implantation of endoprostheses. It has been recognised that higher numbers of macrophages and giant cells (LEE et al., 1992), bone reaction and increased bone-

cement interface tissue formation (EL-WARRAK et al., 2004) precede and are responsible for aseptic loosening of the prosthesis. As the surgical trauma can also result in increased bone reaction and increased bone-cement interface tissue formation with more intensive cellular response in the first months after the operation (EL-WARRAK et al., 2001), we did not carry out early histological examination.

An incomplete cement coat results in cement micro-fractures and release of small cement particles. These minute particles activate macrophages and giant cells and are subsequently phagocytosed by them. Activation of macrophages induces release of cytokines which cause osteolysis and thus also aseptic loosening of the endoprosthesis. The cytokines involved in this process include interleukin 1 (IL-1), interleukin 6 (IL-6), tumour necrotizing factor α (TNF- α) and a macrophage colony stimulating factor (M-CSF). By means of a complex process, the fluid activator N,N-dimethylparatoluidin (DMT) induces a hypersensitive response and the bone cement has a general toxic action on macrophages, resulting in their break-down and release of cytokines (EL-WARRAK et al., 2001).

Our observations detected only sporadic macrophages, giant cells and monocytes which indicates only a slight probability of aseptic loosening of both artificial acetabulum and femoral stem.

The fact that surgical trauma and PMMA increase production of fibrous tissue is indicated by the small number of fibroblasts, and new bone formation at the level of osteoids points to changes of fibrous tissue into bone tissue.

Bone reaction, resorption and new bone formation indicate that biomechanical forces are transmitted predominantly to the end of the femoral stem and the end part of the bone cement and for this reason remodelling of bones in this region is most intensive. Moreover, the most frequent deviation from the central position of the endoprosthesis is the shift of the distal part of the endoprosthesis stem slightly caudally and as a result the cement in this region is frequently thinner than 2 mm and fails to act to the full extent as a buffering and transmitting agent of biomechanical forces. Besides changes occurring in endosteum, histological examination also revealed mild changes in the periosteum although they could not be diagnosed by radiography.

The results obtained in this study indicate that although the bone-cement interface tissue could not be detected by radiography, histology proved its presence in the examined samples. The results obtained also revealed that an intact cement coat on radiograms is associated with only minimal histological changes.

A well fixed endoprosthesis induces generally smaller bone reaction (KLAPACH et al., 2001) but the differences in bone remodelling are also important due to individual biological responses (MALONEY et al., 1996).

The results obtained proved that even at 6 months after total hip replacement changes at a cellular level are still in progress, with the predominance of fibroblasts and new bone formation at the level of osteoids.

Future investigations could focus on the histological changes associated with cement coat defects and their comparison with the results obtained in this experiment.

References

- BOBYN, J. D., R. M. PILLIAR, A. G. BINNINGTON, J. A. SZIVEK (1987): The effect of proximally and fully porous-coated canine hip stem design on bone remodelling. *J. Orthop. Res.* 5, 393-408.
- BRIEN, W. W., E. A. SALVATI, F. BETTIS, P. BULLOUGH, T. WRIGHT, C. RIMMAC (1992): Metal levels in cemented total hip arthroplasty: A comparison of well-fixed and loose implants. *Clin. Orthop.* 276, 66-74.
- CATELAS, I., A. PETIT, D. J. ZUKOR, R. MARCHARD, L' H. YAHIA, O. L. HUK (1999): Induction of macrophage apoptosis by ceramic and polyethylene particles *in vitro*. *Biomaterials* 20, 625-630.
- CHARNLEY, J. (1970): The reaction of bone to self-curing acrylic cement. *J. Bone Joint Surg.* 52B, 340-353.
- De YOUNG, D. J., R. A. SCHILLER (1992): Radiographic criteria for evaluation of uncemented total hip replacement in dogs. *Vet. Surg.* 21, 88-98.
- DYCE, J., E. R. WISNER, Q. WANG, M. L. OLMSTEAD (2000): Evaluation of risk for luxation after total hip replacement in dogs. *Vet. Surg.* 29, 524-532.
- EDWARDS, M. R., E. L. EGGER, P. D. SCHWARTZ (1997): Aseptic loosening of the femoral implant after cemented total hip arthroplasty in dogs: 11 cases in 10 dogs (1991-1995). *J. Am. Vet. Med. Assoc.* 211, 580-586.
- EL-WARRAK, A. O., M. L. OLMSTEAD, B. von RECHENBERG, J. A. AUER, (2001). A review of aseptic loosening in total hip arthroplasty. *Vet. Comp. Orthop. Traumatol.* 14, 115-124.
- EL-WARRAK, A. O., M. OLMSTEAD, D. APELT, F. DEISS, H. NOETZLI, K. ZLINSKY (2004): An animal model for interface tissue formation in cemented hip replacements. *Vet. Surg.* 33, 495-504.
- FIELD, J. R., H. ABERMAN, A. CARBONE, P. SHARPE, N. SMITH, D. DUNLOP, D. W. HOWIE (2001): An ovine model for total hip replacement: operative procedure and complications. *Vet. Comp. Orthop. Traumatol.* 14, 32-39.
- GOLDRING, S. R., A. L. SCHILLER, M. ROELKE, C. M. ROURKE, D. A. O'NEIL, W. H. HARRIS (1983): The synovial-like membrane at the bone-cement interface in loose total hip replacement and its proposed role in bone lysis. *J. Bone Joint Surg. (Am)* 65, 575-584.
- HOWIE, D. W, D. R. HAYNES, S. D. ROGERS, M. A. McGEE, M. J. PEARCY (1993): The particulate response to debris. *Orthop. Clin. NA.* 24, 571-581.

- HUO, M. H., E. A. SALVATI, J. R. LIEBERMAN, F. BETTS, M. BANSAL (1992): Metallic debris in femoral endosteolysis in failed cemented total hip arthroplasties. *Clin. Orthop.* 276, 157-168.
- JOHANSON, N. A., P. G. BULLOUGH, P. D. WILSON Jr., E. A. SALVATI, C. S. RANAWAT (1987): The microscopic anatomy of the bone-cement interface in failed total hip arthroplasties. *Clin. Orthop.* 218, 123-135.
- JOHNSTON, R. C., R. H. FITZGERALD, W. H. HARRIS, R. POSS, M. E. MULLER, C. B. SLEDGE (1990): Clinical and radiographic evaluation of total hip replacement. *J. Bone Joint Surg.* 72A, 161-168.
- KLAPACH, A. S., J. J. CALLAGHAN, D. D. GOETZ, J. P. OLEJNICZAK, R. C. JOHNSTON (2001): Charnley total hip arthroplasty with use of improved cementing techniques: A minimum twenty-year follow-up study. *J. Bone Joint Surg. (Am)* 83-A, 1840-1848.
- LEE, J. M., E. A. SALVATI, F. BETTS, E. F. DiCARLO, S. B. DOTY, P. G. BULLOUGH (1992): Size of metallic and polyethylene debris particles in failed cemented total hip replacements. *J. Bone Joint Surg.* 74B, 380-384.
- MALONEY, W. J., R. L. SMITH (1997): Periprosthetic osteolysis in total hip arthroplasty: the role of particulate wear debris. *J. Bone Joint Surg. (Am)* 77, 1448-1461.
- MALONEY, W. J., C. SYCHTERZ, C. BRAGDON, T. McGOVERN, M. JASTY, C. A. ENGH, W. H. HARRIS (1996): The Otto Aufranc Award. Skeletal response to well fixed femoral components inserted with and without cement. *Clin. Orthop.* 333, 15-26.
- OLMSTEAD, M. L., R. B. HOHN, T. M. TURNER (1981): Technique for canine total hip replacement. *Vet. Surg.* 10, 44-50.
- SHAHAR, R., L. BANKS-SILLS, R. ELIASY (2003): Mechanics of canine femur with two types of hip replacement stems. *Vet. Comp. Orthop. Traumatol.* 16, 145-152.
- TURNER, T. M., D. R. SUMMER, R. M. URBAN, D. P. RIVERO, J. O. GALANTE (1986): A comparative study of porous coatings in a weigh-bearing total hip arthroplasty model. *J. Bone Joint Surg. (Am)*. 68, 1396-1409.
- XU, J. W., Z. T. KONTTINEN, J. LASSUS, S. NATAH, A. CEPONIS, S. SOLOVIEVA (1996): Tumor necrosis factor-alpha (TNF-alpha) in loosening of total hip replacement (THR). *Clin. Exp. Rheumatol.* 14, 643-648.

Received: 1 July 2009
Accepted: 22 December 2009

FRANKA, D., V. LEDECKÝ, J. BODNÁR, M. HLUCHÝ, S. HORŇÁK, M. USHMIRSKÝ, K. LEDECKÁ, L. SKURKOVÁ: Reakcija koštanoga tkiva u ovaca nakon ugradnje umjetnoga bočnoga zgloba upotrebom fiksacijskog cementa. Vet. arhiv 80, 329-342, 2010.

SAŽETAK

Ovce su bile upotrijebljene kao model za istraživanje rendgenskih i histoloških promjena u koštanom tkivu nakon ugradnje umjetnoga bočnoga zgloba. Rendgenski su bile pregledane mjesec dana, te tri i šest mjeseci nakon što im je jednostrano bio ugrađen umjetni bočni zglob. Šest mjeseci nakon operacije ovce su bile eutanazirane, a koštano je tkivo bilo uzeto za histološku pretragu. Histološka pretraga bila je usmjerena na površinske promjene, promjene koštanoga tkiva te tip i broj prisutnih stanica. Rendgenskom pretragom nisu ustanovljene patološke promjene. Histološkom pretragom dokazano je obnavljanje koštanoga tkiva s pregradnjom kostiju. U tri uzorka (12,5%) bile su prisutne promjene u resorpciji i obnovi koštanoga tkiva na razini osteoida. Stanična reakcija u smislu prisutnosti makrofaga i fibroblasta bila je neznatna u svim uzorcima. Promjene karakteristične za pregradnju oblikovane kosti s izraženim koštanim strukturama, uključujući Haversov sustav koštanih lamela, bile su prisutne u 11 (45,83%) uzoraka. Poremećaj cjelovitosti cementnoga omotača dovodi do aktivacije stanica i aseptične nestabilnosti. Stanična aktivacija bila je minimalna te se u nekim uzorcima moglo uočiti znakove potpuno razvijene kosti što svjedoči o čvrstoj fiksaciji endoproteze u koštanom tkivu te da su promjene na staničnoj razini prisutne i šest mjeseci nakon operacije.

Ključne riječi: aseptična razlabavljenost, histologija, ugradnja umjetnoga bočnoga zgloba, ovca
