

Oviductal lymphangiectasia secondary to mesosalpinx leiomyoma in a chicken (*Gallus gallus domesticus*) - a case report

Olusola L. Ajayi^{1*}, and Richard E. Antia²

¹Department of Veterinary Pathology, University of Agriculture, Abeokuta, Ogun-State, Nigeria

²Departments of Veterinary Pathology, University of Ibadan, Ibadan, Nigeria

AJAYI, O. L., R. E. ANTIA: Oviductal lymphangiectasia secondary to mesosalpinx leiomyoma in a chicken (*Gallus gallus domesticus*) - a case report. Vet. arhiv 80, 155-161, 2010.

ABSTRACT

A rare case of oviductal lymphangiectasia was described in a 73-week old Nera-black layer, brought from a farm in the western part of Nigeria with a capacity of 41,000 birds. The layer was found dead inside the cage, without premonitory signs. Necropsy examination revealed marked oedema of the oviduct, with prominent mucosal folds. The dorsal ligament showed prominent and markedly dilated lymphatic vessels, having a discrete, soft but firm, pouch-like appearance and a centrally located oval-shaped, solid encapsulated tumorous mass. Histologically, there was severe oedema of the lamina propria, submucosa and muscularis of the oviduct, with ballooning dilatation of their lymphatic vessels and those of the dorsal ligament, which contained deeply eosinophilic proteinaceous fluid and moderate mononuclear cells, mostly lymphocytes and macrophages. The tumorous mass revealed interlacing bundles of elongated cells that showed eosinophilic cytoplasm and oval to cigar-shaped nuclei. The tumorous mass was positive with Van Gieson stain. This is the first reported case of oviductal lymphangiectasia secondary to mesosalpinx leiomyoma in a domestic chicken.

Key words: lymphangiectasia, oviduct, leiomyoma, chicken, Nigeria

Introduction

Reports associated with circulatory disturbances of the oviduct in domestic chickens are seldom reported in the literature (AJAYI et al., 2008). In the gastrointestinal tracts of domestic animals conditions such as intussusception, volvulus, lymphangiectasia and torsion have been documented as causative agents of circulatory disturbances (BURROWS et al., 1995; GELBERG, 2001). These conditions rarely cause circulatory derangement in the oviducts of domestic animals and in poultry. Various disease conditions of the oviduct

*Corresponding author:

Ajayi Olusola Lawrence, DVM, M.V.Sc, Department Veterinary Pathology, University of Agriculture Abeokuta, Nigeria, P. M. B. 2240, Phone: +234 8068 783895; E-mail: alabsola@yahoo.com

have been reported in the literature, such as cystic right and left oviduct (GOLDHAFT, 1956), oviductal prolapse (RANDALL, 1991), impacted oviduct with paralysis of the oviductal musculature (RIDDELL, 1997) and oviductal volvulus (AJAYI et al., 2008). However, circulatory derangement of the reproductive tract in domestic chickens caused by dilatation of the lymphatic vessels (lymphangiectasia) of the oviduct and dorsal ligament, to the best of our knowledge, has not been described in any wild or domestic birds. Lymphangiectasia is the dilatation of the lymph vessels (VAN VLEET and FERRANS, 2001). It may be congenital or acquired. Congenital lymphangiectasia may be due to insufficiency or aplasia of the lymphatic vessels, while acquired or secondary lymphangiectasia develops secondary to conditions such as right-sided heart failure, constrictive heart disease, intestinal neoplasia and inflammatory disease (RIEMANN and SCHMIDT, 1981; BURNS, 1982; HOLLAND, 1997; GELBERG, 2001). Moreover, intestinal lymphangiectasia is characterized by severe oedema, thickening of the bowel wall, protein-losing enteropathy, ascites and pleura effusion (GELBERG, 2001). In avian species, there is paucity of information on oviductal circulatory derangement due to lymphangiectasia. In this report, we describe the gross and histopathomorphologic changes of oviductal lymphangiectasia secondary to leiomyoma of the mesosalpinx (dorsal ligament) in a Nera-black chicken.

Materials and methods

The subject was one of the carcasses submitted to the Department of Veterinary Pathology, University of Agriculture, Abeokuta, for postmortem examination between January and December 2007. The carcass was a Nera-black layer, 73 weeks old, brought from a farm in the western part of Nigeria with a capacity of 41,000 birds. The layer was found dead inside the cage, without premonitory signs. Necropsy was performed and tissues from different parts of the oviduct, dorsal ligament and tumorous mass were routinely fixed in 10% neutral buffered formalin. These tissues were then dehydrated, embedded in paraffin wax, sectioned at 5µm and stained with heamatoxylin and eosin and the tumorous section was also stained with Van Gieson stain.

Results

At necropsy, the carcass was in good physical condition and weighed 1.35 kg. The whole length of the oviduct was moderately shrunken and the serosal surface appeared rough and wrinkled. The dorsal ligament showed prominent lymphatic vessels, which were markedly dilated, having a discrete, soft but firm, pouch-like appearance (0.5cm-1.5cm in diameter) along its path. The whole dorsal ligament was involved, extending from the cranial portion to the caudal part. The dilated lymphatic vessels and pouch-like nodules contained pale-yellowish watery fluid and some of them were observed at the ligament border of the oviduct and appeared to extend into the tunica muscularis (Fig. 1).

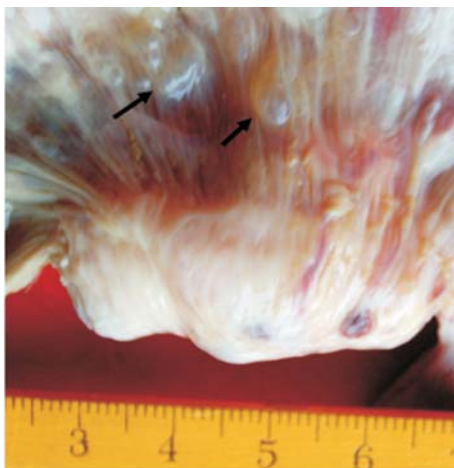


Fig. 1. Dorsal ligament showing dilated lymphatic vessels having pouch-like nodules (arrows) and tumorous mass with foci of haematoma

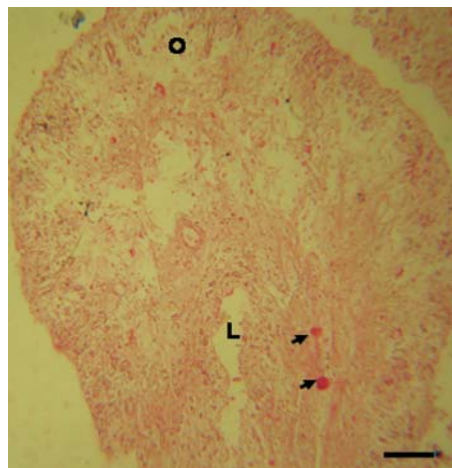


Fig. 2. Oviduct; tip of the mucosal fold of magnum showing moderate oedema of the lamina propria (L), deeply eosinophilic proteinaceous materials (arrows) and disruption of the normal arrangement of the acini by oedema fluid (O). Scale bar = 100 μ m.

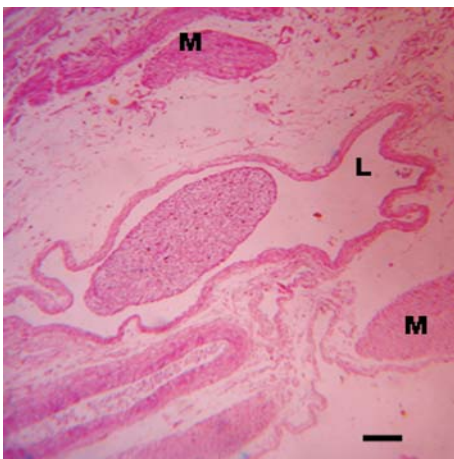


Fig. 3. Oviduct showing separation of the two layers of tunica muscularis (M) by oedema fluid with marked dilatation of lymphatic vessel (L) and aggregate of lymphocytic cells in the lumen. H&E. Scale bar = 300 μ m.

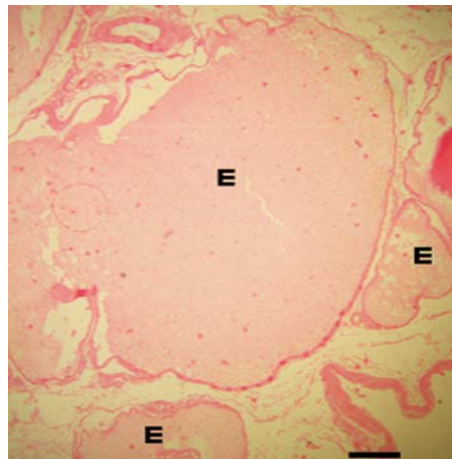


Fig. 4. Cross section of the dorsal ligament showing ballooning dilatation of lymphatic vessels (lymphangiectasia) with eosinophilic proteinaceous fluid (E). H&E. Scale bar = 200 μ m.

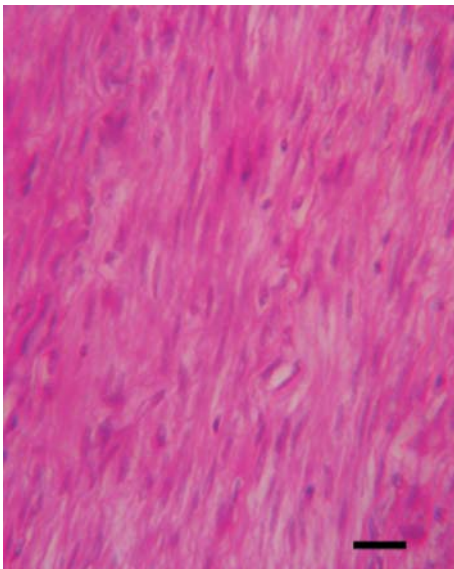


Fig. 5. Tumorous mass showing interlacing bundles of smooth muscle fibres with eosinophilic cytoplasm and oval to cigar-shaped nuclei. H&E. Scale bar = 85 µm.

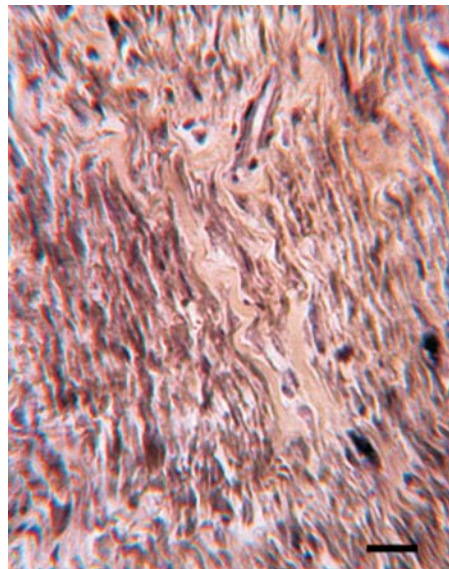


Fig. 6. Smooth muscle fibres positive with Van Gieson stain. Scale bar = 75 µm.

On incision, the wall was thickened and the mucosal surface was oedematous. The mucosa folds were swollen and prominent. The lumen of the oviduct contained yolks without albumen in the shell gland and grayish-white watery exudate. A solid, oval-shaped encapsulated tumorous mass (4 cm × 2 cm) weighing 63.0 g was centrally located in the dorsal ligament, having a grayish-white glistening appearance upon incision, with multiple foci of minute haematoma. The abdominal cavity contained approximately 58ml of slightly yellowish watery exudate. A presumptive diagnosis of lymphangiectasia due to the tumorous mass compressing or obstructing the lymphatic drainage was made.

Microscopically, the magnum, isthmus and the shell gland were most affected. The lamina propria mucosae were moderately dilated with oedema fluid and round, deeply eosinophilic proteinaceous materials. The acini of the magnum mucosa were empty and their normal arrangements were severely disrupted by oedema fluid (Fig. 2). The submucosa and muscularis were severely oedematous, with their lymphatic vessels markedly dilated. There was separation of the two layers of tunica muscularis by oedema fluid (Fig. 3). Multiple foci of lymphocytic aggregates were observed in the lamina propria and within the lymphatic vessels of the submucosa and muscularis. The wall of the dorsal ligament

was markedly oedematous. The lymphatic vessels and the macroscopically pouch-like nodules showed ballooning dilatation and contained deeply eosinophilic proteinaceous fluid, some with aggregates of mononuclear cells, mostly lymphocytes and macrophages (Fig. 4).

The tumorous mass revealed encapsulated and non-invasive neoplastic cells. The tumor was composed of interlacing bundles of elongated cells that showed eosinophilic cytoplasm and oval to cigar-shaped nuclei (Fig. 5). Mitotic figures and multinucleated giant cells were not observed, which was consequently suggestive of a benign tumor of the smooth muscles (leiomyoma). The tumorous mass was also positive with Van Gieson stain, showing blue-black smooth muscle fibers interspersed with light yellowish collagen fibers (Fig. 6).

Discussion

The gross and histomorphologic findings with respect to the thickening of the wall of the oviduct and mucosa folds, pouch-like nodules of lymphatic vessels in the dorsal ligament, moderate oedema fluid in the lamina propria, submucosa and muscularis, marked dilatation and the presence of deeply eosinophilic proteinaceous materials in the lamina propria and lymphatic vessels resemble the reports of POTOČNJAK et al. (2001) and GELBERG (2001) on intestinal lymphangiectasia in domestic animals. However, peritonitis and lipogranulomatous lymphagitis observed in these reports were not present in this study.

Oviductal lymphangiectasia is an uncommon finding, both in mammals and avian species. In poultry, oviductal lymphangiectasia seems to be very rare. The authors of this report found no reference to this condition either in domestic animals or in poultry. Although SIJUN et al. (2002) reported dilatation of the thoracic duct in ascitic broilers, reports on lymphangiectasia of the oviduct and the dorsal ligament are rare in the literature.

Intestinal neoplasia has been reported as one of the causative agents of lymphangiectasia (GELBERG, 2001). The aetiopathogenesis of oviductal lymphangiectasia in this report might have been due to the tumorous mass (leiomyoma), which probably obstructed or compressed the lymphatic drainage and prevented lymph from returning into the main circulation at the rate equal to the rate of capillary filtration (WILSON et al., 1988).

In mammals, intestinal lymphangiectasia is the most reported cause of protein-losing enteropathy (GELBERG, 2001; POTOČNJAK et al., 2001). In this report, though the level of the serum protein was not determined, the altered functional capability of the oviduct was evident from the absence of albumen surrounding the yolks, the presence of watery exudate in the lumen and severe oedema of the oviduct. The histomorphologic changes of ballooning dilatation of the lymphatic vessels in the dorsal ligament, submucosa and

muscularis of the oviduct was in correlation with the report of HALL and SIMPSON (2000) and WILLARD (2003) in making a definitive diagnosis of true lymphangiectasia. This condition should be differentiated from cystic formation along the oviduct and dorsal ligament as reported by GOLDHAFT (1956).

In conclusion, oviductal lymphangiectasia appears to be very rare in wild and domestic birds. This report, to the best of our knowledge, appears to be the first documented case of oviductal lymphangiectasia in an avian species.

References

- AJAYI, O. L., R. E. ANTIA, S. O. OMOTAINSE (2008): Oviductal volvulus in a Nera black chicken (*Gallus gallus domesticus*) in Nigeria. *Avian Pathol.* 37, 139-140.
- BURNS, M. G. (1982): Intestinal lymphangiectasia in the dog: a case report and review. *J. Am. Ani. Hosp. Ass.* 18, 97-105.
- BURROWS, C. F., R. M. BATT, R. G. SHERDING (1995): Diseases of the small intestine. In: *Textbook of Veterinary Internal Medicine.* (Ettinger, S. J., E. C. Feldman, Eds.). W. B. Saunders Company, Philadelphia, pp. 1169-1232.
- GELBERG H. B. (2001): Alimentary system. In: *Thomson's Special Veterinary Pathology.* (McGavin M. D., W. W. Carlton, J. F. Zachary, Eds.), Mosby Inc, St. Louis Missouri, USA. pp. 1-79
- GOLDHAFT, T. M. (1956): Cystic oviducts in domestic fowls. *Cornell Vet.* 46, 223-227.
- HALL, E. J., K. W. SIMPSON (2000): Disease of the small intestine. In: *Textbook of Veterinary Internal Medicine.* (Ettinger, S. J., E. C. Feldman, Eds.), W. B. Saunders Company, Philadelphia, pp. 1182-1238.
- HOLLAND, M. (1997): Lymphangiectasia. In: *The 5 Minute Veterinary Consult Canine and Feline.* (Tilley L. P., F. W. K. Smith, Eds.). Williams & Wilkins A Waverly Company. Baltimore, pp. 788-789.
- POTOČNJAK, D., K. RAMADAN, N. KUČER, V. MATIJATKO, S. ČURIĆ, R. SABOČANEC, K. ČULJAK. (2001) Secondary intestinal lymphangiectasia in a dog - a case report. *Vet. Arhiv* 71, 159-171.
- RANDALL, C. J. (1991). *A Colour Atlas of Diseases and Disorders of the Domestic Fowl and Turkey*, 2nd ed., Wolfe, London, England.
- RIDDELL, C. (1997): Developmental, metabolic, and other noninfectious disorders. In: *Diseases of Poultry.* (Calnek B. W., H. J. Barnes, C. W. Beard, L. R. McDougald, Y. M. Saif, Eds.), Iowa State Press, USA pp. 931-950.
- RIEMANN, J. F., H. SCHMIDT (1981): Synopsis of endoscopic and other morphological findings in intestinal lymphangiectasia. *Endoscopy* 13, 60-63.
- SIJUN, Y., G. DINGZONG, Y. BAOAN (2002): Histopathology of the lymphatic system in ascitic broilers. *Vet. Med. - Czech*, 47, 264-269.

- VAN VLEET, J. F., V. J. FERRANS (2001): Cardiovascular System. In: Thomson's Special Veterinary Pathology. (McGavin, M. D., W. W. Carlton, J. F. Zachary, Eds.). Mosby Inc., St. Louis Missouri USA. pp. 197-233.
- WILLARD, M. D (2003): Disorders of the Intestinal tract. In: Textbook of Small Animal Internal Medicine. (Nelson R. W., C. G. Couto, Eds.) Mosby, Inc. St. Louis, Missouri USA. pp. 431-465.
- WILSON, J. B., R. J. JULIAN, I. K. BARKER (1988): Lesions of right heart failure and ascites in broiler chickens. Avian Dis. 32, 246-261.

Received: 18 August 2008
Accepted: 22 December 2009

AJAYI, O. L., R. E. ANTIA: Limfangiektazija jajovoda kao posljedica leiomioma mezosalpinksa u kokoši (*Gallus gallus domesticus*). Vet. arhiv 80, 155-161, 2010.

SAŽETAK

Rijedak slučaj limfangiektazije jajovoda opisan je u 73 tjedna stare nesilice podrijetlom s farme od 41000 ptica u zapadnom dijelu Nigerije. Nesilica je nađena uginula bez prethodnih znakova bolesti. Pri razudbi je ustanovljen edem jajovoda s izraženim sluzničnim naborima. Na dorzalnom ligamentu isticale su se znatno proširene limfne žile s mekanom, ali čvrstom vrećastom tvorevinom u čijem se središtu nalazila jajasta, solidna, učahurena tumorska masa. Histološki je ustanovljen jak edem lamine proprije te submukoze i mišićnice jajovoda s balonskim proširenjem njegovih limfnih žila i onih na dorzalnom ligamentu koje su sadržavale bjelančevinsku tekućinu i eozinofile te nešto mononuklearnih stanica, pretežito limfocita i makrofaga. Tumorska masa sastojala se od isprepletenih snopića izduženih stanica koje su imale eozinofilnu citoplazmu s jezgrama jajastoga do cigarastoga oblika. Tumorska masa bila je pozitivna bojenjem po Van Giesonu. To je prvi opisani slučaj limfangiektazije jajovoda kao posljedice leiomioma mezosalpinksa u domaće kokoši.

Ključne riječi: limfangiektazija, jajovod, leiomiom, kokoš, Nigerija
