

***Dirofilaria repens* infection in a dog in Croatia - a case report**

**Petar Džaja*¹, Ana Beck², Gordana Kiš³, Andrea Gudan Kurilj²,
Tanja Živičnjak⁴, Branka Artuković², Relja Beck⁴, Marko Hohšteter²,
Ivan Conrado Zuckermann Šoštarić², and Željko Grabarević²**

¹Department of Forensic Veterinary Medicine, Faculty of Veterinary Medicine, University of Zagreb, Croatia

²Department of General Pathology and Pathological Morphology, Faculty of Veterinary Medicine, University of Zagreb, Croatia

³Veterinary Management, Armed Forces of Croatia, Zagreb, Croatia

⁴Department of Parasitology and Parasitic Diseases with Clinics, Faculty of Veterinary Medicine, University of Zagreb, Croatia

DŽAJA, P., A. BECK, G. KIŠ, A. GUDAN KURILJ, T. ŽIVIČNJAK, B. ARTUKOVIĆ, R. BECK, M. HOHŠTETER, I. C. ZUCKERMANN ŠOŠTARIĆ, Ž. GRABAREVIĆ: *Dirofilaria repens* infection in a dog in Croatia. Vet. arhiv 78, 521-527, 2008.

ABSTRACT

This work presents the finding of *Dirofilaria repens* microfilariae after necropsy on a dog in Croatia. The cause of death was peritonitis caused by perforation of the intestinal diverticula. Necropsy revealed severe cachexia with a phlegmonous subcutaneous inflammation in the cubital, coxal and carpal regions. The liver cirrhosis with icterus was also seen. Histopathological examination showed numerous microfilariae in all examined organs located predominantly intravascularly, but in the phlegmone, liver, lymph node and lungs they were located in the tissue of the haemorrhage area. Two otherwise healthy dogs which had lived in cohabitation with the necropsied one had been found positive by modified Knott's test for *D. repens* microfilariae and were successfully treated with ivermectin.

Key words: *Dirofilaria repens*, dog, pathomorphology

Introduction

Dirofilariosis due to *Dirofilaria repens* as a helminthic zoonosis (*Dirofilaria repens*, Raillet and Henry, 1911) is a parasite of the subcutaneous connective tissues mainly of dogs. The parasite has a complex life cycle, with mosquitoes serving as intermediate

*Contact address:

Prof. Dr. Petar Džaja, Faculty of Veterinary Medicine, University of Zagreb, Department of Forensic Veterinary Medicine, Heinzelova 55, 10000 Zagreb, Croatia, Phone +385 1 2390 126; E-mail: dzaja@vef.hr

hosts. Adults reside in the subcutaneous connective tissues; females produce larvae (microfilariae) in the natural host organism and release them into the circulation. There are reports from domestic cats (NUCHPRAYOON et al., 2006; MAZURKEVICH et al., 2004; SCHWAN et al., 2000) and foxes (GRADONI et al., 1980) and a large number of cases reported in humans (PAMPIGLIONE and RIVASI, 2000). This species is world widespread (East Europe, Africa, Asia). *Dirofilaria* infections in humans in Croatia are described by TERLEVIĆ et al. (2007).

Little is known about the pathogenesis of *D. repens* infection which is sometimes characterized by painless subcutaneous nodules in which the adult parasites reside (BREDAL et al., 1998). Infection with *D. repens* is generally asymptomatic; therefore discovery of the disease is usually accidental. Some authors have classified apparent clinical manifestation of *D. repens* infections in two syndromes. The first syndrome is characterized by nodular multifocal dermatitis (SCOTT and VAUGHN, 1987) and the second by the presence of several pruriginous papule (HALIWELL and GORMAN, 1989). Apparent dermatological signs could be associated with the presence of adults and/or microfilariae in the skin (LEE GROSS et al., 1992; KAMALU, 1986; ŽIVIČNJAK et al., 2006). In a few cases where dogs found to be massively infected with adult worms and with high microfilaremia in blood, gross and histopathological changes in many organs, like spleen, liver, kidneys, lungs, heart and brain (KAMALU, 1991; MANDELLI and MANTOVONI, 1966; RESTANI et al., 1962) were reported. Dirofilariosis is also an underestimated problem in veterinary medicine and public health in Croatia. Microfilariae burden in dogs is quite common throughout Croatia (average 15,5 %) and the microfilariae of *Dirofilaria* genus have been generally detected by chance in clinically healthy dogs (ŽIVIČNJAK et al., 2007). This work describes the first finding of this parasite in a dog in Croatia after necropsy.

Materials and methods

During March 2004, a military dog (Rothweiler, 9 years old) was sectioned at the Department of Pathology, Faculty of Veterinary Medicine University of Zagreb and histopathological as well as cytological (HE and DIFF quick stain) examination of subcutaneous tissue, brain, pancreas, kidney, lymph nodes, liver, stomach, lung, myocardium and small intestine was performed. Also, blood smears and tissue imprints (liver, lymph node and subcutaneous tissue) were stained with DIFF Quick and examined. The two otherwise healthy dogs which had lived in cohabitation with the necropsied one (both Sarplaninac, 11 and 9 years old) were examined by modified Knott's test at the Department of Parasitology and Parasitic Diseases with Clinic. For the parasitological examination, a 3-5 mL of whole blood was drawn from the cephalic vein of the each dog and modified Knott's test was performed within three hours of the venepunction. All microfilariae in every sample were counted and measured using 400× magnification

with an ocular micrometer. S/c therapy with ivermectin (Iverktin® 1% Veterina d.o.o. 300 µg/kg b.m. twice q 7 days) was introduced.

Results

Gross findings. Necropsy revealed severe cachexia with the phlegmonous subcutaneous inflammation in the cubital, coxal and carpal regions (Fig. 1). Ruptured large jejunal diverticulum (Fig. 2) with subsequent diffuse peritonitis caused death. The intestine at the location of the diverticulum was stenotic which caused proximal jejunal dilatation (Fig. 3). In the abdomen approximately one liter of the greenish fluid was found. Stomach mucosa was focally thickened. The liver was indurate, fibrous perihepatitis and miliary disseminated hepatitis and dilatation of the gall bladder were noted. The spleen was atrophic and in the kidneys interstitial nephritis was found. The heart was dilated and hydropericardium with pulmonary edema and congestion was present. The carcass was mildly icteric and the brain was congested.

Histopathology. Vacuolar ganglyocytic cerebral change and congestion with vasogenic edema were noted in the brain. Interstitial chronic pancreatitis with proliferative chronic inflammation of the pancreatic ducts was found. Proliferative glomerulonephritis with disseminated glomerular sclerosis was present. The lymph nodes were atrophic with depleted lymphocytes, but the mesenterial lymph nodes (Fig. 4) were hyperplastic with significant hystiocytosis. The liver was cirrhotic and icteric (Fig. 5). Focal mucosal fibrosis with infiltration of the globule leukocytes was noted in the stomach mucosa (Fig. 6). In the lungs, congestion, alveolar emphysema, thrombosis of the branches of the pulmonary artery and anthracosis were present. Myofibrillar degeneration with hemorrhages (Fig. 7) in the myocardium was seen, and in the small intestine catarrhal chronic inflammation was noted. The subcutaneous tissue was affected with purulent inflammation. In all examined organs, predominately intravascular microfilariae (width 7-8 µm, length 700-850 µm) were noted. However, microfilariae were seen in tissue in the phlegmone, liver, lymph node and lungs. In the blood smears and tissue imprints of the liver, lymph node (Fig. 8) and subcutaneous phlegmone numerous microfilariae were evident.

Parasitological examination. Knott's test on the blood from the two otherwise healthy dogs which had lived in cohabitation with the necropsied one, revealed severe microfilariaemia (12000 and 3700 microfilariae per mL of blood respectively). The length and width of all microfilaria in each sample were measured. The average width of microfilaria was 7.45 µm, and average length was 395 µm. On the basis of the observed characteristics (length, width and general morphology) the microfilariae were interpreted as the species *Dirofilaria repens*.

Therapy - Applied therapy managed to clear the *D. repens* infection in 48 hours after the first application with no side-effects. Both dogs remained negative (Knott's test) and asymptomatic 35 days after the second application.

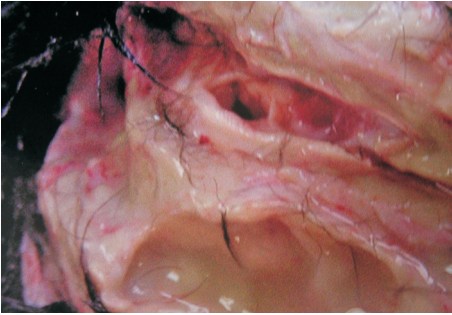


Fig. 1. Subcutaneous phlegmonous inflammation, cubital region

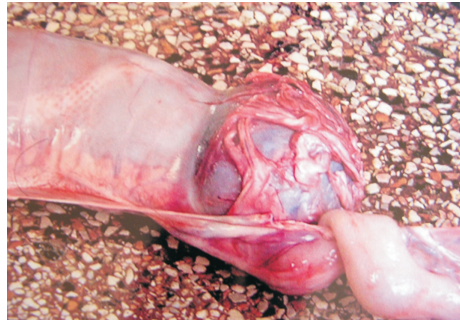

Fig. 2. Jejunal stenosis and dilatation

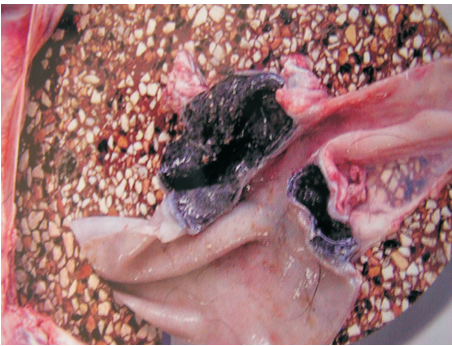

Fig 3. Jejunal diverticulum

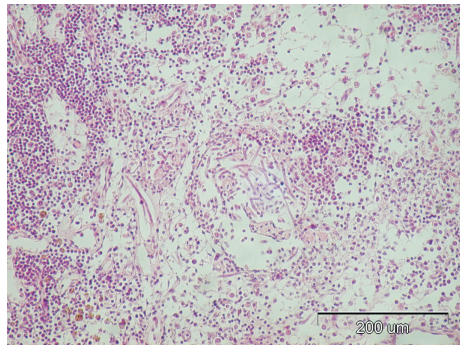


Fig. 4. Mesenterial lymph node histiocytosis and extravascular microfilariae. H&E.

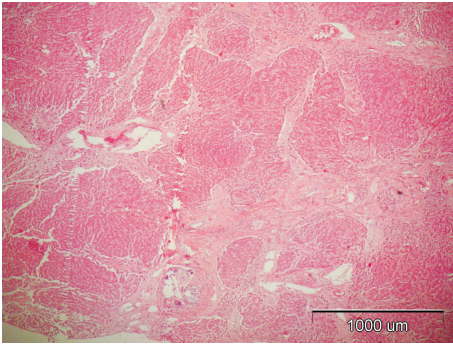


Fig. 5. Liver cirrhosis. H&E.

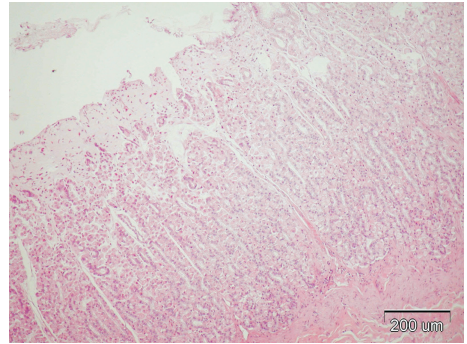


Fig. 6. Focal mucosal fibrosis with infiltration of the superficial layer with globule leukocytes. H&E.

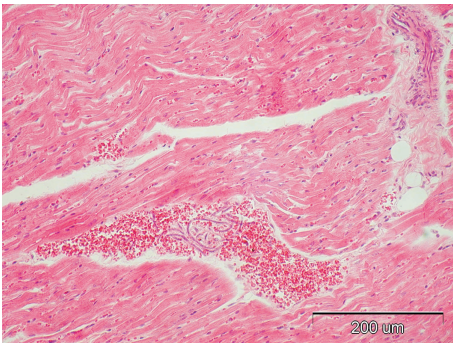


Fig. 7. Myofibrillar degeneration, hemorrhages, and microfilariae in the area of hemorrhage, myocardium. H&E.

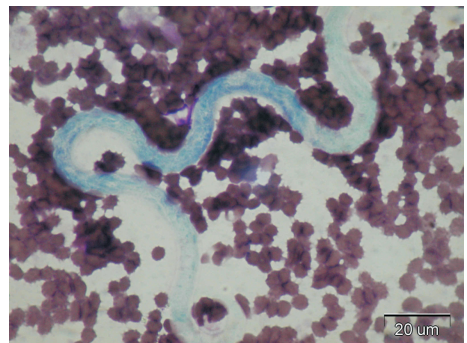


Fig. 8. Lymph node imprint, microfilaria of the *D. repens*, Diff-quick stain.

Discussion

Considering the fact that the most cases of *Dirofilaria repens* infection have been asymptomatic (GRANDI et al., 2007) there is a relative lack of information concerning pathological changes. However, severe microfilaraemia have been attributed to immunosuppression induced by some other disease (HARRUS et al., 1999). In this case, chronic intestinal and liver lesions with severe cachexia were probably responsible for

such a severe microfilariae burden. The pathogenesis of the disease is also not known. In humans, who are dead-end hosts, dead adults provoke severe inflammation with granulomatous response including giant cells, and eosinophilic infiltrate (TILAKARATNE and PITAKOTUWAGE, 2003; GARDINER et al., 1978). Rare reports pointed out the toxic and immunological effects of this parasite as very important factors in the pathogenesis of the disease (KAMALU, 1991). That opinion is partly proven by our findings concerning the pulmonary vascular thrombosis. The finding of globule leukocytes in the stomach mucosa is significant for the immune-mediate process. These cells are also present in other parasitic infections of the alimentary and respiratory systems in humans and animals (STANKIEWICZ et al, 1993). However, besides phlegmonous inflammation, it is really difficult to state which lesions are direct consequences of dirofilariosis and which result from chronic liver and intestinal lesions (stenosis and dilatation) followed by rupture which is the final cause of death.

References

- BREDAL, W. P., B. GJERDE, M. L. EBERHARD, M. ALEKSANDERSEN, D. K. WILHELMSSEN, L. S. MANSFIELD (1998): Adult *Dirofilaria repens* in a subcutaneous granuloma on the chest of a dog. *J. Small Anim. Pract.* 39, 595-597.
- GARDINER, C. H., C. E. OBERDORFER, J. E. REYES, W. H. PINKUS (1978): Infection of man by *Dirofilaria Repens*. *Am. J. Trop. Med. Hyg.* 27, 1279-1281.
- GRADONI, L., E. POZIO, M. MAROLI (1980): Filariasis in foxes in the Province of Grosseto. *Ann. Ist. Super Sanita* 16, 251-256.
- GRANDI, G., T. ŽIVIČNJAK, R. BECK (2007): Pathogenesis of *Dirofilaria* spp. infection. *Mappe parasitologiche* 8, Cringoli, G., series editor, Naples, pp. 59-66.
- HALLIWELL, R. E., W. N. T. GORMAN (1989): *Veterinary Clinical Immunology*, Philadelphia. WB. Saunders, pp. 239.
- HARRUS, S., A. HARMELIN, S. RODRIG, G. FAVIA (1999): *Dirofilaria repens* infection in a dog in Israel. *Am. J. Trop. Med. Hyg.* 61, 639-641.
- KAMALU, B. P. (1986): Canine filariasis in southeastern Nigeria. *Bull. Anim. Health Prod. Afr.* 34, 203-205.
- KAMALU, B. P. (1991): Canine filariasis caused by *Dirofilaria repens* in southeastern Nigeria. *Vet. Parasitol.* 40, 335-338.
- LEE GROSS, T., P. J. IHRKE, E. J. WALDER (1992): *Veterinary Dermatopathology*. Mosby Year Book.
- MANDELLI, G., A. MONTOVANI (1966): Su di un caso di infestazione massiva da *Dirofilaria repens* nel cane. *Parassitologie*, 8, 21-28.
- MAZURKEVICH, A., N. VASYLYK, T. AVRAMENKO, S. VELICHKO, W. TARELLO, E. VARODI (2004): Adult *Dirofilaria repens* nematodes in a cat from Kiev, Ukraine. *Vet. Rec.* 155, 638-639.

- NUCHPRAYOON, S., A. JUNPEE, S. NITHIUTHAI, S. CHUNGPIVAT, S. SUVANNADABBA, Y. POOVORAWAN (2006): Detection of filarial parasites in domestic cats by PCR-RFLP of ITS1. *Vet. Parasitol.* 140, 366-372.
- PAMPIOGLIONE, S., F. RIVASI (2000): Human dirofilariosis due to *Dirofilaria (Nochtiella) repens*: an update of world literature from 1995 to 2000. *Parassitologia* 42, 231-254.
- RESTANI, R., G. ROSSI., G. SEMPRONI (1962): Due interessanti reperti clinici in cani portatori di *Dirofilaria repens*. *Atti della Societa Italiana delle Scienze Veterinarie* 16, 406-412.
- SCHWAN, E. V., D. B. MILLER, D. de KOCK, A. Van HEERDEN (2000): *Dirofilaria repens* in a cat with acute liver failure. *J. S. Afr. Vet. Assoc.* 71, 197-200.
- SCOTT, D. W., T. C. VAUGHN (1987): Papulonodular dermatitis in a dog with occult filariasis. *Comp. Anim. Pract.* 1, 32-34.
- STANKIEWICZ, M., W. E. JONAS, P. C. G. DOUCH, B. RABEL, S. BISSET, W. CABAJ (1993): Globule leukocytes in the lumen of the small intestine and the resistance status of sheep infected with parasitic nematodes. *J. Parasitol.* 79, 940-949.
- TERLEVIĆ, E., B. GABROVEC, N. LANDEKA, M. LADAVAC VRANIĆ (2007): Dirofilaria - a new anthroponosis in Istria. Abstract book of the First European Dirofilaria Days, 22-25th February, Zagreb, Croatia. p. 13.
- TILAKARATNE, W. M., T. N. PITAKOTUWAGE (2003): *Dirofilaria repens* infection: report of seven cases. *J. Oral Pathol.* 32, 502-505.
- ŽIVIČNJAK, T., F. MARTINKOVIĆ, R. BECK (2006): Dirofilariosis in Croatia: spread and public health impact. 5th Croatian Congress on Infective Diseases, Zadar, Croatia.
- ŽIVIČNJAK, T., F. MARTINKOVIĆ, R. BECK (2007): Canine dirofilariosis in Croatia: Let's face it. Abstract Book of the First European Dirofilaria Days, 22 - 25 February, Zagreb, Croatia. p. 35.

Received: 22 November 2007

Accepted: 24 November 2008

DŽAJA, P., A. BECK, G. KIŠ, A. GUDAN KURILJ, T. ŽIVIČNJAK, B. ARTUKOVIĆ, R. BECK, M. HOHSTETER, I. C. ZUCKERMANN ŠOŠTARIĆ, Ž. GRABAREVIĆ: Invazija psa parazitom *Dirofilaria repens*. *Vet. arhiv* 78, 521-527, 2008.

SAŽETAK

U radu je prikazan nalaz invazije psa parazitom *Dirofilaria repens* koja je utvrđena razudbom. Uzrok smrti bio je peritonitis uzrokovan rupturom crijevnog divertikula. Razudbom je utvrđena teška kaheksija, flegmonozna upala potkožja u lakatnom, koksalnem i karpalnom području te jetrena ciroza praćena žuticom. Histopatološkom pretragom uočene su mnoge mikrofilarije u svim pregledanim organima, pretežito intravaskularno, u flegmoni, jetri, limfnom čvoru i plućima. U druga dva, inače zdrava psa, koji su držani zajedno s razudenom životinjom, utvrđena je dirofilarioza Knottovim testom, koja je bila izlječena ivermektinom.

Ključne riječi: *Dirofilaria repens*, pas, patomorfoloģija
