

Spontaneous agnathia-otocephaly in a lamb of the Chiotiko breed - a case report

Aris Frixos Pourlis*

*Laboratory of Anatomy, Histology and Embryology, Veterinary School, University of Thessaly, Karditsa,
Greece*

**POURLIS, A. F.: Spontaneous agnathia-otocephaly in a lamb of the Chiotiko breed
- a case report. Vet. arhiv 78, 449-456, 2008.**

ABSTRACT

A case of extreme agnathia-otocephaly in a female lamb of the Chiotiko breed was studied from the anatomical point of view and described in the present study. The external and the x-ray examination revealed a total absence of the mandible and associated structures, as well as synotia and synophtalmia-exophthalmia. In the cranial cavity severe brain malformation was observed. Dissection of the body revealed a normal structure with absence of the right kidney and ureter. The purpose of the present study was to provide an anatomic description of the agnathic lamb, to present information regarding the etiologies of this malformation and, to review the relevant literature.

Key words: congenital malformations, sheep

Introduction

Numerous cases of congenital deformities of the jaw have been reported in the international literature. Their terminology varies according to the extent of their malformation. The following terms have been proposed to characterize the different cases of jaw abnormalities: agnathia, micrognathia, brachygnathia, bird face, parrot beak, overshot jaw, undershot jaw, strophocephalia. These congenital anomalies arise from defects of pharyngeal arches.

Agnathia is relatively rare in humans, but is common in other species especially in small ruminants. From the existing literature in humans (BROWN and MARSH, 1990), as well as in sheep (DENNIS and LEIPOLD, 1972), the majority of these abnormalities are associated with various types of other anomalies, mainly in the head.

*Contact address:

Dr. Aris Pourlis, Laboratory of Anatomy, Histology and Embryology, Veterinary School, University of Thessaly, Karditsa PO Box 199, 43100 Greece, Phone: + 30 24410 66013; Fax: +30 2310 478 251; E-mail: apourlis@vet.uth.gr

The first description of agnathia in sheep was recorded in 1827 (DENNIS and LEIPOLD, 1972). The cases which were published later comprise various grades of this malformation and different classification schemes without consensus of application (THERET, 1948; FISHER, 1955; McFARLAND and DENIZ, 1964; SMITH, 1968; GLAHN-LUFT et al., 1978).

The incidence of agnathia in sheep varies among the published studies, according to their classification and the breeds. HUGHES et al. (1972), observed 25 cases of agnathia (31% lethal malformations) in 80 dead newborn lambs, during a survey of spontaneous congenital abnormalities in flocks of Merinos breed. DENNIS and LEIPOLD (1972) reported 74 cases of various types of agnathia (18.3%) among 401 malformed lambs in Western Australia during a 3-year period.

In this article, an uncommon form of agnathia - otocephaly is described, combined with other malformations that does not conform to any previously reported cases. Also, the agents and pathogenetic mechanisms of this malformation are reviewed and discussed.

Materials and methods

A dead female lamb was presented at the Unit of Experimental Embryology and Teratology of the Veterinary School, of the Aristotelian University of Thessaloniki. The delivery was normal. There was no family history of congenital anomalies and no history of drug administration.

The lamb was examined externally and photographed. Following, the head as well as the body of the lamb were x-rayed and dissected in order to detect other malformations. The head was disarticulated from the vertebral column, skinned, and examined carefully.

Results

The external examination, revealed extensive malformation of the head (Fig. 1), whereas the rest of the body exhibited normal structures in the trunk, tail and limbs. The X-rays showed the absence of brain substance bilaterally, respectively to the roof of the skull (Fig. 2). The nasal conchae were normally formed but the nasal cavities ended blindly because of rinopharyngeal aplasia. The ethmoidal conchae were well recognizable whereas the nasal septum and consequently the nose were slightly oblique (Fig. 3). The female lamb possessed a normal postcranial skeleton

Total absence of the mandible as well as complete absence of the masticatory and superficial muscles was observed. The oral cavity was absent, the bucco-pharyngeal cavity was occluded by mucous membrane and there was ventrally displacement of the pinnae. The mouth, lips and dentition were absent, but on the ventral surface, a slit like opening was observed. This opening communicated with the pharyngeal diverticulum and was surrounded by a rudimentary bone (Fig. 3). A single orbit was placed ventrally and a diaphragm of dense connective tissue separated the two orbital globes. Synophthalmia,

with increased in size (macrophthalmia), protruding eyeballs (exophthalmia) could be observed. The occipital condyles were present but it was impossible to distinguish and identify the bones of the skull. No apparent foramens except the foramen magnum could be observed. The hyoid apparatus was absent. On the lateral parts of the skull a branching vessel resembled the facial artery. The salivary glands were absent. The cranial cavity was almost empty, except a small amorphous encephalic substance which appeared to be undifferentiated. Dissection of the body revealed the absence of the right kidney and ureter.

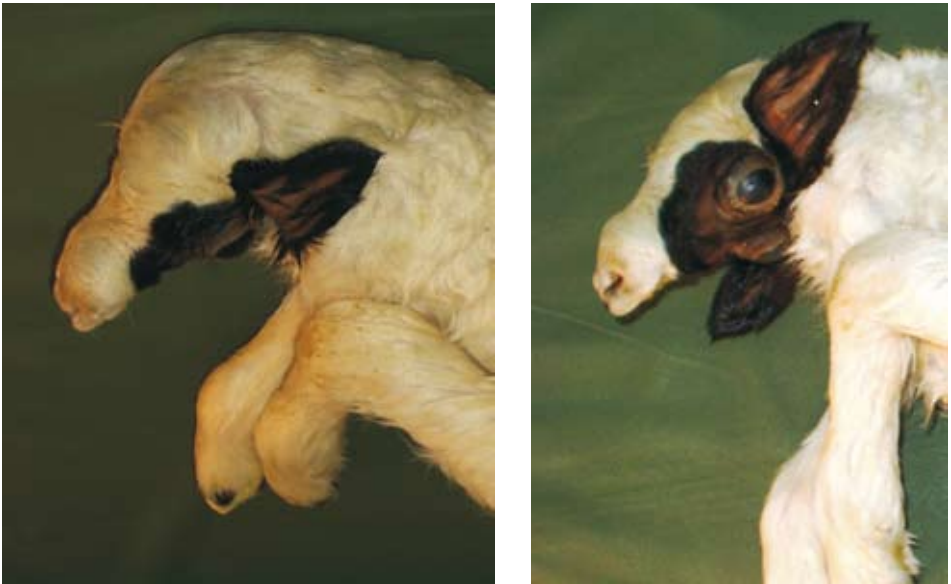

Fig. 1. Dorsolateral (left) and ventrolateral (right) aspect of the head of the agnathic lamb

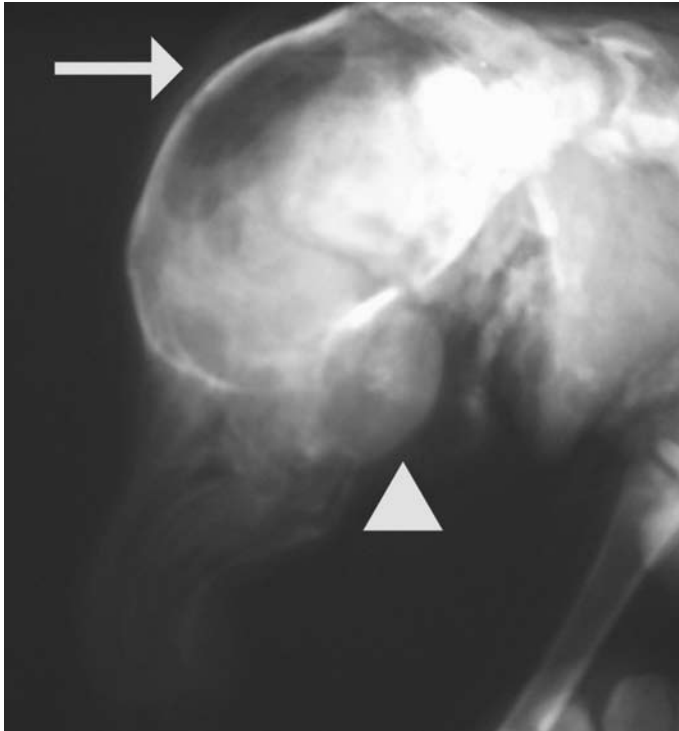


Fig. 2. Radiograph of the head. Lateral aspect. On the dorsal region (arrow) of the cranial cavity, is apparent the brain malformation. The ocular bulb is prominent (arrow head).

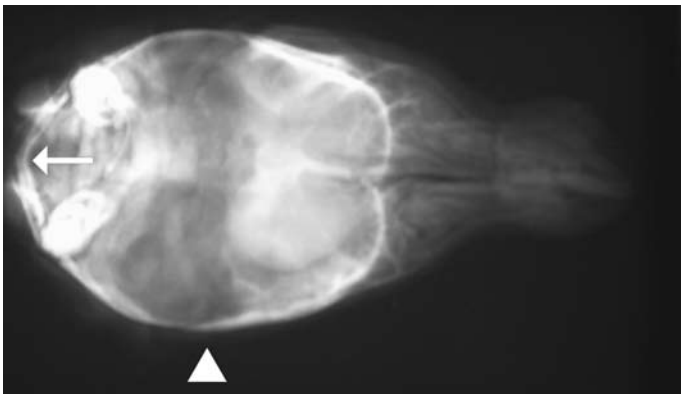


Fig. 3. Radiograph of the head. Dorsal aspect. The arrow indicates the rudimentary bone of the opening. The central area of the brain case is empty (head arrow).

Discussion

The case described above is an extreme form of agnathia which involves also malformation of the mouth, tongue, ears, eyes and face. This malformation complex could be characterized as an otocephaly. The complete absence of the mandible and the secondary abnormalities of the otopharyngeal region result in a non-patent or poorly functional airway. For this reason, agnathia is always a lethal condition.

Various classification schemes for mandibular deficiency and associated ear and facial abnormalities were devised by Saint-Hilaire, Taruffi, and Blanc (GLADSTONE and WAKELEY, 1923). These authors described and tried to group the malformations of the head in various animals, but the vast variability of agnathia and otocephaly did not permit this characterization in the present case. DENNIS and LEIPOLD (1972) proposed a morphologic classification for the malformations of the first pharyngeal arch in sheep. This classification includes all mandibulofacial malformations and is divided into 5 main types. The present case represents an intermediate form of type 3-otocephalia and type 4-ateloprosopia with exophthalmos.

The developmental history of the mandible in vertebrates is complicated. The main pathogenetic mechanism of jaw malformations involves the ventral portion of the first pharyngeal arch, which could be a secondary anomaly to deficient migration or proliferation of the neural crest cells arising from the dorsal region of the neural epithelium (WRIGHT and WAGNER, 1934). PAULI et al. (1983) suggested that agnathia results either from disturbance in neural differentiation in the region of the anterior neural plate or from breakdown of mesodermal elements required for induction of the neural plate and neural crest derivatives. Otherwise it could be the result of a primary deficiency of the mesoderm in the region of the mandibular prominence (JURILOFF et al., 1985).

Under normal conditions, the majority of head muscles originate from the somitomeres, whereas, the tongue muscles are derived from hypaxial somites 2-5 (YAMANE, 2005).

The brain malformation could be characterized as prosencephalic dysplasia. SERGI and SCHMITT (2000) described a case of vesicular forebrain (pseudo-aprosencephaly) in humans, which resembles the present lamb. The dictum "The face predicts the brain" which has been proposed from DeMYER et al. (1963), could fit perfectly in the present case.

The absence of the right kidney is extraordinary, even though it has been recorded in humans (PAULI et al., 1981). DENNIS and LEIPOLD (1972) reported one case of unilateral renal agenesis in 74 agnathic lambs. Also, the presence of macrophthalmia and exophthalmia was observed and recorded for the first time. The ocular deformity probably could be due to the abnormal development of the facial head skeleton.

The associated head and renal malformations in this case suggest a single defect at a very early stage in embryogenesis, most likely before or between the 15th -18th day of gestation, when the first and second pharyngeal arches become recognizable and the somites were formed (BRYDEN et al., 1972; OPITZ et al., 2002).

Cases of agnathia have been reported in bovine as an inherited recessive lethal deformity, restricted to the male (ELY et al., 1939; LALONDE, 1940). These cases did not present evidence for other concomitant malformations as they occur in sheep.

There is no critical evidence that agnathia in sheep is a recessive or even genetic trait although the cases reported by THERET (1948) and FISHER (1955), were associated with inbreeding. GLAHN-LUFT et al. (1978) attributed the etiology of agnathia in the hypoxia of the ovine foetus during the differentiation of the first pharyngeal arch. Another cause of agnathia could be the consumption of a teratogenic plant. In fact, BINNS et al. (1965) found that sheep embryos were highly susceptible to the range plant *Veratrum californicum* when it is eaten by ewes on day 14 of gestation. The defects were primarily confined to the head region. Secondary compounds from the plant such as the teratogens cyclophamine, jervine and cycloposine are possibly responsible (KEELER, 1978).

X-irradiation of pregnant rats at day 9 or 10, or mice at day 8, can occasionally result in agnathia (WILSON et al., 1953). Similar exposure in chicks can also result in agnathia (WOLFF, 1934). Trypan blue administration around day 9 or 10 in rats or day 8 in mice has been occasionally associated with agnathia (ZAWOISKI, 1975). Timed administration of streptonigrin can have a similar effect on mandible development (WARKANY and TAKACS, 1965). Hyperthermia at days 7 to 10 has been associated with agnathia in mice (PENNYCUIK, 1965).

Over the past decade, many studies have highlighted the role of various molecular pathways in normal and abnormal craniofacial development. These pathways such as Shh (Sonic HedgeHog), Bmp (Bone Morphogenetic Protein), Fgf (Fibroblast Growth Factor), Wnt and Pax 2 appear to influence several cellular processes in the embryologic development of the head. (OPITZ et al., 2002; TAPADIA et al., 2005) and kidney (QUAGGIN, 2003).

The identification of etiological agents or causative mechanisms is extremely difficult. From the study of the relevant literature, seems that agnathia in sheep could be an excellent model for the understanding of the molecular mechanisms involved in the normal formation or malformation of the head.

Acknowledgements

The author would like to thank Dr B. Babidis who provided the lamb, and the staff of the Clinic of Surgery for their technical assistance.

References

- BINNS, W., J. L. SHUPE, R. F. KEELER, L. F. JAMES (1965): Chronologic evaluation of teratogenicity in sheep fed *Veratrum californicum*. J. Am. Vet. Med. Assoc. 147, 839-842.
- BROWN, D. M., J. L. MARSH (1990): Agnathia and associated malformations: A case report. Cleft Palate J. 27, 415-418.
- BRYDEN, M. M., H. E. EVANS, W. BINNS (1972): Embryology of the sheep. I. Extraembryonic membranes and the development of body form. J. Morph. 138, 169-186.
- DeMYER, W., W. ZEMAN, C. G. PALMER (1963): The face predicts the brain: diagnostic significance of median facial anomalies for holoprosencephaly (arhinencephaly). Pediatrics 34, 256-263.
- DENNIS, S. M., H. W. LEIPOLD (1972): Agnathia in sheep: External observations. Am. J. Vet. Res. 33, 339-347.
- ELY, F., F. E. HULL, H. B. MORRISON (1939): Agnathia, a new bovine lethal. J. Hered. 30, 105-108.
- FISHER, H. (1955): Agnathia, a rare lethal malformation in sheep. Hemera Zoa 62, 260.
- GLADSTONE, R.J., C. P. G. WAKELEY (1923): Defective development of the mandibular arch. J. Anat. 57, 149-167.
- GLAHN-LUFT B., H. SCHNEIDER, J. SCHNEIDER, R. WASSMUTH (1978): Agnathie beim schaf mit chromosomenaberrationen und Hb-Mangel. Dtsch. Tierärztl. Wschr. 85, 472-474.
- HUGHES, K. L., K. G. HAUGHEY, W. J. HARTLEY (1972): Spontaneous congenital developmental abnormalities observed at necropsy in a large survey of newly born dead lambs. Teratology 5, 5-10.
- JURILOFF, D. M., K. K. SULIK, T. H. RODERICK., B. K. HOGAN (1985): Genetic and developmental studies of a new mouse mutation that produces otocephaly. J. Craniofac. Genet. Dev. Biol. 5, 121-145.
- KEELER, R. F. (1978): Cycloamine and related steroidal alkaloid teratogens: Their occurrence, structural relationship and biologic effects. Lipids 13, 708-715.
- LALONDE, L. M. (1940): A new type of bovine agnathia. J. Hered. 33, 80-81.
- McFARLAND, L. Z., E. DENIZ (1964): Extreme agnathia in a ewe lamb. Cornell Vet. 54, 541-544.
- OPITZ, J. M., G. ZANNI, J. F. JR. REYNOLDS, E. GILBERT-BARNES (2002): Defects of blastogenesis. Am. J. Med. Genet. 115, 269-286.
- PAULI, R. M., J. M. JR. GRAHAM, M. BARR (1981): Agnathia, situs inversus and associated malformations. Teratology 23, 85-93.
- PAULI, R. M., J. C. PETERSEN, A. S. ARY, E. GILBERT (1983): Familial agnathia-holoprosencephaly. Am. J. Med. Genet. 14, 677-698.
- PENNYCUIK, P. R. (1965): The effects of acute exposure to high temperature on prenatal development in the mouse with particular reference to secondary vibrissae. Aust. J. Biol. Sci. 18, 97-113.

- QUAGGIN, S. E. (2003): Mammalian kidney development: molecules to treatment. *Fetal Matern. Med. Rev.* 14, 309-327.
- SERGI, C., H. P. SCHMITT (2000): The vesicular forebrain (pseudo-aprosencephaly): a missing link in the teratogenic spectrum of the defective brain anlage and its discrimination from aprosencephaly. *Acta Neuropathol.* 99, 277-284.
- SMITH, I. D. (1968): Agnathia and micrognathia in the sheep Austral. *Vet. J.* 44, 510-511.
- TAPADIA, M. D., D. R. CORDERO, J. A. HELMS (2005): It's all in your head: new insights into craniofacial development and deformation. *J. Anat.* 207, 461-477.
- THERET, M. (1948): Une mutation létale récessive chez le mouton. *Rec. Méd. Vét.* 84, 445-447.
- YAMANE, A. (2005): Embryonic and postnatal development of masticatory and tongue muscles. *Cell Tissue Res.* 322, 183-189.
- WARKANY, J., E. TAKACS, (1965): Congenital malformations in rats from streptonigrin. *Arch. Pathol.* 79, 65-79.
- WILSON, J. R., H. C. JORDAN, R. L. BRENT (1953): Effects of irradiation on embryonic development II. X-rays on the ninth day of gestation in the rat. *Am. J. Anat.* 92, 153-177.
- WOLFF, E. (1934): Recherches experimentales sur otocephalie et les malformations fondamentales de la face. *Arch. Anat. Histol. Embryol.* 18, 231-261.
- WRIGHT, S., K. WAGNER (1934): Types of subnormal development of the head from inbred strains of guinea pigs and their bearing on the classification and interpretation of vertebrate monsters. *Am. J. Anat.* 54, 383-448.
- ZAWOISKI, E. J. (1975): Prevention of trypan blue-induced exencephaly and otocephaly in gestating albino mice. *Toxicol. Appl. Pharmacol.* 31, 191-200.

Received: 13 June 2007

Accepted: 5 September 2008

POURLIS, A. F.: Spontana agnatija-otocefalija u janjeta pasmine Chiotiko - prikaz slučaja. *Vet. arhiv* 78, 449-456, 2008.

SAŽETAK

Prikazane su anatomske značajke izrazite agnatije-otocefalije u ženskoga janjeta pasmine Chiotiko. Općom pretragom i pretragom x-zrakama nije ustanovljena donja čeljust ni pripadajuće strukture. Uočena je sinotija i sinoftalmija-egzoftalmija. U lubanjskoj šupljini ustanovljene su teške malformacije mozga. Tijelo je bilo normalno građeno, ali je nedostajao desni bubreg i mokraćna cijev. Svrha ovoga prikaza bila je pružiti anatomske opis agnatije u janjeta, raspraviti o etiologiji te malformacije te dati pregled odgovarajuće literature.

Ključne riječi: kongenitalne malformacije, ovca
