

The rodenticidal effect of indomethacin: pathogenesis and pathology

Victor Olusegun Taiwo, and Omotayo Lawal Conteh

Department of Veterinary Pathology, University of Ibadan, Ibadan

TAIWO, V. O., O. L. CONTEH: The rodenticidal effect of indomethacin: pathogenesis and pathology. Vet. arhiv 78, 167-178, 2008.

ABSTRACT

The pathogenesis and pathology of the rodenticidal action of indomethacin, a non-steroidal anti-inflammatory drug, were investigated. Sixteen Norway rats and 16 albino mice, aged 10-12 weeks with mean mass of 99.6 g and 28.4 g, respectively were divided into eight groups of 4 rats (R1, R2, R3 and R4) and 4 mice (M1, M2, M3 and M4). Rodents in R1 and M1 were controls (0 mg/kg indomethacin), while those in R2, R3, R4, and M2, M3, M4 were each given 83 mg/kg, 166 mg/kg and 250 mg/kg body mass of indomethacin orally, respectively. Clinical signs, symptoms and mortalities were monitored, while detailed postmortem examination was carried out. Indomethacin caused anorexia, dehydration and weakness, which became progressively worse with time; and there was 100% mortality within 36 and 82 hours in mice and rats, respectively. Seven rats (43.8%) were diarrheic, and had bilateral medial canthi haemorrhages. Gross lesions in all the rodents include congested and haemorrhagic stomach and intestinal mucosae, with focal areas of ulcerations, and focal pale areas on the liver. Histopathological changes in various organs were similar, irrespective of the animal species and dose of indomethacin, and include widespread congestion and haemorrhage, thrombi in arterioles and capillaries of the kidney, heart, lungs, brain, testes and splenic fat. There was widespread glandular degeneration and necrosis, erosions, ulcerations in the stomach and small intestines, renal glomerular and tubular degeneration, hepatocellular necrosis, myocardial necrosis, testicular and neuronal degeneration. Indomethacin appears to cause widespread endothelial and mucosal damage, haemorrhage and vascular thrombosis, leading to ischaemic necrosis, with subsequent multiple organ failure and death. The mechanisms of action and implications of the use of indomethacin as a rodenticide to domestic pets are discussed.

Key words: rodenticide, indomethacin, toxicoses, pathology, pathogenesis, rats, mice

Introduction

Various methods of controlling rodents have been employed in times past. These methods range from the ancient biological means, which is by keeping of cats, dogs, snakes, ferrets and so on, to act as predators in rat infested areas (ALONGE, 2003). This

*Contact address:

Victor Olusegun Taiwo, DVM, MVetSci, PhD, MCVSN, Department of Veterinary Pathology, University of Ibadan, Ibadan, Nigeria, Phone: +234 803 610 7013; E-mail address: victaiwo52@yahoo.com

method is still in use in most rural areas of developing countries. Physical methods of control are the use of baited traps and rat-proof construction (ALONGE, 2003).

Meanwhile, the most widely employed method of control is the use of chemicals called rodenticides. These include α -naphthyl thiourea (ANTU), warfarin congeners, zinc phosphide, cyanide compounds, strychnine, thallium, fluorosilicate, fluoroacetamide, fluoroacetate and so on. However, because of the high cost and the dangers (side/toxic effects) of the aforementioned rodenticides, attempts have been made to look into alternative chemicals that are cheaper and less dangerous to man and his animals.

Indomethacin is a non-specific anti-inflammatory drug (NSAID) that was developed specifically to abate the inflammatory responses to the indolic hormones, serotonin and tryptophan (BOYNTON et al., 1988; BRANDT, 1991). It was introduced in 1963 for the treatment of rheumatoid arthritis, degenerative joint diseases, ankylosing spondylitis, gout, acute musculoskeletal disorders, inflammation and oedema following surgical technique and pain associated with primary dysmenorrhoea (HARDMAN et al., 2001). The development, chemistry and pharmacology have been reviewed (HARDMAN et al., 2001). Indomethacin is 1-(p-chlorobenzoyl)-5-methoxy-2-methylindole-3-acetic acid that has prominent anti-inflammatory and analgesic-antipyretic properties similar to the salicylates. It has analgesic properties distinct from its anti-inflammatory effects and there is evidence for both a central and peripheral action. Indomethacin is a potent inhibitor of the cyclooxygenases (COX) 1 and 2; it also inhibits motility of polymorphonuclear leucocytes. Like many other NSAIDs, indomethacin uncouples oxidative phosphorylation at supratherapeutic concentrations and depresses the biosynthesis of mucopolysaccharides (BRANDT, 1991; SLAGLE, 2001). Quite recently, Piroxicam[®], another inhibitor of COX-2 activity like indomethacin, has been used for the treatment of oral squamous cell carcinoma in dogs (PESTILI de ALMEIDA et al., 2001; SCHMIDT et al., 2001).

Due to the high incidence and severity of side-effects associated with long-term administration, indomethacin is not commonly used for therapy as an analgesic or antipyretic again (SLAGLE, 2001). Currently, there is less human usage or commercial demand for the drug which therefore makes it relatively cheap and available in most third world countries, especially in Nigeria. Meanwhile, there are increasing reports of its use as a rodenticide in most homes and farms. Due to the relative ease of human and especially animal toxicosis associated with possible consumption of rodents killed with indomethacin, it is imperative to study the pathogenesis and pathology of its rodenticidal activity, by determining the effects of various dosage regimens, the interval between ingestion of the drug, onset of clinical signs and death, and document the pathological changes in the various organs in order to elucidate the pathogenesis of the lesions.

Materials and methods

Animal, indomethacin preparation and experimental design. Sixteen common or Norway rats (*Rattus norvegicus*) and sixteen house mice (*Mus musculus* L) were used for this experiment. They were aged between 10-12 weeks and weighed 85-105 g (99.6 ± 5.9 g) and 17-34 g (28.4 ± 4.8 g), for rats and mice, respectively. They were purchased from the Experimental Animal Unit, Faculty of Veterinary Medicine, University of Ibadan. The animals were stabilized for one week before the commencement of the project and were given commercial pelleted feed and clean drinking water *ad libitum*. After stabilization, the rats and mice were randomly divided into four (4) groups of four rats each: R1, R2, R3 and R4, and four mice each: M1, M2, M3 and M4. Groups R1 and M1 served as the controls.

Sixteen capsules of Indocid® (25 mg indomethacin; Merck, Sharp and Dohme, UK) were purchased from the Jaja Clinic Pharmacy, University of Ibadan, Nigeria. The 16 capsules were reconstituted with 16 millilitres (mL) of clean water to make a final dilution of 25 mg indomethacin/mL of water. Though indomethacin is sparingly soluble in water, a homogenous solution was achieved by constant stirring. Each rat and mouse in groups R2 and M2, R3 and M3, and R4 and M4 were given calculated volumes of the solution equivalent to 83 mg/kg, 166 mg/kg and 250 mg/kg body mass of indomethacin, respectively. Administration was carried out by the use of a 1 mL syringe fitted with a 1mm bore metal canular to deliver the drug directly into the oesophagus. The animals were fasted overnight prior to the administration, while feed and water were introduced immediately after.

Monitoring of clinical signs and symptoms. From the onset of drug administration, the rats and mice were monitored for any clinical signs and symptoms of appetite, skin coat sheen and turgour, mortality and other behavioural signs, such as response to stimuli (noise and light) continually until the last mortality was recorded.

Histopathology. Immediately after death, or sacrifice of control rats and mice by diethyl ether suffocation, the carcasses were placed on dorsal recumbency on flat soft wood and held in place by pins on the fore and hind limbs for post mortem examination. The internal organs were exposed by gentle dissection. The liver, heart, spleen, kidney, lungs, brain, stomach, intestines, testes/ovaries and adrenal glands were observed for gross lesions. Small portions, 4-5 mm diameter, of each organ/tissue were preserved in 10% phosphate-buffered formalin for 24 hours. The tissues/organs were thereafter dehydrated in graded concentrations of absolute alcohol, cleared in xylene and embedded in paraffin wax at 60 °C. The paraffin-embedded tissue sections were cut on a microtome at 5 µm, mounted on clean glass slides and dried in an oven. The sections were stained with haematoxylin and eosin (H&E) for examination under light microscope for histopathological changes. Photomicrographs of selected lesions in each tissue were taken at different magnification

using camera (Ortholux; GmbH) fitted to a light microscope as described by TAIWO and ANOSA (2000).

Results

Clinical signs and symptoms. Rats and mice in the control group did not manifest any unusual clinical signs and symptoms or abnormal behaviour throughout the experimental period and no mortality was recorded in this group. However, all the rats and mice in the experimental groups showed anorexia, dehydration and weakness, which became progressively worse with time. Anorexia developed immediately after administration of the drug as experimental rats and mice only went near the feed, without consuming it. Weakness started developing as they responded slowly and sluggishly to stimuli such as touch, light and noise. By 24 hours after drug administration, dehydration was noticed in all animals, as normal skin turgor was almost lost.

All the experimental mice died within 36 hours with the earliest (one from group M2) dying at about 28 hours and the last (one from group M2) dying at about 36 hours after drug administration. Meanwhile, all rats in group R4 (those given 250 mg/kg body mass indomethacin) and one from group R2 (those given 166 mg/kg body mass indomethacin) died 36-48 hours after drug administration. These showed clinical signs similar to those reported for the experimental mice. The remaining 7 rats (three from group R2 and four from R3) died after 48 hours but additionally had diarrhoea and bilateral haemorrhage from the medial canthi. The last rat (from group R2) died at 82 hours after drug administration.

Pathology. Rats and mice in the control group showed no significant observable gross lesions on the heart, liver, spleen, brain, stomach, intestines and testes. Rats and mice given 83 mg/kg and 166 mg/kg body mass of indomethacin had their stomachs filled with undigested feed, some mixed with blood, but no observable gross lesions on the heart, liver, spleen, brain, stomach, intestines, testes and ovaries. Rats and mice given 250 mg/kg body mass of indomethacin also had their stomachs filled with blood-stained undigested feed, had congested stomach and intestinal mucosae and a few focal pale areas on the liver and myocardium, haemorrhagic intestines and slightly soft testes in the males. The rats and mice in the control groups (R1 and M1) showed no histological lesions in any organs.

Histological lesions observed in all the experimental animals were similar, irrespective of the animal species and dose of indomethacin, but they varied in severity and spread in the different experimental animals (Table 1; Figs. 1 to 5). In summary, these lesions include vascular congestion and haemorrhage in the kidney, heart, lungs, brain, testes and splenic fat, and thrombi in blood vessels of the lungs, kidney, heart,

Table 1. Organ/tissue pathology scores of rats and mice after oral administration of varying doses (mg/kg body mass) of indomethacin

Organ/tissue lesions	Mice				Rats			
	M1 (0)	M2 (83)	M3 (166)	M4 (250)	R1 (0)	R2 (83)	R3 (166)	R4 (250)
Lungs								
Pulmonary congestion	±	++	++	++	±	++	++	++
Haemorrhage	-	++	+++	++	-	+++	++	+++
Pulmonary oedema	-	++	++	++	-	++	++	++
Thrombi in vessels	-	++	+	++	-	++	+	++
Heart								
Congestion/haemorrhage	-	±	+	++	-	+	++	++
Myocardiac degeneration and necrosis	-	+	-	++	-	+	+++	+++
Cellular infiltration	-	+	-	+	-	±	++	++
Thrombi in blood vessels	-	++	+	+	-	+	+	++
Liver								
Sinusoidal congestion	-	++	++	++	-	++	++	++
Hepatic necrosis	-	++	+	+++	-	++	++	+++
Kupffer cell hyperplasia	-	+	+	+	-	±	+	++
Kidney								
Congestion/haemorrhage	±	++	++	+++	-	+	++	++
Glomerular and tubular degeneration and necrosis	-	+++	++	+++	-	++	++	+++
Thrombi in vessels	-	+	+	++	-	+	+	+
Stomach								
Congestion/haemorrhage	-	++	++	+++	-	++	++	++
Glandular necrosis	-	+	++	++	-	+	++	++
Erosions/ulcers	-	++	++	+++	-	++	++	++
Small Intestine								
Congestion/haemorrhage	±	++	++	++	-	+	++	+++
Villous collapse	-	++	++	++	-	++	++	+++
Erosions/ulcers	-	+++	++	++	-	++	++	++
Glandular necrosis	-	++	++	+	-	+	++	++
Brain								
Congestion/ haemorrhage	-	++	++	++	±	+	++	++
Neuronal degeneration, gliosis and spongiosis	-	++	+	++	-	++	++	++
Cerebral malacia	-	±	-	±	-	+	++	++
Testis								
Testicular degeneration	-	++	++	++	-	+	++	++
Thrombi in vessels	-	++	+	±	-	+	++	++
Spleen/Splenic fat								
Lymphoid necrosis	-	+	+	+	-	+	++	+
Enhanced haemopoiesis	±	+	+	+	±	+	+	++
Thrombi in vessels	-	-	+	+	-	-	++	-

- no lesions observed; ± mild, focal lesions; + moderate, multifocal lesions; ++ moderately severe, diffuse lesions; +++very severe, diffuse lesions

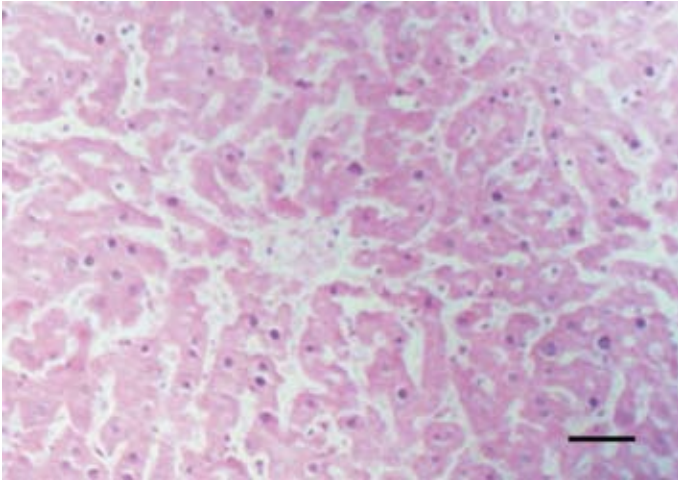


Fig. 1. Severe widespread sinusoidal congestion and coagulative necrosis of hepatocytes in a mouse given 83 mg/kg body mass indomethacin. H&E.

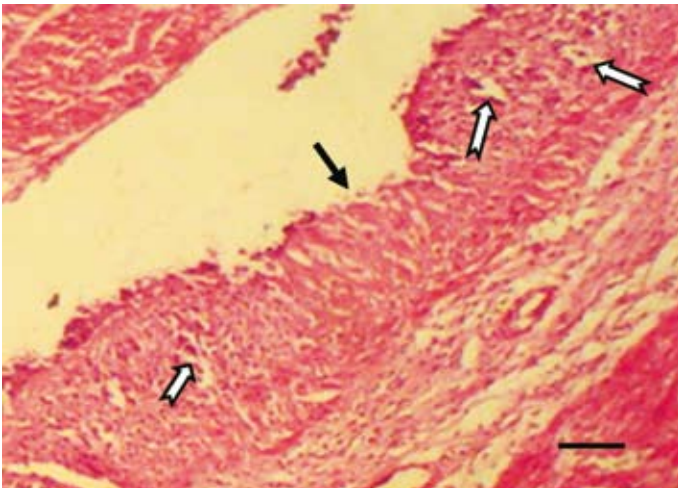


Fig. 2. Vascular congestion, haemorrhage, gastric ulceration (black arrow) and glandular necrosis (notched arrows) in the stomach of a mouse given 166 mg/kg body mass indomethacin. H&E.

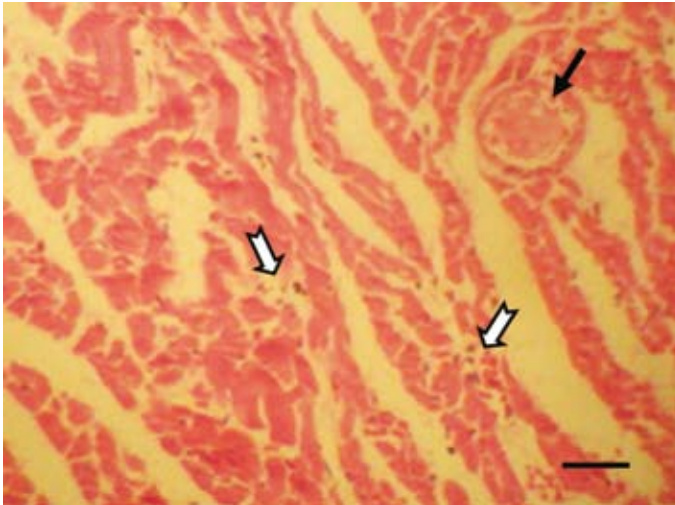


Fig. 3. Myocardial degeneration, necrosis and mononuclear cellular infiltration (notched arrows) and a thrombus in a vasa vasorum (black arrow) of a rat given 250 mg/kg body mass indomethacin. H&E.

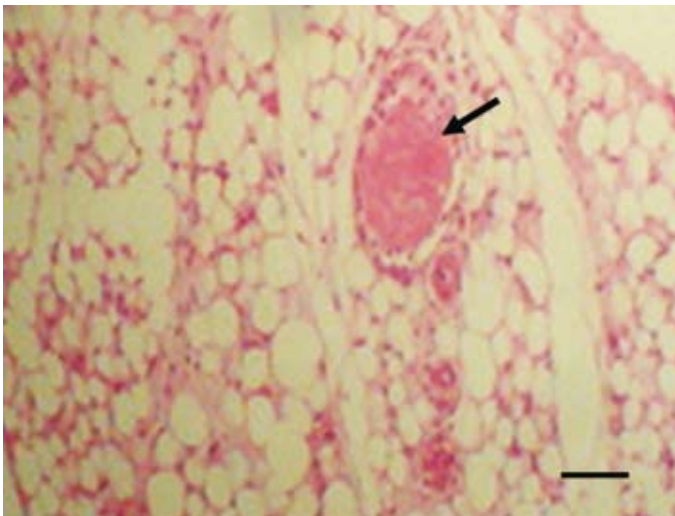


Fig. 4. A thrombus in a venule (arrow) and congestion in the perirenal fat of a rat given 166 mg/kg bodyweight indomethacin. H&E.

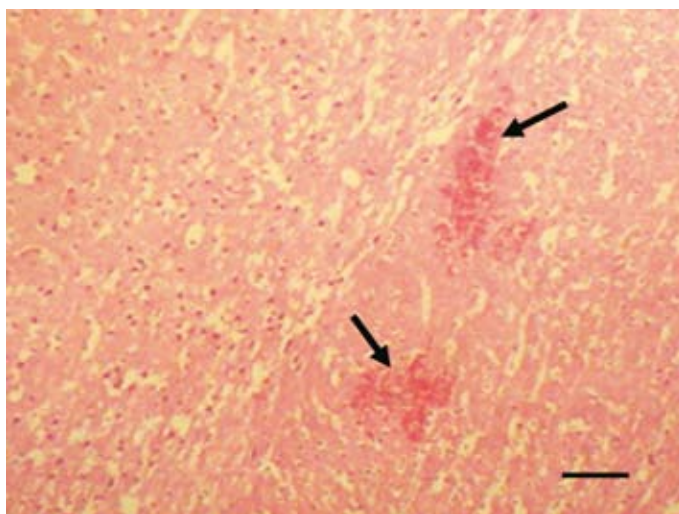


Fig. 5. Cerebral haemorrhages (arrows), neuronal degeneration and mild spongiosis in a rat given 166 mg/kg body mass indomethacin. H&E.

spleen and testis. There was also severe glandular degeneration and necrosis, erosions, ulcerations in the stomach and small intestines, severe widespread renal glomerular and tubular degeneration, coagulative necrosis of the liver, myocardiac degeneration and necrosis, testicular degeneration, encephalomalacia and neuronal degeneration, gliosis and spongiosis.

Discussion

Rats and mice in the control group did not show any unusual clinical signs and symptoms, neither did they die nor show any gross or histological organ/tissue lesions. The anorexia observed in all experimental rats and mice may be due to the immediate and almost complete absorption of indomethacin and subsequent irritation of the gastrointestinal tract in fasting subjects (JONNES et al., 1992). The dehydration in the experimental animals may be due to the anorexia and probably the extreme weakness and inability of the animals to get to where water was placed. The presence of undigested and blood-stained feed in the stomach seen in most of the experimental rats and mice may be associated with single or multiple gastric ulcerations in the stomach wall.

This study has shown that indomethacin will kill rats and mice within 24-96 hours, even with a dose as low as 83 mg/kg body mass. Though OMOGBAI et al. (1999) reported an LD_{50} of indomethacin to be 12.5 ± 1.15 mg/kg body mass in a seven-day trial in rats,

our preliminary results revealed an average LD₅₀ of 21.5 mg/kg body mass in rats and 15.2 mg/kg body mass in mice within 12 hours (unpublished data). Our findings show a significant reduction in the dosage of a similar rodenticidal regimen by MAKINDE (1991) who used between 25-75 mg/kg body mass of indomethacin and yet did not observe 100% mortality. This variation may be attributed to the mode of drug delivery in the earlier study.

The gross and histopathological changes observed in all the experimental animals are similar, irrespective of the animal species and dose of indomethacin. However, some of the lesions, notably the severity and extent of vascular congestion and haemorrhage, varied slightly with increasing doses. Like many other NSAIDs, indomethacin has been shown to uncouple oxidative phosphorylation at supratherapeutic concentrations and depresses the biosynthesis of mucopolysaccharides (SLAGLE, 2001). Mucopolysaccharides are secreted into the stomach and intestinal mucosae by goblet cells where they act as surface protective substances against the very acidic and alkaline nature of the stomach and intestines, respectively. Lack of these substances will expose these mucosae to acids and alkali, thus leading to necrosis, erosions and ulceration.

Indomethacin has also been reported to inhibit synthesis of prostaglandins, which have cytoprotective effects on gastric mucosa. In fact, this has been thought to be the major mechanism of the gastrotoxic effect of indomethacin (WHITTLE, 1976; BRANDT, 1991). However, it has been suggested that the gastrotoxic effects of NSAIDs cannot only be explained by their inhibitory effect on prostaglandins synthesis. Rather, it was reported that most NSAIDs cause gastric mucosa damage through both necrosis and apoptosis of gastric mucosa cells (BRUNE, 1987; SLAGLE, 2001).

Whilst the concept that NSAIDs act through inhibition of prostaglandin synthesis has been used widely as the single most coherent, pathogenetic pathway of action and ulcerogenic side effects, it has been shown that many other aspirin-like drugs inhibit other cellular enzymes (FLOWER, 1974; BOYNTON et al., 1988; BRANDT, 1991). For instance, inhibition of phosphodiesterase enzyme and the uncoupling of mitochondrial phosphorylation may be important in considering the effects of these drugs when used at high local or systemic concentrations. Damage to mitochondria at the site of local high concentrations was reported to result in failure of mucosal integrity, ulceration, haemorrhage and perforation of stomach wall (BOYNTON et al., 1988; SLAGLE, 2001). Because of the high concentration of indomethacin in the blood, the uncoupling of endothelial cell DNA will lead to cell death, vascular damage, thrombosis and tissue/organ ischaemia and necrosis. This latter pathogenetic pathway has been aptly demonstrated in this study as the most plausible cause of organ damage, haemorrhagic necrosis and death of the rodents.

Conclusions

Indomethacin has been found to be a good rodenticide, as adult common or Norway rats (*Rattus norvegicus*) and house mouse (*Mus musculus L*) died 2-4 days after consumption of doses between 86 to 250 mg/kg body mass. A capsule of indomethacin (25 mg) generously applied to baits like meat, fish, sausage or other food stuff and a significant number of such scattered in a rat-infested area will give almost 100% mortality in less than one week. Other commonly used rodenticides have faster onset of action, e.g. ANTU (12-15 mins) and fluoroacetate (30 mins-2 hours) (HATCH et al., 1975), indomethacin has a slower onset of rodenticidal action like warfarin (act over a period of one week). This implies that indomethacin poisoned-baits can be carried to nesting places for consumption by other rodents. This makes rodents die in inaccessible locations, thus giving the premises an offensive odour (HATCH et al., 1975). Household pets such as dogs and cats are at risk in rodent-infested areas, especially where indomethacin is commonly used. Consumption of rodents killed with indomethacin (or other NSAIDs) by these pets may render them vulnerable to the toxic effects of the drug, especially when consumed in relatively high doses over a short period of time, or in low doses over a long period (JONNES et al., 1992). This may explain some of very common, non-infectious hepatic toxicosis, gastric and intestinal haemorrhages, ulceration and melena often encountered in city dogs brought for autopsy in recent times.

The present study has revealed that the most severe central lesion is mucosal and endothelial damage, haemorrhage and disseminated intravascular coagulation. Widespread organ necrosis, especially the stomach, intestines, liver, kidneys, heart and brain through thrombosis and ischaemia constitute the major pathogenetic pathway of the rodenticidal action of indomethacin. Further studies, necessary to ascertain the safety or otherwise of dogs and cats that may consume indomethacin poisoned-rats in our environment, are in progress.

References

- ALONGE, D. O. (2003): Meat and Milk Hygiene. Chapter 5. Ibadan University Press. pp. 45-55.
- BOYNTON, C. S., C. F. DICK, G. H. MAYOR (1988): NSAIDs: an overview. *J. Clin. Pharmacol.* 28, 12-17.
- BRANDT, K. D. (1991): The mechanism of action of NSAIDs. *J. Rheumatol.* 18, 120-121.
- BRUNE, K., K. DIETZEL, B. NUMHERG, H-Th. SCHNEIDER (1987): Recent insights into the mechanism of gastrointestinal tract ulceration. *Scand. J. Rheumatol.* 16 (Suppl 65), 135-140.
- FLOWER, R. J. (1974): Drugs which inhibit prostaglandin biosynthesis. *Pharm. Rev.* 26, 33-67.
- HARDMAN, J. G., L. E. LIMBIRD, A. G. GILMAN (2001): Goodman and Gilman's The Pharmacological Basic of Therapeutics. 10th International Edition, The McGraw-Hill Companies Inc.

V. O. Taiwo and O. L. Conteh: The rodenticidal effect of indomethacin: pathogenesis and pathology

- HATCH, R. C. (1975): Poisons causing respiratory insufficiency. In: Veterinary Pharmacology and Therapeutics. 4th ed, Chapters 57-59, pp. 1129-1181.
- JONNES, R. D., R. E. BAYNES, C. T. NIMITZ (1992): NSAIDs toxicosis in dogs and cats: 240 cases. J. Am. Vet. Med. Assoc. 2001, 475-477.
- MAKINDE, A. J. (1991): Toxic effect of varying doses of indomethacin on laboratory rodents. DVM Project Dissertation, University of Ibadan, Ibadan.
- OMOGBAI, E. K., R. I. OZOLUA, P. E. IDAEWOR, A. O. ISAH (1999): Some studies on the rodenticidal action of indomethacin. Drug Chem. Toxicol. 22, 629-642.
- PESTILI de ALMEIDA, E. M., C. PICHÉ, J. SIROIS, F. MONIQUE (2001): Expression of cyclo-oxygenase-2 in naturally occurring squamous cell carcinomas in dogs. J. Histochem. Cytochem. 49, 867-875.
- SCHMIDT, B. R., N. W. GLICKMAN, D. B. A. E, de GORTARI, D. W. KNAPP (2001): Evaluation of piroxicam for the treatment of oral squamous cell carcinoma in dogs. J. Am. Vet. Med. Assoc. 218, 1783-1786.
- SLAGLE, M. A. (2001). Featured CME Topic: Pain Management. Southern Med. J. 94, 771-774.
- TAIWO, V. O., V. O. ANOSA (2000): In vitro erythrophagocytosis by cultured macrophages stimulated with extraneous substances and those isolated from the blood, spleen and bone marrow of Boran and N'dama cattle infected with *Trypanosoma congolense* and *T. vivax*. Onderstepoort J. Vet. Res. 67, 273-287.
- WHITTLE, B. J. R. (1976): Relationship between the prevention of rat gastric erosions and the inhibitions of acid secretion by prostaglandins. Eur. J. Pharmacol. 40, 233-239.

Received: 24 September 2006

Accepted: 3 March 2008

TAIWO, V. O., O. L. CONTEH: Rodenticidni učinak indometacina: patogeneza i patologija. Vet. arhiv 78, 167-178, 2008.

SAŽETAK

Istražena je patogeneza i patologija rodenticidnoga učinka nesteroidnoga protuupalnoga lijeka indometacina. Istraživanje je provedeno na 16 smeđih štakora prosječne tjelesne mase od 99,6 g i 16 albino miševa prosječne tjelesne mase od 28,4 g u dobi od 10 do 12 tjedana. Životinje su bile podijeljene u osam skupina. U svaku skupinu uvrštena su četiri štakora (R1, R2, R3, R4) odnosno četiri miša (M1, M2, M3, M4). Životinje pod oznakom R1 i M1 bile su kontrolne i nisu dobivale indometacin. Štakorima skupina R2, R3, R4 te miševima skupina M2, M3, M4 oralnim je putem apliciran indometacin u dozama od 83 mg/kg, 166 mg/kg i 250 mg/kg. Promatrani su klinički znakovi i uginuća. Uginule životinje bile su razudene. Indometacin je uzrokovao anoreksiju, dehidraciju i slabost te 100%-tnu smrtnost tijekom 36 sati nakon primjene u miševa i 82 sata nakon primjene u štakora. U sedam štakora (43,8%) zabilježen je proljev te krvarenje po sluznici medijalnih očnih kutova. U svih je glodavaca dokazana punokrvnost, krvarenja po sluzici želuca i crijeva sa žarišnim ulceracijama te mjestimično bljedilo jetre. Patohistološke promjene u različitim organima bile su slične bez obzira na vrstu životinje i dozu. Najčešće je ustanovljena kongestija organa i krvarenja te trombi u arteriolama i kapilarama bubrega, srca, pluća, mozga, sjemenika i slezene. Zabilježena je i žljezdana degeneracija kao i nekroze, erozije,

V. O. Taiwo and O. L. Conteh: The rodenticidal effect of indomethacin: pathogenesis and pathology

ulceracija želuca i tankog crijeva, glomerulotubularna degeneracija bubrega, hepatocelularna nekroza, nekroza miokarda te degeneracija sjemenika i živčanih stanica. Čini se da indometacin uzrokuje značajno oštećenje endotela i sluznice, krvarenje i vaskularnu trombozu koja prelazi u ishemičnu nekrozu s posljedičnim zatajenjem mnogih organa i uginućem. Detaljno su obrazloženi mehanizmi djelovanja indometacina kao rodenticida.

Ključne riječi: rodenticid, indometacin, patologija, patogeneza, štakor, miš
