

Chylothorax associated with lunglobe torsion in a dog - a case report

Karlapudi Satish Kumar*, and Palaniswamy Ramesh

Department of Veterinary Clinical Medicine, College of Veterinary Science, Sri Venkateswara Veterinary University, (formerly A.N.G.R. Agricultural University), Rajendranagar, Hyderabad, Andhra Pradesh, India

KUMAR, K. S., P. RAMESH: Chylothorax associated with lunglobe torsion in a dog - a case report. Vet. arhiv 77, 561-566.

ABSTRACT

A ten year old male spitz was presented to the college clinic with the signs of respiratory distress, cough, in-somnolence, frequent vomiting and anorexia. Upon clinical examination, muffled heart sounds with absence of lung sounds over the cranioventral thorax (on auscultation) and low-pitched dull sounds (on percussion) were observed, and pleural effusion was suspected. The dog collapsed during examination and the autopsy revealed the presence of an odorless, pinkish-white fluid in the thoracic cavity, along with torsion of the left cranial lung lobe. Detailed analysis of the fluid, based on the ether clearance test, identified the fluid as chyle, and the cause of the death as chylothorax associated with lung lobe torsion.

Key words: chylothorax, lung lobe, torsion, dog

Introduction

Accumulation of fluid in the pleural space (which is normally a potential space) between the visceral and the parietal pleura may result when capillary hydrostatic pressure permeability is increased, or intravascular oncotic pressure is decreased, or lymphatic drainage is impeded. The imbalance causing the accumulation of fluid determines the fluid characteristics. Chylothorax develops when chyle, fluid containing a high concentration of chylomicrons and lymph, effuses from the thoracic duct-cistern chyli system into the pleural space. Lung lobe torsion can be associated with trauma, but often the underlying cause is not identified. It may be secondary to other problems such as pleural effusion.

This is a rare condition but seen commonly in deep chested dogs, with the right middle and caudal parts of the left cranial lobes most likely to be affected (CORCORAN, 1998). Lot of work has been done on chylothorax in cats (FOSSUM, 1998) and dogs (FOSSUM et al., 1986), and there is nor shortage of relevant literature in other countries. In India, however,

*Contact address:

Dr. K. Satish Kumar, Assistant Professor, Department of Veterinary Clinical Medicine, College of Veterinary Science, Sri Venkateswara Veterinary University, (formerly A.N.G.R. Agricultural University), Rajendranagar, Hyderabad - 500 030, Andhra Pradesh, India, Phone: +91 984 8421 375; E-mail. dr_petlover@yahoo.co.in

papers on chylothorax in dogs are few and far between. This work is concentrating on the clinical, hematobiochemical and pathological findings of chylothorax in dogs.

Materials and methods

A ten year old male spitz was brought to the Teaching Veterinary Clinical Complex, College of Veterinary Science, Rajendranagar, Hyderabad, Andhra Pradesh, India, with the history of respiratory distress, cough, vomiting and inappetence. Clinical parameters such as rectal temperature, pulse and respiratory rates, were slightly higher than normal. Auscultation of lungs revealed moderate dyspnoea and moist rales. The dog was treated with parenteral amoxicillin and cloxacillin, 20 mg/kg for 5 days and dexamethasone, 0.5 mg/kg and chlorpheniramine maleate, 1 mL for the first 3 days. The clinical signs started alleviating after 2nd day of therapy, and by 5th day the dog was absolutely healthy with normal appetite and respiration.

After 60 days the same dog was again brought to the clinic with more severe tachypnoea, respiratory distress, cough and in-somnolence. The animal suffered from frequent vomiting, loss of weight, anorexia, restlessness and lack of sleep over couple of days. Clinical parameters were slightly higher. Physical examination revealed subcutaneous emphysema over thoracic cavity, muffled heart sounds and absence of lung sounds over the cranio-ventral thorax on auscultation, as well as low-pitched dull sounds on percussion. Blood sample was collected and subjected for complete blood picture (CBP) using Animal Blood Counter (Vet ABC), supplied by M/S Tech Comp Ltd., Hong Kong, and serum for biochemical analysis, using Ultraviolet visible Spectrophotometer (UV 7500), supplied by M/S Micros Analyser, France. The dog was suspected for pleural effusion and, while being prepared for radiography, it suddenly collapsed. The autopsy was carried out immediately to find out the cause of death.

Results and discussion

The CBP revealed 7.6×10^6 erythrocytes/mL, 12 g/dL hemoglobin, 42% packed cell volume, 7.4×10^3 leucocytes/mL with neutrophilia (82%), lymphopenia (10%) and normal levels of monocytes (3%) and eosinophils (5%). Biochemical analysis revealed mild hypoglycemia (49 mg/dL), hypoproteinemia (3.8 g/dL) with hypoalbuminemia (1.8 g/dL), and moderate hyperkalemia (6.2 mEq/L)

The autopsy revealed accumulation of huge amounts of (app. 1.4 L) milky, pinkish-white and odorless fluid in the thoracic cavity (Fig. 1). The fluid was left to stand in a glass tube for few hours, whereupon a cream layer formed. When the pleural fluid was subjected for cultural studies no organism of pathogenic importance was identified. Centrifugation of a sample revealed a thin red layer of sediment with complete opaque

fluid above. Analysis of pleural fluid revealed 3000 leukocytes/mL with a predominance of neutrophils (57%) and lymphocytes (36%), and 1.6×10^6 erythrocytes/mL. When the collected fluid was subjected to ether clearance test, the sample dissolved in ether and became clear. No abnormalities were detected in the heart, trachea and bronchi. However, a close examination of lung lobes revealed a torsion of the left cranial lobe. The affected lobe was atrophied and cyanotic. Based on the observation and analysis of the pleural fluid the cause was diagnosed as pleural effusion with chyle, chylothorax associated with lung lobe torsion.

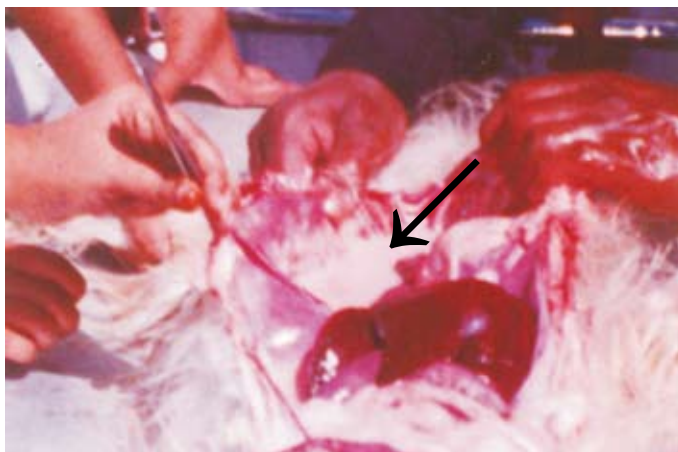


Fig. 1. Voluminous milky white fluid (chyle) in the thoracic cavity

Chylothorax, a potentially fatal accumulation of chylous fluid (lymph and chylomicrons) in the pleural cavity, is usually secondary to other conditions / diseases and can be difficult to treat (BIRCHARD and FOSSUM, 1987). Regardless of the cause, chylothorax has been associated with poor survival rates in dogs and cats (FOSSUM et al., 1986).

The formation of chyle with chylomicrons occurs in four stages in stomach and small intestines, viz., the stage of emulsification of fats, hydrolysis, micelle formation and their absorption. Chylomicrons are small, water-soluble structures with a core of hydrophobic, nonpolar lipids and an outer coat of polar lipids, which are absorbed into intestinal lymphatic, and which travel to the cisterna-chyli. The thoracic duct carries the chylomicrons from the cisterna chyli into the venous circulation for distribution to tissues (HERDT, 1992).

Chylothorax may be idiopathic in dogs, but several causes have been implicated including cardiomyopathy, thoracic and mediastinal neoplasia, heartworm disease, congenital lymphocytic defects, trauma, chronic vomiting / cough, rupture of lymphatic vessels, diaphragmatic hernia, lung lobe torsion and venous thrombi (FOSSUM et al., 1986). GELZER et al. (1997) and LORD et al (1973) reported that chylothorax is associated with accessory lung lobe torsion in dogs. There doesn't seem to be a gender predisposition for the development of chylous effusions in dogs, but trauma related, idiopathic and congenital causes of chylothorax tend to occur in younger dogs, whereas, chylothorax associated with neoplasia, heart diseases and lung lobe torsion tend to occur in older animals (FOSSUM et al., 1986). The present findings of chylothorax, which occurred in a 10 yr old dog as a result of lung lobe torsion, were in accordance with the above authors.

The most common presenting signs in dogs are dyspnoea and cough. Other clinical signs and historical findings include weight loss, anorexia, lethargy, gagging, regurgitation, vomiting, exercise intolerance and salivation. Abnormal physical findings most commonly include dyspnoea, muffled heart sounds, absence of lung sounds over the cranioventral thorax, tachycardia (FOSSUM et al., 1986). Similar clinical signs and abnormal physical findings were noticed with the present dog.

The complete blood picture revealed mature neutrophilia, which could be due to inflammation and lymphopenia from the loss of lymphocytes into chylous fluid (FOSSUM et al., 1986). The serum biochemical profile revealed mild to moderate hypoglycemia, hypoproteinemia, hypoalbuminemia and hyperkalemia, which could be attributed to anorexia, protein deficiency, therapeutic drainage of chylous effusions and hypovolemia or renal secretion defects of potassium, respectively (MEADOWS and MAC WILLIAMS, 1994). The present findings, which are in accordance with the above authors, could be attributed to the said reasons with the exception of chyle drainage, which was not the case with the present dog.

The chylous fluid was pinkish-white, odorless, free from particulate matter and it formed a cream layer when left standing in a tube, because chylomicra have a low density and reaches to surface. Upon centrifugation the sample became white. The findings of the present chylous fluid were in agreement with MEADOWS and MAC WILLIAMS (1994). Cytological analysis of pleural fluid revealed a TLC of 3000 / cmm with a predominance of neutrophils (57%) and lymphocytes (36%). Typically a predominance of small lymphocytes is considered characteristic of chylous effusion; however, neutrophilia may be associated with chronicity. The increase in neutrophil could be the result of an irritant effect of the effusion on the pleural lining (MEADOWS and MAC WILLIAMS, 1994). In the study of 19 dogs with chylothorax, neutrophils were the predominant cells in most effusions, while lymphocyte were predominant in only 2 dogs (FOSSUM et al., 1986). An

ether clearance test is a quick and highly efficacious test that may confirm the fluid as chyle (FOSSUM, 1998).

Treatment of chylothorax could be a medicinal or surgical approach, which depends on cause of the effusion. Medical therapy consists of thoracocentesis (allows palliative drainage and clinical improvement of respiratory distress), and dietary management (low fat diet to decrease the amount of lipid absorbed via intestine lymphatic). Surgical management is typically performed in cases where medicinal therapy has failed (BIRCHARD et al., 1998).

Although sufficient work was done and lot of literature exists in other countries, additional studies are needed to determine causes of idiopathic chylothorax and develop appropriate diagnostic and viable treatment options with facilities available particularly in a developing country like India.

References

- BIRCHARD, S. J., T. W. FOSSUM (1987): Chylothorax in dog and cat. *Vet. Clin. N. Am.* 17, 271-283.
- BIRCHARD, S. J., D. D. SMEAK, M. A. MC LOUGHLIN (1998): Treatment of idiopathic chylothorax in dogs and cats. *J. Am. Vet. Med. Assoc.* 212, 652-657.
- CORCORAN, B. (1998): Pleural and mediastinal diseases. In: *Canine Medicine and Therapeutics*. Neil T. Gorman. IV edn., Blackwell Sciences Inc. USA.
- FOSSUM, T. W. (1998): The characteristics and treatment of feline chylothorax. *Comp. Cont. Ed.* 914-928.
- FOSSUM, T. W., S. J. BIRCHARD, R. M. JACOBS (1986): Chylothorax in 34 dogs. *J. Am. Vet. Med. Assoc.* 188, 1315-1318.
- GELZER, A. R. M., M. O. DOWNS, S. M. NEWELL, M. B. MEHAFFEY, J. FLETCHER, K. S. LATIMER (1997): Accessory lung lobe torsion and chylothorax in an Afgan hound. *J. Am. Vet. Med. Assoc.* 33, 171-176.
- HERDT, T. (1992): Digestion and absorption of fats. In: *Textbook of Veterinary Physiology*, Cunningham, J. G. WB Saunders Company, Philadelphia, PA. pp. 322-326.
- LORD, P. F., T. P. GREINER, R. W. GREENE (1973): Lung lobe torsion in the dog. *J. Am. Anim. Hosp. Assoc.* 9, 473-482.
- MEADOWS, R. L., P. S. MAC WILLIAMS (1994): Chylous effusions revisited. *Vet. Clin. Pathol.* 23, 52-54.

Received: 13 January 2006
Accepted: 2 November 2007

KUMAR, K. S., P. RAMESH: Hiltoraks kao posljedica torzije plućnog režnja u psa - prikaz slučaja. Vet. arhiv 77, 561-566.

SAŽETAK

Na sveučilišnoj klinici zaprimljen je desetogodišnji pas pasmine špic sa znakovima poremećaja disanja, kašljem, nesvjesticom, učestalim povraćanjem i anoreksijom. Na osnovi kliničkog nalaza prigušenih srčanih tonova s odsutnošću dišnih šumova na kranioventralnom dijelu prsnog koša i muklijeg perkusijskog šuma posumnjalo se na pleuralni izljev. Pas je kolabirao tijekom pregleda, a razudbom je ustanovljena prisutnost ružičaste tekućine bez mirisa u prsnoj šupljini te torzija lijevog kranijalnog plućnog režnja. Iscrpnom pretragom temeljenom na testu klirensa etera dokazano je da je bila riječ o limfnoj tekućini te da je uzrok smrti bio hiltoraks praćen torzijom plućnog režnja.

Ključne riječi: hiltoraks, plućni režanj, pas
