

Caprine besnoitiosis in the southwest of Iran

Mohammad Mirzaie^{1*}, Amin Derakhshanfar¹, and Mehrdad Pourjafar²

¹Department of Pathobiology, School of Veterinary Medicine, Shahid Bahonar University of Kerman, Kerman, Iran

²Department of Large Animal Medicine, Faculty of Veterinary Medicine, Shahrekord University, Shahrekord, Iran

MIRZAI, M., A. DERAKHSHANFAR, M. POURJAFAR: Caprine besnoitiosis in the southwest of Iran. Vet. arhiv 77, 435-439, 2007.

ABSTRACT

Besnoitia sp. are protozoans that cause a disease affecting the skin, subcutis, blood vessels, mucus membranes, and other tissues. The *Toxoplasma gondii*-like organisms multiply in endothelial, histocytic and other cells, producing characteristic large, thick-walled cysts filled with bradyzoites. In this study, infected animals originated from the southwest area of Iran. A total of 50 head goats with characteristic sclero-conjunctival cysts of *Besnoitia* sp. were isolated for further clinical observation. No infected animals other than goats with besnoitiosis were reported in this region. Microscopic examination revealed crescent-shaped organisms with a more pointed anterior than posterior end (banana-shaped morphology) confirming that cysts belong to the genus *Besnoitia*. Experimental transmission of *Besnoitia* sp. from these patients resulted in besnoitiosis in goats but not in rabbits and mice. Therefore, *B. caprae* was accepted as the cause of the infection. It seems that factors such as the presence of thorn remnants in the eyelids, pneumonic coughing goats and a range of flies and ticks could facilitate transmission of the disease.

Key words: besnoitiosis, *Besnoitia caprae*, goat, transmission

Introduction

The genus *Besnoitia* is classified under the family *Sarcocystidae*, in the subfamily Toxoplasmatinae (JUBB et al., 1993). This genus is characterized by having cysts containing bradyzoites in fibroblasts and possibly other cells (SOULSBY, 1982). The mature cysts incite no cellular reaction (JUBB et al., 1993). Bovine besnoitiosis was first reported in 1912 in southern France. *Besnoitia caprae* is the host specific aetiological agent of the disease and ultrastructurally unique (NJENGA et al., 1999b). Caprine besnoitiosis is an economically important disease and has been reported in Kenya (NJENGA et al., 1993). Although, caprine besnoitiosis has been reported in Iran (CHEEMA and TOOFANIAN, 1979) previously, the related cysts were observed in the skin, blood vessels, epididymis

*Contact address:

Assist. Prof. Mohammad Mirzaie, Department of Pathobiology, Faculty of Veterinary Medicine, Shahid Bahonar University of Kerman, Kerman, IRAN. Postal box: 76169-133, Postal code: 7616914111, Phone: +98 341 3222047, Phone: +98 913 197 3203 Fax: +98 341 3222047, E-mail: dr_mirzaie_mo@mail.uk.ac.ir

and testes, while in this study the disease was diagnosed mainly as the sclero-conjunctival form.

Materials and methods

This investigation was carried out in Kazeroon-Fars province in southwest Iran in 2005. In this region mean annual rain fall is approximately 400 mm. A wide range of fly and tick species infest the region. Temperature varies from 5 °C to 45 °C. A total of 50 head goats with characteristic sclero-conjunctival cysts of *Besnoitia* sp. were isolated for further clinical observation. After necropsy, gross lesions were identified. Tissue samples were then obtained and embedded in paraffin wax, sectioned and stained with haematoxylin and eosin. For further confirmation, experimental transmission of *Besnoitia* sp. to apparently healthy goats, rabbits and mice was done. The laboratory animals and goats were 2 months and 1.5 - 2 years old, respectively. Approximately 1×10^8 bradyzoites, which were obtained from carcasses of chronically infected goats, were inoculated intravenously and subcutaneously into 5 healthy goats and 1×10^6 bradyzoites were inoculated intraperitoneally and subcutaneously into 5 rabbits and 5 mice obtained from the Medical University of Shiraz. Infective materials were prepared as previously described by NGANGA and KASIGAZI (1994). All animals were examined daily for the development of clinical besnoitiosis. The goats and laboratory animals were euthanized between day 60 and 120 post-inoculation. Smears were made from the peritoneal fluid, blood and buffy coat of laboratory animals, stained with Giemsa and examined microscopically.

Results

Clinical observation showed sand-like cysts as small white foci on the sclero-conjunctive, eyelid, muzzle and mucus membranes of the trachea. All patients had sclero-conjunctival cysts, while some of them showed *Besnoitia* sp. cysts on the muzzle and tracheal mucosa. The cysts were visible to the naked eye. Other body organs were free from cysts. The patients suffered from fever, dyspnea and anorexia. Purulent nasolacrimal discharge, emaciation and dull demeanour were characteristic. Mild lymphadenopathy of superficial lymph nodes of the head, neck and prescapular region was seen. Abortion and infertility were not seen and kids born of dams with besnoitiosis did not contract the infection in uterus. No infected animals other than goats with besnoitiosis were reported in this region. Cattle raised together with infected goats were free from the disease. Mortality rate was 4.8%. There was no difference in age and sex susceptibility. Remnants of thorns in the face and muzzle could be seen. Moderate infestation with ticks and flies existed. Histological evaluation revealed numerous cysts with thick fibrous capsules filled

with bradyzoites. There was no cellular reaction (Fig. 1). Further examination revealed crescent-shaped organisms with a more pointed anterior than posterior end (banana-shaped morphology) confirming that cysts belong to the genus *Besnoitia*. Experimental transmission of *Besnoitia* sp. resulted in besnoitiosis in 5 of 5 goats. Sclero-conjunctival cysts were diagnosed 35 days post-inoculation in goats and confirmed on histological evaluation. None of the rabbits and mice showed signs of the disease. All laboratory animals had good body condition. The blood, buffy coat and peritoneal fluid smears of laboratory animals did not contain any bradyzoites.

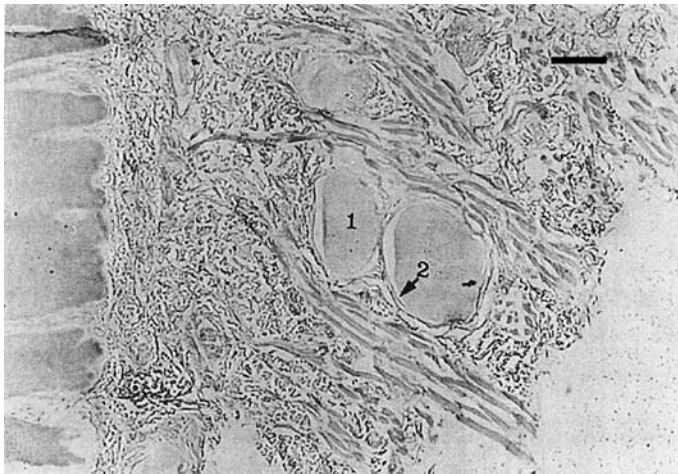


Fig. 1. *B. caprae* cysts in dermis. Cyst filled with bradyzoites (1) and fibrous component of the wall (2). H&E; scale bar = 300 μ m.

Discussion

Caprine besnoitiosis has been reported in Iran by CHEEMA and TOOFANIAN (1979). Their observation revealed *Besnoitia* sp. cysts in the skin, blood vessels, epididymis and testes. The present study places special emphasis on ocular besnoitiosis, with some involvement of muzzle and tracheal mucosa. Experimental transmission of *Besnoitia* sp. succeeded only in goats, but not in rabbits and mice. In addition, the disease was not seen in other animals, especially cattle which co-pastured with these goats. *B. caprae* was therefore accepted as the aetiological agent of the disease. NJENGA et al. (1993) and NGANGA and KASIGAZI (1994) have reported similar results. The results of this investigation confirm previous findings by NJAGI et al. (1998) which stated that visual examination for the presence of sclero-conjunctival cysts is reliable. However, SANNUSI (1991) suggested a simple field diagnostic smear test for bovine besnoitiosis. Previous

studies have investigated the possible modes of transmission of *B. caprae* in goats. NJENGA et al. (1999a) believed that the presence of thorn remnants in the eyelids might play a role in the mechanical transmission of *B. caprae*. He suggested that the presence of many pneumonic coughing goats could facilitate transmission through inhalation. NJAGI et al. (1998) showed that the presence of a range of flies and ticks on the ranch presents optimum condition for mechanical transmission. In this investigation all three above mentioned factors were observed. NJENGA et al. (1999a) believed that abortion and infertility are possible consequences of besnoitiosis. These researchers showed the absence of *Besnoitia* sp. cysts in histological preparations of tissues of the uterus, placenta, fetuses and kids. In the present study, abortion, infertility and the presence of *Besnoitia* sp. cysts in the reproductive system were not seen, and kids of infected animals were apparently healthy. However, NJENGA et al. (1999c) observed changes in semen of infected goats which was considered to be severe enough to account for the infertility in the flock. It seems that further studies are necessary to shed light on caprine besnoitiosis and its economic importance in domestic animals in Iran.

Acknowledgements

The authors gratefully acknowledge the assistance of Mr. M. Azangoo in the preparation of tissue slides.

References

- CHEEMA, A. H., F. TOOFANIAN (1979): Besnoitiosis in wild and domestic goats in Iran. *Cornell Vet.* 69, 159-168.
- JUBB, K. V. F., P. C. KENNEDY, N. PALMER (1993): *Pathology of domestic animals*, 4th ed., Vol. I, Academic Press, Inc.
- NGANGA, C. J., S. KASIGAZI (1994): Caprine besnoitiosis: studies on the experimental intermediate hosts and the role of the domestic cat in transmission. *Vet. Parasitol.* 52, 207-210.
- NJAGI, O. N., C. M. NDARATHI, P. N. NYAGA, L. K. MUNGA (1998): An epidemic of besnoitiosis in cattle in Kenya. *Onderstepoort J. Vet. Res.* 65, 133-136.
- NJENGA, M. J., O. BWANGAMOI, E. R. MUTIGA, E. K. KANGETHE, G. M. MUGERA (1993): Preliminary findings from an experimental study of caprine besnoitiosis in Kenya. *Vet. Res. Commun.* 17, 203-208.
- NJENGA, M. J., E. K. KANGETHE, O. BWANGAMOI, S. J. M. MUNYUA, G. M. MUGERA, E. R. MUTIGA (1999a): Experimental transmission of *Besnoitia caprae* in goats. *J. S. Afr. Vet. Assoc.* 70, 161-163.
- NJENGA, M. J., S. J. M. MUNYUA, O. BWANGAMOI, E. K. KANGETHE, G. M. MUGERA, E. R. MUTIGA, J. P. O. WAMUKOYA (1999b): Prevalence of besnoitiosis in domestic ruminants in Kenya: a preliminary survey. *J. S. Afr. Vet. Assoc.* 70, 151-153.

- NJENGA, M. J., S. J. M. MUNYUA, E. R. MUTIGA, J. M. GATHUMA, E. K. KANGETHE, O. BWANGAMOI, G. M. MUGERA (1999c): Semen characteristic of goats with subacute, acute and chronic besnoitiosis. *J. S. Afr. Vet. Assoc.* 70, 18-20.
- SANNUSI, A. (1991): A simple field diagnostic smear test for bovine besnoitiosis. *Vet. Parasitol.* 39, 185-188.
- SOULSBY, E. J. L. (1982): *Helminths, arthropods and protozoa of domesticated animals*, 7th ed., Bailliere Tindal. London. pp. 686-687.

Received: 25 October 2006

Accepted: 28 September 2007

MIRZAIE, M., A. DERAKHSHANFAR, M. POURJAFAR: Kozja beznoitioza u jugozapadnom Iranu. *Vet. arhiv* 77, 435-439, 2007.

SAŽETAK

Vrste roda *Besnoitia* su praživotinje koje uzrokuju promjene na koži, potkožju, krvnim žilama, sluznicama i drugim tkivima. Te praživotinje po mnogo čemu podsjećaju na mnogo učestaliju praživotinju *Toxoplasma gondii*. Umnožavaju se u endotelnim stanicama, histiocitima i drugim stanicama tvoreći karakteristične ciste omeđene debelom ovojnicom, ispunjene bradizoitima. U ovom istraživanju invadirane životinje potjecale su iz jugozapadnog dijela Irana. Ukupno je za daljnja istraživanja izdvojeno 50 koza s karakterističnim sklerokonjuktivalnim cistama. Ni u jedne druge vrste nisu zabilježeni znakovi ove bolesti. Mikroskopskom pretragom dokazani su vretenasti organizmi karakteristične građe što je ujedno potvrdilo da je riječ o pojavi beznoitioze. Pokusna beznoitioza izazvana je u koza, ali ne u kunića i miševa te se smatra da je vrsta *B. caprae* uzrokovala invaziju. Čini se da čimbenici poput ostataka trnja u vjedama, bolesti dišnog sustava kao i prisutnost dvokrilaca i krpelja, mogu biti pogodovni za prijenos uzročnika.

Ključne riječi: beznoitioza, *Besnoitia caprae*, koza, prijenos
