

Internal fixation of a femoral fracture in a green iguana developing metabolic bone disease - a case report

**Dražen Matičić^{1*}, Marko Stejskal¹, Dražen Vnuk¹, Damir Stanin²,
Tomislav Babić¹, and Marko Pećin¹**

¹*Clinic for Surgery, Orthopedics and Ophthalmology, Faculty of Veterinary Medicine, University of Zagreb, Croatia*

²*Department of Radiology, Ultrasound Diagnostics and Physical Therapy, Faculty of Veterinary Medicine, University of Zagreb, Croatia*

MATIČIĆ, D., M. STEJSKAL, D. VNUK, D. STANIN, T. BABIĆ, M. PEĆIN: Internal fixation of a femoral fracture in a green iguana developing metabolic bone disease - a case report. Vet. arhiv 77, 81-86, 2007.

ABSTRACT

One case of a right femoral bone fracture repair by intramedullary pin fixation in a green iguana is described. A fracture of the right femur was diagnosed as a result of trauma. Open reduction with intramedullary pin fixation was used for the fracture repair. The progress of healing had been monitored clinically and radiographically over a four-month period. Two months postoperatively, functional deterioration was noticed and signs of metabolic bone disease had been recognized. The calcium and phosphorus ratio in the blood biochemistry results confirmed the disease. For the successful outcome of the fracture healing process in a green iguana, the full engagement of both veterinarian and owner is crucial.

Key words: femoral fracture, pin fixation, green iguana, metabolic bone disease

Introduction

Green iguanas are relatively new and rare pets in Croatia. However, the demand for veterinary services to that specific species is growing. Their owners experience various problems, including those of an orthopaedic nature. Long bone fractures in reptiles are usually the result of trauma or metabolic bone disease (MBD) (MARCUS, 1981). Pathologic fractures secondary to the MBD are amenable to treatment using external coaptation together with calcium imbalance correction, whereas in other situations internal fixation

*Contact address:

Asist. Prof. Dr. Dražen Matičić, Clinic for Surgery, Orthopedics and Ophthalmology, Faculty of Veterinary Medicine, University of Zagreb, Heinzelova 55, 10000 Zagreb, Croatia, Phone: +385 1 2390 384; Fax: +385 1 2390 380; E-mail: drmaticic@vef.hr

is indicated (BENNETT, 1996). Intramedullary Steinmann pins and orthopaedic wires are inexpensive, provide axial alignment and bending stability, and require minimal tissue exposure for insertion. Kirschner wires may be used as intramedullary pins. Coaptation with splinting of the legs to the body is often used in lizards, together with intramedullary pins to provide additional stability. In reptiles, bones heal over a period of months, as opposed to weeks in mammals (GILLESPIE, 1994). It is essential to monitor the progress of healing by x-rays. Diet analysis, with adequate calcium intake, can ensure proper healing. However, ignoring the calcium to phosphorus ratio for only a short length of time can cause MBD.

The objective of this case report is to describe all aspects of open reduction with intramedullary pinning as a method in iguana, as well as the process of fracture healing in iguana developing MBD.

Materials and methods

A six-month-old green iguana weighing 100g was presented with a dysfunctional right hind leg a day after it fell from its owner's hands. During clinical orthopaedic examination, abnormal mobility in the right femoral region was determined with suspected fracture of the right femur. Radiographs confirmed the clinical diagnosis: on a lateral view of the right femur an oblique fracture was found in the diaphyseal middle third (Fig. 1). The distal fragment was dislocated cranially and contracted proximally for about 10 mm. Diagnosis: Fractura ossis femoris dextri. With the owner's compliance the decision was made for the patient to undergo orthopaedic surgery, i.e. open reduction and fixation of the fractured femur. Prior to surgery a blood sample (0.5 mL) was collected from the ventral tail vein. Calcium and phosphorus plasma levels were within the normal range: Ca = 2.4 mmol·L⁻¹, P = 1.9 mmol·L⁻¹ (determined by Olympus AU 600 analyzer), with a calcium to phosphorus ratio of 1.26:1.

Surgery was performed under general inhalational anaesthesia induced with ketamine hydrochloride ("Narketan 10", Vétouinol, Bern, Switzerland) 15 mg/kg i/m and maintained with isoflurane (Forane, Abbott laboratories Ltd, Queenborough, UK) 2.5% in O₂ with an oxygen flow rate of 6 L/min, delivered via face mask, in a non-rebreathing system (Mapleson D) and with an average spontaneous respiratory rate of four breaths per minute. Additional analgesia was provided with flunixin meglumine ("Finadyne RP", Essex Tierarznei, Munich, Germany) 1 mg/kg i/m. The patient was administered a single dose of enrofloxacin ("Vetoflok 5%", Veterina d.o.o., Kalinovica, Croatia) 10 mg/kg i/m preoperatively. The patient was placed on a heating pad and the operating field was aseptically prepared for surgery.

After a lateral approach to the femur, a 1.00 mm Kirschner wire was retrogradely introduced into the proximal fragment of the femur, and after reposition of the fragments advanced distally until optimal stability of the fragments was achieved. The fascia was sutured with Vicryl (Ethicon, Norderstedt, Germany) 4-0 in a simple continuous pattern, and skin closure was done using Prolene (Ethicon, Norderstedt, Germany) 4-0 in an interrupted horizontal mattress fashion. Righting reflex was observed 1 hour after surgery. The control radiographs showed proper reposition via the intramedullary pin. Caudally, at the level of the fracture line, one smaller bone fragment, 4 × 2 mm, was observed (Fig. 2). For additional stability, coaptation of the leg to the tail of the patient during the first two weeks postoperatively was used. Skin sutures were removed 6 weeks after surgery.

Results

Healing progress was monitored clinically and periodically by X-rays. The first radiograph was taken immediately after surgery, followed by four evaluations scheduled on a monthly basis. Clinical monitoring consisted of periodical check-up examinations at seven-day intervals. One month after surgery the bone was stable and the function of the leg was slowly recovering, but had not yet achieved normal function. Control radiographs showed that the bone fragments remained in the correct position, but not even minimal signs of the bone callus could be seen.

Two months postoperatively, functional deterioration was noticed both by the owner and clinically. The patient no longer used leg, but dragged it behind. Radiographs showed the preserved primary bone shape, with thinning of compacta and corticalis and widened medullary canal (Fig. 3). Those radiographic characteristics revealed a less pronounced bone macrostructure, which caused secondary multifragmentary fracture of the femur. The

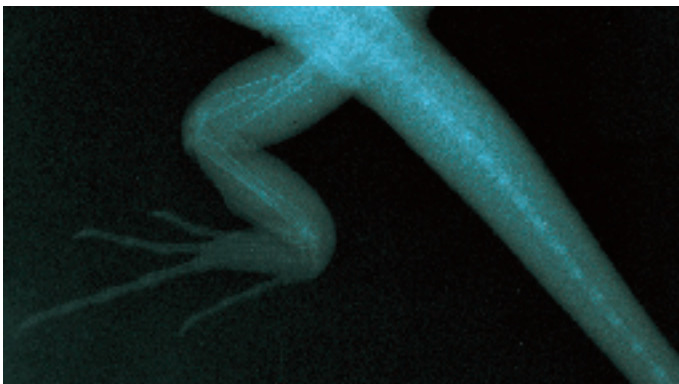


Fig. 1. Oblique diaphyseal femoral fracture

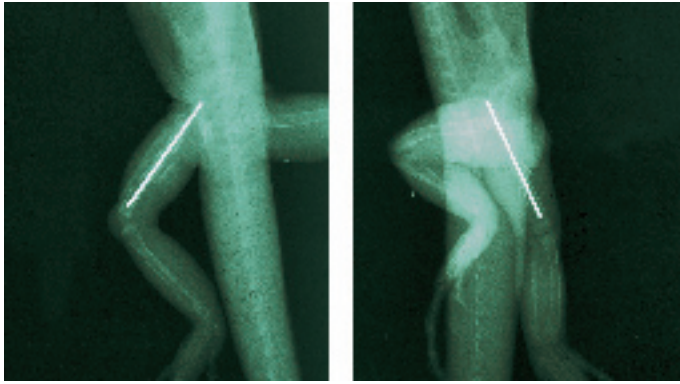


Fig. 2. Postoperative control radiographs, the day of surgery




Fig. 3. Control radiographs, two months postoperatively

intramedullary pin was still in position. Calcium and phosphorus plasma levels changed: $\text{Ca} = 2.0 \text{ mmol}\cdot\text{L}^{-1}$, $\text{P} = 4.9 \text{ mmol}\cdot\text{L}^{-1}$ (determined by Olympus AU 600 analyzer), with the inverse Ca:P ratio 1:2.45 being strong evidence of MBD. According to the owner, the patient's diet consisted mostly of lamb's lettuce, carrots, chicken and pastry, all low in calcium while at the same time with an inappropriate calcium to phosphorus ratio. The owner was advised to supplement the patient's diet with calcium and vitamin D. Four months after surgery, because of symptoms of advanced-stage MBD, the left fore-leg was x-rayed. The macrostructure of humerus, radius and ulna had evidently lessened shade intensity, with very thin compacta and corticalis and widened medullary canal. The patient's overall condition was deteriorating rapidly, culminating in constipation and death within two weeks.

Discussion

According to BENNETT (1996), pathologic fractures secondary to MBD are amenable to treatment using external coaptation together with calcium imbalance correction, whereas in other situations internal fixation is indicated. In our case, surgical treatment of the fracture was chosen because no evidence of MBD was present at that time. Calcium and phosphorus plasma levels were within normal limits, their ratio not ideal but still within an acceptable range. The goal of the open reduction was to shorten total recovery time and to provide better leg function. The applied anaesthetic protocol, parenteral induction with inhalation maintenance, was the protocol of choice because it enabled better control of anaesthetic depth and faster recovery, compared to solely injectable agents. Although information about the uses and effects of analgesic agents in reptilian medicine is scant, routine administration of analgesics to any reptile that undergoes invasive or painful surgery is recommended (SCHUMACHER, 1996). Non-steroidal anti-inflammatory drugs seem to be the most appropriate postoperative analgesics (BENNETT, 1996). In our case, we chose flunixin meglumine. By observing the patient, we assessed the analgesia as satisfactory, but one must consider the difficulties of pain recognition and evaluation in a reptile patient. Analgesia in reptiles is still a field with many question marks.

Intramedullary pinning was our method of choice because of its technical simplicity and at the same time its efficiency in achieving stability in such a small patient.

Regardless of the relative success of the surgical procedure and the promising findings over the first two months postoperatively, we qualify this case as one of failure.

For the successful outcome of the fracture healing process in a green iguana, the full engagement of both veterinarian and owner is crucial. All and any medical efforts will fail to correct MBD if husbandry, especially diet, is not improved (BOYER, 1996). This was the first open reduction on a green iguana in Croatia.

References

- BENNETT, R. A. (1996): Fracture Management. In: Reptile Medicine and Surgery. (Mader D. R., Ed.). W. B. Saunders Company. Philadelphia, London, New York, St. Louis, Sydney, Toronto. pp. 281-287.
- BOYER, T. H. (1996): Metabolic Bone Disease. In: Reptile Medicine and Surgery. (Mader D. R., Ed.). W. B. Saunders Company. Philadelphia, London, New York, St. Louis, Sydney, Toronto. pp. 385-392.
- GILLESPIE, D. (1994): Reptiles. In: Saunders Manual of Small Animal Practice, 1st ed. (Birchard S. J., R. G. Sherding, Eds.). W. B. Saunders Company. Philadelphia, London, Toronto, Montreal, Sydney, Tokyo. pp. 1390-1411.
- MARCUS, L. C. (1981): Veterinary Biology and Medicine of Captive Amphibians and Reptiles. Lea & Febiger. Philadelphia. pp. 77-79.

D. Matičić et al.: Internal fixation of a femoral fracture in a green iguana developing metabolic bone disease
- a case report

SCHUMACHER, J. (1996): Reptiles and Amphibians. In: Lumb & Jones' Veterinary Anesthesia, 3rd ed. (Thurmon, J. C., W. J., Tranquilli, G. J., Benson, Eds.). Lippincott Williams & Wilkins. Philadelphia, Baltimore, New York, London, Buenos Aires, Hong Kong, Sydney, Tokyo. pp. 670-685.

Received: 8 November 2005

Accepted: 21 December 2006

MATIČIĆ, D., M. STEJSKAL, D. VNUK, D. STANIN, T. BABIĆ, M. PEĆIN:
Unutarnje učvršćivanje prijeloma bedrene kosti u zelene iguane s razvijenom
metaboličnom bolešću kostiju - prikaz slučaja. Vet. arhiv 77, 81-86, 2007.

SAŽETAK

U radu se opisuje slučaj operacijskog liječenja loma desne bedrene kosti intramedularnom iglom u iguane. Kao posljedica traume utvrđen je prijelom desne bedrene kosti. Za repoziciju i učvršćenje koštanih ulomaka primijenjena je intramedularna igla. Cijeljenje kostiju klinički i rengenološki praćeno je u razdoblju od četiri mjeseca. Dva mjeseca nakon operacije opaža se nazadovanje u funkciji operiranoga uda te se uočavaju znaci metabolične bolesti kostiju. Omjer kalcija i fosfora u rezultatima biokemijske pretrage krvi potvrdio je bolest. Za uspješan ishod procesa cijeljenja loma kosti u iguane, nužna je predanost i veterinaru i vlasniku pacijenta.

Cljučne riječi: bedrena kost, lom, operacijsko lijećenje, iguana, metabolična bolest kostiju
