

Postweaning multisystemic wasting syndrome in wild boar (*Sus scrofa*) in Croatia

Zoran Lipej^{1*}, Joaquim Segalés², Dinko Novosel¹, Besi Roić¹,
and Luka Manojlović³

¹Croatian Veterinary Institute, Zagreb, Croatia

²Animal Health Research Centre (CReSA), Department of Animal Health and Anatomy, Veterinary Faculty, Autonomous University of Barcelona, Barcelona, Spain

³Hunting estate Moslavina, Zagreb, Croatia

LIPEJ, Z., J. SEGALÉS, D. NOVOSEL, B. ROIĆ, L. MANOJLOVIĆ: Postweaning multisystemic wasting syndrome in wild boar (*Sus scrofa*) in Croatia. Vet. arhiv 76, S41-S50, 2006.

ABSTRACT

This paper describes the first cases of porcine circovirus type 2 (PCV2) infections in four wild boars in Croatia associated with morphological lesions, which are regarded as characteristic for postweaning multisystemic wasting syndrome (PMWS) in domestic pigs. During the winter 2005 several wild young piglets, approximately 2 to 5 months of age were found dead in a fenced hunting area. Fulfilling the all three key criteria: the presence of compatible clinical signs of wasting, the presence of the characteristic microscopic lymphoid lesions, and the detection of PCV2 within the lesions by in situ hybridisation (ISH); PMWS was diagnosed. This is the first demonstration of PMWS in wild boar in Croatia based on all scientifically accepted diagnostic criteria.

Key words: postweaning multisystemic wasting syndrome (PMWS), wild boar, *Sus scrofa*, pathology, porcine circovirus type 2, Croatia

Introduction

A new and unusual disease syndrome of six- to twelve-week-old weaned and growing pigs was for the first time identified in Canada in 1996. Drs. John Harding and Edward G. Clark are credited for the first report on a new disease entity termed Postweaning Multisystemic Wasting Syndrome (PMWS) (HARDING, 1996; CLARK, 1997). The porcine

* Contact address:

Dr. Zoran Lipej, Pathology Department, Croatian Veterinary Institute, Savska cesta 143, 10000 Zagreb, Croatia, Phone: +385-1-6123-606; Fax: +385-1-6190-841; E-mail: lipej@veinst.hr

circovirus type 2 (PCV2) is considered as the causative agent of this global, emerging disease in domestic pigs. During the foregoing decade PMWS was reported worldwide on every continent except Oceania (SEGALÉS and DOMINGO, 2002). In Croatia the first finding of PMWS on several pig producing farms was reported by LIPEJ et al. (2003). The syndrome has also been reported in countries neighbouring Croatia, such as Slovenia (TOPLAK et al., 2002), Hungary (KISS et al., 2000), Austria (SCHMOLL et al., 2002), and Italy (MARTELLI et al., 2000). For the clinical suspicion of PMWS an individual expression of the disease is important with a variety of signs of wasting, unthriftiness, paleness of the skin, palpable lymphadenopathy, respiratory and digestive distress, and occasionally, jaundice (HARDING and CLARK, 1997; SEGALÉS et al., 1997). At necropsy, the most obvious lesions include marked enlargement of particular/or all lymph nodes, rubbery and non-collapsed lungs with interlobular oedema, and large intestinal and mesenteric oedema (ROSELL et al., 1999). The most striking microscopic findings are lymphocyte depletion with histiocytic and/or multinucleate giant cell infiltration, basophilic intracytoplasmic inclusions and lymphohistiocytic interstitial pneumonia (ROSELL et al., 1999). It is well known that PCV2 is a ubiquitous virus present in both PMWS affected and non-affected animals (ROSE et al., 2002). Because not all pigs with clinical symptoms of wasting suffer from PMWS, the establishment of a final diagnosis of PMWS has to be based on all three criteria as suggested by SEGALÉS et al. (2003).

The serological analyses have shown that not only the domestic swine but also the wild boar (*Sus scrofa*) are susceptible to the circoviral infection (SANCHEZ et al., 2001; SEGALÉS et al., 2002). The first described cases of PMWS in four European wild boars (*Sus scrofa*) were reported in Spain (SEGALÉS et al., 2003) and Germany (SCHULTZE et al., 2003). In the North American continent PMWS was first identified in a group of free-ranging Eurasian wild boar (ELLIS et al., 2003).

The aim of this study was to contribute the investigation into the PCV2 infection in the wild boar population in Croatia after PMWS in domestic pigs has been previously confirmed (LIPEJ et al., 2005).

Materials and methods

During the winter season 2005 eight wild boars were found dead in a fenced hunting area. Six of eight animals were approximately at age of 2 months, while other two were approximately 5 months old. The hunting area is located in the continental part of Croatia (in the Sisačko-Moslavačka region). The localities have a territorial area of 600 ha with a density of approximately 50 reproductive wild sows. The fenced hunting area has half-intensively managed estates: vaccination of sows against classical swine fever, sanitary management due to oral administration of parasiticides (ivermectin) in feed and artificial

feeding. There are no commercial pig farms in close proximity to the hunting area.

A complete autopsy of each animal was performed at the Pathology Department of the Croatian Veterinary Institute. The samples of different organs were taken from all animals for microbiological (bacteriological and virological), histopathological and parasitological examinations.

Formalin-fixed samples of the lymph nodes, lungs, and spleen of eight wild boar piglets were dehydrated, embedded in paraffin wax, sectioned at 4 mm, and stained with haematoxylin and eosin (HE), following the protocol described by ROSELL et al. (1999).

An in situ hybridization (ISH) technique to detect the PCV2 nucleic acid was carried out on the formalin-fixed and paraffin-embedded tissues of the lymph nodes according to the previously published protocols (ROSELL et al., 1999).

The samples of spleen, lungs, liver and intestines of all piglets were studied bacteriologically. Tissues were cultured on several different media under both aerobic and microaerophilic conditions. After 48 hours of incubation at 37 °C isolated colonies were taken for biochemical identification.

Parasitological examinations of the lungs, intestines (small and large) and skin were carried out by routine methods.

Virological examinations of the spleen for detection of classical swine fever virus were performed by an immunoassay test (ELISA) with commercially available kit (CHEKIT-CFS-VIRUS-III, Dr Bommeli AG, Switzerland).

Results

From the epizootiological point, the PMWS issue started during winter time with unexpected mortality among wild piglets in the fenced hunting conditions. Although the exact number of dead wild piglets could not be established, based on the finding of carcass remains (mostly bones) left after predators, an approximate 20% mortality rate could be supposed. The clinical signs observed in majority of affected animals included mainly wasting and diarrhoea with diffuse cyanosis of the skin in several cases.

Pathological and ISH findings. The most frequent gross finding in majority of carcasses was emaciation (Fig. 1), splenomegaly, generalised lymphadenopathy (Fig. 2) and catarrhall/suppurative bronchopneumonia involving the cranial lung lobes (Fig. 3). In the same time ventral lung lobes of several animals had the lesions indicative for parasitic pneumonia due to the lungworms. Some of them had a diffuse erythema of the skin accompanied with petechial haemorrhages on the kidney cortex. Microscopic lesions of the lymphoid tissues (spleen and lymph nodes) observed in four of eight

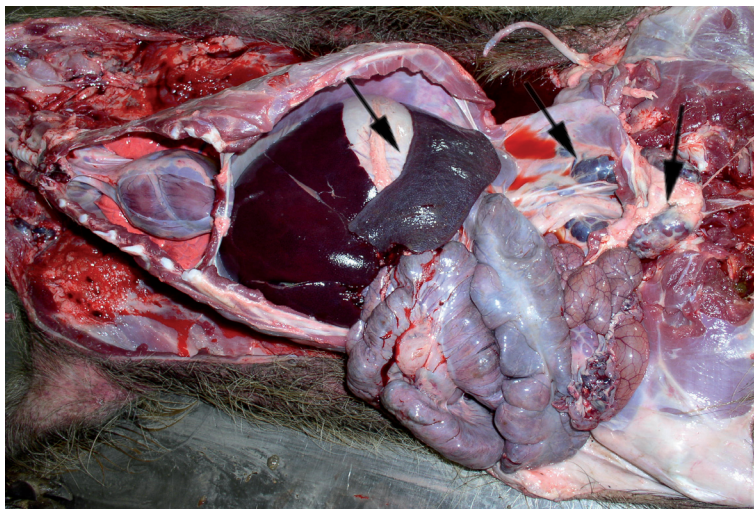


Fig. 1. Open chest and abdominal cavity of the wild boar: presence of splenomegaly and lymphadenopathy of inguinal lymph nodes

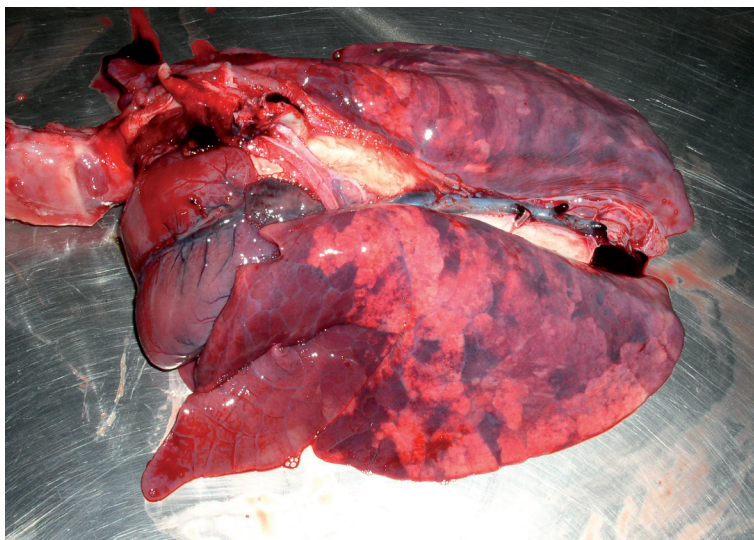


Fig. 2. Lungs of wild boar piglet with pronounced bronchopneumonia.

carcasses (No. 3, 5, 7 and 8) included a slight to moderate lymphocyte depletion and histiocytic infiltration (Fig. 4), as well as the presence of multinucleated giant cells in the wild boar No. 3 (Fig. 5). The remaining four animals had no apparent microscopic lesions on lymphoid tissues.

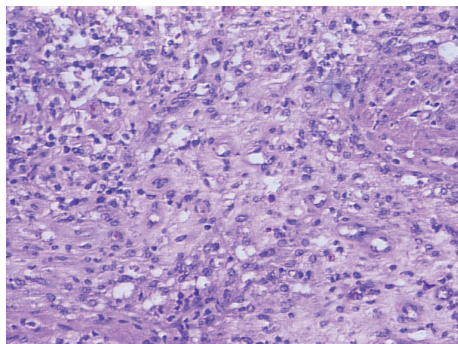


Fig. 3. Superficial inguinal lymph node with depletion of lymphocytes. H&E x 100.

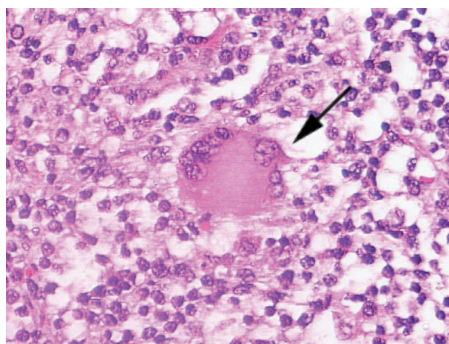


Fig. 4. Lymph node of wild piglet: depletion of lymphoid cells, with histiocytic infiltration and presence of a multinucleated giant cell (arrow). H&E. x 100.

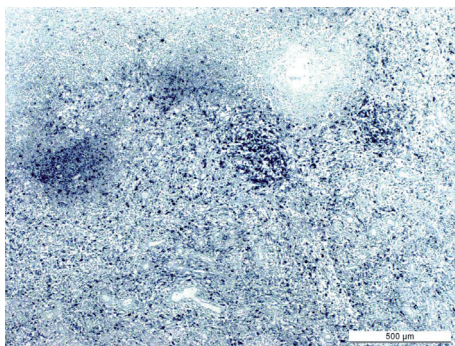


Fig. 5. Lymph node of PMWS affected wild piglet. Presence of PCV2 nucleic acid in whole lymph node parenchyma. In situ hybridization technique with fast green counterstain. Bar = 500 µm.

The PCV2 genome detected by ISH was present in 4 of eight wild piglets examined (Table 1). In lymph nodes from three wild boars (Nos. 2, 5 and 8), the presence of a small amount (+) of PCV2 nucleic acid was mainly detected in the cytoplasm of the

Table 1. Summary of clinical data, gross pathological findings, histopathological lesions of lymphoid tissues and results of ISH test in the 8 necropsied wild boars

No./age* of animals	Clinical data and gross pathological findings	Histopathological findings of lymphoid tissues	Bacteriological findings	ISH results
1/2	Emaciation, mange, lymphadenopathy, splenomegaly, bronchopneumonia	No apparent lesions	<i>S. choleraesuis</i>	Negative (-)
2/2	Emaciation, bronchopneumonia, splenomegaly, multifocal liver necrosis	No apparent lesions	<i>S. choleraesuis</i> + <i>P. multocida</i>	Positive (+)
3/2	Emaciation, lymphadenopathy, non-collapsed, rubbery lungs with interlobular oedema and haemorrhages, catarrhal enterocolitis	Moderate lymphocyte depletion, slight to moderate histiocytic infiltration, presence of multinucleate giant cells	Negative	Positive (++)
4/2	Emaciation, bronchopneumonia	No apparent lesions	<i>S. choleraesuis</i>	Negative (-)
5/2	Emaciation, lymphadenopathy, splenomegaly, petechial haemorrhages on the kidney cortex	Slight to moderate lymphocyte depletion with slight histiocytic infiltration	<i>S. choleraesuis</i>	Positive (+)
6/2	Emaciation, mange, lymphadenopathy, splenomegaly, bronchopneumonia	No apparent lesions	<i>S. choleraesuis</i>	Negative (-)
7/5	Erythema of the skin, splenomegaly, bronchopneumonia, petechial haemorrhages on the kidney cortex	Moderate lymphocyte depletion with slight histiocytic infiltration	<i>S. choleraesuis</i>	Negative (-)
8/5	Emaciation, bronchopneumonia, petechial haemorrhages on the kidney cortex	Slight lymphocyte depletion	<i>S. choleraesuis</i>	Positive (+)

Results of the ISH technique were expressed in a semi-quantitative fashion based on the amount of viral genome: - absence; + slight amount; ++ moderate amount; +++ high amount

macrophages and follicular dendritic cells. A moderate amount (++) of PCV2 nucleic acid in the follicular and interfollicular areas and occasionally in the nuclei of macrophages were present in the wild boar No. 3 (Fig. 6). The pathomorphological findings and ISH results of all necropsied wild pigs are shown in Table 1.

Microbiological and parasitological findings. A pathogenic bacteria *Salmonella choleraesuis* was isolated from different organs (liver, spleen, lungs) in six of 8 examined animals (No. 1, 4, 5, 6, 7 and 8). In only one case *Salmonella choleraesuis* together with *Pasteurella multocida* were isolated from the lungs of one animal (No. 2). The same organs (liver, spleen and lungs) in only one animal (No. 3) were bacteriologically negative.

Virological examinations of the spleen for detection of classical swine fever virus in all eight animals were negative.

Parasitological analysis revealed the presence of parasites in all observed animals. The lungs from 4 (No. 1, 2, 4, and 6) of eight animals were affected with a moderate to high amount of lungworm *Metastrongylus apri*. A variable degree from slight to moderate infestation with intestine nematodes (*Ascaris suum*, *Trichuris suis*) and coccidian oocysts was found in almost all examined intestines.

The skin of the animals (No. 1 and 6) was highly affected with *Sarcoptes scabiei* var. *suis*.

Discussion

The present paper is the first report demonstrating the PMWS in Croatia in four wild boar piglets based on all three scientifically accepted diagnostic criteria (SEGALÉS, 2002). The first key criteria met here was a clinical picture of wasting, diarrhoea and bronchopneumonia observed in affected wild piglets 2 to 5 months of age. Other compatible clinical signs of the PMWS observed in domestic pigs such as skin paleness, enlargement of the lymph nodes and respiratory distress could not be eliminated. The main problem for a detailed clinical survey of young piglets is related to impossibility to catch them during the suckling period. The second fulfilled criterion was to find the typical lesions in the lymphoid tissues (spleen and lymph nodes) characterised by lymphocyte depletion, histiocytic infiltration and the presence of multinucleated giant cells. A third and the most important finding, which confirm our statement that PMWS is present in wild boar from Croatia is detection of the PCV2 genome in typical lymphoid lesions by in situ hybridization. Although the results presented here showed that 4 of 8 animals had positive ISH results for the PCV2 genome, only one pig (No. 3) had a sufficient amount of viral genome and severe lesions compatible with a PMWS. The other three animals had a low amount of PCV2 nucleic acid, which is compatible with a sub-clinical viral infection.

It cannot be ruled out that this situation is also compatible to convalescent form of PMWS with recovering of lymphoid tissues (SEGALÉS, 2002).

Our findings are in complete agreement with previous literature data concerning PMWS in European (SEGALÉS et al., 2003; SCHULTZE et al., 2003) and Eurasian wild boar (ELLIS et al., 2003).

Bacteriological analysis revealed that majority of animals examined in this study, as well as animals from the previous studies by SEGALÉS et al. (2003) and SCHULTZE et al. (2003) had a *Salmonella choleraesuis* infection. It is well known that non-specific activation of the immune system and concurrent viral or bacterial infection can trigger or worsen the PMWS presentation (SEGALÉS and DOMINGO, 2002). Therefore, the hypothesis that bacterial infection with *Salmonella choleraesuis* is a possible co-factor of PMWS in wild boars could not be eliminated.

Although results of our investigations irrefutable confirm the existence of PMWS in the wild boar population in the Republic of Croatia, further studies on larger sample are encouraged. Consequentially, the potential importance of this disease in wild boar piglets could not be evaluated, because in spite of unexpected piglet mortality, the number of wild boar population has not drastically decreased. Our study highlights the need to include the epizootiological and particularly serological surveys on the presence of PCV2 antibodies in the wild boar population from different parts of Croatia.

To improve our knowledge on PCV2 infection and determine the role of this disease in the wild boar population, future investigations should pay attention to the numerous piglet age- classes and a prompt retrieval of the carcasses as suggested by VINCENTE et al. (2004).

References

- CLARK, E. (1997): Post-weaning multisystemic wasting syndrome. Proceedings of the American Association of Swine Practitioners 28, 499-501.
- ELLIS, J., M. SPINATO, C. YOUNG, K. WEST, F. MCNILLY, B. MEEHAN, S. KENNEDY, E. CLARK, S. KRAKOWKA, G. ALLAN (2003): Porcine circovirus 2-associated disease in Eurasian wild boar. J. Vet. Diagn. Invest. 15, 364-368.
- HARDING, J. C. (1996): Post-weaning multisystemic wasting syndrome: preliminary epidemiology and clinical findings. Proc. W. Can. Assoc. Swine Pract. p. 21.
- HARDING, J. C. S., E. G. CLARK (1997): Recognizing and diagnosing postweaning multisystemic wasting syndrome (PMWS). Swine Health and Production, 201-203.
- KISS, I., S. KECSKEMETI, T. TUBOLY, E. BAYJMOCY, J. TANYI (2000): New pig disease in Hungary: postweaning multisystemic wasting syndrome caused by circovirus (short communications). Acta Vet. Hung. 48, 469-473.

- LIPEJ, Z., I. TOPLAK, B. ŠOŠTARIĆ, K. ŽARKOVIĆ, LJ. ŠKRINJAR (2003): Demonstration of porcine circovirus infection in pigs with postweaning multisystemic wasting syndrome (PMWS) in Croatia. Proceedings of the 4th International symposium on emerging and re-emerging pig diseases, Rome, June 29th – July 2nd, pp. 228-229.
- LIPEJ, Z., J. SEGALÉS, I. TOPLAK, B. ŠOŠTARIĆ, B. ROIĆ, M. LOJKIĆ, P. HOSTNIK, J. GROM, D. BARLIĆ-MAGANJA, K. ŽARKOVIĆ, D. ORAIĆ (2005): Postweaning multisystemic wasting syndrome (PMWS) in pigs in Croatia: PCV2 detection and characterization. Acta Vet. Hung. 53, 385-396.
- MARTELLI, P., M. TERRENI, N. AMENNA, H. MORVAN, S. CAVIRANI (2000): Involvement of PCV2 in an outbreak of postweaning multisystemic wasting syndrome (PMWS) in Italy. The 16th International Pig Veterinary Society Congress, Melbourne, Australia, 17-20 Sept. Proceedings, p. 534.
- ROSE, N., P. BLANCHARD, G. LAROUR, G. LEDIGUERHER, E. EVENO, J. P. JOLLY, A. OGER, M. LEDIMMA, A. JESTIN, F. MADEC (2002): Post-weaning multisystemic wasting syndrome (PMWS) in France: serological profiles of affected versus non-affected herds and preliminary analytical epidemiology. Pig. J. 50, 124-134.
- ROSELL, C., J. SEGALÉS, J. PLANA-DURÁN, M. BALASH, G. M. RODRÍGIEZ-ARRIOJA, S. KENNEDY, G. M. ALLAN, F. MCNEILLY, K. S. LATIMER, M. DOMINGO (1999): Pathological, immunohistochemical, and in-situ hybridization studies of natural cases of postweaning multisystemic wasting syndrome (PMWS) in pigs. J. Comp. Pathol. 120, 59-78.
- SANCHEZ, R., H. NAUWYNUCK, M. PENSEART (2001): Serological survey of porcine circovirus 2 antibodies in domestic and feral pig populations in Belgium. Proc. ssDNA viruses of plants, birds, pigs and primates. St. Malo (France), 122.
- SCHMOLL, F., T. OPRIESSNIG, F. SCHILCHER, B. LEEB, B. BAUDER, M. SCHUH (2002): First description of postweaning multisystemic wasting syndrome (PMWS) in Austria. Wien. Tierärztl. Monatschr. 89, 50-56.
- SCHULTZE, C., G. NEUMANN, I. GRUTZE, A. ENGELHARDT, C. MIRLE, F. EHLERT, A. HLINAK (2003): Porcine circovirus type 2-infection in an European wild boar (*Sus scrofa*) in the state of Brandenburg, Germany. Deutsc. Tierärztl. Wochenschr. 110, 10, 426-428.
- SEGALÉS, J., M. SITJAR, M. DOMINGO, S. DEE, M. DEL POZO, R. NOVAL, C. SACRISTAN, A. DE LAS HERAS, A. FERRO, K. S. LATIMER (1997): First report of post- weaning multisystemic wasting syndrome in pigs in Spain. Vet. Rec. 141, 600-601.
- SEGALÉS, J. (2002): Update on postweaning multisystemic wasting syndrome and porcine dermatitis and nephropathy syndrome diagnostics. J. Swine Health Prod. 10, 277-281.
- SEGALÉS, J., M. DOMINGO (2002): Postweaning multisystemic wasting syndrome (PMWS) in pigs - a review. Vet. Q. 24. 109-124.
- SÉGALES, J., I. MARCO, M. CALSAMIGLIA (2002): Evidence of porcine circovirus type 2 infection in wild boar (*Sus scrofa*) in Spain. Proc. 17th IPVS Congress, Ames (USA), p. 397.
- SÉGALES, J., C. SCHULTZE, C. GORTAZAR, J. VICENTE, M. DOMINGO (2003): First description of postweaning multisystemic wasting syndrome in the wild boar (*Sus scrofa*) in Europe. Proceedings of the 4th International symposium on emerging and re-emerging pig diseases, June 29th – July 2nd, Rome, Italy, pp. 177-178.

- SÉGALES, J., M. CALSAMIGLIA, M. DOMINGO (2003): How we diagnose postweaning multisystemic wasting syndrome. Proceedings of the 4th International symposium on emerging and re-emerging pig diseases, June 29th – July 2nd, Rome, Italy, pp. 149-151.
- TOPLAK, I., J. GROM, P. HOSTNIK, D. BARLIĆ-MAGANJA (2002): Detection and differentiation of porcine circovirus types 1 and 2 in Slovenia using “multiplex PCR”. 3rd Slovenian veterinary congress, 6-7 December 2002, Portorož, Slovenia, p. 43.
- VINCENTE, J., J. SEGALÉS, U. HOFLE, M. BALASCH, J. PLANA-DURAN, M. DOMINGO, C. GORTÁZAR (2004): Epidemiological study on porcine circovirus type 2 (PCV2) infection in the European wild boar (*Sus scrofa*). *Vet. Res.* 35, 243-253.

Received: 15 August 2005

Accepted: 4 April 2006

LIPEJ, Z., J. SEGALÉS, D. NOVOSEL, B. ROIĆ, L. MANOJLOVIĆ: Sindrom kržljivosti odbijene prasadi u divljih svinja (*Sus scrofa*) u Hrvatskoj. *Vet. arhiv*, S41-S50, 2006.

SAŽETAK

Opisani su prvi slučajevi pojave svinjske cirkovirusne infekcije 2 (CVS2) u četiriju divljih svinja, povezanih s morfološkim promjenama karakterističnim za sindrom kržljivosti odbijene prasadi (SKOP) u domaćih svinja. Tijekom zime 2005. godine u ograđenom lovištu pronađena je uginula prasad divljih svinja u dobi od 2 do 5 mjeseci. Dijagnoza SKOP-a postavljena je nakon što su ispunjena sva tri ključna kriterija: prisutnost kliničkih znakova mršavljenja, nazočnost karakterističnih mikroskopskih promjena u limfatičnim tkivima i dokaz svinjskog cirkovirusa tip 2 (CVS2) u utvrđenim lezijama tehnikom hibridizacije in situ. To je ujedno prvi dokaz SKOP-a u divljih svinja na temelju svih znanstveno prihvatljivih dijagnostičkih kriterija.

Ključne riječi: sindrom kržljivosti odbijene prasadi, divlja svinja, *Sus scrofa*, patologija, svinjski cirkovirus tip 2, Hrvatska
