

The spectrum of tusk pathology in wild boar (*Sus scrofa* L.) from Croatia

Dean Konjević^{1*}, Uwe Kierdorf², Luka Manojlović³, Krešimir Severin¹,
Zdravko Janicki¹, Alen Slavica¹, Branimir Reindl⁴, and Igor Pivac⁵

¹Department for Game Biology, Pathology and Breeding, Faculty of Veterinary Medicine, University of Zagreb, Zagreb, Croatia

²Department of Biology, University of Hildesheim, Hildesheim, Germany

³Hunting ground "Moslavina", Zagreb, Croatia

⁴State Inspectorate of the Republic of Croatia, Zagreb, Croatia

⁵Croatian Forests d.d., Management Unit Osijek, Osijek, Croatia

KONJEVIĆ, D., U. KIERDORF, L. MANOJLOVIĆ, K. SEVERIN, Z. JANICKI, A. SLAVICA, B. REINDL, I. PIVAC: The spectrum of tusk pathology in wild boar (*Sus scrofa* L.) from Croatia. Vet. arhiv 76, S91-S100, 2006.

ABSTRACT

Pathological alterations in the permanent tusks of twenty male wild boars are presented. The animals were taken during regular hunting operations in the hunting area "Moslavina" near Garešnica (18 cases) and in hunting grounds near the Croatian/Bosnian border (Dvor na Uni, 1 case) and in Dalmatia (Vrgorac, 1 case). Tusk alterations comprised complete tusk fracture, deformation due to trauma during an early stage of tooth development, tusk duplication, tusk malposition, and pulp necrosis. Our findings indicate that the most frequent cause of tusk pathology is trauma to the teeth. We further discuss the significance of such pathology to the wild boar.

Key words: wild boar, tusks, trauma, pathology, pulp infection

Introduction

Tusks of mammals are continuously growing (elodont) anterior teeth (incisors, canines) that protrude from the mouth (STEENKAMP, 2003). For example, the tusks of African elephants (*Loxodonta africana*) and Asian elephants (*Elephas maximus*)

* Contact address:

Dean Konjević, DVM, Department for Game Biology, Pathology and Breeding, Faculty of Veterinary Medicine, University of Zagreb, Heinzlova 55, 10 000 Zagreb, Croatia, Phone: + 385 1 2390 156; Fax: + 385 1 2390 156; E-mail: dean.konjevic@vef.hr

are modified permanent upper incisors, whereas the tusks of the walrus (*Odobenus rosmarus*) are modified permanent upper canines. In male wild boar (*Sus scrofa*), both the maxillary and the mandibular permanent canines are developed as tusks (THENIUS, 1989; STEENKAMP, 2003). Normally, the opposing maxillary and mandibular tusks of wild boar wear each other down, thereby maintaining the normal length and functional shape of the teeth.

Tusks are characterized by a large, conically shaped pulp with a wide apical opening. Due to the lifelong presence of formative tissues at its apical end, the repair potential of continuously growing teeth like tusks is much higher than that of other teeth (MILES and GRIGSON, 1990). For continuously growing teeth of rodents, the presence of apically located, specialized epithelial structures containing adult stem cells has recently been suggested (OHSHIMA et al., 2005).

Despite the fact that wild boar tusks are collected as trophies by hunters and regularly displayed at trophy exhibitions, relatively few reports on pathological alterations of these teeth and/or their alveoli can be found in the scientific literature (MILES and GRIGSON, 1990; PALÁŠTHY and PALÁŠTHY, 1991; HORWITZ and DAVIDOVITZ, 1992; KIERDORF and KIERDORF, 2003; STEENKAMP, 2003; KIERDORF et al., 2004a; KIERDORF et al., 2004b; KONJEVIĆ et al., 2004a; KONJEVIĆ et al., 2004b). In this paper, we report our findings on pathological alterations in a sample of tusks from Croatian wild boar.

Materials and methods

A total of 20 tusk sets of male wild boar with one or more abnormal canines were collected in the period from 1996 to 2005. Of these, 18 sets (from wild boar Nos. 1-18) came from the hunting ground "Moslavina" (near the city of Garešnica), while one set (from wild boar No. 19) was obtained from the area of Dvor na Uni (near the Croatian – Bosnian border) and another one (from wild boar No. 20) from the region of Vrgorac in Dalmatia. All samples originated from animals that had been culled in the course of regular hunting operations.

Tusks were removed from the jaws according to the instructions given for trophy preparation (FRKOVIĆ, 1989; VARIČAK, 1997). The age of the individuals was estimated based on the length of the wear (whetting) surface of the mandibular tusks and by using the method of Brandt (WAGENKNECHT, 1979). Age estimation could not be performed in wild boar No. 4, due to the aberrant condition of its mandibular tusks. This individual was therefore just classified as "adult". All tusks were subjected to macroscopic examination. Tusk length (taken along the outer curvature of the tooth), and the length of the whetting surface of the mandibular tusks were measured with a flexible steel tape. In addition, the

anterior part of the mandible of wild boar No. 19 was radiographed (42 kV and 18 mAs). No histological analyses could be performed on the tusks, because their owners did not allow the use of destructive methods on the teeth.

Results and discussion

Fracture was the most common disorder observed in the wild boar tusks (Table 1). Our observation is in line with the statement by STEENKAMP (2003) that trauma is the most commonly described problem affecting tusks.

Table 1. Spectrum of tusk pathology in Croatian wild boars.

	Number of cases	Age of boars (years; average value)
Fracture of upper canines	4	6.25
Fracture of lower canines	6	6.16
Fracture of both upper and lower canines	3	6.33
Supernumerary teeth	1	8.0
Pulp necrosis	4	7.0
Early trauma	1	Adult
Malposition	1	7.0

Wild boar uses their tusks as powerful weapons in intraspecific and interspecific fights as well as for marking trees. In addition, tusks are used in feeding. Thus, according to BRIEDERMANN (1990), wild boar use their tusks as levers to lift up larger stones or other heavy objects in order to get access to food items located below them. The various ways in which tusks are used, in combination with the fact that they protrude from the mouth, makes them particularly prone to injury. Depending on the location and the intensity of an impact on a tusk, complete or incomplete intra- or extra-alveolar fracture can be observed (MILES and GRIGSON, 1990; PALÁŠTHY and PALÁŠTHY, 1991; KIERDORF et al., 2004b; KONJEVIĆ et al., 2004a; KONJEVIĆ et al., 2004b). The fracture-risk is increased when tusks exhibit overgrowth due to non-development, loss or malposition of the opposing tusk. The degree of overgrowth of a tusk is a function of the rate at which it elongates and the time it has been without an opposing tusk. Two impressive examples of symmetrical overgrowth of the lower tusks in wild boar are depicted in MILES and GRIGSON (1990, p.367). In the individuals with tusk fractures that were studied by us, we did not notice any significant overgrowth of the opposing tusk, which indicated that the observed injuries had occurred shortly before death.

A malformed and abnormally bent right C inf. (A in Fig. 1) was observed in boar No. 4. MILES and GRIGSON (1990) describe elephant tusks exhibiting similar malformations. The right C sup. of boar No.4 was missing, as was the tip of the lower left tusk, probably as a result of fracture. It may be assumed that the right C inf. was subjected to a strong impact dislocating the portion of the tusk already formed on the growth region.

Formation of distinct ledges demarcating an incisal from an apical tusk portion was observed in the tusks of four wild boar (Nos. 6, 16, 18, 20). As noted earlier (KIERDORF and KIERDORF, 2003) these changes can be of a symmetrical or asymmetrical nature. One of the affected lower canines (No. 16) was not filled with wax (which is normally done during tusk preparation), providing the opportunity to examine the pulp cavity (Fig. 2). Similarly to previously described cases (PALÁŠTHY and PALÁŠTHY, 1991; KIERDORF and KIERDORF, 2003; KONJEVIĆ et al., 2004b), a dentinal plug was found in the pulp cavity of this tooth. This plug separated the distal, *intra vitam* probably necrotic portion of the pulp from the proximal one, which *intra vitam* had remained viable. It was previously concluded that most likely bacterial invasion (that can occur via different routes) caused inflammation and partial necrosis of the dental pulp (KIERDORF et al., 2004a). The observed ledges are indicative of temporary growth arrest caused by the inflammation, which resulted in enamel hypoplasia.

Dentinal plugs in the pulp cavity can be macroscopically observed in split/broken tusks (PALÁŠTHY and PALÁŠTHY, 1991; KIERDORF and KIERDORF, 2003; KONJEVIĆ et al., 2004b) or radiographically in undamaged tusks (KIERDORF et al., 2004a). The plugs consist of tertiary (reparative) dentine, which is deposited in larger amounts as a reaction to pulp exposure (MURRAY et al., 2003).

The right C inf. of wild boar No. 18 exhibited a pronounced notch on its aboral aspect and an irregular shape apical to this notch (Fig. 3). It may be assumed that a severe impact on the tooth led to the observed damage and affected its growth region.

Occurrence of one or more supernumerary teeth is referred to as hyperodontia or polyodontia. Supernumerary teeth can result from the splitting of a tooth bud or from local hyperactivity of the dental lamina (GARVEY et al., 1999) and they have been reported in most tusk-bearing mammals (MILES and GRIGSON, 1990). A case of duplication of the left C sup. was observed in wild boar No. 7 (Fig. 4). Both canines had an abnormal position. Thus, the erupted part of the posterior (distal) tusk was orientated almost horizontally, and the tooth had grown against the anterior tusk. The latter projected downwards, rather than being curved upwards as would be normal, and had an abnormally large wear facet. Furthermore, the anterior tusk was flattened and the early stage of formation of two growth regions at the apical end was discernible (Fig. 5).



Fig. 1. Tusk set of wild boar No. 4. Note severely malformed right C inf. (A) with irregular surface (C). Dilacerated region was filled with wax during the standard preparation procedure.

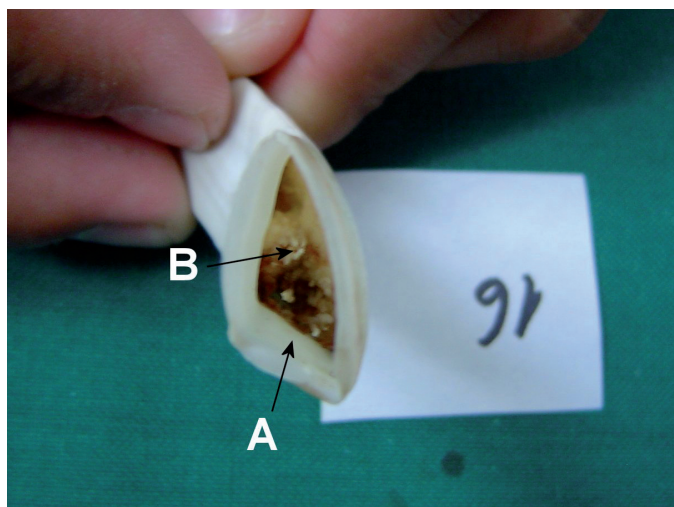


Fig. 2. Right C inf. of the wild boar No. 16. Note tertiary dentine within the pulp cavity (B).
A: tusk wall.



Fig. 3. Tusk set of wild boar No. 18. Note notch on the right C inf. and severely altered proximal portion of this tooth.

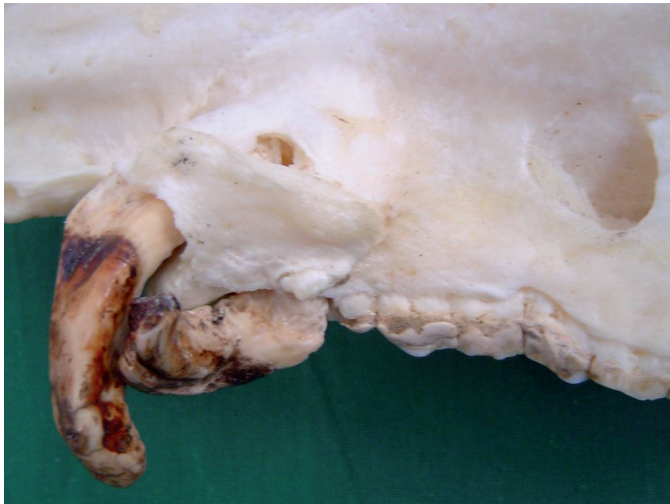

Fig. 4. Duplication of the left C sup. In wild boar No. 7. Note downward projection of the anterior of the two canines and horizontal position of the posterior tusk, which has grown against the anterior one.

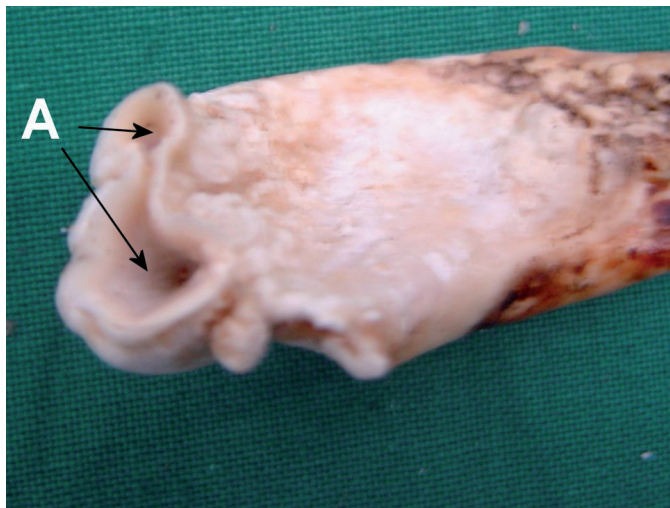


Fig. 5. Anterior of the two tusks from wild boar No. 7 shown in Fig. 4. Note flattening of the proximal tooth portion. Note early stage of development of two separate growth regions (A).

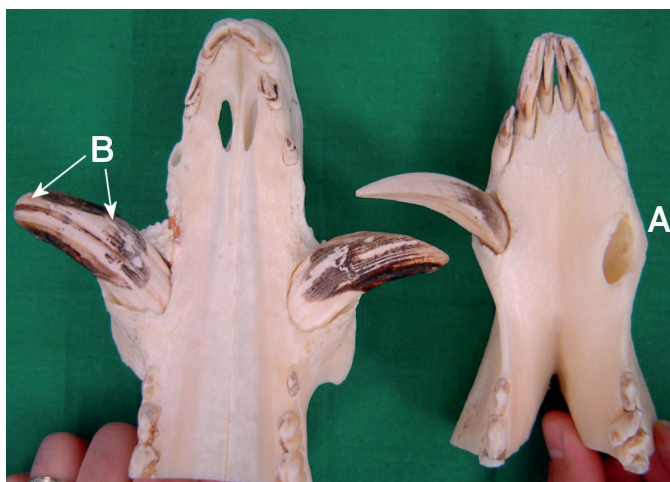

Fig. 6. Tusk set of wild boar No. 19. the right C inf. is missing. Note abnormal position of its alveolar opening (A), which is misplaced posteriorly. Right P3 and P4 are rotated. Position and length of the wear surface of the right C sup. (B) indicate later onset of attrition.

These abnormalities had probably been caused by the abnormal pressure exerted by the posterior tusk on this tooth. KONJEVIĆ et al. (2004a) previously described a wild boar C sup. with two completely separated growth regions. In that case, the splitting of the growth region was diagnosed to result from trauma to the tooth. The observed fenestration of the alveolar bone (Fig. 5) may be related to the abnormal pressure of the basal tooth portion on the alveolar wall and the resulting bone resorption.

Inspection of the tusk set of wild boar No. 19 revealed complete loss of the right C inf. and rotation by approximately 45° of the mandibular right P3 and P4 (Fig. 6). The presence of the alveolus of the right C inf. indicated that this tooth had erupted. The position of the alveolar opening (A in Fig. 6) was, however, abnormal, in that it was misplaced posteriorly. A similar case of tusk malposition and loss was described by KIERDORF et al. (2004b). We assume that the (congenital) malposition of the right C inf. caused the later onset of attrition. Evidence in support of this view is the fact that the wear surface on the right C sup. (B in Fig. 6) is less developed than that on the left C sup., which was in contact with the normally positioned left mandibular tusk. It is further assumed that due to this late contact with the opposing maxillary canine, the right C inf. had shown considerable overgrowth prior to establishment of such contact. It seems possible that loss of the right C inf. was caused by its abnormal position and growth. The alveolus is not filled with newly formed bone, indicating that loss of this tooth had occurred shortly before the animal's death.

In summary, we can conclude that their large size and the fact that they protrude from the mouth makes wild boar tusks particularly susceptible to trauma. On the other hand, tusks have an enormous reparative potential that is much higher than that of normal teeth. No information is available regarding the question whether or to what extent tusk disorders in wild boar exert negative effects on the animals. However, in the case of tusk infection, spreading of infection and deterioration of the general health state of the boar can be assumed.

Acknowledgement

We are grateful to Ivica Todorčić and Borislav Maršić for cooperation and for permission to use their private collections.

References

- BRIEDERMANN, L. (1990) Schwarzwild. 2. Aufl. Deutscher Landwirtschaftsverlag, Berlin, Germany.
- FRKOVIĆ, A. (1989): Lovačke trofeje, obrada, ocjenjivanje i vrednovanje Evropska divljač. Lovački savez Hrvatske, Zagreb, Hrvatska.

- GARVEY, T. M., H. J. BARRY, M. BLAKE (1999): Supernumerary teeth – an overview of classification, diagnosis and management. *J. Can. Dent. Assoc.* 65, 612-616.
- HORWITZ, L., K. DAVIDOVITZ (1992): Dental pathology of wild pigs (*Sus scrofa*) from Israel. *Israel J. Zool.* 38, 111-123.
- KIERDORF, H., U. KIERDORF (2003): Abnormal lower tusks in a male wild boar (*Sus scrofa* L.). *Z. Jagdwiss.* 49, 150-155.
- KIERDORF, U., D. KONJEVIĆ, Z. JANICKI, A. SLAVICA, T. KEROS, J. ČURLÍK (2004a): Tusk abnormalities in wild boar (*Sus scrofa* L.). *Eur. J. Wildl. Res.* 50, 48-52.
- KIERDORF, U., D. KONJEVIĆ, P. LAZAR, M. ŠEHIĆ, M. GRUBEŠIĆ (2004b): Malposition and loss of the left mandibular permanent canine in a male wild boar (*Sus scrofa* L.). *Eur. J. Wildl. Res.* 50, 213-215.
- KONJEVIĆ, D., U. KIERDORF, F. J. M. VERSTRAETE, Z. JANICKI, A. SLAVICA, T. KEROS, K. SEVERIN (2004a): Malformation of the permanent maxillary canine following dental infraction in a wild boar (*Sus scrofa* L.). *J. Zoo. Wildl. Med.* 35, 403-405.
- KONJEVIĆ, D., U. KIERDORF, Z. JANICKI, A. SLAVICA, T. KEROS, J. ČURLÍK (2004b): Some pathological changes in the tusks of wild boars (*Sus scrofa* L.) from Croatia and Slovakia. *Vet. arhiv* 74, 383-393.
- MILES, A. E. W., C. GRIGSON (1990): Colyer's variations and diseases of the teeth of animals, revised edition. Cambridge University Press, Cambridge.
- MURRAY, P. E., I. ABOUT, P. J. LUMLEY, J. C. FRANQUIN, L. J. WINDSOR, A. J. SMITH (2003): Odontoblast morphology and dental repair. *J. Dent.* 31, 75-82.
- OHSHIMA, H., N., NAKASONE, E. HASHIMOTO, H. SAKAI, K. NAKAKURA-OHSHIMA, H. HARADA (2005) The eternal tooth germ is formed at the apical end of continuously growing teeth. *Arch. Oral Biol.* 50, 153-157.
- PALÁŠTHY, J., S. PALÁŠTHY (1991): Klassifikation von Eckzahnmalien beim Wildschwein. *Z. Jagdwiss.* 37,195-203.
- STEENKAMP, G. (2003): Oral biology and disorders of tusked mammals. *Vet. Clin. Exot. Anim.* 6, 689-725.
- THENIUS, E. (1989) Zähne und Gebiß der Säugetiere. *Handbuch der Zoologie*, Vol. VIII, Part 56. W. de Gruyter, Berlin, Germany.
- VARIČAK, V. (1997): Ocjenjivanje lovačkih trofeja. Euroteam, Zagreb, Hrvatska.
- WAGENKNECHT, E. (1979): Altersbestimmung des erlegten Wildes. 5. Aufl. J Neumann-Neudamm, Melsungen, Germany, pp. 86-96.

Received: 15 August 2005

Accepted: 4 April 2006

KONJEVIĆ, D., U. KIERDORF, L. MANOJLOVIĆ, K. SEVERIN, Z. JANICKI, A. SLAVICA, B. REINDL, I. PIVAC: Spektar patoloških stanja na kljovama veprova (*Sus scrofa* L.) na području Hrvatske. Vet. arhiv 76, S91-S100, 2006.

SAŽETAK

Prikazane su patološke promjene na trajnim kljovama 20 veprova, uključujući potpune prijelome očnjaka, ozljede u tijeku rane faze razvoja zuba, prekobrojne očnjake, nepravilni položaj zuba i odumiranje pulpe. Veprovi su potjecali s područja lovišta "Moslavina" (u blizini Garešnice) te otvorenih lovišta u blizini državne granice s Bosnom i Hercegovinom (Dvor na Uni) i u Dalmaciji (Vrgorac), a odstrijeljeni su u sklopu redovitih lovnih zahvata. Iz prikazanih podataka razvidno je da je ozljeda najčešći uzrok patoloških promjena na kljovama. Nadalje, u radu se raspravljalo o značenju navedenih patoloških stanja za život i gospodarsku vrijednost vepva.

Ključne riječi: vepar, kljove, ozljeda, patologija
