

Autogenous skin transplant for repair of traumatic ventral hernia in sheep

Seifollah Nazhvani Dehghani^{1*}, and Mohtaram Nasrollahy²

¹*Department of Veterinary Surgery and Radiology, School of Veterinary Medicine, Shiraz University, Shiraz, Iran*

²*College of Medicine, University of Sarry, Sarry, Iran*

DEGHANI, S. N., M. NASROLLAHY: Autogenous skin transplant for repair of traumatic ventral hernia in sheep. Vet. arhiv 76, 269-274, 2006

ABSTRACT

Traumatic ventral abdominal hernia is common in sheep. Fifteen adult sheep affected with large ventral hernia defect were treated. Skin was harvested from the same sheep and replaced for the defective abdominal muscle and sutured. Subcutaneous tissue and skin were opposed over the transplanted skin and sutured. The animals were evaluated clinically, haematologically and by biopsy. Clinically, the animals ate and drank normally after surgery. The transplanted skins were perfectly secured in place. Leukocytosis with neutrophilia and lymphopenia were noticed in 77.7% of cases until the 5th day post-operation. Biopsy results indicated vascularization, atretic hair follicles and no signs of rejection. After six months there were signs of re-herniation and the transplanted skin began to enlarge, showing a defect in the abdominal wall in all cases.

Key words: sheep, hernia, skin transplant

Introduction

Acquired abdominal hernia may result from trauma such as vehicle accident and horning injuries. It tends to enlarge progressively and repair is indicated to prevent strangulation, pain or inconvenience (SABISTON, 1981; TIRGARY, 1980). If the hernia defect is small, re-approximation of the edges and simple closure of hernia is sufficient. For large-size hernia prosthetic material (BECKER et al., 1985; HUSTON and AZMY, 1985; SABISTON, 1981; TULLERNERS and FRETZ, 1983) should be used, or application of other techniques is necessary to reduce the gap of the abdominal wall (BURKITT et al., 1990; KAWCAK and STASCHAK, 1995; SCHWARTZ, 1969; TIRGARY, 1980; TULLERNERS and

* Contact address:

Dr. Seifollah Nazhvani Dehghani, Professor and Head, Department of Veterinary Surgery and Radiology, School of Veterinary Medicine, University of Shiraz, 71345-1731, Iran, Phone: +98 711 628 0701, 628 0702, 6280 703; Fax: +98 711 6280 707; E-mail: sdehghan04@yahoo.com

DONAWICK, 1983; WINTZER, 1962). Otherwise, the animal should be salvaged for slaughter or euthanized. In this study 15 sheep affected by hernia were treated, using their own skin to repair the abdominal wall gap. Therefore, the purpose of this study was to determine the feasibility of this technique and to monitor the treated sheep clinically, haematologically and by histological (biopsy) examination.

Materials and methods

Fifteen adult sheep (Mehraban breed) clinically affected by traumatized hernia defect were selected. Five male (ram) and 10 female (ewe) aged 28.20 ± 4.00 months, weighing 30.00 ± 4.30 kg were starved for 24 hours prior to operation. Blood samples were collected for complete blood count prior to operation and then daily until 10 days post-operation. None of the sheep showed an emergency surgical requirement and surgery was postponed for 3-5 days after reception.

Surgical technique. The animals were sedated with 0.2 mg/kg Xylazin HCl(*) and restrained in dorsa-lateral recumbency. The area, including the hernia sac, were shaved and prepared. Local analgesia was induced using Lidocaine HCl 1% by subcutaneous infiltration. The skin over the hernia defect was incised elliptically for removal of excess skin. The herniated intestine and other organs pushed back into the abdomen. Excess skin from the hernia sac was trimmed in an area smaller than the muscular defect in body wall, its fascia and connective tissue was then removed and was sutured to the body wall gap by simple interrupted suture using No. 1 chromic catgut. The facial surface of the transplanted skin was directed toward the peritoneum. The subcutaneous tissue was opposed over the transferred skin in a simple continuous pattern using the same suture material. The skin incision was sutured using No.1 Silk in a simple interrupted pattern.

Tissue samples from the transplanted skin were obtained for biopsy test on the 15th day post- operation. The skin specimen was fixed by buffered formalin 10%, prepared by using routine histological methods. Sections were stained by haematoxylin and eosin and studied by light microscopy. All patients received Oxytetracyclin 10 mg/kg intramuscular prior to the operation and continued until the 5th day post-operation. They were examined clinically daily for three months and then bimonthly for an additional six months. Local surgical area was tested for signs of heat, swelling, pain, etc.

Results

Size of hernia ring and the location of the hernia are presented in Table 1. Hernia contents were variable and consisted of omentum, small intestine, spiral colon and abomasum. Animals received half the daily ration for 3-5 days post-operation to prevent intra-abdominal pressure build up over the treated hernia area. Follow-up indicated that the transplanted skin was holding perfectly and no signs of complications or rejections were

noticed. Results of biopsy from the transplanted skin under the normal skin indicated the following percentages in each case: epidermal cell 66%, hyperkeratosis and hypodermis 33%, dermis 100%, fibroblast, collagen fibre and blood vessel 100%, chronic inflammatory cells 22%, median number of hair follicles 33%, sebaceous glands 11% and sweat glands in 77% of the cases, proving vascularization and atretic hair follicle (Fig.1). Leukocytosis with neutrophilia and lymphopenia were noticed in 77.7% of sheep until the 5th day post-operation. There were no significant changes in eosinophil, monocyte, haematocrit or haemoglobin. After six months the transplanted skin began to stretch and became enlarged to show a defect in the abdominal wall and re-herniation in all cases.

Table 1. Hernia repair in 15 adult sheep by autogenous skin transplant in the abdominal wall musculature gap

N ^o .	Age (month)	Sex	Mass (kg)	Hernia size cm ²	Location
1	28	F	40.0	108	Midline
2	34	F	39.0	60	Midline
3	38	F	37.5	30	L. para inguinal
4	29	F	38.5	56	R. para inguinal
5	33	F	41.5	36	RF
6	42	F	43.5	32	LF
7	28	M	40.0	64	RF
8	24	F	40.0	88	RF
9	22	F	49.0	30	RF
10	22	F	45.0	204	Midline
11	26	M	45.0	169	RF
12	25	M	38.0	225	RF
13	22	M	42.0	221	Midline
14	26	M	48.0	100	LF
15	24	F	48.0	49	LF

F = female, M = male, RF = right flank, LF = left flank

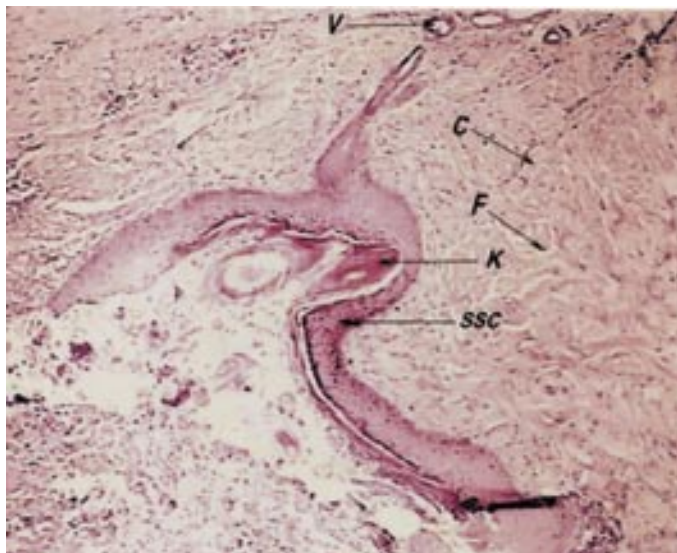


Fig.1. Biopsy from transplanted skin to abdominal muscle layer on 15th day post-surgical transplantation. C = capillary, F = fibroblast, K = regressing hair follicle, SSC = stratum spinosum converting to connective tissue, V = blood vessel, H&E, ×100.

Discussion

Skin transplantation has been used widely for repair of large cutaneous wounds in horses (McILWRAIT and TURNER, 1987); dogs (BOJRAB, 1992), and humans (BURKITT et al., 1990). In dog repair of cranial cruciate ligament, rapture has been accomplished by autogenous skin transplant (BOJRAB, 1992). Large defects of abdominal wall have been treated mainly by surgical mesh (KAWCAK and STASCHAK, 1995; McILWRAIT and TURNER, 1987; TULLERNERS and FRETZ, 1983). Autogenous or heterologous tissue has been used for treatment of hernia in humans (BURKITT et al., 1990; SABISTON, 1981; SCHWARTZ, 1969). Collagen-based biosynthetic material has been used for the repair of abdominal wall defects (WERKMEISTER et al., 1988). Preserved dura and pericardium have been used for closure of large abdominal wall and diaphragmatic defects in children (HUTSON and AZMY, 1985). The bovine pericardium has been used as a bioprosthesis for the closure of abdominal wall defects in calf (BECKER et al., 1985). There are no reports on the use of autogenous skin transplant in sheep, nor has there been a detailed study demonstrating the use of autogenous skin for repair of hernia defect in animals. Young collagen tissue was observed in all cases, indicating presence of connective tissue between transplanted skin and abdominal muscle layer, together with the presence of young blood vessels,

which proved vascularization and success of the graft. The absence of hair follicles and the atretic appearance of some hair follicles, as well as atretic sebaceous gland, indicated transformation of the skin to a different structure to meet the requirements of muscular support. The sheep were not treated in the same way as for emergency operation because the edges of the hernia ring muscles in a fresh traumatized situation are weak, friable and do not hold sutures properly. Also, muscle fibres tend to rip off. Therefore, a time lag of 3-5 days ensures strength and holding power in those muscles. In this study the fascia surface of the transplanted skin was faced towards the peritoneal cavity, which can provide good nourishment for the graft. It was not clear why the transplanted skin lost its tensile strength and stretched to an enlarged state, again showing re-herniation after 6 months. It is possible that twisting the skin in such a way that the epidermal surface of the transplanted skin faces the peritoneum would produce different results, with no re-herniation. Harvesting the skin and treating it by tannic materials prior to suturing it in the abdominal wall defect area is another possibility that requires further research in this area. However, autogenous skin transplant was a successful treatment for immediate surgical repair of abdominal wall defects in sheep.

References

- BEKER, M., B. KAEGI, M. WAXENBERGER (1985): The bovine pericardium. A bioprosthesis for the closure of abdominal wall defects in the calf. *Schweiz. Arch. Tierheikd.* 127, 379-383.
- BOJRAB, M. J. (1992): *Current Technique in Small Animal Surgery*. Lea & Febiger, Philadelphia. pp. 78-80.
- BURKITT, H. G., C. R. G. QUICK, D. GATT (1990): *Essential Surgery, Problems, Diagnosis and management*. Churchill Livingstone, Edinburgh. pp. 651-652.
- HUTSON, J. M., A. F. AZMY (1985): Preserved dura and pericardium for closure of large abdominal wall and diaphragmatic defects in children. *Ann. Coll. Surg. Engl.* 67, 107-108.
- KAWCAK, C. E., T. S. STASHAK (1995): Predisposing factors, diagnosis and management of large abdominal wall defects in horses and cattle. *J. Am. Vet. Med. Assoc.* 206, 607-611.
- McILWRAIT, C. W., A. S. TURNER (1987): *Equine Surgery Advance Technique*. Lea & Febiger, Philadelphia. pp. 234-239.
- SABISTON, D. C. jr (1981): *Davis-Christopher Textbook of Surgery, The Biological Basis of Modern Surgical Practice*. Saunders Co. Philadelphia. pp. 1346-1349.
- SCHWARTZ, S. I. (1969): *Principles of Surgery*. McGraw-Hill Book Co. New York. pp. 389.
- TIRGARY, M. (1980): Ventral hernia in the sheep. *Vet. Rec.* 106, 7-9.
- TULLERNERS, E. P., P. B. FRETZ (1983): Prosthetic repair of large abdominal wall defects in horses and food animals. *J. Am. Vet. Med. Assoc.* 182, 256-262.
- TULLERNERS, E. P., W. J. DONAWICK (1983): Secondary closure of infected abdominal incisions in cattle and horses. *J. Am. Vet. Med. Assoc.* 182, 1377-1379.

WERKMEISTER, J. A., G. A. EDWARDS, F. CASAGRANDA, J. F. WHITE, J. A. RAMSHAW (1988): Evaluation of collagen based biosynthetic material for the repair of abdominal wall defects. *J. Biomed. Mater. Res.* 39, 429-436.

WINTZER, H. J (1962): Methods for surgical treatment of bovine abdominal hernias. *J. Am. Vet. Med. Assoc.* 141, 131-134.

Received: 24 February 2004

Accepted: 2 May 2006

DEHGHANI, S. N., M. NASROLLAHY: Autologni presadak kože za liječenje traumatske ventralne kile u ovaca. *Vet. arhiv* 76, 269-274, 2006

SAŽETAK

Traumatska ventralna trbušna kila česta je u ovaca. U radu je operirano 15 ovaca s velikom ventralnom kilom. Koža je uzeta od same ovce s kilom i upotrijebljena kao nadomjestak za njezino trbušno mišićje. Potkožno tkivo i koža sašiveni su na presadak. Životinje su bile promatrane klinički, a učinjene su hematološke pretrage i biopsija. Nakon operacije životinje su normalno jele i pile. Presađena koža u potpunosti je srasla na mjestu presatka. Leukocitoza s neutrofilijom i limfopenijom ustanovljena je u 77,7% ovaca u tijeku pet dana poslije operacije. Rezultati pretrage biopsata pokazali su vaskularizaciju i atretične dlačne folikule. Nisu primijećeni znakovi odbacivanja presatka. Nakon šest mjeseci bilo je znakova povratka kile, a presađena koža se povećala te su se u svih operiranih ovaca pojavili znakovi poremećaja u trbušnoj stijenci.

Ključne riječi: ovca, kila, kožni presadak
